

High Ankle Sprains in Professional Ice Hockey Players

Prognosis and Correlation Between Magnetic Resonance Imaging Patterns of Injury and Return to Play

Brent Mollon,* MD, MSc, FRCSC, David Wasserstein,*[†] MD, MSc, FRCSC, Gráinne M. Murphy,[‡] MB, BCh, BAO, MMedSci, FFR, RCSI, Lawrence M. White,[§] MD, FRCPC, and John Theodoropoulos,*^{||¶} MD, MSc, FRCSC

Investigation performed at Mount Sinai Hospital, Toronto, Ontario, Canada

Background: Hockey players sustain a greater incidence of ankle syndesmosis injuries than other athletes. These injuries have a higher morbidity and more unpredictable recovery than lateral ankle sprains. Magnetic resonance imaging (MRI) has been used to establish the diagnosis but has not been evaluated for its ability to predict return to play.

Hypothesis: We hypothesized that patterns of injury defined on MRI could be used to predict return to play in a cohort of professional hockey players with syndesmosis sprains.

Study Design: Cohort study; Level of evidence, 3.

Methods: A prospectively collected National Hockey League (NHL) database was analyzed from the 2006-2007 to 2011-2012 seasons to assess return to play after an injury. A separate retrospective review of ankle MRI scans from professional hockey players with a documented high ankle sprain sustained between 2007 and 2012 was performed. Injuries were classified on MRI as complete or partial tears of the anterior-inferior tibiofibular ligament (AITFL), posterior-inferior tibiofibular ligament (PITFL), anterior talofibular ligament (ATFL), posterior talofibular ligament (PTFL), calcaneofibular ligament (CFL), and deltoid ligament. Fractures, bone contusions, and osteochondral lesions were also recorded.

Results: A total of 105 NHL athletes sustained high ankle sprains over the 5 seasons studied. Of these athletes, 85 were unable to play and missed a median of 8 games (range, 0-65 games). A retrospective MRI evaluation of 21 scans identified complete AITFL tears in 13 (62%) and high-grade partial tears in 5 (24%) cases. In contrast, the PITFL was partially torn in 9 (43%) and normal in 12 (57%) cases. Bone contusions were seen in 71% of cases and lacked a consistent pattern. The most commonly associated ligamentous injury was of the ATFL, which was injured in 52% of cases (11/21; 3 complete and 8 partial). There was no difference in the mean number of days lost when players were stratified by patterns of injury (incomplete/complete AITFL tear \pm additional ligamentous injury, bone contusion, syndesmosis width).

Conclusion: A high ankle sprain resulted in significant variations in time of recovery among professional hockey players. A torn AITFL and bone bruising were the most common patterns of injury. Although MRI can be used to confirm the diagnosis of a syndesmosis injury, it did not predict return to play in this population.

Keywords: high ankle sprain; magnetic resonance imaging; National Hockey League; cohort study

Injuries around the ankle are common in sports. One specific injury, a high ankle sprain or syndesmosis injury, involves damage to any or all of the anterior-inferior tibiofibular ligament (AITFL) and posterior-inferior tibiofibular ligament (PITFL) and the interosseous ligament. The most commonly described mechanism producing this injury is an external rotation force applied to a dorsiflexed ankle.¹¹

Rigid ankle immobilization, such as a hockey skate or ski boot, may predispose patients to the injury.⁷

While syndesmosis injuries comprise only 10% to 20% of ankle sprains across all athlete populations,^{3,5,8} this proportion appears to be higher in hockey players. For example, Flik et al⁶ reported that 36% of ankle injuries in National Collegiate Athletic Association (NCAA) hockey players were high ankle sprains, while 74% of ankle injuries involved the syndesmosis in 2 National Hockey League (NHL) teams evaluated for almost 10 years.¹⁵ This association is significant for both clinicians and athletes, as

The Orthopaedic Journal of Sports Medicine, 7(9), 2325967119871578

DOI: 10.1177/2325967119871578

© The Author(s) 2019

This open-access article is published and distributed under the Creative Commons Attribution - NonCommercial - No Derivatives License (<http://creativecommons.org/licenses/by-nc-nd/4.0/>), which permits the noncommercial use, distribution, and reproduction of the article in any medium, provided the original author and source are credited. You may not alter, transform, or build upon this article without the permission of the Author(s). For article reuse guidelines, please visit SAGE's website at <http://www.sagepub.com/journals-permissions>.

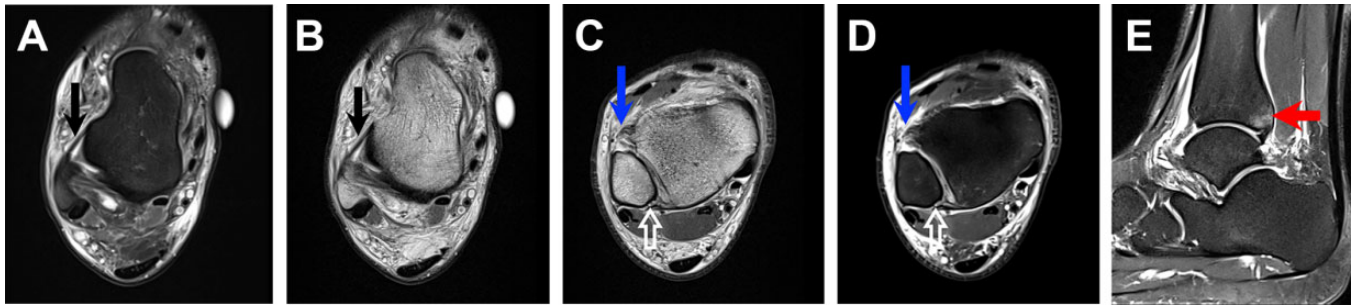


Figure 1. Example of magnetic resonance imaging (MRI) findings of high ankle sprains. (A, B) Axial intermediate and fat-suppressed T2-weighted MRI scans at the level of the anterior talofibular ligament (ATFL) demonstrating low signal intensity in the intact thin ATFL (black arrows). (C, D) Axial intermediate and T2-weighted fat-suppressed MRI scans at the level of the syndesmosis demonstrating a complete tear of the anterior-inferior tibiofibular ligament (thick blue arrows) and a partial stripping-type tear of the posterior-inferior tibiofibular ligament from the distal fibula (open white arrows). (E) Sagittal T2-weighted fat-suppressed MRI scan demonstrating bone bruising of the posterior tibial plafond (red arrow).

syndesmosis injuries are associated with increased time lost from sport or athletic activity when compared with other ankle injuries, such as lateral ankle sprains. This was demonstrated in a large review of United States Military Academy recruits, with high ankle sprains resulting in a mean recovery time of 55 days when compared with 28 days for third-degree lateral ankle sprains.⁹ The reported time to return to sport in professional athletes with a syndesmosis injury is variable, with recent series suggesting return to play in NHL and National Football League (NFL) athletes at a mean 45 days (range, 6-137 days) and 28 days (range, 8-90 days), respectively.^{10,15} In comparison, the mean time to return to play for lateral ankle sprains was 1.4 days (range, 0-6 days),¹⁵ further distinguishing the importance of this injury to the athlete.

The ability to predict return to play after a high ankle sprain would be a useful tool for athletes and the health care team involved in their recovery. While numerous clinical tests have been described to evaluate the ligaments around the ankle,¹ cadaveric studies have questioned the ability of clinical examinations to identify the discrete abnormality or discern normal from abnormal syndesmoses.² Classification systems such as the West Point Ankle Sprain Grading System⁸ have not been widely adopted, in part because the definition of instability remains controversial.

Magnetic resonance imaging (MRI) has been reliably shown to be the best diagnostic modality to evaluate high ankle sprains, with high sensitivity, specificity, and accuracy when compared with findings during ankle arthroscopic surgery.^{10,12} MRI can also identify a range of

associated abnormalities, including bone bruising, talar dome osteochondral lesions, and anterior talofibular ligament (ATFL) disruption,⁴ the presence of which may affect recovery times (Figure 1). However, utilizing constellations of MRI findings to predict return to play has been unsuccessful after high ankle sprains in NFL players.¹⁰ It is unclear if this finding translates to other professional sports. No study to date has evaluated the ability of MRI to help predict return to play in a group of professional hockey players.

To better understand the clinical course of high ankle sprains in professional hockey players, we reviewed the official NHL injury database to identify and report on players diagnosed with high ankle sprains. Additionally, we independently reviewed available ankle MRI scans from professional hockey players with a known diagnosis of a high ankle sprain to compare identified abnormalities against prospectively collected data on return to play. We hypothesized that the presence of concomitant abnormalities (ie, bone bruising, ATFL disruption) and degree of the syndesmosis injury on MRI would lengthen the time to return to play in this population.

METHODS

Upon approval from the NHL and the research ethics board of our institution, we undertook a retrospective review of the prospectively collected NHL injury database from the 2006-2007 to 2011-2012 seasons. We included professional hockey players diagnosed with a high ankle sprain/

*Address correspondence to John Theodoropoulos, MD, MSc, FRCSC, Mount Sinai Hospital, 600 University Avenue, Suite 20-440, Toronto, ON M5G 1X5, Canada (email: John.Theodoropoulos@sinaihealthsystem.ca).

*University of Toronto Orthopaedic Sports Medicine, Women's College Hospital, Toronto, Ontario, Canada.

†Division of Orthopaedic Surgery, Sunnybrook Health Sciences Centre, Toronto, Ontario, Canada.

‡Department of Radiology, Heartlands Hospital, University Hospitals Birmingham NHS Foundation Trust, Birmingham, UK.

§Division of Musculoskeletal Radiology, Mount Sinai Hospital, Toronto, Ontario, Canada.

||Division of Orthopaedic Surgery, Mount Sinai Hospital, Toronto, Ontario, Canada.

The authors declared that there are no conflicts of interest in the authorship and publication of this contribution. AOSSM checks author disclosures against the Open Payments Database (OPD). AOSSM has not conducted an independent investigation on the OPD and disclaims any liability or responsibility relating thereto.

Ethical approval for this study was obtained from the Mount Sinai Hospital Research Ethics Board.

syndesmosis injury by team physicians or medical staff. Information on team position, mechanism of injury, physical examination findings, and recovery period (number of professional games missed, days to pain-free return to sport) was extracted.

We then solicited team physicians for available ankle MRI scans of professional hockey players with known high ankle sprains. MRI was ordered at the discretion of team physicians for diagnostic purposes and was not performed for the purpose of this study. Available MRI scans were then sent, via a CD-ROM disc when performed at outside institutions, for an independent assessment. Patients were excluded if there was an associated ankle fracture or the timing of injury precluded an accurate assessment of return to play (ie, injuries occurring at the end of the season). Corresponding demographic and clinical data were compiled from a chart review, discussions with team physicians, and the NHL injury database.

MRI scans were then retrospectively reviewed by 2 musculoskeletal radiologists (L.M.W., G.M.M.) with expertise in ankle MRI. Recorded findings included integrity of the distal ankle ligaments (AITFL, PITFL, calcaneofibular ligament [CFL], ATFL, posterior talofibular ligament [PTFL], and deltoid ligament), presence and location of bone contusions or osteochondral injuries, and syndesmosis width. Radiologists were blinded to all clinical data beyond knowledge of a high ankle sprain diagnosis. Our definition of an AITFL or PITFL injury was similar to that of Oae et al.¹² To summarize, an injury was signified by either ligament discontinuity or a wavy/curved ligament contour in addition to intrasubstance high signal intensity on T2 sequences noted first on axial images and confirmed on sagittal and coronal views. This definition, when compared with intraoperative arthroscopic findings, is capable of identifying an injury to the AITFL with 100% sensitivity, 93% specificity, and 97% accuracy and an injury to the PITFL with a sensitivity, specificity, and accuracy of 100%. All ligaments (AITFL, PITFL, ATFL, PTFL, CFL, and deltoid ligament) were graded as normal, partial tear, or complete tear. A partial tear was determined if there was attenuation of the ligament and/or intrasubstance high signal intensity on T2-weighted imaging. A complete tear was defined as discontinuity or nonvisualization of the ligament. A bone contusion was defined as high marrow signal intensity on T2-weighted imaging, whereas a fracture was noted if there was a low signal intensity line on both T1- and T2-weighted sequences. Syndesmosis width was defined as the distance between the medial border of the fibula and the lateral border of the posterior tibia and was measured 1 cm above the tibial plafond.

Interrater reliability was not calculated in this series because of our methods of assessment and the range of MRI machines utilized by the various teams. However, several recent trials have established the reliability of MRI assessments in syndesmosis injuries.^{10,12-14}

As we are aware of no available tool to prognosticate high ankle sprains based on MRI, we proposed classifying high ankle sprains as follows: no or partial AITFL disruption, high-grade (>50%) partial or complete AITFL disruption, complete AITFL tear + 1 additional ligament partially/

completely disrupted, and complete AITFL tear + ≥ 2 additional ligaments partially/completely disrupted. The above classification system was compared with return to sport using analysis of variance. The presence of bone bruising and return to sport were compared using an independent *t* test. Syndesmosis width was treated as a nominal variable and compared with return to sport using analysis of variance. Clinical intuition and experience would suggest that bone bruising and/or more advanced ligamentous disruption would increase the odds of delay to return to sport, the most objective clinical measure available in this population. Data analysis was performed by SPSS Statistics (version 22.0.0; IBM) and Excel 2011 (version 14.3.6; Microsoft).

RESULTS

NHL Injury Database

The prospective injury database identified 107 high ankle sprains in 105 NHL athletes over the 5 seasons studied. All athletes were male. Database restrictions for confidentiality reasons precluded reporting on athlete age. Right ankles tended to be injured more often (57%; 60/105). High ankle sprains were most commonly reported in forwards (59%; 62/105), followed by defensemen (34%; 36/105) and goaltenders (7%; 7/105). The majority of injuries (85%; 89/105) occurred during the regular season; 9% (9/105) occurred during the preseason, and 7% (7/105) occurred during playoffs. Injuries most often occurred during games (88%; 92/105), with the remainder occurring during practices, with the exception of 1 off-ice injury. High ankle sprains occurring during games tended to occur earlier during play (45% in the first period, 32% in the second period, 23% in the third period, and 1% in overtime).

There was substantial variability in return to play in our sample. Twenty athletes (19%) were reported to have lost no time because of their injury. Of those 85 athletes unable to play after an injury, the median recovery time was 22.5 days (range, 1-271 days). These athletes missed a median of 8 games (range, 0-65 games).

MRI Findings

Team physicians from 5 Canadian hockey teams submitted 21 MRI scans from 19 professional hockey players (2 players had bilateral injuries/examinations separated in time). These investigations were performed between 2007 and 2012. All players were male, with a mean age of 24 years (range, 19-29 years). Twelve injuries were to the right ankle and 9 to the left ankle. The median time to MRI after injury was 3 days (range, 1-102 days). All except 2 patients were imaged within 3 weeks of the injury. Patients were unable to play in a mean of 18 professional hockey games (range, 0-35 games) and returned to sport, on average, 41 days after the injury. The recalled mechanism of injury was forced external rotation in 10 cases, combined hyperdorsi-flexion and external rotation in 5 cases, external rotation in

TABLE 1
Significance of MRI Findings on Return to Play
After High Ankle Sprains^a

Group	Return to Play, Mean ± SD, d	Significance
Based on degree of ligamentous injury		ANOVA:
No/partial AITFL disruption	38.2 ± 13.4	SSq = 29.1; <i>df</i> = 17; <i>F</i> = 2.6; <i>P</i> = .238
High-grade/complete AITFL disruption	72.0 ± N/A	
Complete AITFL tear + 1 additional ligament injured	38.4 ± 24.0	
Complete AITFL tear + ≥2 ligaments injured	42.0 ± 25.1	
Based on presence of bone bruising		<i>t</i> test:
Present	42.1 ± 19.1	<i>t</i> = 0.438; <i>df</i> = 19; <i>P</i> = .666
Absent	37.7 ± 25.0	
Based on syndesmosis width		ANOVA:
2 mm	36.0 ± N/A	SSq = 7.3; <i>df</i> = 17; <i>F</i> = 0.287; <i>P</i> = .961
3 mm	47.5 ± 28.6	
4 mm	40.3 ± 17.8	
5 mm	36.8 ± 26.5	

^aAITFL, anterior-inferior tibiofibular ligament; ANOVA, analysis of variance; MRI, magnetic resonance imaging; N/A, not available; SSq, sum of squares.

3 cases, plantarflexion/inversion in 1 case, and unclear in 2 cases.

All MRI scans evaluated were abnormal. Injuries to the AITFL were identified in 95% of cases (20/21; 13 complete, 5 high-grade partial, and 2 partial) and to the PITFL in 43% (9/21; 9 partial). There were no complete tears to the PITFL. The most commonly associated ligamentous injury was to the ATFL, which was injured in 52% of cases (11/21; 3 complete and 8 partial). The next most commonly injured was the deltoid ligament (29%; 1 complete, 5 partial, and 15 normal), followed by the CFL (19%; 4 partial and 17 normal). The PTFL was normal in all cases. The syndesmosis width ranged from 2 to 5 mm.

MRI revealed bone contusions in 15 of 21 cases (71%). The locations of contusions were variable and included the posterior/posteromedial talus, posterior/posteromedial tibia, and medial or lateral malleoli. An osteochondral defect was identified in 1 player, who only missed 3 professional games.

The correlation between MRI findings and return to play can be found in Table 1. Statistical analysis failed to establish any significant correlation between ligamentous injuries, bone contusions, fractures, or syndesmosis widening and return to play. A similar analysis (not reported) failed to show any correlation between MRI findings and the number of professional games missed for injuries occurring at the beginning of the season or midseason.

DISCUSSION

High ankle sprains are a relatively common injury in ice hockey players and result in greater time lost compared

with low ankle sprains. This cohort is the largest correlating MRI findings with return to sport in professional athletes with syndesmosis injuries and the only one specifically assessing professional hockey players. Our study suggests substantial variability in return to play after high ankle sprains in professional hockey players. Data from the NHL injury database suggested that players who required time off because of an injury needed a median of 22.5 days to recover and missed a median of 8 games. The MRI evaluation identified a myriad of ligamentous and bony structures injured with a high ankle sprain, most commonly the AITFL (95%), ATFL (52%), and PITFL (43%). Bone contusions were present in 71% of MRI scans and lacked a specific geographic pattern. We did not see a predictable pattern for either bone bruises or concomitant ligament injuries, perhaps reflecting possible varying degrees of foot position (plantar-dorsiflexion), energy, and mechanism of injury (contact vs noncontact) at the time of injury. It is also possible that a tightly tied hockey skate alters ankle biomechanics when compared with other sports. While the AITFL demonstrated the highest number of complete tears, the other ligaments were rarely completely torn. There was no association between MRI findings and either return to sport or the number of professional games missed.

The role of MRI for the diagnosis of high ankle sprains has been established in the literature and has been associated with high interrater reliability and sensitivity/specificity when compared with intraoperative findings.^{10,12-14} However, no features have been found to be associated with return to play. The results of our study are similar to those of Howard et al,¹⁰ who found no association between MRI and return to play in high-level NFL athletes. It remains unclear if MRI results predict return to sport in other sports or in those athletes at lower levels of competition. Based on these results, the primary benefits of MRI in cases of suspected high ankle sprains include confirmation of the diagnosis, exclusion of complications, and evaluation of other possible associated injuries, each of which may provide prognostic and management decision-making information to a sports medicine physician. However, MRI findings do not correlate with observed variable return-to-play time frames in individual elite athletes with confirmed imaging features of an isolated high ankle ligamentous injury.

Our trial does have limitations. As the NHL database allows for voluntary input from both physicians and trainers, it is possible that some injuries diagnosed as high ankle sprains were actually other abnormalities or that other players with a diagnosis of a high ankle sprain were not captured in this database. As there is no standardized treatment for high ankle sprains among teams, it is possible that MRI was only ordered on more severe cases or that return to play was explained by another factor (such as treatment). Similarly, the sharing of MRI scans for this study was voluntary, and we were only able to obtain a small number of MRI scans from Canadian teams. MRI was performed at several sites over numerous years and, as such, utilized differing protocols on a variety of scanners. While radiologists were blinded to the clinical course and the interpretation of the radiologist who initially read the

MRI scan, there is a potential for reader bias in that there was a known diagnosis of a syndesmosis injury.

Furthermore, while MRI has been associated with high interrater reliability and sensitivity/specificity when compared with intraoperative findings,^{10,12-14} no such evaluation was performed during our study, as all MRI scans were reviewed by a 2-person radiology team and all injuries were treated conservatively. Additionally, none of our MRI scans were contrast enhanced. Although some reports have described improved sensitivity and specificity with contrast administration,¹⁴ these reports were on earlier-generation MRI, and we believe that imaging quality has improved sufficiently in the interim to make noncontrast evaluations as accurate. Finally, despite being the largest collection of MRI scans from professional hockey players with high ankle sprains, our study may have been underpowered to detect factors associated with return to play.

CONCLUSION

High ankle sprains are associated with a variable but often high number of missed games in a cohort of elite hockey players in whom early return to play is crucial. A torn AITFL and bone bruising were the most common MRI findings. Although MRI can be used to confirm the diagnosis of a syndesmosis injury, it does not appear to predict return to play in this high-level athletic population.

REFERENCES

1. Amendola A, Williams G, Foster D. Evidence-based approach to treatment of acute traumatic syndesmosis (high ankle) sprains. *Sports Med Arthrosc Rev*. 2006;14(4):232-236.
2. Beumer A, van Hemert WL, Swierstra BA, Jasper LE, Belkoff SM. A biomechanical evaluation of clinical stress tests for syndesmosis ankle instability. *Foot Ankle Int*. 2003;24(4):358-363.
3. Boytim MJ, Fischer DA, Neumann L. Syndesmosis ankle sprains. *Am J Sports Med*. 1991;19(3):294-298.
4. Brown KW, Morrison WB, Schweitzer ME, Parellada JA, Nothnagel H. MRI findings associated with distal tibiofibular syndesmosis injury. *AJR Am J Roentgenol*. 2004;182(1):131-136.
5. Cedell CA. Ankle lesions. *Acta Orthop Scand*. 1975;46(3):425-445.
6. Flik K, Lyman S, Marx RG. American collegiate men's ice hockey: an analysis of injuries. *Am J Sports Med*. 2005;33(2):183-187.
7. Fritschy D. An unusual ankle injury in top skiers. *Am J Sports Med*. 1989;17(2):282-285, discussion 285-286.
8. Gerber JP, Williams GN, Scoville CR, Arciero RA, Taylor DC. Persistent disability associated with ankle sprains: a prospective examination of an athletic population. *Foot Ankle Int*. 1998;19(10):653-660.
9. Hopkinson WJ, St Pierre P, Ryan JB, Wheeler JH. Syndesmosis sprains of the ankle. *Foot Ankle*. 1990;10(6):325-330.
10. Howard DR, Rubin DA, Hillen TJ, et al. Magnetic resonance imaging as a predictor of return to play following syndesmosis (high) ankle sprains in professional football players. *Sports Health*. 2012;4(6):535-543.
11. Lin CF, Gross ML, Weinhold P. Ankle syndesmosis injuries: anatomy, biomechanics, mechanism of injury, and clinical guidelines for diagnosis and intervention. *J Orthop Sports Phys Ther*. 2006;36(6):372-384.
12. Oae K, Takao M, Naito K, et al. Injury of the tibiofibular syndesmosis: value of MR imaging for diagnosis. *Radiology*. 2003;227(1):155-161.
13. Takao M, Ochi M, Oae K, Naito K, Uchio Y. Diagnosis of a tear of the tibiofibular syndesmosis: the role of arthroscopy of the ankle. *J Bone Joint Surg Br*. 2003;85(3):324-329.
14. Vogl TJ, Hochmuth K, Diebold T, et al. Magnetic resonance imaging in the diagnosis of acute injured distal tibiofibular syndesmosis. *Invest Radiol*. 1997;32(7):401-409.
15. Wright RW, Barile RJ, Surprenant DA, Matava MJ. Ankle syndesmosis sprains in National Hockey League players. *Am J Sports Med*. 2004;32(8):1941-1945.