

Homozygous pathogenic variant in *BRAT1* associated with nonprogressive cerebellar ataxia

Areej Mahjoub, MD,* Zuzana Cihlarova, MS,* Martine Tétreault, PhD, Lauren MacNeil, PhD, Neal Sondheimer, MD, PhD, Keith W. Caldecott, PhD, Hana Hanzlikova, PhD, and Grace Yoon, MD, on behalf of the Care4Rare Canada Consortium

Neurol Genet 2019;5:e359. doi:10.1212/NXG.0000000000000359

Correspondence

Dr. Yoon
grace.yoon@utoronto.ca
or Dr. Hanzlikova
hana.hanzlikova@img.cas.cz

Abstract

Objective

To investigate the pathogenicity of a novel homozygous *BRAT1* variant in 2 siblings with nonprogressive cerebellar ataxia (NPCA) through functional studies on primary and immortalized patient cell lines.

Methods

BRAT1 protein levels and ataxia-telangiectasia mutated (ATM) kinase activity in patient-derived and control cell lines were assessed by Western blotting. The impact of the novel *BRAT1* variants on mitochondrial function was also assessed, by comparing patient and control cell lines for rates of oxygen consumption and for phosphorylation (S293) of the E1 α subunit of pyruvate dehydrogenase (PDH).

Results

Two male siblings with NPCA, mild intellectual disability, and isolated cerebellar atrophy were found to be homozygous for a c.185T>A (p.Val62Glu) variant in *BRAT1* by whole exome sequencing. Western blotting revealed markedly decreased *BRAT1* protein levels in lymphocytes and/or fibroblast cells from both affected siblings compared to control cell lines. There were no differences between the patient and control cells in ATM kinase activation, following ionizing radiation. Mitochondrial studies were initially suggestive of a defect in regulation of PDH activity, but there was no evidence of increased phosphorylation of the E1 α subunit of the PDH complex. Measurement of oxygen consumption rates similarly failed to identify differences between patient and control cells.

Conclusions

Biallelic pathogenic variants in *BRAT1* can be associated with NPCA, a phenotype considerably milder than previously reported. Surprisingly, despite the molecular role currently proposed for *BRAT1* in ATM regulation, this disorder is unlikely to result from defective ATM kinase or mitochondrial dysfunction.

*These authors contributed equally to this work.

From the Division of Neurology (A.M., G.Y.), Department of Paediatrics, University of Toronto, The Hospital for Sick Children, Canada; Department of Genome Dynamics (Z.C., K.W.C., H.H.), Institute of Molecular Genetics of the Czech Academy of Sciences, Prague, Czech Republic; Faculty of Science (Z.C.), Charles University in Prague, Czech Republic; Department of Neuroscience (M.T.), Université de Montréal, CHUM, Montréal, Québec, Canada; Department of Paediatric Laboratory Medicine (L.M.), Hospital for Sick Children; Department of Lab Medicine and Pathobiology (L.M.), University of Toronto, Ontario, Canada; Program in Genetics and Genome Biology (N.S.), SickKids Research Institute, Toronto, Ontario, Canada; Division of Clinical and Metabolic Genetics (N.S., G.Y.), Department of Paediatrics, University of Toronto, The Hospital for Sick Children, Toronto, Canada; and Genome Damage and Stability Centre (K.W.C., H.H.), School of Life Sciences, University of Sussex, Falmer, Brighton, UK.

Go to Neurology.org/NG for full disclosures. Funding information are provided at the end of the article.

Care4Rare Canada Consortium coinvestigators are listed in the appendix 2 at the end of the article.

The Article Processing charge was funded by the authors.

This is an open access article distributed under the terms of the Creative Commons Attribution-NonCommercial-NoDerivatives License 4.0 (CC BY-NC-ND), which permits downloading and sharing the work provided it is properly cited. The work cannot be changed in any way or used commercially without permission from the journal.

MORE ONLINE

▶ Videos

Glossary

AFP = alpha-fetoprotein; ATM = ataxia telangiectasia mutated; DCA = dichloroacetate; NPCA = non-progressive cerebellar ataxia; PDH = pyruvate dehydrogenase.

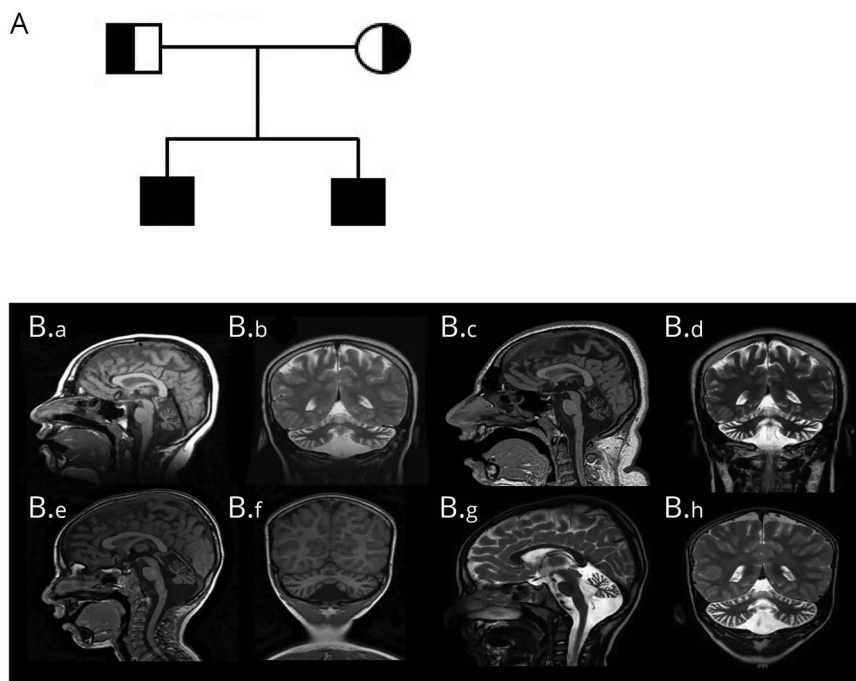
BRAT1 (*BRCA1*-associated ataxia telangiectasia mutated [ATM] activator 1) mutations were initially identified to cause rigidity and multifocal seizure syndrome, lethal neonatal (RMFSL, OMIM #614498).¹ Nonlethal phenotypes were subsequently described in several patients with biallelic *BRAT1* mutations, with clinical features ranging from severe developmental delays, ataxia, and seizures to “atypical” RMFS with no lethality.^{2–8} The underlying mechanism for this phenotypic variability is unknown. We report 2 brothers with a novel homozygous *BRAT1* variant who present with a much milder phenotype than reported in the literature to date, with mild intellectual disability, nonprogressive cerebellar ataxia (NPCA), and stable cerebellar atrophy on serial brain imaging. Functional studies confirmed markedly decreased levels of *BRAT1* protein in both affected patients’ cells compared to controls.

Clinical report

We describe 2 brothers with NPCA and ocular motor apraxia born to a healthy, nonconsanguineous couple of Pakistani descent. The family history was negative for ataxia, developmental delays, seizures, or other neurologic disorders.

Sibling 1, currently 24 years of age, was born spontaneously at term. Pregnancy and delivery were uneventful except for clubfoot noted at birth. He rolled at 3 months, sat without support at 7–8 months, pulled to stand at 12 months, and crawled at 18 months. At the age of 15 months, parents noted gait instability with frequent falls. Limb ataxia was formally documented at 3 years of age. He spoke his first words at 4 years, was able to ambulate independently, and continued to make steady developmental gains. By 8 years, he was able to feed himself, drink from a cup, write single letters and numbers, and perform simple mathematical calculations. He completed education at the college level and is fully independent for all activities of daily living, although he uses a walker for longer distances. Neurologic examination revealed normal head circumference and mild dysarthria with monophasic scanning speech. He had mild ocular motor apraxia, saccadic smooth pursuit, and gaze-evoked nystagmus (video 1), and fundoscopy was normal. Dysmetria and dysdiadochokinesia were evident, and he had truncal titubation. Gait was ataxic and he was unable to complete tandem gait (video 2). Extensive metabolic and other laboratory investigations, including microarray and serum alpha-fetoprotein (AFP) were normal, as were EMG and nerve conduction studies. Serial brain imaging at 9 and 16 years of age revealed

Figure 1 Pedigree and brain imaging



(A) Family pedigree. (B) Neuroimaging findings in the affected siblings. (B.a–B.d) Serial brain imaging for sibling 1. (B.a) Sagittal T1 image at 9 years showing normal cerebrum and brainstem, with diffuse cerebellar atrophy and moderately dilated fourth ventricle with prominent CSF spaces surrounding the cerebellum. (B.b) Coronal T2 image at 9 years showing cerebellar atrophy of both hemispheres and vermis. (B.c) Sagittal T1 and (B.d) coronal T2 images for sibling 1 at the age of 16 years, shows similar findings of stable severe cerebellar atrophy. (B.e–B.h) Serial brain imaging for sibling 2. (B.e) Sagittal T1 image at 3 years showing cerebellar volume loss with prominent CSF spaces and fourth ventricle; brain and brainstem are normal. (B.f) Coronal T1 at 3 years showing small vermis and cerebellar hemispheres. (B.g) Sagittal T2 and (B.h) coronal T2 images for sibling 2 at the age of 5 years showing stable cerebellar atrophy.

stable isolated cerebellar atrophy (figure 1, A–D). Molecular testing of *FXN*, *APTX*, *SETX*, and spinocerebellar ataxia types 1, 2, 3, 6, 7, 8 was normal. Muscle biopsy showed no overt histopathologic abnormalities, and CoQ10 levels in muscle were normal. Mitochondrial studies of patient-derived fibroblasts revealed a decreased native pyruvate dehydrogenase (PDH) level of 0.38 nmoles/min/mg protein compared with that of control (0.73) but the activated PDH (with dichloroacetate, [DCA]) was restored to the normal levels of 1.12, compared with control (1.22). The cellular lactate/pyruvate ratio of 6.1 was low in patients compared with control (12.09).

Sibling 2, currently 7 years of age, was born spontaneously at term following a normal pregnancy. He first sat at 8 months, stood with support at 12 months, but did not walk until 21 months. He spoke his first words at 12 months but did not speak in full sentences until 4.5 years of age. His hearing is normal but he wears glasses for myopia. He attends a regular grade 2 program, with an individualized educational plan, speech therapy, occupational therapy, and physical therapy support. He has no swallowing difficulties or bulbar

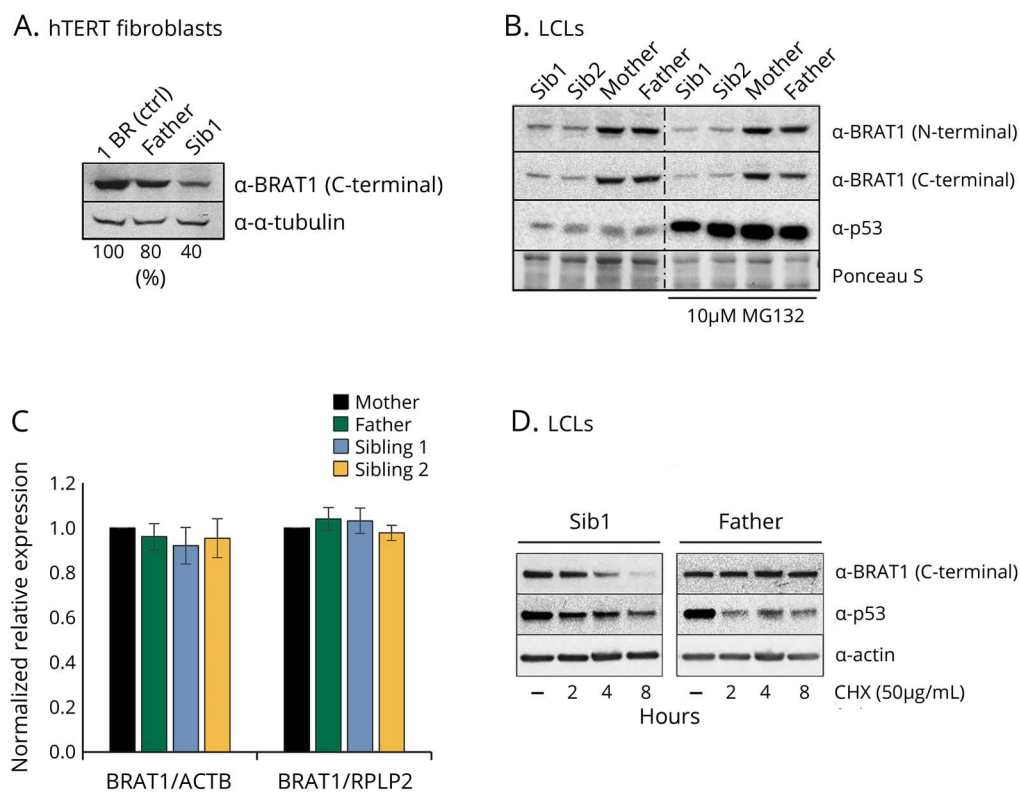
symptoms, and is able to walk without assistance, but with a clearly ataxic gait. Neurologic examination revealed normal head circumference, and funduscopy was normal. He had dysarthria, ocular motor apraxia, saccadic smooth pursuit, gaze-evoked nystagmus, dysmetria, dysdiadochokinesia, and mild wide-based ataxic gait with unsteadiness while turning. He was unable to perform tandem gait. Metabolic investigations including serum AFP, microarray, EMG, and NCS were normal. Brain imaging at the ages of 3 and 5 years revealed stable isolated cerebellar atrophy, similar to his brother (figure 1, E–H).

Methods

Standard protocol approvals, registrations, and patient consents

This study was approved by the Research Ethics Board of The Hospital for Sick Children (#100009004). Tissue samples were obtained with appropriate informed consent according to the declaration of Helsinki principles of medical research involving human subjects. The parents provided written

Figure 2 BRAT1 expression in patient cells



(A) Quantification of BRAT1 protein in control (1BR), parent (Father), and BRAT1 patient (Sib1) hTERT fibroblasts normalized to tubulin levels using *Image studio lite*. (B) BRAT1 protein levels measured in BRAT1 patients' (Sib1 and Sib2) and parents' (Mother and Father) LCLs before and after incubation with the proteasome inhibitor MG132 by Western blotting. p53 was used as a positive control. (C) BRAT1 mRNA levels in parents' (Mother and Father) and patients' (Sib1 and Sib2) LCLs as measured by qPCR. (D) BRAT1 protein levels measured in BRAT1 patient (Sib1) and parent (Father) LCLs before and after incubation with the protein synthesis inhibitor CHX by Western blotting. Note that default exposure levels were adjusted. p53 was used as a positive control. CHX = cycloheximide; LCL = lymphoblastoid cell line.

informed consent to participate in this study, including publication of videos.

Whole exome sequencing and BRAT1 expression

Whole exome sequencing of genomic DNA extracted from blood lymphocytes from both siblings identified a homozygous missense c.185T>A (p.Val62Glu) variant in *BRAT1*. There are no homozygotes for this *BRAT1* variant in large databases of genetic variation including the Genome Aggregation Database (gnomad.broadinstitute.org/; accessed July 2019). The parents were each heterozygous carriers of the variant. This mutation, which is located in the middle of the second exon encoding a putative CIDE-N domain, markedly reduced the level of BRAT1 protein in patient-derived cell lines from both affected siblings (figure 2, A and B). This reduction was not due to decreased levels of BRAT1 mRNA, which were similar in the patients' and parental cells (figure 2C), suggesting instead that it might reflect instability of the mutant BRAT1 protein. Indeed, although we could not restore normal levels of BRAT1 protein in the patient cells by incubation with the proteasome inhibitor MG132 (figure 2B), incubation with cycloheximide to prevent nascent protein synthesis revealed that the half-life of the mutant protein was much shorter than the parental BRAT1 (figure 2D). This instability could reflect incorrect folding of

the mutant protein, and/or reduced binding to one or more as yet unidentified protein partners.

ATM kinase activation studies

BRAT1 has been reported to be important for ATM phosphorylation at Ser1981 and for activation of this protein kinase by DNA damage.⁹ We therefore compared ATM autophosphorylation and transphosphorylation of its downstream targets (e.g., Chk2, p53, and H2AX) in patient and parental control cells lines, following ionizing radiation. Surprisingly, however, we failed to detect a defect in the BRAT1 patient cells in ATM kinase activity (figure 3).

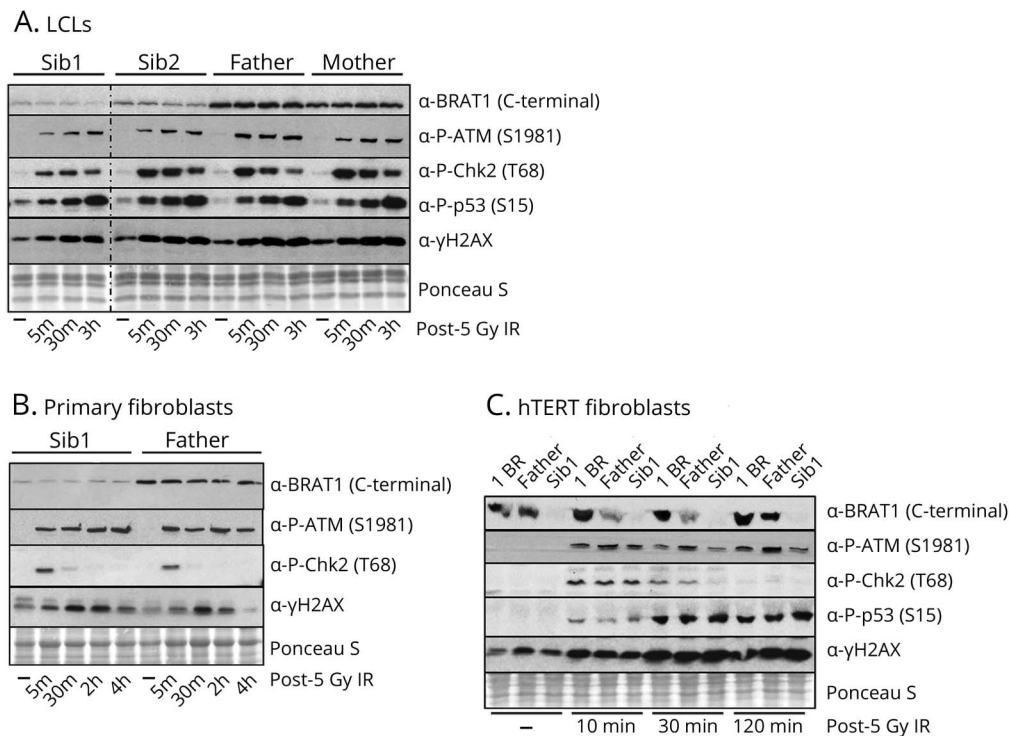
Mitochondrial studies

Despite initial indications of a possible PDH dysfunction, analysis of the E1 α subunit of this protein for phosphorylation at S293 by Western blotting failed to identify a difference between patient and parent control cells, even with the addition of DCA (figure 4A). Moreover, measurement of oxygen consumption rates in fibroblasts did not reveal any differences between the patient and the parental control cells (figure 4B).

Data availability

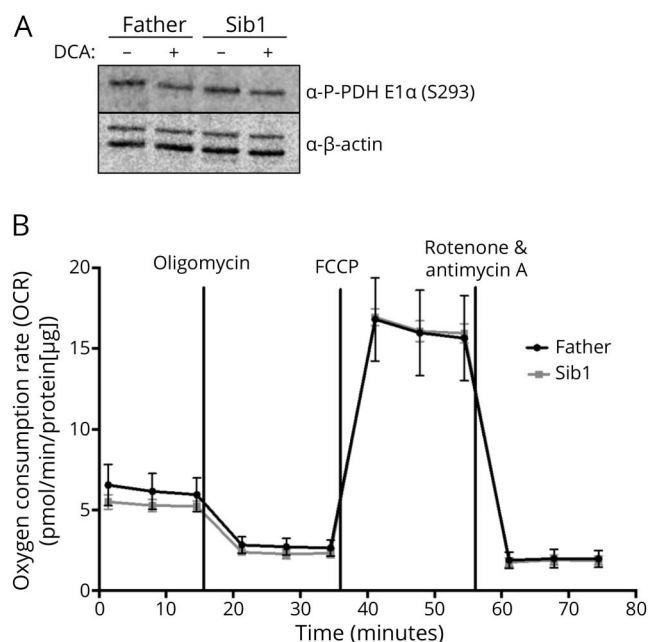
Detailed methods are available as supplemental data (e-Methods, links.lww.com/NXG/A185). All data presented in this study are available on reasonable request.

Figure 3 ATM activation in BRAT1 patient cells



Western blot analysis of the phosphorylation of ATM kinase and its downstream substrates in indicated BRAT1 patients (Sib1 and Sib2), parents (Mother and Father), and control (1BR) (A) LCLs, (B) primary fibroblasts and/or (C) hTERT fibroblasts before and after ionizing irradiation (IR, 5 Gy) as indicated. ATM = ataxia telangiectasia mutated.

Figure 4 Analysis of PDH E1 α phospho293 (S293) expression and oxygen consumption rates in parent and BRAT1 patient primary fibroblasts



(A) Representative Western blot analysis showing no observed differences in PDH E1 α S293 expression in parent (Father) and BRAT1 patient (Sib1). Protein lysates were extracted from untreated cells or fibroblasts treated with 5 mM DCA (B) OCRs of the same fibroblast cells using the Seahorse XFe96 Extracellular Flux Analyzer (Seahorse Bioscience). OCR was normalized to protein to eliminate differences in growth rate between cell lines ($n = 8$ wells/cell line). DCA = dichloroacetate; PDH = pyruvate dehydrogenase; OCR = oxygen consumption rates.

Discussion

We describe 2 brothers, both homozygous for a pathogenic variant in *BRAT1*, with NPCA, ocular motor apraxia, and isolated cerebellar atrophy, which was nonprogressive on serial brain imaging. Seizures have not been observed in either of the affected siblings. While both siblings have mild intellectual disability, the elder brother completed education at college level and is independent for ambulation at the age of 24. Variable but consistently severe phenotypes have been associated with biallelic *BRAT1* mutations ranging from RMFSL to severe neurodevelopmental disorder with cerebellar atrophy with or without seizures (NEDCAS, OMIM #618056). The reason for this variable phenotype is not well understood, but the possibility of hypomorphic *BRAT1* variants, which have less disruptive effects on protein function resulting in a milder phenotype has been considered.^{3,4} The nonprogressive nature and considerably milder clinical course of the patients we describe are consistent with NPCA, which has never been previously associated with biallelic mutations in *BRAT1*.

BRAT1 has been reported to interact with the tumor-suppressor BRCA1 (breast cancer type 1) and ATM, and is believed to play a role in the activity of these proteins during cellular responses to DNA damage.⁹ However, the exact mechanism(s) by which mutations in *BRAT1* trigger neurodegeneration and to what

extent a defect in ATM function contributes to this disease are unknown. We therefore evaluated a potential effect of the novel *BRAT1* variant on ATM protein kinase activity following DNA damage. Surprisingly, however, *BRAT1* patient cells did not exhibit a defect in ATM protein kinase activity following DNA damage induced by exposure to ionizing radiation. This may reflect differences in the cell lines and experimental systems employed in the studies.⁹ Nevertheless, our data strongly suggest that defective ATM activity does not contribute to the *BRAT1* disease phenotype.

One patient with biallelic mutations in *BRAT1* exhibited severely reduced cytochrome c oxidase enzyme histochemical staining on muscle biopsy, suggestive of mitochondrial dysfunction.⁷ In another study, loss of *BRAT1* expression caused decreased cell proliferation and increased glucose uptake and reactive oxygen species production, also suggestive of mitochondrial impairment.¹⁰ In the current study, analysis of fibroblasts from sibling 1 revealed decreased native PDH, again consistent with a mitochondrial defect. However, a muscle biopsy from sibling 1 was essentially normal, and DCA activation restored PDH to normal levels, suggesting that mitochondrial function was intrinsically normal. Indeed, we were unable to demonstrate a deleterious impact of the *BRAT1* variant on either PDH regulation or oxygen consumption rate in the patient cells.

A major consequence of the Val62Glu homozygous variant in *BRAT1* appears to be reduced *BRAT1* protein levels and it is possible that this mutation also affects one or more as yet unidentified activities of this protein. We note that the Val62Glu mutation resides within a putative CIDE-N domain, a domain identified previously in apoptotic nucleases.

Finally, we highlight here that biallelic pathogenic variants in *BRAT1* can be associated with NPCA, a phenotype considerably milder than previously reported, but which should be considered in the differential diagnosis of NPCA.

Acknowledgment

The authors thank the family for participating in this study. This work was selected for study by the Care4Rare Canada (Enhanced Care for Rare Genetic Diseases in Canada) Consortium Gene Discovery Steering Committee: Kym Boycott (lead; University of Ottawa), Alex MacKenzie (co-lead; University of Ottawa), Jacek Majewski (McGill University), Michael Brudno (University of Toronto), Dennis Bulman (University of Ottawa), and David Dymant (University of Ottawa). HH is funded by an ERC Advanced Investigator Award (SIDSCA; 694996) to KWC. The study was supported by the Charles University, project GA UK fellowship (project No. 1212219) to ZC.

Study funding

This study was supported by Genome Canada, the Canadian Institutes of Health Research, the Ontario Genomics Institute, Ontario Research Fund, Genome Quebec, Children's

Hospital of Eastern Ontario Foundation, and The Hospital for Sick Children. The study was funded by an ERC Advanced Investigator Award to KWC (SIDSCA; 694996). The study was supported by the Charles University, project GA UK fellowship (project No. 1212219) to ZC.

Disclosure

Disclosures available: Neurology.org/NG.

Publication history

Received by *Neurology: Genetics* February 25, 2019. Accepted in final form July 29, 2019.

Appendix 1 Authors

Name	Location	Role	Contribution
Areej Mahjoub, MD	University of Toronto, Toronto, ON, Canada	Author	Contributed clinical data and wrote the first draft of the manuscript
Zuzana Cihlarova, MS	Institute of Molecular Genetics of the Czech Academy of Sciences, Prague, CZ	Author	Acquisition of BRAT1/ATM data, analysis and interpretation, critical revision of the manuscript for important intellectual content
Martine Tétreault, PhD	Université de Montréal, Montréal, QC, Canada	Author	Performed analysis of whole exome sequencing data, critically reviewed the manuscript for important intellectual content
Lauren MacNeil, PhD	University of Toronto, Toronto, ON, Canada	Author	Clinical mitochondrial analyses and interpretation, critical revision of the manuscript for important intellectual content
Neal Sondheimer, MD, PhD	University of Toronto, Toronto, ON, Canada	Author	Mitochondrial study concept and design, acquisition of data, analysis and interpretation, critical revision of the manuscript for important intellectual content
Keith W. Caldecott, PhD	University of Sussex, Falmer, Brighton, UK	Author	Critical revision of the manuscript for important intellectual content
Hana Hanzlikova, PhD	Institute of Molecular Genetics of the Czech Academy of Sciences, Prague, CZ	Author	BRAT1/ATM study concept and design, acquisition of data, analysis and interpretation, critical revision of the manuscript for important intellectual content

Appendix 1 (continued)

Name	Location	Role	Contribution
Grace Yoon, MD	University of Toronto, Toronto, ON, Canada	Author	Overall study concept and design, acquisition of data, analysis and interpretation, critical revision of the manuscript for important intellectual content, and overall study supervision

Appendix 2 Co-investigators

Name	Location	Role	Contribution
Kym Boycott	University of Ottawa, Ottawa, Canada	Co-investigator	Care4Rare Canada Consortium Steering Committee
Alex MacKenzie	University of Ottawa, Ottawa, Canada	Co-investigator	Care4Rare Canada Consortium Steering Committee
Jacek Majewski	McGill University, Canada	Co-investigator	Care4Rare Canada Consortium Steering Committee
Michael Brudno	University of Toronto, Canada	Co-investigator	Care4Rare Canada Consortium Steering Committee
Dennis Bulman	University of Ottawa, Canada	Co-investigator	Care4Rare Canada Consortium Steering Committee
David Dymont	University of Ottawa, Canada	Co-investigator	Care4Rare Canada Consortium Steering Committee

References

- Puffenberger EG, Jinks RN, Sougnez C, et al. Genetic mapping and exome sequencing identify variants associated with five novel diseases. *PLoS One* 2012;7: e28936.
- Hanes I, Kozenko M, Callen DJ. Lethal neonatal rigidity and multifocal seizure syndrome—A misnamed disorder? *Pediatr Neurol* 2015;53:535–540.
- Mundy SA, Krock BL, Mao R, Shen JJ. BRAT1-related disease—identification of a patient without early lethality. *Am J Med Genet A* 2016;170:699–702.
- Srivastava S, Olson HE, Cohen JS, et al. BRAT1 mutations present with a spectrum of clinical severity. *Am J Med Genet A* 2016;170:2265–2273.
- Fernández-Jaén A, Álvarez S, So EY, et al. Mutations in BRAT1 cause autosomal recessive progressive encephalopathy: report of a Spanish patient. *Eur J Paediatr Neurol* 2016;20:421–425.
- Valence S, Cochet E, Rougeot C, et al. Exome sequencing in congenital ataxia identifies two new candidate genes and highlights a pathophysiological link between some congenital ataxias and early infantile epileptic encephalopathies. *Genet Med* 2019;21:553–563.
- Horn D, Weschke B, Knierim E, et al. BRAT1 mutations are associated with infantile epileptic encephalopathy, mitochondrial dysfunction, and survival into childhood. *Am J Med Genet A* 2016;170:2274–2281.
- Smith NJ, Lipssett J, Dibbens LM, Heron SE. BRAT1-associated neurodegeneration: intra-familial phenotypic differences in siblings. *Am J Med Genet A* 2016;170:3033–3038.
- Aglipay JA, Martin SA, Tawara H, Lee SW, Ouchi T. ATM activation by ionizing radiation requires BRCA1-associated BAAT1. *J Biol Chem* 2006;281:9710–9718.
- So EY, Ouchi T. BRAT1 deficiency causes increased glucose metabolism and mitochondrial malfunction. *BMC Cancer* 2014;14:548.