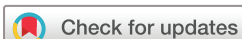

# Endoscopic ultrasound in the assessment of advanced duodenal adenomatosis in familial adenomatous polyposis

Peter L Labib,<sup>1</sup> George Goodchild,<sup>1,2</sup> James P Turbett,<sup>2</sup> James Skipworth,<sup>3</sup> Arjun Shankar,<sup>3</sup> Gavin Johnson,<sup>2</sup> Sue Clark,<sup>4,5</sup> Andrew Latchford,<sup>4,5</sup> Stephen P Pereira <sup>1,2</sup>

**To cite:** Labib PL, Goodchild G, Turbett JP, *et al*. Endoscopic ultrasound in the assessment of advanced duodenal adenomatosis in familial adenomatous polyposis. *BMJ Open Gastro* 2019;**6**:e000336. doi:10.1136/bmjgast-2019-000336

Received 15 August 2019  
Revised 2 September 2019  
Accepted 4 September 2019



© Author(s) (or their employer(s)) 2019. Re-use permitted under CC BY-NC. No commercial re-use. See rights and permissions. Published by BMJ.

<sup>1</sup>Institute for Liver & Digestive Health, University College London, London, UK

<sup>2</sup>Gastroenterology, University College London Hospitals NHS Foundation Trust, London, UK

<sup>3</sup>Hepatopancreaticobiliary Surgery, Royal Free Hospital, London, UK

<sup>4</sup>St Mark's Hospital, London, UK

<sup>5</sup>Surgery and Cancer, Imperial College London, London, UK

## Correspondence to

Prof Stephen P Pereira;  
stephen.pereira@ucl.ac.uk

## ABSTRACT

**Objective** Current surveillance strategies for duodenal adenomatosis in familial adenomatous polyposis (FAP) miss malignancies and underestimate cancer risk in ampullary disease. This study aimed to evaluate the utility of endoscopic ultrasound (EUS) in the assessment of FAP patients with duodenal and/or ampullary polyposis referred for surgical intervention.

**Design** A retrospective analysis of FAP patients undergoing index EUS between December 2006 and May 2015 was performed. Follow-up was completed in January 2018, including review of all EUS procedures and surgical interventions (median follow-up 6 years).

**Results** Fifty-five patients underwent 188 EUS procedures. Six patients (11%) developed malignancy (three duodenal, three ampullary). Ampullary cancer risk was underestimated by Spigelman stage and overestimated by Kashiwagi classification. Ultrasound findings were poor predictors of malignancy, with common bile duct dilatation being the only finding present in one EUS prior to a diagnosis of ampullary cancer. The best predictors of ampullary malignancy were an ampullary polyp size >3 cm and an increase >1 cm in ampullary polyp size. Ampullary polyp size >3 cm provided the best predictive value, correctly identifying two of the three cases of ampullary cancer and both patients with high-grade dysplasia. EUS biopsy failed to detect malignancy later confirmed by surgical histology in two patients.

**Conclusion** EUS surveillance confers little additional benefit to standard endoscopic surveillance in FAP patients. The best predictor of ampullary malignancy is an ampullary polyp >3 cm; this could be regarded as a relative indication for surgery.

## INTRODUCTION

Duodenal adenomatosis is a common extra-colonic manifestation of familial adenomatous polyposis (FAP) with a lifetime risk approaching 100%.<sup>1</sup> Due to improved patient identification and prophylactic colectomy, duodenal and ampullary cancer are now leading causes of cancer-related mortality in FAP.<sup>2–4</sup> Guidelines advocate endoscopic

## Summary box

### What is already known about this subject?

- ▶ Despite recognition of the benefits of endoscopic surveillance of duodenal adenomatosis in familial adenomatous polyposis (FAP), current practice still misses malignancies and underestimates cancer risk in ampullary disease.
- ▶ Endoscopic ultrasound (EUS) may provide additional information that could better identify patients at highest risk of malignant transformation, but evidence for this is lacking.

### What are the new findings?

- ▶ EUS findings were poor predictors of malignancy. The best predictors for ampullary cancer were a polyp size >3 cm and an interval polyp size increase of >1 cm; both visual rather than ultrasound findings.

### How might it impact on clinical practice in the foreseeable future?

- ▶ EUS should not be considered superior to duodenoscopy alone in the duodenal surveillance of FAP patients unless there are specific indications for its use. An ampullary polyp >3 cm is a relative indication for surgery, regardless of the biopsy result.

surveillance of the upper gastrointestinal tract from age 25 years or when FAP is diagnosed, if later.<sup>5–7</sup> Although patients diagnosed with cancer through screening have a better prognosis than those diagnosed once symptoms develop, prognosis remains poor.<sup>2,8</sup> Because most patients will not develop cancer and duodenal surgery is associated with significant morbidity and mortality,<sup>7,9</sup> surveillance aims to identify patients at highest risk of malignant transformation to operate before cancer develops, while avoiding surgery in patients with lower risk disease.

Severity of duodenal adenomatosis is usually assessed using the modified Spigelman and/or Kashiwagi classifications (table 1).<sup>10,11</sup>

**Table 1** Modified Spigelman and Kashiwagi classifications

Modified Spigelman classification for duodenal assessment					
Score					
Criterion	1 point	2 points	3 points		
Number of polyps	1–4	5–20	>20		
Polyp size (mm)	1–4	5–10	>10		
Histological architecture	Tubular	Tubulovillous	Villous		
Dysplasia	Low grade	–	High grade		
Stage					
Number of points	0	1–4	5–6	7–8	9–12
Stage	0	I	II	III	IV
Kashiwagi classification for ampullary assessment					
Criterion	Minor ampullary polyposis	Major ampullary polyposis			
Size	<10mm	≥10mm			
Histological architecture	Tubular	Tubulovillous or villous			
Dysplasia	Low	High			

Adapted from Saurin *et al* and Kashiwagi *et al*.<sup>11 17</sup>

The Spigelman classification uses two macroscopic and two histological criteria to calculate the Spigelman stage (0–IV). Because this classification does not assess the ampulla separately, and ampullary adenomas pose a greater risk of malignant transformation,<sup>12</sup> some centres also perform ampullary assessment using the Kashiwagi classification. The surveillance interval is determined by these assessments.

However, current practice has several limitations. Guidelines recommend different surveillance intervals that have led to inconsistent practice. Time for progression from Spigelman stage IV disease to duodenal adenocarcinoma is highly variable and there is potential for developing interval cancers between surveillance endoscopies.<sup>13</sup> Up to 13% of patients undergoing surgery are diagnosed with malignancy in the surgical histology that was not detected at preoperative endoscopy.<sup>14</sup> Reasons for this include biopsy sampling error and a paucity of macroscopic features of malignancy such as ulceration, firmness, friability and contact bleeding.<sup>9 15</sup> Roughly half of patients who develop cancer do not have Spigelman stage IV disease.<sup>16</sup> Lastly, the lack of distinction between ampullary and non-ampullary polyposis in the Spigelman classification underestimates the need for more intensive surveillance in patients with ampullary disease.<sup>4 12 17</sup>

Endoscopic ultrasound (EUS) may provide additional information compared with duodenoscopy that could address some of these limitations.<sup>9</sup> We performed a retrospective analysis of FAP patients with advanced ampullary or duodenal adenomatosis referred for EUS assessment to determine if EUS improved cancer detection and/or selection of patients for surgery.

## METHODS

### Duodenoscopy surveillance programme

St Mark's Hospital coordinates a duodenoscopy surveillance programme for FAP patients. Patients were entered into surveillance at the age of 25 years or at diagnosis of FAP (if later). A side-viewing duodenoscope assessed the severity of duodenal and ampullary polyposis using Spigelman and Kashiwagi classifications and surveillance schedules were determined based on the disease severity as per local guidelines. Patients whose disease could be endoscopically managed (eg, endoscopic resection/polypectomy) remained under surveillance at St Mark's Hospital. Those with stage IV duodenal polyposis no longer amenable to endoscopic management, Kashiwagi major ampullary disease no longer amenable to endoscopic management or suspected malignancy were referred for surgical assessment.

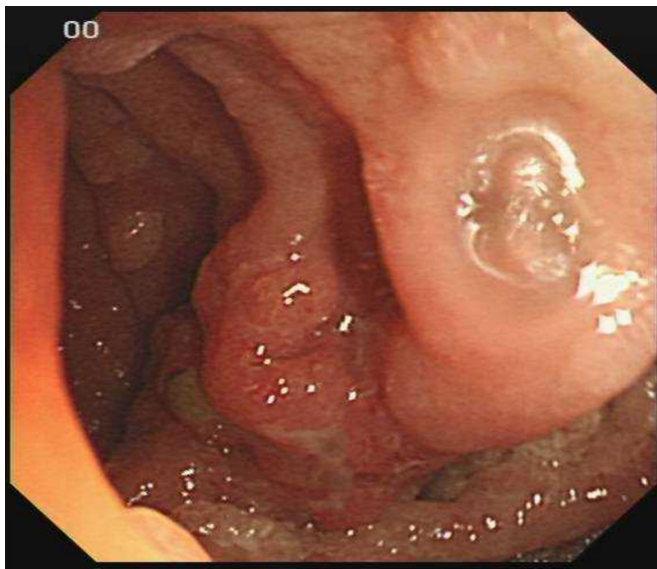
### Surgical assessment, index EUS and EUS surveillance programme

The majority of patients (89%) were referred from the surveillance programme at St Mark's Hospital. All referred patients underwent index EUS and CT to confirm that the disease was no longer endoscopically resectable, to exclude established malignancy and identify significant desmoid disease precluding surgical intervention. Based on the CT and EUS results:

- ▶ Patients with suspected malignancy or high-risk disease confirmed not amenable to endoscopic management underwent surgery if appropriate.
- ▶ Patients whose disease was reclassified as endoscopically manageable (eg, suspected ampullary polyp reclassified as periampullary with no proximal extension) were discharged back to the referring hospital for ongoing endoscopic management and standard duodenoscopy surveillance.
- ▶ Patients whose disease was not considered to be at imminent risk of malignant transformation but confirmed to be not endoscopically manageable (eg, ampullary polyp with proximal extension) were entered into the EUS surveillance programme, undergoing annual EUS in lieu of duodenoscopy.

### Patient cohort

A retrospective analysis of FAP patients undergoing an index EUS at University College Hospital London (UCLH) between December 2006 and May 2015 was performed. Patients were identified from the procedure indications on the electronic endoscopy database. The cohort was cross-checked at St Mark's and further patients identified based on referral records. EUS reports were reviewed independently by two investigators to determine endoscopic findings, ultrasound findings, Spigelman stage and Kashiwagi classification. Positive ultrasound findings were defined as documented pancreatic duct (PD) dilatation ≥5mm, common bile duct (CBD) dilatation ≥8mm, muscularis propria invasion and paraduodenal lymphadenopathy. Follow up to January 2018 was



**Figure 1** Endoscopic appearance of a duodenal polyp with mucosal ulceration.

completed by reviewing electronic records at UCLH, Royal Free Hospital and St Mark's to identify subsequent endoscopic, EUS and surgical procedures and histology. General practitioners were contacted to provide patient outcomes when secondary care data were not available.

### EUS procedure

A Pentax oblique-viewing echoendoscope with linear ultrasound probe and Hitachi HI VISION Preirus ultrasound platform was used. The duodenum was assessed with the echoendoscope visually as per conventional duodenoscopy. Ultrasound of the duodenum, paraduodenal structures and dominant polyps was performed. Polyp size was estimated visually using open biopsy forceps (Radial Jaw 4, Boston Scientific) and biopsies taken from polyps  $\geq 10$  mm.

### Data analysis

Comparison of groups was assessed using Student's unpaired t-test (continuous parametric data), Mann-Whitney U test (continuous non-parametric data) and Fisher's exact test (dichotomous data). Statistical analysis was performed using IBM SPSS Statistics V.25.

## RESULTS

### Demographics

Between December 2006 and May 2015, 55 FAP patients underwent an index EUS. Median age was 51 years (range 27–75) and 20 patients (36%) were female. Forty-nine (89%) were referred from St Mark's, three were internal referrals from UCLH and three were referred from other UK hospitals.

### EUS frequency

The 55 patients underwent 188 procedures. Sixteen (29%) underwent one EUS, whereas 39 had two or more EUS procedures (median 4, range 2–10) over a median

of 3.8 years (range 0.1–9.0). Median interval between procedures was 12 months (range 1–65).

### Index EUS

#### Spigelman stage, ampullary disease and Kashiwagi classification

Spigelman stage at index EUS was II in 11 (20%) patients, III in 36 (65%) patients and IV in 8 (15%) patients. Twenty-nine patients (53%) had polyps  $\geq 10$  mm and 16 (29%) had  $\geq 20$  polyps. The most common histological architecture was tubulovillous (90.9%) followed by tubular (3.6%) and villous (1.8%). Two biopsies (3.6%) did not comment on histological architecture. Although no biopsies demonstrated high-grade dysplasia or malignancy, one patient with Spigelman stage IV disease had duodenal cancer diagnosed on their surgical histology 3 months post-EUS (see 'Risk of malignancy' section below).

In the 47 patients whose EUS commented on the ampulla, 34 (72%) had macroscopic ampullary disease. Median polyp size was 15 mm (range 6–57 mm). In the 33 who had ampullary biopsy (97%), 28 (85%) showed tubulovillous adenoma, 2 (6%) showed tubular adenoma and 1 (3%) showed villous architecture. Two biopsies (6%) did not comment on histological architecture. Two biopsies (6%) demonstrated high-grade dysplasia and both patients underwent surgery (see below). In the 34 patients with ampullary disease, 32 (94%) had Kashiwagi major disease.

### Endoscopic ultrasound findings

Seven patients (13%) had abnormal EUS findings; these were dilated PD (n=4), dilated CBD (n=1), dilated PD and CBD (double duct sign, n=1) and small volume lymphadenopathy (n=1). No patients demonstrated muscularis propria invasion. One of the seven patients was diagnosed with ampullary cancer after a second EUS (see below).

### Other endoscopic findings

A visual finding suggestive of malignancy is mucosal ulceration overlying a polyp (figure 1). This was observed in two patients; both underwent surgery and one was found to have duodenal cancer (see 'Surgical intervention' below).

### Surveillance EUS procedures

#### Spigelman stage, ampullary disease and Kashiwagi classification

Of the 39 patients who underwent more than one EUS, 12 (22%) had an increase in their Spigelman stage. Median interval from index EUS to an increase in Spigelman stage was 23 months (range 11–108). Patients with an increase in Spigelman stage were more likely to have had longer follow-up (62 vs 42 months,  $p=0.033$ ).

Thirty-three patients (85%) had data available to determine their Kashiwagi classification over time. At index EUS, 25 patients (76%) had macroscopic Kashiwagi major ampullary disease and 8 (24%) had normal ampullae. In those eight, three had normal ampullae at their last EUS, whereas five had developed macroscopic



Kashiwagi major ampullary disease. All biopsies bar one showed low-grade dysplasia, the exception showing ampullary adenocarcinoma (see 'Risk of malignancy' section below).

In 37 patients it was possible to estimate polyp size increase over their surveillance. Five patients had an ampullary polyp size increase of  $\geq 10$  mm; three patients with existing ampullary polyps and two patients with previously normal ampullae. Two of the three ampullary cancers that developed on EUS surveillance occurred in patients with size increases of  $\geq 10$  mm (over 1 and 5 years, respectively).

#### Ultrasound and other endoscopic findings

Fourteen patients (36%) had positive ultrasound findings during their surveillance; five in their index EUS and nine at a subsequent EUS. These occurred in Spigelman stage II (n=1), stage III (n=11) and stage IV (n=2) disease. Seven had progressive findings, three had transient findings and four had regressing findings on subsequent procedures. In those with progressive findings, six developed CBD dilatation and one patient with a dilated CBD developed double duct sign. In those with transient findings, one had temporary PD dilatation, one had transient small volume lymphadenopathy and one patient with a normal index EUS developed small volume lymphadenopathy, then CBD dilatation, then finally had a normal EUS. In those with regressing findings, two patients had resolution of PD dilatation from index EUS and one patient with small volume lymphadenopathy developed PD dilatation, then CBD dilatation and then had a normal EUS. The final patient with PD dilatation on index EUS had double duct sign on several subsequent EUS procedures, with their last EUS showing CBD dilatation only. No procedures demonstrated muscularis propria invasion.

#### Surgical intervention

Twelve patients (22%) underwent surgery; seven after one EUS, three while under EUS surveillance and two after being discharged from EUS surveillance (table 2). Surgical indications in patients following one EUS were large ampullary polyp (n=2), large ampullary polyp with double duct sign (n=1) or PD dilatation (n=1), ulceration overlying a dominant duodenal polyp (n=2) and severe carpeting duodenal polyposis (n=1). Surgical indications for the three patients on EUS surveillance were biopsy-proven ampullary cancer, ampullary polyposis with PD dilatation and widespread duodenal polyposis. Both patients undergoing surgery after discharge from EUS surveillance developed duodenal cancer 4 and 5 years post-discharge. At last preoperative EUS, the Spigelman stages were IV (n=4), III (n=7) and II (n=1). Ten of the 11 patients whose ampullae were commented on had Kashiwagi major ampullary polyposis. Five had positive EUS findings; PD dilatation (n=2), double duct sign (n=1) and ulceration overlying a dominant polyp (n=2). The operations undertaken were pancreaticoduodenectomy (n=7),

total pancreatectomy, duodenectomy and splenectomy (n=2) and abandoned pancreaticoduodenectomy due to extensive desmoid disease (n=3). The final diagnoses (based on surgical histology or latest biopsy if resection abandoned) were duodenal cancer (n=3), ampullary cancer (n=2), ampullary tubulovillous adenomas (TVA) with focal moderate-grade or high-grade dysplasia (n=3), ampullary TVA with low-grade dysplasia (n=3) and widespread duodenal polyposis with no malignancy (n=1). In the three cases of cancer that occurred in patients still under the care of UCLH and the Royal Free Hospital, one ampullary cancer was diagnosed on biopsy preoperatively whereas the other ampullary cancer and duodenal cancer were diagnosed on surgical histology (having shown moderate-grade and low-grade dysplasia on their last EUS, respectively).

#### Risk of malignancy and predictive value of Spigelman stage and Kashiwagi classification

Six patients (10.9%) developed malignancy over a median follow-up of 6 years (range 0.2–9.8). Three developed duodenal adenocarcinoma and three developed ampullary adenocarcinoma. One was diagnosed after one EUS, three while on EUS surveillance and two several years after discharge from EUS surveillance.

In the three patients with duodenal cancer:

- ▶ Patient 1's index EUS demonstrated an ulcerated duodenal polyp, Spigelman stage IV disease with no ampullary involvement and no positive ultrasound findings. Biopsy demonstrated low-grade dysplasia, but pancreaticoduodenectomy confirmed a T3N0 duodenal adenocarcinoma. They developed metastatic disease postoperatively.
- ▶ Patient 2's index EUS demonstrated Spigelman stage IV disease, a 1 cm ampullary polyp and no positive ultrasound findings. The patient was discharged as CT demonstrated significant desmoid disease that precluded prophylactic surgery. Four years later, they developed duodenal cancer and underwent pancreaticoduodenectomy at their local hospital. They died of short gut syndrome 11 months postoperatively.
- ▶ Patient 3's index and repeat EUS 6 months later demonstrated Spigelman stage II disease with ampullary involvement. The patient moved out of area and had ongoing endoscopic surveillance at their local hospital. They developed duodenal cancer 5 years later and underwent pancreaticoduodenectomy but developed metastatic disease postoperatively.

It is difficult to comment on the predictive value of Spigelman stage for duodenal cancer due to the low number of cases and the fact that two occurred several years after discharge from EUS surveillance. While it can be presumed that the second patient continued to have stage IV disease, the Spigelman stage of the last patient prior to cancer occurrence is not known. Acknowledging these limitations and after excluding the third patient, the risk of duodenal cancer in Spigelman stage IV disease was 10.5% over a median follow-up of 3.2 years.

**Table 2** Clinical details of patients undergoing surgical intervention

Patient	Reason for referral	EUS total	Length of EUS surveillance (months)	Spigelman stage	Macroscopic ampullary disease	Ampullary polyp size (mm)	Kashiwagi classification	EUS findings	Surgery	Cancer	Surgical histology	Outcome/further details
1	EUS at referring hospital suggestive of early ampullary cancer	8	89	IV	Present	40	Major	Transient small lymph nodes and CBD dilatation	Laparotomy	Ampullary	–	Last EUS confirmed ampullary adenocarcinoma on biopsy. Attempted pancreaticoduodenectomy abandoned due to extensive desmoid disease
2	High grade dysplasia in duodenal polyposis	1	–	IV	Absent	–	–	Polyp ulceration	Pancreaticoduodenectomy	Duodenal	pT3N0 duodenal adenocarcinoma	Died of metastatic duodenal cancer 3 years postoperatively
3	5 cm ampullary polyp	1	–	III	Present	57	Major	None	Pancreaticoduodenectomy	–	TVA with focal HGD	–
4	3 cm ampullary polyp	1	–	III	Present	35	Major	None	Pancreaticoduodenectomy	–	TVA with focal HGD	–
5	3 cm ampullary polyp	3	64	III	Present	15	Major	Polyp ulceration	Laparotomy	–	–	Attempted pancreaticoduodenectomy abandoned due to extensive desmoid disease. Returned to EUS surveillance
6	2.5 cm ampullary polyp	1	–	III	Present	30	Major	Double duct sign	Pancreaticoduodenectomy	–	TVA with LGD	–
7	2 cm ampullary polyp	1	–	IV	Present	10	Major	None	Total pancreatectomy, duodenectomy & splenectomy	Duodenal	Unavailable	Discharged back to referrer as desmoid disease precluded prophylactic surgery. Developed duodenal cancer 4 years after discharge. Surgery performed at other hospital. Patient died from short gut syndrome 1 year postoperatively
8	Multiple ampullary polyps	2	6	III	Present	15	Major	Transient PD dilatation	Pancreaticoduodenectomy	Ampullary	T3N1 ampullary adenocarcinoma	Developed metastatic disease 2 years postoperatively
9	Severe duodenal polyposis and 1 cm ampulla	1	–	IV	Present	15	Major	PD dilatation	Pancreaticoduodenectomy	–	TVA with focal MGD	–
10	Severe duodenal polyposis not amenable to endoscopic management	1	–	III	Present	7	Minor	None	Total pancreatectomy, duodenectomy & splenectomy	–	Widespread duodenal polyposis, no malignancy	–

Continued

Table 2 Continued

Patient	Reason for referral	EUS total	Length of EUS surveillance (months)	Spigelman stage	Macroscopic ampullary disease	Ampullary polyp size (mm)	Kashiwagi classification	EUS findings	Surgery	Cancer	Surgical histology	Outcome/further details
11	Duodenal polyposis not amenable to endoscopic management	2	21	II	Present	"Large"	Major	None	Pancreaticoduodenectomy	Duodenal	Unavailable	Moved out of area. Developed duodenal cancer 5 years after discharge. Developed metastatic disease 2 years postoperatively
12	Severe duodenal polyposis not amenable to endoscopic management	3	21	III	Unknown	Unknown	Unknown	None	Laparotomy	-	-	Attempted pancreaticoduodenectomy abandoned due to extensive desmoid disease

Transient EUS finding defined as present in a previous EUS procedure but resolved in the last preoperative EUS.

— EUS, endoscopic ultrasound; HGD, high-grade dysplasia; LGD, low-grade dysplasia; MGD, moderate-grade dysplasia; PD, pancreatic duct; TVA, tubulovillous adenoma.

In the three patients with ampullary cancer:

- ▶ Patient 1's index EUS revealed Spigelman stage III disease, a 3 cm ampullary polyp and no positive ultrasound features. Biopsy showed TVA with low-grade dysplasia (Kashiwagi major disease). They underwent annual EUS over 7 years; the third EUS showed subcentimetre lymphadenopathy and the sixth EUS showed a dilated CBD (10 mm) but both findings resolved on subsequent procedures. The polyp increased in size to 3.5 cm on the fifth EUS and 4 cm on the final (eighth) EUS. All biopsies from first to penultimate EUS showed TVA with low-grade dysplasia but the last biopsy diagnosed ampullary adenocarcinoma. On the final EUS there were no positive ultrasound findings. Pancreaticoduodenectomy was attempted but abandoned due to extensive desmoid disease.
- ▶ Patient 2's index EUS revealed Spigelman stage III disease and a 15 mm ampullary polyp with PD dilatation (5 mm). Biopsy showed TVA with low-grade dysplasia (Kashiwagi major disease). Repeat EUS 6 months later showed similar findings, although the PD had normalised (3.5 mm). As a CT scan had also shown a mildly dilated PD, pancreaticoduodenectomy was performed, revealing a T3N1 ampullary cancer. The patient developed metastatic disease 2 years postoperatively.
- ▶ Patient 3's index EUS showed Spigelman stage III disease, a 1 cm ampullary polyp and no positive ultrasound findings. Biopsy showed TVA with low-grade dysplasia (Kashiwagi major disease). They underwent annual EUS over 7 years. The fourth EUS showed CBD dilatation (9 mm) that resolved on the subsequent EUS. The polyp increased in size to 3 cm on the fourth EUS and 5 cm on the final (eighth) EUS. All biopsies showed TVA with low-grade dysplasia. However, the final EUS identified liver metastases and CBD dilatation. Although ampullary biopsy showed TVA with low-grade dysplasia, percutaneous liver biopsy confirmed metastatic ampullary adenocarcinoma.

In the cohort having two or more EUS procedures (n=39), 33 (85%) had data available to estimate the risk of ampullary disease progression and ampullary cancer. In patients with normal ampullae on index EUS (n=8), five developed macroscopic ampullary disease (median follow-up 4 years). These all progressed from normal ampullae to Kashiwagi major disease in a single EUS, rather than developing Kashiwagi minor disease as an interim state between normal and major disease. The risk of ampullary malignancy in Kashiwagi major disease was 10.3% over a median follow-up of 3.2 years.

### Predictive value of EUS findings

After excluding the two patients who developed duodenal cancer several years after discharge, the sensitivity, specificity, positive predictive value (PPV), negative predictive value (NPV) and diagnostic accuracy of ultrasound and endoscopic findings for the remaining four cancers (three ampullary, one duodenal) were calculated (table 3).

**Table 3** Sensitivity, specificity, PPV, NPV and accuracy of individual EUS and endoscopic findings

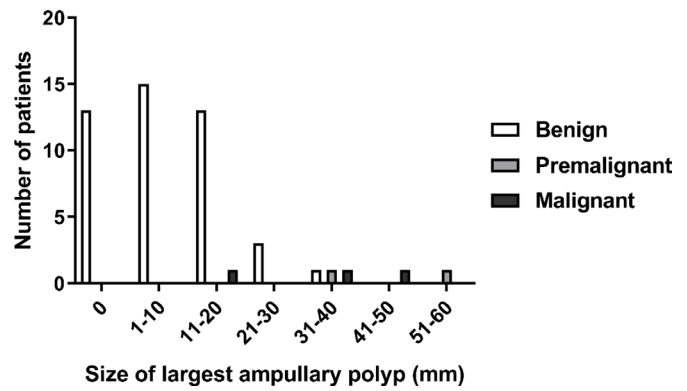
Statistical data	Dilated pancreatic duct (PD)	Dilated common bile duct (CBD)	Muscularis propria invasion	Lymphadenopathy	Ulceration of dominant polyp	Ampullary polyp size increase >1 cm*	Ampullary polyp size >3 cm in size†
True positive	0	1	0	0	1	2	2
False negative	4	3	4	4	3	1	1
False positive	13	15	0	4	1	2	3
True negative	171	169	184	180	183	32	45
Sensitivity (%) (95% CI)	0.0 (0.0 to 60.2)	25.0 (0.6 to 80.6)	0.0 (0.0 to 60.2)	0.0 (0.0 to 60.2)	25.0 (0.6 to 80.6)	66.7 (9.4 to 99.2)	66.7 (9.4 to 99.2)
Specificity (%) (95% CI)	92.9 (88.2 to 96.2)	91.9 (86.9 to 95.4)	100.0 (98.0 to 100.0)	97.8 (94.5 to 99.4)	99.5 (97.0 to 100.0)	94.1 (80.32 to 99.3)	93.8 (82.8 to 98.7)
PPV (%) (95% CI)	N/A‡	6.3 (1.1 to 28.0)	N/A‡	N/A‡	50.0 (7.0 to 93.0)	50.0 (17.3 to 82.7)	40.0 (14.7 to 72.1)
NPV (%) (95% CI)	97.7 (97.6 to 97.8)	98.3 (97.0 to 99.0)	97.9 (97.9 to 97.9)	97.8 (97.8 to 97.8)	98.4 (97.2 to 99.1)	97.0 (86.6 to 99.4)	97.8 (90.1 to 99.6)
Accuracy (%)	91.0 (85.9 to 94.6)	90.4 (85.3 to 94.2)	97.9 (94.6 to 99.4)	95.7 (91.8 to 98.2)	97.9 (94.6 to 99.4)	91.9 (78.1 to 98.3)	92.2 (81.1 to 97.8)

\*Reported for the 37 patients with available data (serial ampullary polyp size measurements) as a risk for developing ampullary adenocarcinoma.

†Reported for the 50 patients with available data (presence/absence of ampullary polyposis and polyp size if ampullary disease present) as a risk for developing ampullary adenocarcinoma.

‡Unable to calculate as no EUS demonstrated a true positive.

CBD, common bile duct; EUS, endoscopic ultrasound; N/A, not available; NPV, negative predictive value; PD, pancreatic duct; PPV, positive predictive value.



**Figure 2** The reported size of the largest ampullary polyp in patients with benign (low-grade dysplasia), premalignant (high-grade dysplasia) and malignant ampullary disease. According to endoscopic ultrasound biopsy±surgical histology, if available.

Although the absence of suspicious ultrasound findings was highly specific for benign disease, their absence in cancer cases generated low sensitivities. The only ultrasound finding detected prior to a cancer diagnosis was CBD dilatation in a patient with ampullary cancer.

Visual findings showed variable predictive ability. Polyp ulceration, while only present in one case of duodenal cancer, had superior specificity to PD and CBD dilatation due to the low number of false positives. Having an ampullary polyp size increase of >1 cm resulted in a sensitivity, specificity, PPV, NPV and diagnostic accuracy of 66.7%, 94.1%, 50.0%, 97.0% and 91.9%, respectively. Patients with ampullary cancer were more likely to have larger ampullary polyps (35 vs 17 mm,  $p=0.019$ ). Using a cut-off of >3 cm to determine a positive result for malignancy resulted in a sensitivity, specificity, PPV, NPV and diagnostic accuracy of 66.7%, 93.8%, 40.0%, 97.8% and 92.2%, respectively. If positive cases also included those with high-grade dysplasia, this increased the sensitivity, specificity, PPV, NPV and diagnostic accuracy to 80.0%, 97.8%, 80.0%, 97.8% and 96.1%, respectively (figure 2).

## DISCUSSION

It has been suggested that EUS may provide additional information compared with duodenoscopy in the assessment of advanced duodenal and ampullary adenomatosis that could address some of the limitations of standard endoscopic surveillance.<sup>9</sup> As EUS can provide more detailed assessment of polyps (eg, ultrasound-guided cross-sectional measurement and identification of deep polyp extension), it may be superior to duodenoscopy for identifying high-risk polyps requiring intervention. Gluck *et al* reported on the utility of EUS in 28 FAP patients with ampullary adenomas.<sup>13</sup> On duodenoscopy, patients' polyps were classified as non-advanced or advanced (defined as >1 cm, villous architecture or high-grade dysplasia). EUS was then performed to assess resectability. If patients had advanced adenomas confirmed then ampullectomy or polypectomy was





performed, whereas non-advanced adenomas remained under surveillance. EUS up-staged nine patients (due to improved size estimation) and down-staged one patient, altering the treatment course in 36% of patients.

However, some series have not found EUS to be beneficial. Azih *et al* compared the preoperative EUS findings of 47 patients with benign ampullary or duodenal adenomas with their histological reports following endoscopic or surgical resection.<sup>18</sup> Muscularis involvement was found to have a moderate specificity (87.8%) but a low sensitivity (33%). Cahen *et al* compared the preoperative EUS findings of 18 patients with ampullary adenomas or adenocarcinomas with their postoperative histology; EUS did not identify malignant invasion in the four patients with adenocarcinoma.<sup>19</sup> It was also frequently falsely positive for malignant invasion (n=5) and lymphadenopathy (n=5) in patients with benign disease.

Our study highlights some of the limitations of current staging systems and surveillance practice. The cohort showed an equal risk of developing duodenal and ampullary cancer once advanced (Spigelman IV or Kashiwagi major) disease had occurred (10.5% and 10.3% risk over 3.2 years of follow-up, respectively). While this is likely to be an overestimate as many patients will have had advanced disease prior to index EUS, it highlights the importance of assessment of duodenal and ampullary polyposis using site-specific staging systems. The Spigelman classification underestimated disease severity in patients with ampullary polyposis (two cases of ampullary cancer had Spigelman stage III disease on their last EUS prior to developing malignancy) and the Kashiwagi classification was too sensitive (97% of patients with ampullary polyposis had Kashiwagi major disease). This is because unlike the system used by Gluck *et al*, Kashiwagi classifies tubulovillous as well as villous architecture as major disease. Most biopsies in our cohort showed tubulovillous architecture (85% of patients on index EUS, rising to 91% by their last EUS). Of note, the five patients who developed ampullary polyposis during surveillance all went from macroscopically normal ampullae to Kashiwagi major disease in a single EUS, suggesting that the use of tubulovillous architecture as a criterion for major disease is too sensitive.

Although one-third of patients showed positive ultrasound findings during surveillance, these correlated poorly with malignancy. The only ultrasound finding detected on the last EUS prior to developing a malignancy was CBD dilatation in a patient with ampullary cancer. Muscularis propria invasion was not identified in any procedures, including the EUS that identified liver metastases from ampullary cancer. The absence of PD and CBD dilatation and lymphadenopathy in cases of malignancy and their occurrence in benign disease made these findings poor predictors of malignancy. In contrast, the endoscopic findings of ulceration of a dominant polyp, ampullary polyp size increase of >1 cm and ampullary polyp size >3 cm provided higher PPVs while maintaining similar NPVs to ultrasound findings.

While the above EUS findings have been considered in the context of established malignancy, the goal is to perform surgery in patients with high-grade dysplasia. Three patients were operated on at the ideal time (TVA with moderate-grade/high-grade dysplasia). Highlighting the importance of resection before cancer development is the observation that three of the four patients with cancer who underwent resection developed metastatic disease postoperatively. Despite the theory that EUS could provide more accurate biopsy specimens, thereby reducing the number of cancers diagnosed from surgical histology, two of the three cancers operated on under our care were diagnosed postoperatively.

Acknowledging these limitations, the best findings to select patients for surgery were ulceration overlying a dominant polyp (either cancer), ampullary polyp size >3 cm (ampullary cancer) and ampullary polyp size increase of >1 cm (ampullary cancer). A cut-off of >3 cm identified all cases of ampullary high-grade dysplasia and two of the three cases of ampullary cancer, while only including one false positive (figure 2). This provided a sensitivity of 80% and specificity of 97.8%, far surpassing any other endoscopic or ultrasound finding.

There are several study limitations to be acknowledged when interpreting these findings. FAP is a relatively rare disease which limited the size of the cohort. The retrospective design meant that some data were inevitably absent; ultrasound and endoscopic findings not mentioned on EUS reports were presumed to be absent, but this cannot be confirmed. Kashiwagi status was also determined in hindsight as the classification was not calculated after EUS procedures. As this was a retrospective study, there was no set EUS protocol and so biopsy sampling and polyp measurement techniques were not standardised. A prospective study with defined EUS protocol, documentation of absent as well as positive findings and calculation of scoring systems at the time of histology review would provide more robust data.

Of note, endoscopic ampullectomy was not practised in the EUS surveillance programme. Many of the cohorts were referred due to significant ampullary polyposis rather than duodenal disease, which explains the low number of patients with Spigelman stage IV disease on their index EUS. Endoscopic ampullectomy may provide an alternative to surgery for patients with major ampullary disease but relative sparing of the duodenum. A prospective trial randomising this subgroup of patients between endoscopic ampullectomy and surgery would be worthwhile to determine best practice.

In conclusion, our study suggests that EUS provides little benefit over duodenoscopy in the identification of high-risk polyps in FAP patients. Ultrasound findings were poor predictors of malignancy and biopsies failed to prevent postoperative cancer diagnoses. The best predictors of malignancy (polyp ulceration, ampullary polyp size >3 cm and ampullary polyp size increase >1 cm) are all endoscopic findings and can be identified using duodenoscopy. An ampullary polyp >3 cm could be



regarded as a relative indication for surgery, regardless of the biopsy result.

**Contributors** SPP was responsible for the conception of the research and PLZL, SPP, SKC and AL were responsible for research design. Data acquisition was performed by PLZL, GG, JPT and AL. Analysis and interpretation of the data were performed by PLZL, JPT, JS, AS, GJJ, SKC, AL and SPP. The initial draft manuscript was written by PLZL and further drafts conducted by GG, JPT, JS, AS, GJJ, SKC, AL and SPP. SPP is responsible for the overall content as guarantor.

**Funding** PLZL's postgraduate studies are part-funded by the Limoges Charitable Trust (charity no: 1016178). SPP is supported by the National Institute for Health Research University College London Hospitals Biomedical Research Centre.

**Competing interests** None declared.

**Patient consent for publication** Not required.

**Ethics approval** Ethical approval was not required. This retrospective analysis was conducted using existing data that were collected as part of routine patient care. No interventions were performed and no patients were contacted or had any change in their care as a result of this research being conducted.

**Provenance and peer review** Not commissioned; externally peer reviewed.

**Data availability statement** Data are available on reasonable request.

**Open access** This is an open access article distributed in accordance with the Creative Commons Attribution Non Commercial (CC BY-NC 4.0) license, which permits others to distribute, remix, adapt, build upon this work non-commercially, and license their derivative works on different terms, provided the original work is properly cited, appropriate credit is given, any changes made indicated, and the use is non-commercial. See: <http://creativecommons.org/licenses/by-nc/4.0/>.

#### ORCID iD

Stephen P Pereira <http://orcid.org/0000-0003-0821-1809>

#### REFERENCES

- Jaganmohan S, Lynch PM, Raju RP, *et al*. Endoscopic management of duodenal adenomas in familial adenomatous Polyposis—A single-center experience. *Dig Dis Sci* 2012;57:732–7.
- Bülow S, Christensen IJ, Højen H, *et al*. Duodenal surveillance improves the prognosis after duodenal cancer in familial adenomatous polyposis. *Colorectal Dis* 2012;14:947–52.
- Hirota WK, Zuckerman MJ, Adler DG, *et al*. ASGE guideline: the role of endoscopy in the surveillance of premalignant conditions of the upper Gi tract. *Gastrointest Endosc* 2006;63:570–80.
- Latchford A, Saunders B. Duodenal adenomas in familial adenomatous polyposis. In: Rodriguez-Bigas M, Cutait R, Lynch P, eds. *Hereditary colorectal cancer*. New York: Springer, 2010.
- Spigelman AD, Talbot IC, Penna C, *et al*. Evidence for adenoma-carcinoma sequence in the duodenum of patients with familial adenomatous polyposis. The Leeds Castle polyposis group (upper gastrointestinal Committee). *J Clin Pathol* 1994;47:709–10.
- Balmaña J, Balaguer F, Cervantes A, *et al*. Familial risk-colorectal cancer: ESMO clinical practice guidelines. *Ann Oncol* 2013;24(suppl 6):vi73–80.
- Syngal S, Brand RE, Church JM, *et al*. Acg clinical guideline: genetic testing and management of hereditary gastrointestinal cancer syndromes. *Am J Gastroenterol* 2015;110:223–62.
- Latchford AR, Neale KF, Spigelman AD, *et al*. Features of duodenal cancer in patients with familial adenomatous polyposis. *Clin Gastroenterol Hepatol* 2009;7:659–63.
- van Heumen BWH, Nieuwenhuis MH, van Goor H, *et al*. Surgical management for advanced duodenal adenomatosis and duodenal cancer in Dutch patients with familial adenomatous polyposis: a nationwide retrospective cohort study. *Surgery* 2012;151:681–90.
- Spigelman A, Talbot IC, Williams CB, *et al*. Upper gastrointestinal cancer in patients with familial adenomatous polyposis. *The Lancet* 1989;334:783–5.
- Saurin J-C, Gutknecht C, Napoleon B, *et al*. Surveillance of duodenal adenomas in familial adenomatous polyposis reveals high cumulative risk of advanced disease. *J Clin Oncol* 2004;22:493–8.
- Cordero-Fernández C, Garzón-Benavides M, Pizarro-Moreno A, *et al*. Gastroduodenal involvement in patients with familial adenomatous polyposis. prospective study of the nature and evolution of polyps: evaluation of the treatment and surveillance methods applied. *Eur J Gastroenterol Hepatol* 2009;21:1161–7.
- Gluck N, Strul H, Rozner G, *et al*. Endoscopy and EUS are key for effective surveillance and management of duodenal adenomas in familial adenomatous polyposis. *Gastrointest Endosc* 2015;81:960–6.
- Skipworth JRA, Morkane C, Raptis DA, *et al*. Pancreaticoduodenectomy for advanced duodenal and ampullary adenomatosis in familial adenomatous polyposis. *HPB* 2011;13:342–9.
- Rodriguez S, Faigal D. EUS of the stomach and duodenum. In: Gress F, Savides T, eds. *Endoscopic ultrasonography*. Oxford: Wiley Blackwell, 2016.
- Thiruvengadam SS, Lopez R, O'Malley M, *et al*. Spigelman stage IV duodenal polyposis does not precede most duodenal cancer cases in patients with familial adenomatous polyposis. *Gastrointest Endosc* 2019;89:345–54.
- Kashiwagi H, Spigelman AD, Debinski HS, *et al*. Surveillance of ampullary adenomas in familial adenomatous polyposis. *The Lancet* 1994;344.
- Azih LC, Broussard BL, Phadnis MA, *et al*. Endoscopic ultrasound evaluation in the surgical treatment of duodenal and peri-ampullary adenomas. *World J Gastroenterol* 2013;19:511–5.
- Cahen DL, Fockens P, de Wit LT, *et al*. Local resection or pancreaticoduodenectomy for villous adenoma of the ampulla of Vater diagnosed before operation. *Br J Surg* 1997;84:948–51.