

[CASE REPORT]

First Case Report of Possible *Sarcocystis truncata*-induced Food Poisoning in Venison

Takayuki Ota¹, Yoshio Nakano¹, Tsuyoshi Mizuno¹, Ayako Shiozaki¹, Yoshikazu Hori¹, Kazuki Yamanishi¹, Kana Hayakawa¹, Takahiro Hayakawa¹, Tokuzo Fujimoto¹, Chiaki Nakamoto², Kei Maejima³, Yasuhiko Wada³, Fumio Terasoma⁴ and Takahiro Ohnishi⁵

Abstract:

Along with the increase in consumption of raw animal meat, the prevalence of food poisoning is increasing. A 67-year-old Japanese man had eaten raw venison 4 hours prior to the beginning of vomiting. Many white cysts were discovered in the venison, with numerous bradyzoites being detected after the cysts were punctured. The presence of the *Sarcocystis* spp. 18S rRNA gene was detected by polymerase chain reaction, and *Sarcocystis truncata* was isolated from the venison. *Sarcocystis truncata* has not previously been identified in sika deer (*Cervus nippon*) in Japan. This is the first report of possible *Sarcocystis truncata*-induced food poisoning following consumption of venison.

Key words: *Sarcocystis truncata*, food poisoning, venison

(Intern Med 58: 2727-2730, 2019)

(DOI: 10.2169/internalmedicine.2817-19)

Introduction

The habit of consuming raw animal meat is common in some countries. As this practice increases, the prevalence of food poisoning or paragonimiasis is also increasing. With recent increases in the population of sika deer (*Cervus nippon*) (1) and the increasing popularity of wild game cuisine, the incidence of food poisoning or paragonimiasis following ingestion of raw venison has been increasing in Japan. A variety of zoonotic pathogens may be found in wild game meat, including venison (2). *Sarcocystis* is one such pathogen, living as a parasite in the muscles and digestive tracts of domestic animals (3).

Aoki et al. isolated *S. sybillensis* and *S. wapiti* from venison that had caused food poisoning and revealed by immunohistochemical staining that both had a protein that reacted with an antibody against a 15-kDa protein from *S. fay-eri* (4). It is widely known that *Sarcocystis* spp. are a causative pathogen of food poisoning from horse meat. However, *Sarcocystis* infection of venison has rarely been reported.

This is the first report describing a case of food poisoning possibly caused by *S. truncata* in venison.

Case Report

A 67-year-old Japanese man, suffering from abdominal pain, vomiting, watery diarrhea, and fever, visited a hospital by ambulance. He had experienced no episodes of cough, sputum, or trauma in the immediate past, and his symptoms had occurred suddenly an hour before he presented to the hospital. The patient had no history of operation. Despite suffering from hepatitis C virus infection, he had never been hospitalized for hepatic diseases. He lived in a rural area surrounded by forests and had a habit of consuming 700 mL of beer a day.

The patient had eaten raw venison 4 hours before the start of vomiting. The deer had been hunted 8 hours prior to consumption and was stored at room temperature. Upon admission, the patient was febrile with a temperature of 37.3°C, blood pressure of 108/83 mmHg, and a pulse rate of 70/min. Vomiting and watery diarrhea continued in the emergency

¹Department of Internal Medicine, Kinan Hospital, Japan, ²Nursing, Kinan Hospital, Japan, ³Tanabe Public Health Center, Japan, ⁴Wakayama Prefectural Research Center of Environment and Public Health, Japan and ⁵National Institute of Health Science, Japan

Received: February 12, 2019; Accepted: March 12, 2019; Advance Publication by J-STAGE: May 22, 2019

Correspondence to Dr. Takayuki Ota, FZG05232@nifty.ne.jp

room. The results of a physical examination were normal, except for a remarkable increase in intestinal peristaltic sounds. The laboratory examination results are shown in Table. The serum levels of creatinine, urea acid, and total protein were found to be elevated, whereas the serum sodium

level was decreased.

The stool culture was negative, with no enteric pathogens, ova, or parasites detected. *Shigella* and other enteritis pathogens were also absent. The differential diagnosis of *Salmonella*, *Escherichia coli*, hepatitis E virus, *Shigella*, *Enterobacteriaceae*, *Leptospira*, *Listeria*, and *Campylobacter* was considered. However, with the exception of *Escherichia coli*, infection symptoms from these pathogens would be expected to present ≥ 6 hours after infection. Besides this patient, two other people who had eaten the same venison displayed identical symptoms, and food poisoning was diagnosed in both cases. Considering the possibility of *Sarcocystis* infection, we asked the public health center to examine the venison for pathogens.

An examination by stereoscopic microscopy revealed the presence of white cysts in the venison muscle tissue (Fig. 1A). The cysts were 1 to 2 mm long and approximately 0.1 mm wide (Fig. 1B and C). Many bradyzoites were detected after puncturing the cysts (Fig. 2). The presence of the *Sarcocystis* spp. 18S rRNA gene was detected by polymerase chain reaction, and *Sarcocystis truncata* was isolated from the venison. We extracted proteins from the cysts isolated from the venison and determined their amino acid sequences, identifying a toxic 15-kDa protein (Fig. 3). No cysts were detected in the venison liver tissue.

No antibiotics were administered. Sufficient infusion was performed. On day 3, the patient improved clinically and became afebrile. He was therefore discharged.

Table. Laboratory Data on Admission.

Hematological analysis		Biochemistry	
WBC	8,700 / μ L	AST	54 U/L
Neutro	78.4 %	ALT	31 IU/L
Lym	17.2 %	γ -GTP	41 IU/L
Eosino	0.3 %	TP	8.2 g/dL
Mono	3.9 %	Alb	4.4 g/dL
Baso	0.2 %	LDH	276 IU/L
RBC	465 $\times 10^4$ / μ L	ALP	305 IU/L
Hb	14.0 g/dL	CK	161 IU/L
Ht	42.3 %	CHE	185 IU/L
PLT	18.3 $\times 10^4$ / μ L	TB	0.6 mg/dL
		CRP	0.05 mg/dL
Immunology		PG	114 mg/dL
HBs-Antigen	negative	Cr	1.23 mg/dL
HBs-Antibody	neagtive	BUN	19.7 mg/dL
HCV-Antibody	positive	UA	10.7 mg/dL
		Na	142 mEq/L
		K	3.3 mEq/L
		Cl	104 mEq/L

Neutro: neutrocyte, Lym: lymphocyte, Eosino: eosinocyte, Mono: monocyte, RBC: red blood cell, Ht: hematocrit, PLT: platelet, HB: hepatitis B virus, HCV: hepatitis C virus, AST: aspartate transaminase, ALT: alanine transaminase, γ -GTP: γ -glutamyl transpeptidase, TP: total protein, Alb: albumin, LDH: lactate dehydrogenase, ALP: alkaline phosphatase, CK: creatine kinase, CHE: cholinesterase, TB: total bilirubin, CRP: C-reactive protein, PG: plasma glucose, Cr: creatinine, BUN: blood urea nitrogen, UA: uric acid, Na: Natrium, K: Kalium, Cl: chlorine

Discussion

Sarcocystis is a zoonotic pathogen that lives as a parasite in the muscles and digestive tracts of domestic animals (3). Carnivorous animals act as final hosts for these parasites and excrete *Sarcocystis* sporocysts in their feces. In herbivorous

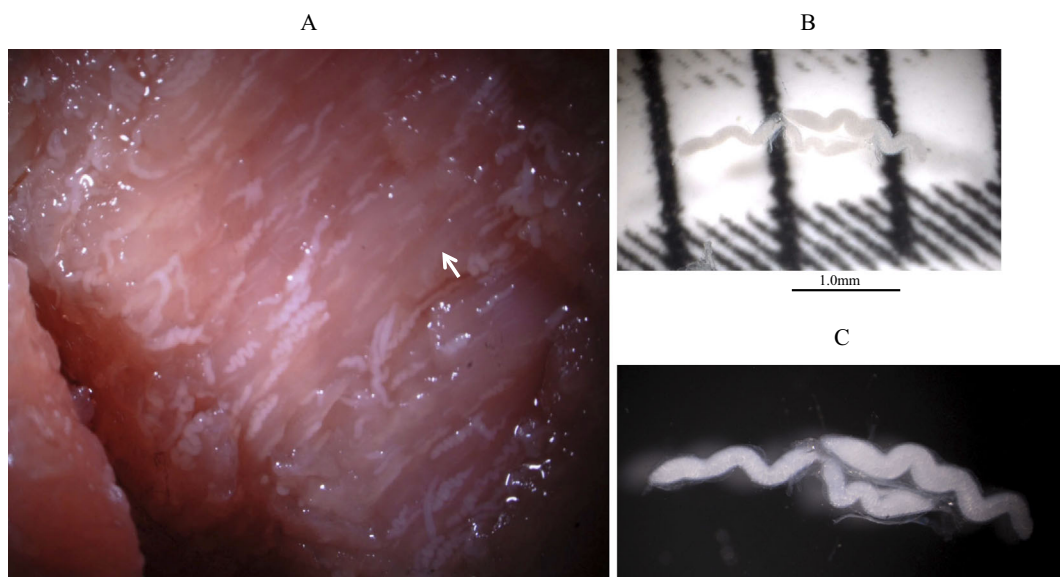


Figure 1. *Sarcocystis truncata* in venison muscle tissue (A), cysts of *Sarcocystis truncata* isolated from the venison causing food poisoning (B, C).

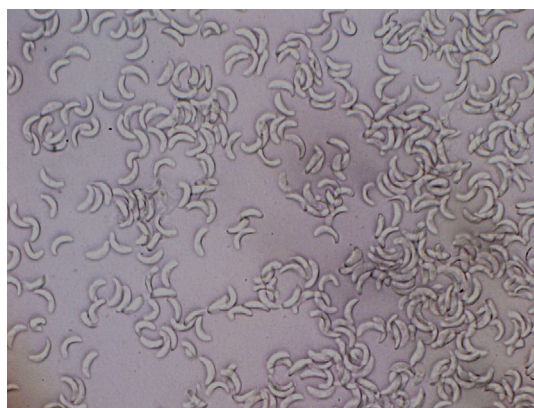


Figure 2. Bradyzoites of *Sarcocystis truncata* isolated from the venison causing food poisoning.

animals, which are its intermediate hosts, *Sarcocystis* species are present within cysts in the musculature, containing proliferating bradyzoites.

Many species of *Sarcocystis* have already been identified in other animals, including *S. cruzi*, *S. hirsuta*, and *S. bovi-hominis* in cattle; *S. miescheriana*, *S. porcifelis*, and *S. suihominis* in pigs; and *S. tenella* and *S. mihoensis* in sheep (3, 5-10). Among these, *S. bovi-hominis* and *S. suihominis* are known to be transmitted to humans, which are their final host (11), and cause a type of intestinal sarcocystosis after infection (12).

Infection with *Sarcocystis* in humans can result in a type of intestinal sarcocystosis (12). After eating raw beef containing the *S. hominis* cysts, patients in Spain experienced nausea, vomiting, abdominal discomfort, abdominal pain, and frequent diarrhea. Sporocysts of *S. hominis* were detected in a specimen of the patients' diarrheal feces, confirming the diagnosis (13).

In the present case, the patient developed symptoms within 4 hours of ingestion, with recovery after 24 hours. Besides this patient, two people who had eaten the same venison showed similar symptoms. Given the duration, rapidity of onset, and clinical symptoms, we suspected food poisoning. However, multiple stool cultures on enriched and selective media gave negative results.

Recently, *S. fayeri* in horses (13) and *Sarcocystis* spp. in deer (4) have been reported as new food poisoning agents that induce gastrointestinal symptoms, such as nausea, vomiting, and diarrhea, within 24 hours of infection, similar to this case. We therefore suspected the food poisoning to have been caused by *Sarcocystis* spp. Using polymerase chain reaction, the presence of the *Sarcocystis* spp. 18S rRNA gene was detected. Furthermore, *Sarcocystis truncata* was isolated from the venison.

To date, *S. sybillensis*, *S. wapiti*, and *S. hofmanni* have been identified in Japanese sika deer (*C. nippon*) (4, 14). *S. truncata* has been identified in white-tailed sea eagle (15) and red deer (*C. elaphus*) in Norway (16) but never in sika deer (*C. nippon*) in Japan. In 2018, *S. truncata* was identified in sika deer farmed in Lithuania (17). It is therefore un-

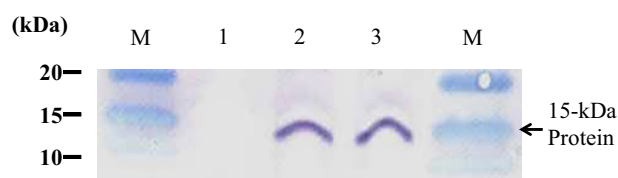


Figure 3. Immunoblotting pattern of the 15-kDa protein in *Sarcocystis* spp. M: Molecular weight marker, 1: control (uninfected horse meat), 2: horse meat infected with *Sarcocystis*, 3: venison infected with *Sarcocystis truncata* (our case).

surprising that *S. truncata* would be found in these animals in Japan.

Since 1969, the toxicity of *Sarcocystis* has been studied experimentally. Rabbits injected with *Sarcocystis* cysts developed rapid respiration, depression, and paralysis and eventually died (18). The protein extracts of *S. gigantea* are toxic to rats and mice (19, 20). A toxic protein fraction has also been isolated from *S. cruzi* cysts in beef (21). This protein had a molecular mass of approximately 15-kDa; however, precise studies on this toxic protein have not been performed.

A related 15-kDa protein produced by *Sarcocystis* spp. present in horsemeat evoked enteropathogenic changes in an animal model (22). Kamata et al. found that, following intravenous administration, a similar protein from *S. fayeri* induced diarrhea and lethal toxicity in rabbits and that it also exhibited enterotoxicity in an ileal loop test (13). This toxin showed homology with the actin-depolymerizing factor from *Toxoplasma gondii* and *Eimeria tenella*. Irikura et al. showed that a recombinant version of the same 15-kDa protein induced enterotoxicity in a rabbit ileal loop test (23). These findings showed that the 15-kDa protein from *S. fayeri* originating from horse meat was a diarrheal toxin functioning as a food poisoning agent in humans. We suspected that one or more toxins originating from *S. truncata* are able to induce pathological changes similar to those caused by *S. cruzi* and confirmed this by isolating a toxic 15-kDa protein from a strain isolated from the patient in the present case. It is reasonable to suspect that this protein was the cause of the gastrointestinal symptoms in this patient.

The cysts of *Sarcocystis* species lose viability following rapid freezing at -20°C , heating at 70°C for 1 minutes, and in 2.0% salt for 1 day (14). Therefore, adequate freezing and heating are needed for the cooking and storage of venison in order to reduce the risk of food poisoning. The 15-kDa protein might be a useful indicator for determining the possibility of food poisoning induced by *Sarcocystis* spp. Further studies will be necessary to reveal whether or not the 15-kDa protein is responsible for the enterotoxicity induced by *Sarcocystis* detected in venison.

Some people prefer to serve their meat rare or raw, allowing consumers to inadvertently ingest live *Sarcocystis* cysts. *Sarcocystis* cysts in meat are therefore a risk factor for public health. To prevent food poisoning caused by venison, it is essential to understand how to inactivate the responsible

toxin during storage. In *S. fayeri*, this can be accomplished by freezing (22). In the present case, the cause of food poisoning was failure to treat the venison at the proper temperature.

This is the first report to describe a case of food poisoning presumably caused by *S. truncata* from venison. While examining patients suffering from venison-related food poisoning, the possibility of infection by *Sarcocystis* spp. should be kept in mind.

The authors state that they have no Conflict of Interest (COI).

Acknowledgement

The authors would like to acknowledge the significant contribution of Akiko Yamazaki (Cooperative Department of Veterinary Medicine, Faculty of Agriculture, Iwate University, Japan) in providing the 15-kDa protein antibody.

References

- Ministry of the Environment :[The population estimation of nihon deer and wild boar by statistical method] [Internet]. [cited 2018 Feb 22]. Available from: <http://www.env.go.jp/press/files/jp/26914.pdf>
- Ruiz-Fons F. A review of the current status of relevant zoonotic pathogens in wild swine (*Sus scrofa*) populations: changes modulating the risk of transmission to humans. *Transbound Emerg Dis* **64**: 68-88, 2017.
- Markus MB. *Sarcocystis* and sarcocystosis in domestic animals and man. *Adv Vet Sci Comp Med* **22**: 159-193, 1978.
- Aoki K, Ishikawa K, Hayashi K, et al. An outbreak of suspected food poisoning related to deer meat containing *Sarcocystis* cysts. *Jpn J Food Microbiol* **30**: 28-32, 2013 (in Japanese, Abstract in English).
- Ashford RW. The fox, *Vulpes vulpes*, as a final host for *Sarcocystis* of sheep. *Ann Trop Med Parasitol* **71**: 29-34, 1977.
- Dubey JP, Streitl RH, Stromberg PC, Toussant MJ. *Sarcocystis fayeri* sp. n. from the horse. *J Parasitol* **63**: 443-447, 1977.
- Fayer R, Esposito DH, Dubey JP. Human infections with *Sarcocystis* species. *Clin Microbiol Rev* **28**: 295-311, 2015.
- Saito M, Shibata Y, Kobayashi T, Kobayashi M, Kubo M, Itagaki H. Ultrastructure of the cyst wall of *Sarcocystis* species with canine final host in Japan. *J Vet Med Sci* **58**: 861-867, 1996.
- Saito M, Shibata Y, Kubo M, Itagaki H. *Sarcocystis mihoensis* n. sp. from sheep in Japan. *J Vet Med Sci* **59**: 103-106, 1997.
- Saito M, Shibata Y, Ohno A, Kubo M, Shimura K, Itagaki H. *Sarcocystis sui hominis* detected for the first time from pigs in Japan. *J Vet Med Sci* **60**: 307-309, 1998.
- Guo M, Dubey JP, Hill D, et al. Prevalence and risk factors for *Toxoplasma gondii* infection in meat animals and meat products destined for human consumption. *J Food Prot* **78**: 457-476, 2015.
- Fayer R. *Sarcocystis* spp. in human infections. *Clin Microbiol Rev* **17**: 894-902, 2004.
- Kamata Y, Saito M, Irikura D, et al. A toxin isolated from *Sarcocystis fayeri* in raw horsemeat may be responsible for food poisoning. *J Food Prot* **77**: 814-819, 2014.
- Honda M, Sawaya M, Taira K, et al. Effects of temperature, pH and curing on the viability of *Sarcocystis*, a Japanese sika deer (*Cervus Nippon centralis*) parasite, and the inactivation of their diarrheal toxin. *J Vet Med Sci* **80**: 1337-1344, 2018.
- Gjerde B, Vikøren T, Hamnes IS. Molecular identification of *Sarcocystis halioti* n. sp., *Sarcocystis lari* and *Sarcocystis truncata* in the intestine of a white-tailed sea eagle (*Haliaeetus albicilla*) in Norway. *Int J Parasitol Parasites Wildl* **7**: 1-11, 2017.
- Gjerde B. *Sarcocystis* species in red deer revisited: with a re-description of two known species as *Sarcocystis elongata* n. sp. and *Sarcocystis truncata* n. sp. based on mitochondrial *cox1* sequences. *Parasitology* **141**: 441-452, 2014.
- Rudaitytė-Lukošienė E, Prakas P, Butkauskas D, Kutkienė L, Vepštaitė-Monstavičė I, Servienė E. Morphological and molecular identification of *Sarcocystis* spp. from the sika deer (*Cervus nippon*), including two new species *Sarcocystis frondea* and *Sarcocystis nipponi*. *Parasitol Res* **117**: 1305-1315, 2018.
- Mandour AM. Studies on the toxicity of *Sarcocystis*. *J Med Microbiol* **2**: 361-363, 1969.
- Al-Hyali NS, Aljawady MA, Mohammad-Fakhri MA. The influence of some physio-chemical properties of sarcotoxin in rats. *J Anim Vet Adv* **9**: 302-305, 2010.
- Al-Hyali NS, Khalil LY, Aljawady MA. Sarcotoxin effect on leukocytic finding and phagocytic activity in mice. *J Anim Vet Adv* **8**: 2395-2398, 2009.
- Saito M, Taguchi K, Shibata Y, Kobayashi T, Shimura K, Itagaki H. Toxicity and properties of the extract from *Sarcocystis cruzi* cysts. *J Vet Med Sci* **57**: 1049-1051, 1995.
- Harada S, Furukawa M, Tokuoaka E, et al. Control of toxicity of *Sarcocystis fayeri* in horsemeat by freezing treatment and prevention of food poisoning. *Shokuhin Eiseigaku Zasshi (J Food Hyg Soc Japan)* **54**: 198-203, 2013 (in Japanese, Abstract in English).
- Irikura D, Saito M, Sugita-Konishi Y, et al. Characterization of *Sarcocystis fayeri*'s actin-depolymerizing factor as a toxin that causes diarrhea. *Genes Cells* **22**: 825-835, 2017.

The Internal Medicine is an Open Access journal distributed under the Creative Commons Attribution-NonCommercial-NoDerivatives 4.0 International License. To view the details of this license, please visit (<https://creativecommons.org/licenses/by-nc-nd/4.0/>).