

## Review Article

# ***Helicobacter pylori* Infection following Endoscopic Resection of Early Gastric Cancer**

Lan Li , and Chaohui Yu 

Department of Gastroenterology, The First Affiliated Hospital, College of Medicine, Zhejiang University, Hangzhou, China

Correspondence should be addressed to Chaohui Yu; zyyych@zju.edu.cn

Received 26 May 2019; Revised 29 July 2019; Accepted 20 August 2019; Published 16 October 2019

Academic Editor: Wen-Jun Li

Copyright © 2019 Lan Li and Chaohui Yu. This is an open access article distributed under the Creative Commons Attribution License, which permits unrestricted use, distribution, and reproduction in any medium, provided the original work is properly cited.

The role of *Helicobacter pylori* (*H. pylori*) infection in patients following endoscopic resection of early gastric cancer (EGC) remains unclear. This article presents a review of literature published in the past 15 years. *H. pylori*-mediated persistent methylation levels are associated with the development of metachronous gastric cancer. The methylation of certain specific genes can be used to identify patients with a high risk of metachronous gastric cancer even after *H. pylori* eradication. *H. pylori* eradication after endoscopic resection should be performed as early as possible for eradication success and prevention of metachronous precancerous lesions. Although whether the eradication of *H. pylori* could prevent the development of metachronous cancer after endoscopic resection is controversial, several meta-analyses concluded that *H. pylori* eradication could reduce the incidence of metachronous gastric cancer significantly. In addition, *H. pylori* eradication in gastric cancer survivors after endoscopic resection could reduce healthcare cost and save lives in a cost-effective way. Taken together, *H. pylori* eradication after endoscopic resection of EGC is recommended as prevention for metachronous precancerous lesions and metachronous gastric cancer.

## 1. Introduction

In recent years, endoscopic resection including endoscopic mucosal resection (EMR) and endoscopic submucosal dissection (ESD) has been widely used in the treatment of early gastric cancer (EGC) [1]. The risk of the development of metachronous gastric cancer in patients who underwent endoscopic resection of EGC is higher than that in gastrectomized patients. Endoscopic resection is minimally invasive and preserves the whole stomach, which could increase the risk of metachronous cancers on unresected parts of the stomach compared to surgical resection [2, 3]. *Helicobacter pylori* (*H. pylori*) is the major cause of gastric carcinogenesis, and its infection leads to chronic gastritis, atrophic gastritis, intestinal metaplasia, dysplasia, and subsequently to gastric adenocarcinoma [4, 5]. The role of *H. pylori* infection in patients following endoscopic resection of EGC remains unclear due to different results from various studies. It is still controversial whether the eradication of *H. pylori* can reduce the likelihood of metachronous gastric cancer. In the present study, we will

review the literature on the relationship between *H. pylori* infection and metachronous gastric lesion after endoscopic resection. The purpose of the present study is to explore the role of *H. pylori* infection and *H. pylori* eradication in the patients after endoscopic resection of EGC.

## 2. Prevalence of *H. pylori* Infection after Endoscopic Resection of Early Gastric Cancer

Endoscopic therapy is a minimally invasive treatment that allows the patient to preserve the entire stomach. The anatomy of the stomach has no significant change after endoscopic resection for EGC, but few studies have examined whether the microbiological profile in the stomach has changed. Prevalence of *H. pylori* infection after endoscopic resection for EGC has seldom been reported. Hwang et al. reported that *H. pylori* infection rate after endoscopic resection of EGC was significantly higher in the patients with residual tumors group than in the patients without residual tumors group [6]. Moreover,

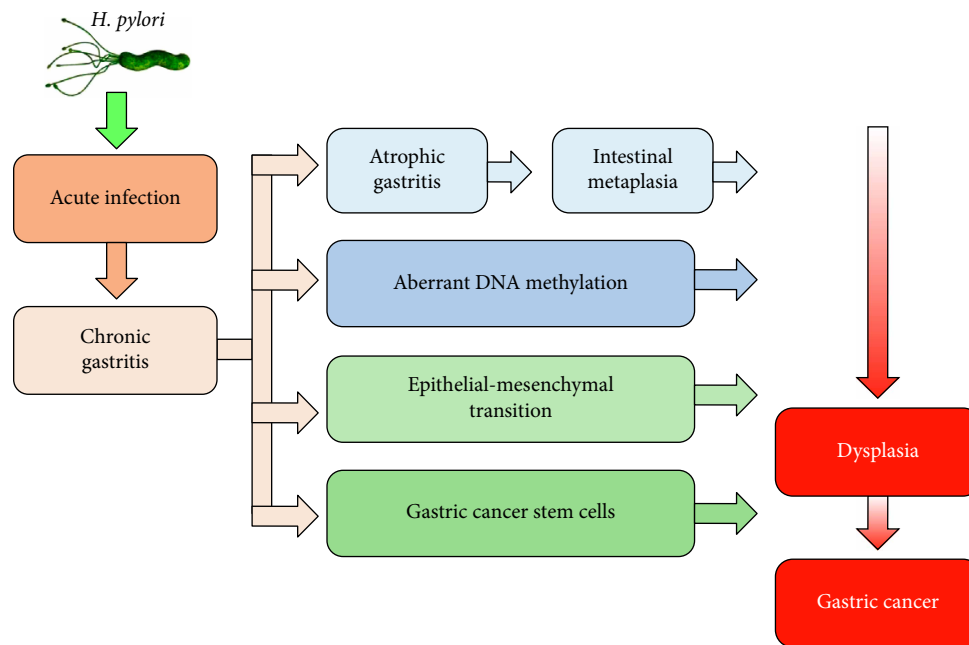


FIGURE 1: A model representing the role of *H. pylori* in the development of gastric cancer.

*H. pylori* were independent factors of the presence of residual tumor in additional gastrectomy after incomplete endoscopic resection for EGC [6]. Large-scale studies are needed to determine whether there is a difference in *H. pylori* infection rate between general population and the patients following endoscopic surgery of EGC.

### 3. Effect of *H. pylori* on Ulcers Developing after Endoscopic Resection of Early Gastric Cancer

Several studies have examined the effect of *H. pylori* eradication on ulcers developing after endoscopic resection of EGC. Song et al. suggested that early *H. pylori* eradication therapy can promote *H. pylori*-positive ESD-induced artificial ulcer healing [7]. Cheon et al. found that *H. pylori* eradication was better than PPI treatment with respect to the healing of artificial gastric ulcer after EMR for EGC [8]. It was reported that *H. pylori* infection led to decreased mucosal blood flow at the margin of EMR-induced ulcers, which indirectly supports the above report [9]. However, in one study concerning the effect of *H. pylori* infection status on post-EMR gastric ulcers by Kakushima et al. [10], the healing rate of ulcers at 8 weeks after EMR was not affected by *H. pylori* infection status. Likewise, several reports have shown that the infection status of *H. pylori* does not affect ulcer healing after ESD [10–14]. The reasons for these are as follows: Eradication therapy promotes the healing process of peptic ulcers by improving microcirculation. However, muscular contraction might be a major factor in the healing process of artificial ulcers, while improvement of microcirculation is only a secondary factor. In addition, the pathogenesis of artificial ulcers is completely mechanical rather than *H. pylori*-induced apoptosis or gastric juice-induced degradation. Further follow-up prospective studies

will help to clarify the effect of *H. pylori* on ulcers developing after endoscopic resection of EGC.

### 4. Molecular Pathogenesis of *H. pylori*-Related Metachronous Gastric Cancer

The current studies found that the mechanisms by which *H. pylori* infection might eventually lead to gastric cancer included *H. pylori*-induced atrophic gastritis and intestinal metaplasia, aberrant DNA methylation, epithelial–mesenchymal transition, and gastric cancer stem cells (Figure 1) [15]. Chronic active *H. pylori* infection leads to the recruitment of immune cells, increasing secretion of interleukin-1 $\beta$ , tumor necrosis factor- $\alpha$ , and reactive oxygen species, which together cause the activation of DNA methyltransferase 1, mediating abnormal DNA methylation in the gastric mucosa [16]. The methylation level in gastric mucosa is partially reversible by *H. pylori* eradication in a gene-specific manner [17–19], but the methylation of some molecules in stem cells can last for a long time [20]. Thus, it is likely that the methylation level after *H. pylori* eradication could reflect the epigenomic damage of stem cells [20, 21]. It was reported that the methylation of MOS and miR-124a-3 could predict the risk of metachronous gastric cancer [20, 22]. The methylation level of MOS in patients with metachronous gastric cancer was significantly higher than that in patients without metachronous gastric cancer [22]. Likewise, high miR-124a-3 methylation level was correlated with an increased risk of developing metachronous gastric cancers [20]. Therefore, *H. pylori*-mediated persistent methylation levels are associated with the development of metachronous gastric cancer. The methylation of certain specific genes can be used to identify patients with a high risk of metachronous gastric cancer even after *H. pylori* eradication.

## 5. Effect of *H. pylori* on Metachronous Precancerous Lesions after Endoscopic Resection of Early Gastric Cancer

Many studies reported the results concerning the effect of *H. pylori* on gastric atrophy and intestinal metaplasia following endoscopic resection of EGC. Choi et al. [23] and Han et al. [24] reported that the grade of atrophy on corpus was significantly lower in the *H. pylori*-eradicated group than in the persistent group during a follow-up period longer than 5 years after endoscopic treatment of EGC. Zhang et al. found that *H. pylori* infection was an independent risk factor for recurrence of gastric mucosal dysplasia after endoscopic resection [25]. Similarly, the multivariate analysis by Chon et al. showed that eradication of *H. pylori* was related to reduce incidence of subsequent gastric dysplasia [26]. Of particular significance is the observation that failure of *H. pylori* eradication occurred more frequently in metachronous patients with gastric dysplasia than in those with carcinoma [27]. In other words, eradication failure was closely related to dysplasia, but not carcinoma, in the metachronous group. Therefore, *H. pylori* infection could play a role in the development of metachronous precancerous lesions after endoscopic resection of EGC. There may be a 'point of no return,' beyond which molecular changes are irreversible and *H. pylori* eradication could no longer prevent metachronous lesions. It is difficult to correctly define the point of no return because the molecular process cannot be determined precisely. On the basis of the above studies, *H. pylori* eradication after endoscopic resection of EGC should be performed as early as possible for the prevention of metachronous precancerous lesions.

## 6. Effect of *H. pylori* Eradication on the Development of Metachronous Gastric Cancer

Although *H. pylori* is a well-known risk factor and plays an important role in the development of gastric cancer, the effect of *H. pylori* infection on the development of metachronous gastric cancer after endoscopic resection of EGC still remains unclear [28]. The mucosa adjacent to *H. pylori*-infected gastric cancer is usually accompanied by atrophy and intestinal metaplasia, which is susceptible to develop metachronous gastric cancer. Endoscopic resection preserves the gastric mucosa to the greatest extent, so the incidence of metachronous gastric cancer in the abnormal background mucosa is significantly increased [2]. Previous studies illustrated that persistent *H. pylori* infection was associated with an increased risk of subsequent gastric dysplasia or cancer after endoscopic resection of EGC, and *H. pylori* infection is an independent risk factors for metachronous gastric cancer after ESD of EGC [29–31]. However, Lim et al. showed an inverse relationship between *H. pylori* infection and metachronous gastric cancer [32]. One possible reason is that *H. pylori*-negative patients may have previously been infected with *H. pylori* and previous long-term infection might have a greater effect on the development of metachronous gastric cancer than newly developed current infection.

It is still on debate whether the eradication of *H. pylori* could prevent the development of metachronous cancer after

endoscopic resection of EGC. Several long follow-up prospective studies reported that eradication of *H. pylori* in the patients treated with endoscopic resection of gastric dysplasia or EGC could reduce the risk of metachronous cancer [23, 33, 34]. However, a 3-year prospective study by Choi et al. reported that the cumulative incidence of metachronous gastric cancer was not different between patients with or without *H. pylori* eradication [35]. Other retrospective studies showed similarly controversial conclusions [26, 27, 31, 36–40]. The reasons for this discrepancy are as follows: First, the study designs were different among the studies. Some were prospective randomized trials, and others were retrospective cohort studies. Second, the timing of the *H. pylori* eradication was not consistent. Some persons received eradication treatment immediately after endoscopic resection, and others received treatment several months after endoscopic resection. Third, the follow-up time was not consistent among the studies and most studies had a follow-up period of less than 5 years. In addition, the methods for calculations of the observation period were different among the studies. Some started from eradication of *H. pylori*, and others started from the initial ESD.

Nevertheless, several meta-analyses concluded that *H. pylori* eradication could reduce the incidence of metachronous gastric cancer significantly, therefore preventing against metachronous gastric cancer in patients who have undergone endoscopic resection [41–44]. Although it is possible to develop metachronous gastric cancer after successful eradication of *H. pylori*, *H. pylori* eradication after endoscopic resection of EGC is still recommended in the Maastricht consensus report and the Guidelines of the Japanese Gastroenterological Society [45, 46]. Further prospective studies with long-term follow-up could help clarify the effect of *H. pylori* eradication in preventing metachronous gastric cancer after endoscopic resection of EGC.

Furthermore, Park et al. clarified that *H. pylori* infection or eradication did not affect the time interval between the initial ESD and the development of metachronous gastric cancer [47], which implied that *H. pylori* eradication might not halt the progression of precancerous lesions, especially when the neoplastic change has reached a certain degree. A possible reason is that metachronous gastric lesions might have already been in the stomach at the time of ESD for EGC as tiny or invisible lesions, and therefore, the time interval to occurrence of metachronous gastric cancer might not be affected by *H. pylori* eradication in patients with undetected early cancer or slowly growing latent cancer [48].

## 7. Optimal Timing for *H. pylori* Eradication for Patients after Endoscopic Resection of Early Gastric Cancer

Few studies have explored the optimal timing to eradicate *H. pylori* after endoscopic resection of EGC. Huh et al. assessed whether the eradication of *H. pylori* at different time points after endoscopic resection affected the success rates of eradication therapy [49]. They concluded that the early treatment group ( $\leq 2$  weeks after endoscopic resection) achieved a

significantly higher eradication rate than the intermediate group (2–8 weeks) or the late group ( $\geq 8$  weeks). Multivariate analysis showed that early initiation of *H. pylori* eradication therapy was an independent significant predictor of eradication success. On the other hand, it was reported that *H. pylori* eradication in the patients who underwent ESD for EGC should be performed before the progression of gastric mucosal atrophy [36]. The presence of moderate-to-severe mucosal atrophy or intestinal metaplasia may be a ‘point of no return’ and does not appear to regress following *H. pylori* eradication [36, 50]. These results suggest that eradication of *H. pylori* as early as possible after endoscopic surgery offers the greatest chance of eradication success.

## 8. Cost-Effectiveness of *H. pylori* Eradication in Patients after Endoscopic Resection of Early Gastric Cancer

Patients after endoscopic resection of EGC are more susceptible to metachronous gastric cancer and might benefit more from *H. pylori* eradication. Shin et al. reported that the health care cost for patients after endoscopic resection of EGC was significantly lower in *H. pylori* eradication group than in no eradication group (US\$29,780 vs. US\$30,594), while mean life expectancy from eradication was significantly longer in *H. pylori* eradication group (13.60 years vs. 13.55 years) [51]. Therefore, eradication of *H. pylori* in gastric cancer survivors after endoscopic resection could reduce healthcare costs while saving lives, and these findings have favorable implication in decision making about the most appropriate treatment option after endoscopic resection of EGC. Large-scale studies are needed to clarify whether this strategy could be cost-effective in selective population with high risk of developing metachronous gastric cancer.

## 9. Conclusion

In this review, we summarized the studies addressing *H. pylori* infection after endoscopic resection of EGC. Unfortunately, prevalence of *H. pylori* infection after endoscopic resection of EGC has seldom been reported. The effect of *H. pylori* eradication on ulcers developing after endoscopic resection is still on debate.

*H. pylori*-mediated persistent methylation levels are associated with the development of metachronous gastric cancer. The methylation of certain specific genes can be used to identify patients with a high risk of metachronous gastric cancer even after *H. pylori* eradication. *H. pylori* eradication after endoscopic resection should be performed as early as possible for eradication success and prevention of metachronous precancerous lesions. Although whether the eradication of *H. pylori* could prevent the development of metachronous cancer after endoscopic resection is controversial, several meta-analyses concluded that *H. pylori* eradication could reduce the incidence of metachronous gastric cancer significantly. In addition, *H. pylori* eradication in gastric cancer survivors after endoscopic resection could reduce health care cost and save lives in a cost-effective way. Taken together,

*H. pylori* eradication after endoscopic resection of EGC is recommended as prevention for metachronous precancerous lesions and metachronous gastric cancer. A large-scale, long-term research is needed to examine the role of *H. pylori* infection and *H. pylori* eradication in the patients following endoscopic resection of EGC.

## Conflicts of Interest

The authors declare that there is no conflict of interest regarding the publication of this article.

## Acknowledgments

This work was supported by the National Natural Science Foundation of China (81400606), Zhejiang Provincial Natural Science Foundation of China (LY17H030004), and Science and Technology plan projects of Zhejiang Province (2015C33102).

## References

- [1] T. Nishizawa and N. Yahagi, “Long-term outcomes of using endoscopic submucosal dissection to treat early gastric cancer,” *Gut and Liver*, vol. 12, no. 2, pp. 119–124, 2018.
- [2] T. Gotoda, “Endoscopic resection of early gastric cancer,” *Gastric Cancer*, vol. 10, no. 1, pp. 1–11, 2007.
- [3] S. Abe, I. Oda, T. Minagawa et al., “Metachronous gastric cancer following curative endoscopic resection of early gastric cancer,” *Clinical Endoscopy*, vol. 51, no. 3, pp. 253–259, 2018.
- [4] P. Correa and J. Houghton, “Carcinogenesis of *Helicobacter pylori*,” *Gastroenterology*, vol. 133, no. 2, pp. 659–672, 2007.
- [5] K. O. Alfarouk, A. H. H. Bashir, A. N. Aljarbou et al., “The possible role of *Helicobacter pylori* in gastric cancer and its management,” *Frontiers in Oncology*, vol. 9, p. 75, 2019.
- [6] J. J. Hwang, D. H. Lee, H. Yoon, C. M. Shin, Y. S. Park, and N. Kim, “Clinicopathological characteristics of patients who underwent additional gastrectomy after incomplete endoscopic resection for early gastric cancer,” *Medicine (Baltimore)*, vol. 96, no. 7, p. e6172, 2017.
- [7] W. C. Song, X. F. Wang, W. W. Lv, X. Y. Xu, and M. Tian, “The effect of early *Helicobacter pylori* eradication on the healing of ESD-induced artificial ulcers: a retrospective study,” *Medicine (Baltimore)*, vol. 98, no. 22, p. e15807, 2019.
- [8] J. H. Cheon, J. H. Kim, S. K. Lee, T. I. Kim, W. H. Kim, and Y. C. Lee, “*Helicobacter pylori* eradication therapy may facilitate gastric ulcer healing after endoscopic mucosal resection: a prospective randomized study,” *Helicobacter*, vol. 13, no. 6, pp. 564–571, 2008.
- [9] K. Adachi, H. Suetsugu, N. Moriyama et al., “Influence of *Helicobacter pylori* infection and cetraxate on gastric mucosal blood flow during healing of endoscopic mucosal resection-induced ulcers,” *Journal of Gastroenterology and Hepatology*, vol. 16, no. 11, pp. 1211–1216, 2001.
- [10] N. Kakushima, M. Fujishiro, N. Yahagi, S. Kodashima, M. Nakamura, and M. Omata, “*Helicobacter pylori* status and the extent of gastric atrophy do not affect ulcer healing after endoscopic submucosal dissection,” *Journal of Gastroenterology and Hepatology*, vol. 21, no. 10, pp. 1586–1589, 2006.

- [11] Y. Yoshizawa, M. Sugimoto, Y. Sato et al., "Factors associated with healing of artificial ulcer after endoscopic submucosal dissection with reference to *Helicobacter pylori* infection, CYP2C19 genotype, and tumor location: multicenter randomized trial," *Digestive Endoscopy*, vol. 28, no. 2, pp. 162–172, 2016.
- [12] S. G. Kim, H. J. Song, I. J. Choi et al., "Helicobacter pylori eradication on iatrogenic ulcer by endoscopic resection of gastric tumour: a prospective, randomized, placebo-controlled multi-centre trial," *Digestive and Liver Disease*, vol. 45, no. 5, pp. 385–389, 2013.
- [13] J. Wang, X. Guo, C. Ye et al., "Efficacy and safety of proton pump inhibitors (PPIs) plus rebamipide for endoscopic submucosal dissection-induced ulcers: a meta-analysis," *Internal Medicine*, vol. 53, no. 12, pp. 1243–1248, 2014.
- [14] J. H. Lim, S. G. Kim, J. Choi, J. P. Im, J. S. Kim, and H. C. Jung, "Risk factors of delayed ulcer healing after gastric endoscopic submucosal dissection," *Surgical Endoscopy*, vol. 29, no. 12, pp. 3666–3673, 2015.
- [15] N. Kim, "Chemoprevention of gastric cancer by *Helicobacter pylori* eradication and its underlying mechanism," *Journal of Gastroenterology and Hepatology*, 2019.
- [16] T. Chiba, H. Marusawa, and T. Ushijima, "Inflammation-associated cancer development in digestive organs: mechanisms and roles for genetic and epigenetic modulation," *Gastroenterology*, vol. 143, no. 3, pp. 550–563, 2012.
- [17] F. Perri, R. Cotugno, A. Piepoli et al., "Aberrant DNA methylation in non-neoplastic gastric mucosa of *H. pylori* infected patients and effect of eradication," *The American Journal of Gastroenterology*, vol. 102, no. 7, pp. 1361–1371, 2007.
- [18] T. Nakajima, S. Enomoto, S. Yamashita et al., "Persistence of a component of DNA methylation in gastric mucosae after *Helicobacter pylori* eradication," *Journal of Gastroenterology*, vol. 45, no. 1, pp. 37–44, 2010.
- [19] C. M. Shin, N. Kim, H. S. Lee et al., "Changes in aberrant DNA methylation after *Helicobacter pylori* eradication: a long-term follow-up study," *International Journal of Cancer*, vol. 133, no. 9, pp. 2034–2042, 2013.
- [20] K. Asada, T. Nakajima, T. Shimazu et al., "Demonstration of the usefulness of epigenetic cancer risk prediction by a multicentre prospective cohort study," *Gut*, vol. 64, no. 3, pp. 388–396, 2015.
- [21] M. Maeda, H. Moro, and T. Ushijima, "Mechanisms for the induction of gastric cancer by *Helicobacter pylori* infection: aberrant DNA methylation pathway," *Gastric Cancer*, vol. 20, no. S1, pp. 8–15, 2017.
- [22] H. Yoon, N. Kim, C. M. Shin et al., "Risk factors for metachronous gastric neoplasms in patients who underwent endoscopic resection of a gastric neoplasm," *Gut and Liver*, vol. 10, no. 2, pp. 228–236, 2016.
- [23] I. J. Choi, M. C. Kook, Y. I. Kim et al., "Helicobacter pylori therapy for the prevention of metachronous gastric cancer," *New England Journal of Medicine*, vol. 378, no. 12, pp. 1085–1095, 2018.
- [24] S. J. Han, S. G. Kim, J. H. Lim et al., "Long-Term Effects of *Helicobacter pylori* eradication on metachronous gastric cancer development," *Gut and Liver*, vol. 12, no. 2, pp. 133–141, 2018.
- [25] L. Zhang and H. Wang, "Prognostic analysis of gastric mucosal dysplasia after endoscopic resection: a single-center retrospective study," *Journal of BUON*, vol. 24, no. 2, pp. 679–685, 2019.
- [26] I. Chon, C. Choi, C. M. Shin, Y. S. Park, N. Kim, and D. H. Lee, "Effect of *Helicobacter pylori* eradication on subsequent dysplasia development after endoscopic resection of gastric dysplasia," *The Korean journal of gastroenterology*, vol. 61, no. 6, pp. 307–312, 2013.
- [27] D. H. Jung, J. H. Kim, Y. C. Lee et al., "Helicobacter pylori eradication reduces the metachronous recurrence of gastric neoplasms by attenuating the precancerous process," *Journal of Gastric Cancer*, vol. 15, no. 4, pp. 246–255, 2015.
- [28] R. Ami, W. Hatta, K. Iijima et al., "Factors associated with metachronous gastric cancer development after endoscopic submucosal dissection for early gastric cancer," *Journal of Clinical Gastroenterology*, vol. 51, no. 6, pp. 494–499, 2017.
- [29] C. S. Chung, H. S. Woo, J. W. Chung et al., "Risk factors for metachronous recurrence after endoscopic submucosal dissection of early gastric cancer," *Journal of Korean Medical Science*, vol. 32, no. 3, pp. 421–426, 2017.
- [30] S. Jung, C. H. Park, E. H. Kim et al., "Preventing metachronous gastric lesions after endoscopic submucosal dissection through *Helicobacter pylori* eradication," *Journal of Gastroenterology and Hepatology*, vol. 30, no. 1, pp. 75–81, 2015.
- [31] Y. H. Kwon, J. Heo, H. S. Lee, C. M. Cho, and S. W. Jeon, "Failure of *Helicobacter pylori* eradication and age are independent risk factors for recurrent neoplasia after endoscopic resection of early gastric cancer in 283 patients," *Alimentary Pharmacology & Therapeutics*, vol. 39, no. 6, pp. 609–618, 2014.
- [32] J. H. Lim, S. G. Kim, J. Choi et al., "Risk factors for synchronous or metachronous tumor development after endoscopic resection of gastric neoplasms," *Gastric Cancer*, vol. 18, no. 4, pp. 817–823, 2015.
- [33] K. Fukase, M. Kato, S. Kikuchi et al., "Effect of eradication of *Helicobacter pylori* on incidence of metachronous gastric carcinoma after endoscopic resection of early gastric cancer: an open-label, randomised controlled trial," *Lancet*, vol. 372, no. 9636, pp. 392–397, 2008.
- [34] J. M. Choi, S. G. Kim, J. Choi et al., "Effects of *Helicobacter pylori* eradication for metachronous gastric cancer prevention: a randomized controlled trial," *Gastrointestinal Endoscopy*, vol. 88, no. 3, pp. 475–485.e2, 2018.
- [35] J. Choi, S. G. Kim, H. Yoon et al., "Eradication of *Helicobacter pylori* after endoscopic resection of gastric tumors does not reduce incidence of metachronous gastric carcinoma," *Clinical Gastroenterology and Hepatology*, vol. 12, no. 5, pp. 793–800.e1, 2014.
- [36] Y. Maehata, S. Nakamura, K. Fujisawa et al., "Long-term effect of *Helicobacter pylori* eradication on the development of metachronous gastric cancer after endoscopic resection of early gastric cancer," *Gastrointestinal Endoscopy*, vol. 75, no. 1, pp. 39–46, 2012.
- [37] Y. I. Kim, I. J. Choi, M. C. Kook et al., "The association between *Helicobacter pylori* status and incidence of metachronous gastric cancer after endoscopic resection of early gastric cancer," *Helicobacter*, vol. 19, no. 3, pp. 194–201, 2014.
- [38] A. Shiotani, N. Uedo, H. Iishi et al., "Predictive factors for metachronous gastric cancer in high-risk patients after successful *Helicobacter pylori* eradication," *Digestion*, vol. 78, no. 2–3, pp. 113–119, 2008.
- [39] J. Y. Seo, D. H. Lee, Y. Cho et al., "Eradication of *Helicobacter pylori* reduces metachronous gastric cancer after endoscopic resection of early gastric cancer," *Hepatogastroenterology*, vol. 60, no. 124, pp. 776–780, 2013.
- [40] S. E. Bae, H. Y. Jung, J. Kang et al., "Effect of *Helicobacter pylori* Eradication on Metachronous Recurrence After

- Endoscopic Resection of Gastric Neoplasm,” *American Journal of Gastroenterology*, vol. 109, no. 1, pp. 60–67, 2014.
- [41] S. B. Yoon, J. M. Park, C. H. Lim, Y. K. Cho, and M.-G. Choi, “Effect of *Helicobacter pylori* eradication on metachronous gastric cancer after endoscopic resection of gastric tumors: a meta-analysis,” *Helicobacter*, vol. 19, no. 4, pp. 243–248, 2014.
- [42] D. H. Jung, J. H. Kim, H. S. Chung et al., “*Helicobacter pylori* eradication on the prevention of metachronous lesions after endoscopic resection of gastric neoplasm: a meta-analysis,” *PLoS One*, vol. 10, no. 4, p. e0124725, 2015.
- [43] S. Xiao, S. Li, L. Zhou, W. Jiang, and J. Liu, “*Helicobacter pylori* status and risks of metachronous recurrence after endoscopic resection of early gastric cancer: a systematic review and meta-analysis,” *Journal of Gastroenterology*, vol. 54, no. 3, pp. 226–237, 2019.
- [44] C. S. Bang, G. H. Baik, I. S. Shin et al., “*Helicobacter pylori* eradication for prevention of metachronous recurrence after endoscopic resection of early gastric cancer,” *Journal of Korean Medical Science*, vol. 30, no. 6, pp. 749–756, 2015.
- [45] European *Helicobacter pylori* Study Group, “Current European concepts in the management of *Helicobacter pylori* infection. The Maastricht consensus report,” *Gut*, vol. 41, no. 1, pp. 8–13, 1997.
- [46] H. Ono, K. Yao, M. Fujishiro et al., “Guidelines for endoscopic submucosal dissection and endoscopic mucosal resection for early gastric cancer,” *Digestive Endoscopy*, vol. 28, no. 1, pp. 3–15, 2016.
- [47] J. Y. Park, S. G. Kim, J. Kim et al., “Risk factors for early metachronous tumor development after endoscopic resection for early gastric cancer,” *PLoS One*, vol. 12, no. 9, p. e0185501, 2017.
- [48] “Schistosomes, liver flukes and *Helicobacter pylori*, IARC Working Group on the Evaluation of Carcinogenic Risks to Humans, Lyon, 7–14 June 1994,” *IARC Monographs on the Evaluation of Carcinogenic Risks to Humans*, vol. 61, pp. 1–241, 1994.
- [49] C. W. Huh, Y. H. Youn, D. H. Jung, J. J. Park, J.-H. Kim, and H. Park, “Early attempts to eradicate *Helicobacter pylori* after endoscopic resection of gastric neoplasm significantly improve eradication success rates,” *PLoS One*, vol. 11, no. 9, p. e0162258, 2016.
- [50] B. C.-Y. Wong, S. K. Lam, W. M. Wong et al., “*Helicobacter pylori* eradication to prevent gastric cancer in a high-risk region of China,” *JAMA*, vol. 291, no. 2, pp. 187–194, 2004.
- [51] D. W. Shin, Y. H. Yun, I. J. Choi, E. Koh, and S. M. Park, “Cost-effectiveness of eradication of *Helicobacter pylori* in gastric cancer survivors after endoscopic resection of early gastric cancer,” *Helicobacter*, vol. 14, no. 6, pp. 536–544, 2009.