




Superior Capsular Reconstruction with Fascia Lata Allograft for Irreparable Supraspinatus Tendon Tears*

Reconstrução da cápsula superior com aloenxerto de fáschia lata para roturas irreparáveis do tendão do músculo Supraespinal

Mauro Emilio Conforto Gracitelli¹ Rodrigo Alves Beraldo¹ Eduardo Angeli Malavolta¹
Jorge Henrique Assunção¹ Danilo Ricardo Okiishi de Oliveira¹ Arnaldo Amado Ferreira Neto¹

¹Institute of Orthopedics and Traumatology, Faculdade de Medicina da Universidade de São Paulo (HCFMUSP), São Paulo, SP, Brazil

Address for correspondence Mauro Emilio Conforto Gracitelli, Instituto de Ortopedia e Traumatologia, Faculdade de Medicina da Universidade de São Paulo (HCFMUSP), São Paulo, SP, Brazil (e-mail: mgracitelli@gmail.com).

Rev Bras Ortop 2019;54:591–596.

Abstract

Superior capsular reconstruction is a recently described procedure for the treatment of irreparable supraspinatus tendon tears. Graft options that have been previously described include autogenous fascia lata and decellularized dermal graft. No studies were published with the use of fascia lata allograft. The purpose of this technical note is to describe the surgical technique of superior capsular reconstruction using fascia lata allograft. The procedure is performed by arthroscopic visualization, with the patient positioned in the lateral decubitus position. The authors describe a technique based on the use of a double-pulley knot in the glenoid and greater tuberosity, facilitating the procedure and allowing the graft to be brought into the subacromial space in the definitive position, with the appropriate tension. The allografts are available from this institution's tissue bank, cryopreserved and submitted to microbiological and histopathological evaluation. Superior capsular reconstruction is a promising surgery. The technique described in the present technical note shows a viable arthroscopic alternative, with a smaller number of anchors when compared with other techniques.

Keywords

- ▶ shoulder
- ▶ rotator cuff tear
- ▶ rotator cuff arthropathy
- ▶ supraspinatus muscle

Resumo

A reconstrução da cápsula superior é um procedimento descrito recentemente para o tratamento das roturas irreparáveis do tendão do músculo supraespinal. Como opções de enxerto podemos citar o uso de fáschia lata autógena e enxerto dermal acelularizado. Nenhum estudo foi publicado com o uso de aloenxerto de fáschia lata. O objetivo da presente nota é descrever a técnica cirúrgica da reconstrução da cápsula superior

* Study developed at the Shoulder and Elbow Group, Institute of Orthopedics and Traumatology, Hospital das Clínicas, Faculdade de Medicina, Universidade de São Paulo, São Paulo, SP, Brazil. Originally Published by Elsevier Editora Ltda.



Palavras-chave

- ▶ ombro
- ▶ lesões do manguito rotador
- ▶ artropatia do manguito rotador
- ▶ músculo supraespal

com aloenxerto de fásia lata. O procedimento é feito por visão artroscópica, com o paciente posicionado em decúbito lateral. Os autores descrevem uma técnica baseada no uso do nó em dupla polia na glenoide e no tubérculo maior, que facilita o procedimento e permite que o enxerto seja levado para o espaço subacromial na posição definitiva e com a tensão adequada. Os aloenxertos usados são provenientes de banco de tecidos, onde são criopreservados e submetidos à avaliação microbiológica e histopatológica. A reconstrução da cápsula superior é uma cirurgia promissora. A técnica descrita mostra uma opção artroscópica viável, com uso de menor número de âncoras quando comparada com as demais descrições.

Introduction

Superior capsular reconstruction is a recently described procedure for the treatment of irreparable supraspinatus tendon tears.^{1,2} It aims to restore superior stability of the glenohumeral joint and, thus, improve shoulder elevation.² It is a technique applied by arthroscopic visualization, with low morbidity and risks when compared with other surgical options, such as reverse arthroplasty and muscular transfers.¹ Biomechanical and clinical studies have demonstrated the effectiveness of the procedure for functional improvement, in addition to demonstrating a high rate of healing of the graft in the humerus and glenoid.^{1,3-5} The indications of the procedure are still controversial, with better results being observed in symptomatic patients with irreparable rupture of the supraspinatus tendon, associated or not with small ruptures of the subscapular and with the presence of active lateral rotation. It is also described in cases of rotator cuff arthropathy in its early degrees.^{1,3}

As graft options, we can mention the use of the autologous fascia lata,⁵ which despite being a safe procedure has the disadvantage of adding greater morbidity to the patient. Acellularized human dermis has also been used,⁶ but it has the disadvantages of being less resistant, not being available in our environment, and significantly increasing the cost of the procedure.^{5,7}

The purpose of the present note is to describe the surgical technique of superior capsule reconstruction with conventional anchors and fascia lata allograft.

Description of the Technique**Anesthesia and Positioning**

Surgery performed under general anesthesia and brachial plexus block. The patient is positioned in lateral decubitus with the upper limb abducted at a 45° angle, and with cutaneous traction.

Portals

Traditional portals for rotator cuff repair are made, consisting of the posterior (PP), anterior (AP), and lateral (LP) portals. The AP is made 1.5 cm higher than the distal end of the coracoid and allows placement of the anterior anchor in the glenoid. The LP is made 2.5 cm lower than the

acromion. Through this portal, the graft will be inserted, with the bursectomy adjacent to the deltoid being of fundamental importance. Two more portals are made for the insertion of the anchors in the major, anterosuperior (AS) and posterosuperior (PS). The Neviasser portal (NP) is also made at the bisector between the intersection of the clavicle and the spine of the scapula. This portal allows the insertion of the posterior anchor in the glenoid and allows traction of the graft by a double pulley system. Eventually, a medial posterosuperior portal (MPSP), 3 cm medial and 1 cm inferior to the posterolateral angle of the acromion, may be necessary for insertion of the posterior anchor of the glenoid, in cases in which the NP does not allow an adequate angle of attack. For the subscapular repair, an additional anterolateral portal may be required.

We performed the procedure with three cannulas. Two traditional rigid cannulas are used in the AP and PP. A third, flexible Passport (Arthrex, Naples, FL, USA), can be used in the LP. This cannula allows the passage of the suture without interposition of soft parts between them. It will be cut and removed after the passage of all the suture to allow the graft to enter the subacromial space. In the unavailability of this model, we performed without the cannula, but with caution to avoid the interposition of soft parts in the LP, always seeking to visualize the passage of the suture through the same hole in the deltoid.

Preparation

Complete joint and subacromial inspection is done. Complete or partial ruptures greater than 5 mm from the subscapular are repaired. After the end of the joint inventory, the subacromial space is approached and a broad bursectomy is performed. The tendon of the long head of the biceps is addressed when presenting subluxation or dislocation, partial lesions greater than 50%, or in the existence of lesions of superior labrum of types 2, 3, and 4, according to Snyder's classification. If the irreparability of the supraspinatus tendon is confirmed, the superior capsule reconstruction procedure will be initiated.

Greater tuberosity is debrided until it is free of tendon stumps and bursal tissue, presenting a good bed for the graft. The upper portion of the glenoid is debrided to the spine of the scapula posteriorly and to the base of the coracoid anteriorly. The upper glenoid neck is prepared until there is a bleeding bed. Preparation should be avoided beyond

1.5 cm medial to the glenoid joint surface to avoid damage to the suprascapular nerve. The base of the coracoid should be visualized and prepared because the anterior anchor should be inserted immediately lateral to the coracoid.

anchors

After preparation, the anchors should be inserted in the planned places. For the superior capsule reconstruction with a single row technique, at least four anchors are used. The preference is for absorbable anchors, double loaded with high strength suture. However, metal anchors can also be used, both in the glenoid and in greater tuberosity. There is a potential disadvantage if a revision for a reverse arthroplasty is necessary. In this same technique, lateral anchors can be added in the tuberosity for double row fixation, which increases the mechanical resistance of the reconstruction.

The glenoid anchors are inserted initially, with visualization by the LP. The anterior anchor is inserted by the AP, which should allow a suitable angle of attack just lateral to the base of the coracoid, ~1 cm medial to the articular surface of the glenoid. The P anchor can be inserted through the NP ~2 cm from the previous anchor.

Greater tuberosity anchors will be inserted through the accessory portals, AS and PS. In the single-row technique, anchors are inserted ~1 cm lateral to the joint border of the humeral head.

Measurement of Distances between the Fixation Points

The distances between the four anchors are measured below, as shown in ►Fig. 1. There are specific instruments for this purpose, but we made these measurements with a non-absorbable suture and a grasper forceps. It is the distance between the anchors of the glenoid and the tuberosity that will allow adequate graft tension, and the procedure must be done carefully and with the shoulder static at a 45° abduction.

Preparation of Fascia Lata Allograft

The allografts come from the tissue bank of our service, and they are donated by deceased individuals with encephalic death. All the donated tissues are submitted to a rigorous serological control and mechanical processing: they are immersed in emulsifying solutions based on hydrogen peroxide and alcohol under ultrasonic agitation, and fragments samples are submitted to microbiological and histopathological evaluation. The packaging is made in sterile, vacuum-sealed and properly labeled triple wrappers. The tissues are stored in cryopreservation rooms (between -85 and -110°C/-121 and -166°F) for a maximum period of 5 years. The preparation of the fascia lata allograft is done by an assistant, soon after determining the irreparability of the supraspinal tendon. We prepared the graft in a standard size, 4 cm wide and 5.5 cm long, folded 4 times over itself. The thickness

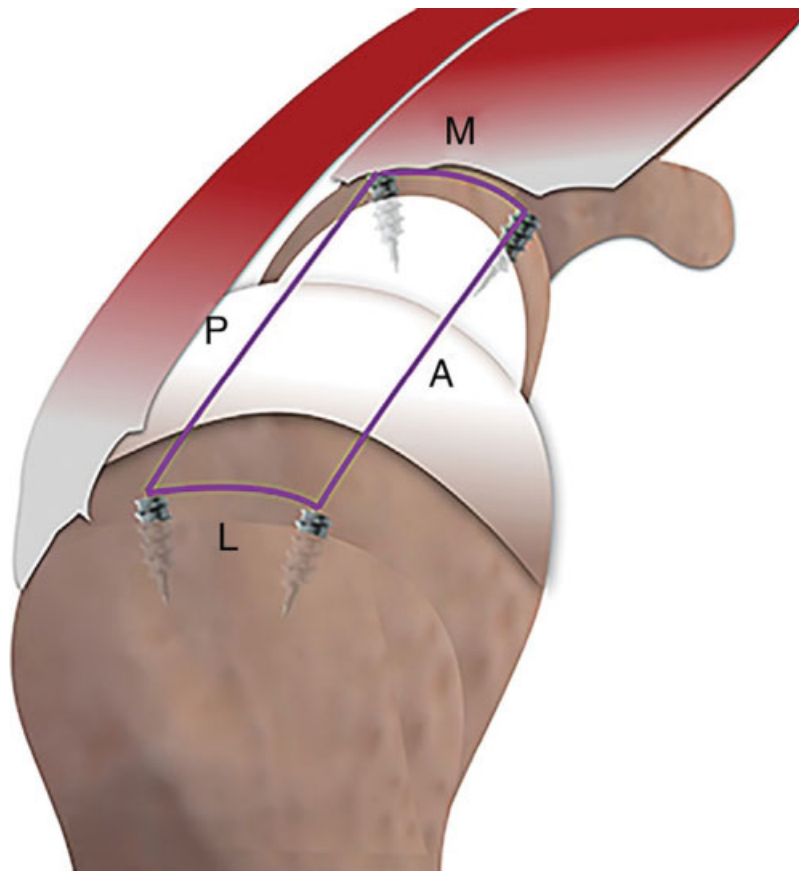


Fig. 1 Measurements of the distances between the anterior and posterior glenoid anchors (M measure) and the major tuberosity (L measure), and of the distance between the glenoid anchors and the anterior (A measure) and posterior (P measure) major tuberosities.

obtained varies from 4 to 6 mm. Simple sutures are made around all edges of the graft with 2-0 nonabsorbable suture. Additional sutures are made between the layers, in the center of the graft, to prevent their slippage.

The measurements described above are used to determine the site of passage of the points in the graft. Two nonabsorbable suture are also passed on the posterior border of the graft for repair of the infraspinatus tendon in the graft, attached with a thick knot, which prevents it from slipping. The final graft and suture appearance are shown in ►Fig. 2.

Suture Management and Graft Insertion

The most complex steps of the procedure are the handling of the suture and the passage of the suture in the graft. We describe our technique in ►Fig. 3.

The suture is based on the use of the double-pulley knot in the glenoid and in greater tuberosity, allowing the graft to be

taken to the subacromial space in the definitive position and with the appropriate tension.

Postoperative Follow-Up

After the surgical procedure, the patients are immobilized with an abdominal cushion sling for 6 weeks. Rehabilitation follows the same protocol as an massive rotator cuff repair. Patients are instructed to do passive shoulder movement after 4 weeks and active after 6 weeks. Twelve weeks after surgery, the patients begin to exercise to strengthen the remaining rotator cuff and the stabilizing musculature of the scapula.

Final Comments

Reconstruction of the upper capsule is a promising technique for a clinical situation with no gold standard of treatment. This explanation of the technique, based on our initial experience in an ongoing prospective cohort, describes in

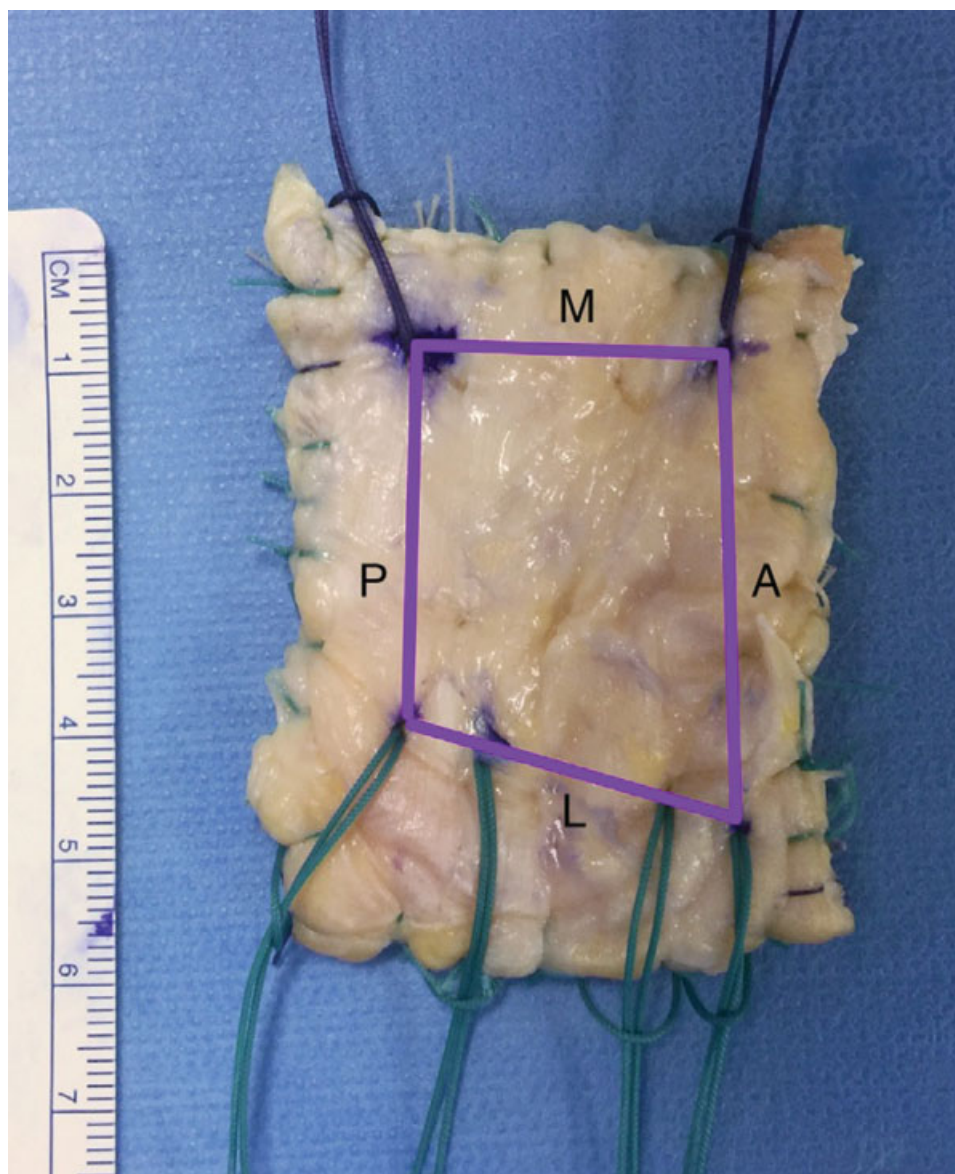


Fig. 2 Temporary suture inserted in the previously measured sites, with different colors for the lateral (green) and medial (purple) portions of the graft. Abbreviations: A, anterior; P, posterior; M, medial; L, lateral.

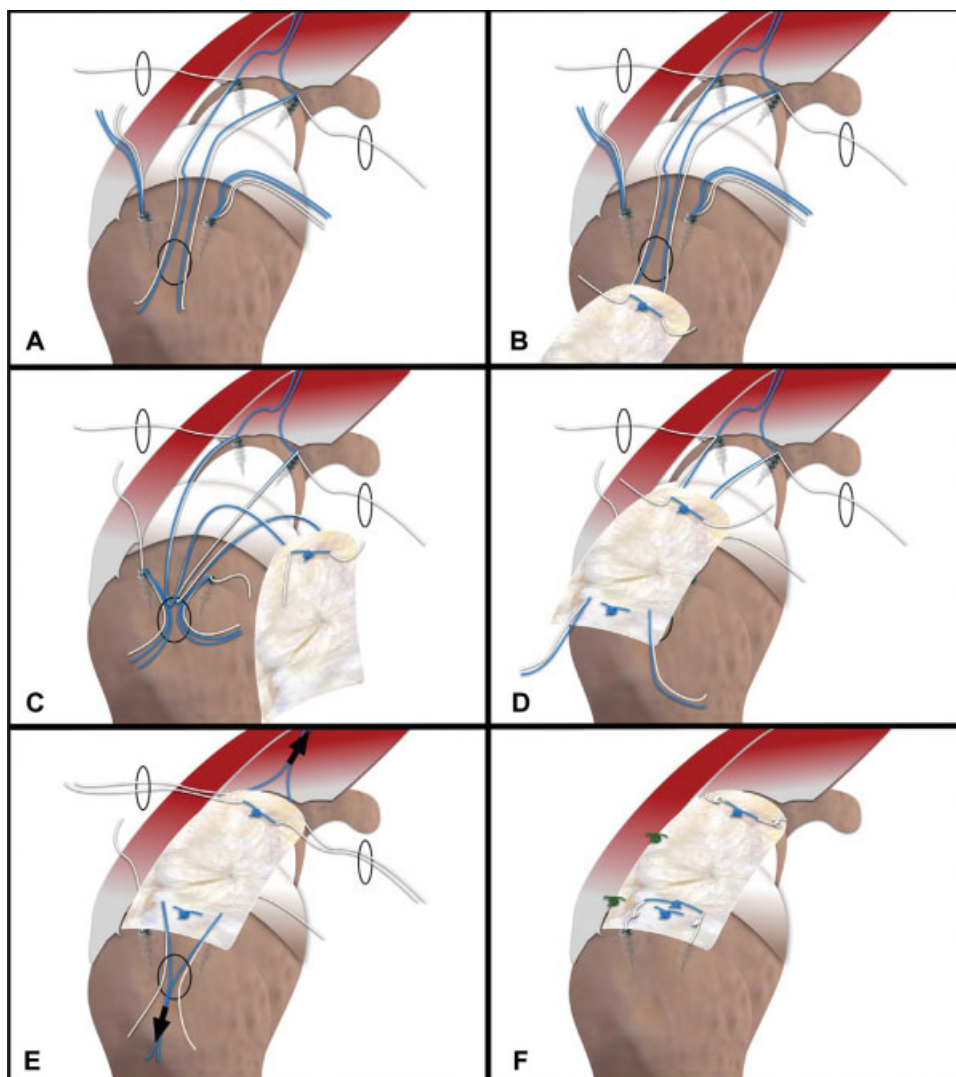


Fig. 3 Detailed description of the graft suture. (A). The anchor suture of the glenoid are passed through the portals shown; (B). The suture (white and blue) are sutured at the medial border of the graft. The two blue suture (one of each anchor of the glenoid) will be sutured together, creating a double pulley; (C). With the graft external to the shoulder, three suture from each anchor of the tuberosity (two blue and one white) are passed through the lateral portal; (D). A suture of each color of the anterior and posterior anchors of the tuberosity is passed in the previously marked place (distance L). The remaining blue suture are then sutured, forming a lateral double pulley; (E). The blue suture from the Neviaser portal are drawn at that moment, and the graft is pushed into the subacromial space with the aid of a forceps. Next, the double-side pulley suture are drawn, and the graft is provisionally fixed. (F). The medial and lateral white suture are sutured with sliding knots, before the blue suture of the double pulleys. The blue suture are then sutured with non-slip knots. In the end, two or more points are made between the graft and the infraspinatus.

detail a feasible and reproducible arthroscopic option that has shown good clinical outcomes. In addition, it is the first superior capsular reconstruction study to describe the use of fascia lata allograft, available at national tissue bank centers, which avoids donor site morbidity. For services that do not have the availability of a tissue bank, the same suture technique described in this article may be applied with the use of fascia lata autograft, as described initially by Mihata et al,^{1,4} despite increasing the morbidity and the surgical time of the procedure.

Despite the description of good functional results,^{1,3} future clinical studies are needed to determine the efficacy of this method over the long term, rates of healing of the reconstructed capsule, and to compare it with traditional methods, such as partial repair of the rotator cuff.

Conflicts of Interest

The authors declare that there are no conflicts of interest.

References

- 1 Mihata T, Lee TQ, Watanabe C, et al. Clinical results of arthroscopic superior capsule reconstruction for irreparable rotator cuff tears. *Arthroscopy* 2013;29(03):459-470
- 2 Mihata T, McGarry MH, Pirollo JM, Kinoshita M, Lee TQ. Superior capsule reconstruction to restore superior stability in irreparable rotator cuff tears: a biomechanical cadaveric study. *Am J Sports Med* 2012;40(10):2248-2255
- 3 Mihata T, Lee TQ, Itami Y, Fujisawa Y, Ohue M, Neo M. Arthroscopic superior capsule reconstruction for irreparable rotator cuff tears: a prospective clinical study in 100 consecutive patients with 1 to 8 years of follow-up. *J Shoulder Elbow Surg* 2016;25(06):e188-e190

- 4 Mihata T, McGarry MH, Kahn T, Goldberg I, Neo M, Lee TQ. Biomechanical effect of thickness and tension of fascia lata graft on glenohumeral stability for superior capsule reconstruction in irreparable supraspinatus tears. *Arthroscopy* 2016;32(03):418-426
- 5 Mihata T, McGarry MH, Kahn T, Goldberg I, Neo M, Lee TQ. Biomechanical role of capsular continuity in superior capsule reconstruction for irreparable tears of the supraspinatus tendon. *Am J Sports Med* 2016;44(06):1423-1430
- 6 Tokish JM, Beicker C. Superior capsule reconstruction technique using an acellular dermal allograft. *Arthrosc Tech* 2015;4(06):e833-e839
- 7 Adams CR, Denard PJ, Brady PC, Hartzler RU, Burkhart SS. The arthroscopic superior capsular reconstruction. *Am J Orthop* 2016;45(05):320-324