

## Hypoparathyroidism with Fahr's syndrome: A case report and review of the literature

Yuan-Yuan Zhou, Ying Yang, Hong-Mei Qiu

**ORCID number:** Yuan-Yuan Zhou (0000-0003-2608-4866); Ying Yang (0000-0001-5753-7106); Hong-Mei Qiu (0000-0002-7893-3770).

**Author contributions:** Zhou YY was the patient's endocrinologist, reviewed the literature, and contributed to manuscript drafting; Yang Y was responsible for the revision of the manuscript for important intellectual content and final approval of the version of the article to be published; Qiu HM revised the manuscript; all authors issued final approval for the version to be submitted.

**Supported by** Endocrine Clinical Medical Center of Yunnan Province, No. ZX2019-02-02; Endocrine Clinical Medical Center of Yunnan Province, No. ZX2019-02-02; Natural Science Foundation of China (No. 81760734; No. 31660313); Natural Science Foundation of Yunnan Province (No. 2017FA048; No. 2017FE467); the fund of Diabetic Innovation Team (No. 2019HC002); the fund of medical leader in Yunnan Province (No. L-201609)

**Informed consent statement:** Written informed consent was obtained from the patient for publication of this report and any accompanying images.

**Conflict-of-interest statement:** The authors declare that they have no conflict of interest.

**CARE Checklist (2016) statement:** The authors have read the CARE Checklist (2013), and the manuscript was prepared and revised according to the CARE

**Yuan-Yuan Zhou, Ying Yang,** Department of Endocrinology and Metabolism, Fourth Affiliated Hospital of Kunming Medical University and The Second People's Hospital of Yunnan Province, Kunming 650021, Yunnan Province, China

**Yuan-Yuan Zhou, Hong-Mei Qiu,** Department of Endocrinology and Metabolism, Sixth Affiliated Hospital of Kunming Medical University and The People's Hospital of Yuxi City, Yuxi 653100, Yunnan Province, China

**Corresponding author:** Ying Yang, PhD, MD, Chief Doctor, Department of Endocrinology and Metabolism, Fourth Affiliated Hospital of Kunming Medical University and The Second People's Hospital of Yunnan Province, No. 176, Youth Road, Kunming 650021, Yunnan Province, China. [yangying2072@126.com](mailto:yangying2072@126.com)

**Telephone:** +86-13577751233

### Abstract

#### BACKGROUND

Hypoparathyroidism with basal ganglia calcification is clinically rare. Here, we report a case of Fahr's syndrome due to hypoparathyroidism and review the literature in terms of etiology, clinical manifestation, diagnosis, and treatment.

#### CASE SUMMARY

A 62-year-old man experienced repeated twitching of both hands in recent 10 years. On July 28, 2017, the patient was admitted to our hospital due to slow response and speech difficulties. On medical examinations, he had a positive Chvostek sign, while no Albright's hereditary osteodystrophy signs or history of neck surgery or radiation, and his family members had no similar medical history. Laboratory examinations revealed hypocalcemia, hyperphosphatemia, and low parathyroid hormone (PTH) levels. Computed tomography revealed basal ganglia calcification. Based on these investigations, a diagnosis of Fahr's syndrome due to hypoparathyroidism was suggested. After receiving intravenous calcium gluconate to relieve symptoms, the patient continued to take oral calcium carbonate and calcitriol for treatment.

#### CONCLUSION

The possibility of hypoparathyroidism should be considered in patients with chronic hypocalcemia, recurrent tetany, and even neuropsychiatric symptoms. Hypoparathyroidism is a common cause of basal ganglia calcification. Therefore, it is recommended that blood calcium, phosphorus, and PTH levels should be measured in all individuals with basal ganglia calcification to exclude hypoparathyroidism.

Checklist (2016).

**Open-Access:** This article is an open-access article which was selected by an in-house editor and fully peer-reviewed by external reviewers. It is distributed in accordance with the Creative Commons Attribution Non Commercial (CC BY-NC 4.0) license, which permits others to distribute, remix, adapt, build upon this work non-commercially, and license their derivative works on different terms, provided the original work is properly cited and the use is non-commercial. See: <http://creativecommons.org/licenses/by-nc/4.0/>

**Manuscript source:** Unsolicited manuscript

**Received:** April 16, 2019

**Peer-review started:** April 19, 2019

**First decision:** September 9, 2019

**Revised:** September 24, 2019

**Accepted:** October 5, 2019

**Article in press:** October 5, 2019

**Published online:** November 6, 2019

**P-Reviewer:** Chen GX

**S-Editor:** Dou Y

**L-Editor:** Wang TQ

**E-Editor:** Liu MY



**Key words:** Hypoparathyroidism; Hypocalcemia; Fahr's syndrome; Case report

©The Author(s) 2019. Published by Baishideng Publishing Group Inc. All rights reserved.

**Core tip:** The clinical manifestations of hypoparathyroidism are complex and varied. Fahr's syndrome is diagnosed when basal ganglia calcification occurs. Fahr's syndrome is clinically rare. Here, we report a case of Fahr's syndrome due to hypoparathyroidism and review the literature from etiology, clinical manifestation, diagnosis, and treatment. On the one hand, this case reflects the importance of standardized treatment and follow-up in patients with hypoparathyroidism. On the other hand, it is recommended that clinicians first consider the possibility of hypoparathyroidism when looking for the cause of basal ganglia calcification.

**Citation:** Zhou YY, Yang Y, Qiu HM. Hypoparathyroidism with Fahr's syndrome: A case report and review of the literature. *World J Clin Cases* 2019; 7(21): 3662-3670

**URL:** <https://www.wjgnet.com/2307-8960/full/v7/i21/3662.htm>

**DOI:** <https://dx.doi.org/10.12998/wjcc.v7.i21.3662>

## INTRODUCTION

Hypoparathyroidism refers to an endocrine disorder caused by insufficient secretion and/or effect of parathyroid hormone (PTH)<sup>[1]</sup>. Its clinical manifestations are varied; however, the main manifestation is increased excitability of nerves and muscles caused by decreased blood calcium. Fahr's syndrome is diagnosed when hypoparathyroidism is combined with basal ganglia calcification<sup>[2]</sup>. Although Fahr's syndrome is not clinically frequent, hypoparathyroidism is the most common cause<sup>[3]</sup>.

## CASE PRESENTATION

### Chief complaints

On July 28, 2017, a 62-year-old male farmer was admitted to the Emergency Department of People's Hospital of Yuxi City (China) due to slow response and speech difficulties for half a day.

### History of present illness

The patient has experienced repeated twitching of both hands in recent 10 years. He had been diagnosed as "hypocalcemia" in a primary hospital, and the symptoms can be alleviated after "calcium supplementation". However, the patient had poor compliance and did not regularly take calcium supplements. The symptoms mentioned above were repeated.

### History of past illness

The patient had cataract, while no history of neck surgery or neck radiation.

### Personal and family history

He had no history of smoking or drinking. His family members had no similar medical history.

### Physical examination

His vital signs were as follows: Blood pressure was 130/80 mmHg, pulse rate was 70 beat per minutes, respiratory rate was 20 breaths/min, and body temperature was 36.4 °C. His consciousness was clear. Neurological examination revealed a positive Chvostek sign, while no Albright's hereditary osteodystrophy (AHO) signs, and cranial nerve abnormalities were not observed.

### Laboratory examinations

The laboratory examinations are shown in Table 1, Coagulation function and glucose were within normal limits. There were no significant changes in full blood count or blood gas analysis. Electrolyte analysis revealed hypocalcemia and hyperphosphatemia: Total calcium, 1.28 mmol/L (normal range: 2.04-2.39 mmol/L); free calcium, 0.64 mmol/L (normal range: 1.00-1.25 mmol/L); phosphorus, 2.08

mmol/L (normal range: 0.87-1.45 mmol/L).

### **Imaging examinations**

Brain, chest, and abdomen computed tomography showed: (1) Multiple calcifications in the dentate nucleus and basal ganglia of bilateral cerebellum hemispheres (Figure 1); (2) Inflammation in bilateral lower lobes of the lungs; (3) Pulmonary balloon shadow in bilateral lower lobes near the pleura; (4) A small amount of pleural effusion in the right pleura; (5) Right renal cyst; and (6) No abnormality was found in plain scans of the liver, gallbladder, pancreas, spleen, left kidney, and lower abdomen.

### **Further diagnostic work-up**

Combined with hypocalcemia, hyperphosphatemia, and basal ganglia calcification, suspected hypoparathyroidism was preliminarily diagnosed. The patient was admitted to the Department of Endocrinology for further diagnosis and treatment. The relevant auxiliary examinations are shown in Table 1. Regulatory hormones involved in the metabolism of calcium and phosphorus had changed: PTH, 2.46 ng/L (normal range: 6.0-80.0 ng/L); calcitonin (CT), 6.9 ng/L (normal range: 0.0-18.0 ng/L); 25-hydroxy (OH) vitamin D, 85.75 nmol/L (normal range: 76.0-250.0nmol/L). Thyroid function test revealed low triiodothyronine syndrome: free triiodothyronine and triiodothyronine were lower than normal ranges. The 24 h urine phosphorus was decreased to 3.63 mmol/24 h (normal range: 12.9-42.0 mmol/24 h). There was no remarkable changes in liver function or pituitary hormones. The renal function, sex hormones, cortisol rhythm, tumor markers, and antinuclear antibody spectrum were within the normal ranges. Electrocardiography (ECG) revealed (Figure 2): (1) Sinus rhythm; (2) ECG axis shifting  $-61^{\circ}$  to the left; and (3) QS type in the II, III, and aVF leads. Thyroid sonography revealed no abnormalities in bilateral thyroid glands and their periphery. Electroencephalogram and echocardiography results were not available because the patient refused.

---

## **FINAL DIAGNOSIS**

Fahr's syndrome due to hypoparathyroidism was taken as a final diagnosis into account.

---

## **TREATMENT**

Combined with the clinical manifestations and laboratory examinations of the patient, it was revealed that there was acute hypocalcemia. Calcium gluconate (10%; 10 mL) was slowly intravenously injected for treatment. Because of repeated symptoms, the patient was given continuous intravenous drip of calcium (10% calcium gluconate [100 mL] diluted to 5% glucose solution [1000 mL]). Acute symptoms were relieved after 3 d, and calcium carbonate (600 mg calcium carbonate was administered 3 times/d) and calcitriol (0.25  $\mu$ g calcitriol was administered twice/d) were given routinely. Blood electrolyte changes during treatment are shown in Table 2. Due to the patient's economic constraints, the patient required to be discharged automatically after 11 days of hospitalization.

---

## **OUTCOME AND FOLLOW-UP**

The patients did not attend follow-up visits regularly at our hospital, thus the follow-up data could not be obtained.

---

## **DISCUSSION**

Hypoparathyroidism is a clinical syndrome caused by insufficient secretion and/or influence of PTH. Its clinical characteristics are mainly manifested as hypocalcemia, hyperphosphatemia, increased neuromuscular excitability as well as heterotopic calcification of soft tissues<sup>[1]</sup>. It is noteworthy that the clinical syndrome of hypocalcemia, hyperphosphatemia, and hyper PTH are called pseudo-hypoparathyroidism (PHP) because of the resistance of target organs (*e.g.*, the kidneys and bone) to PTH. Some patients have been reported to have special physical deformities, such as short stature, obesity, round face, short neck, short finger (toe), and even mental retardation, *i.e.*, typical AHO<sup>[1,4]</sup>. An epidemiological survey

Table 1 Results of laboratory examinations

	Value	Normal range
Liver function		
TBIL	26.8	≤21.0 μmol/L
DBIL	10	0.0-6.8 μmol/L
IBIL	16.8	0.5-10.5 μmol/L
TP	63.1	65.0-85.0 g/L
ALB	40.8	40-55 g/L
AST	34	15-40 IU/L
ALT	42	9-50 IU/L
ALP	83	45-125 IU/L
Thyroid function		
FT3	2.67	3.22-6.47 pmol/L
FT4	20.51	10.18-21.36 pmol/L
T3	0.43	0.73-1.91 μg/L
T4	68	45-135 μg/L
TSH	0.743	0.3-4.44 mIU/L
a-Tg	6.06	0.0-100.0 IU/mL
Tg	5.68	0.0-70.0 μg/L
a-TPO	3.31	0.0-16.0 IU/ml
Coagulation function		
PT	13.7	11.0-14.5 s
aPTT	35.6	26.0-42.0 s
TT	16.4	14.0-21.0 s
FIB	4.88	2.0-4.0 g/L
Blood gas analysis		
pH	7.46	7.35-7.45
PO <sub>2</sub>	91.2	85.0-105.0 mmHg
PCO <sub>2</sub>	33.6	35.0-45.0 mmHg
HCO <sub>3</sub> <sup>-</sup>	23.6	22.0-29.0 mmol/L
Pituitary hormone		
FSH	14.98	1.3-11.8 IU/L
LH	12.76	2.8-6.8 IU/L
PRL	13.25	4.1-18.5 μg/L
Sex hormone		
E2Gen	39.3	0.0-44.5 ng/L
PROG	0.58	0.0-0.61 g/L
TEST	1.38	1.95-8.95 μg/L
Blood cell count		
WBC	10.06 × 10 <sup>9</sup>	3.5-9.5 × 10 <sup>9</sup> /L
RBC	4.99 × 10 <sup>12</sup>	4.3-5.8 × 10 <sup>12</sup> /L
PLT	206 × 10 <sup>9</sup>	125.0-350.0 × 10 <sup>9</sup> /L
Others		
PTH	2.46	6.0-80.0 ng/L
CT	6.9	0.0-18.0 ng/L
25OHD	85.75	76.0-250.0 nmol/L
24 h urinary calcium	4.07	2.7-7.5 mmol/24 h
24 h urine phosphorus	3.63	12.9-42.0 mmol/24 h

TBIL: Total bilirubin; DBIL: Direct bilirubin; IBIL: Indirect bilirubin; TP: Total protein; ALB: Albumin; AST: Aspartate aminotransferase; ALT: Alanine aminotransferase; ALP: Alkaline phosphatase; FT3: Free triiodothyronine; FT4: Free tetraiodothyronine; T3: Triiodothyronine; T4: Tetraiodothyronine; TSH: Thyroid-stimulating hormone; a-Tg: Anti-thyroglobulin antibody; Tg: Thyroglobulin; a-TPO: Thyroid peroxidase antibody; PT: Prothrombin time; aPTT: Activated partial thromboplastin time; TT: Thrombin time; FIB: Fibrinogen; pO<sub>2</sub>: Partial pressure of oxygen; pCO<sub>2</sub>: Partial pressure of carbon dioxide; HCO<sub>3</sub><sup>-</sup>: Actual bicarbonate radical; FSH: Follicle stimulating hormone; LH: Luteinizing hormone; PRL: Prolactin; E2Gen: Estradiol; PROG: Progesterone; TEST: Testosterone; PTH: Intact parathormone; CT: Calcitonin; 25OHD: 25-

hydroxy (OH) vitamin D; WBC: White blood cells; RBC: Red blood cells; PLT: Platelets.

conducted in Japan showed that 58% of PHP patients were female<sup>[5]</sup>. A patient who has a singular sign of AHO while lacks a corresponding biochemical and metabolic abnormality is regarded to have pseudo-PHP<sup>[1]</sup>.

The causes of hypoparathyroidism are varied. Neck surgery is the most frequent cause of hypoparathyroidism, accounting for about 75%<sup>[1]</sup>. Second, autoimmune diseases and genetic factors can affect parathyroid glands alone or simultaneously influence several other endocrine glands<sup>[6-8]</sup>. Gene detection is an important auxiliary diagnostic method. For example, type 1 autoimmune polyglandular syndrome, in addition to hypoparathyroidism, is also associated with Edison's disease, candidiasis, malignant anemia, type 1 diabetes mellitus, primary hypothyroidism, autoimmune thyroid disease and so on<sup>[9]</sup>. Moreover, abnormal magnesium metabolism, both hypermagnesemia and severe hypomagnesemia, could inhibit the secretion and function of PTH<sup>[6,10]</sup>. If factors, such as surgery, inheritance, and abnormal magnesium metabolism are excluded, rare causes, involving invasive diseases, tumor metastasis, and ionizing radiation, should be considered<sup>[6]</sup>.

In this case, the clinical manifestation of the patient was recurrent tetany in the past 10 years, and his personality gradually became isolated. The patient visited hospital because of slow reaction and speech difficulties. He had a positive Chvostek sign, while no AHO signs; he had no history of neck surgery or radiation; however, a history of cataract (suggesting ectodermal malnutrition) was found. Laboratory tests showed that total blood calcium and free calcium were significantly lower than normal, blood phosphorus was elevated, urine phosphorus was reduced, blood magnesium was normal, PTH was lower than normal, and bone turnover index was normal. There was no evidence of hypocalcemia caused by vitamin D deficiency, liver and kidney dysfunction, alkalosis, malnutrition, *etc.* No evidence of autoimmune diseases (*e.g.*, hypofunction of adrenal cortex, autoimmune-related hypothyroidism, and diabetes) or tumors was noted as well. However, genetic testing could not be undertaken due to the limitations, thus genetic factors could not be excluded. Therefore, the etiology of hypoparathyroidism was undetermined. The patient's brain computed tomography showed manifestations in the basal ganglia, simultaneously suggesting the diagnosis of Fahr's syndrome.

Basal ganglia calcification, also known as Fahr's syndrome or Fahr's disease, is a neurological disorder, in which there are calcium deposits abnormally in areas of the brain that control motor activity, leading to neuropsychiatric symptoms<sup>[11]</sup>. However, it should be clearly pointed out that Fahr's syndrome is not exactly Fahr's disease, although they have similar clinical manifestations, and there are obvious differences in etiology, prognosis, and treatment. Fahr's syndrome is often associated with other diseases, and parathyroid dysfunction (especially hypoparathyroidism) is the most common cause of Fahr's syndrome<sup>[3,12]</sup>. With the improvement of the means of diagnosis, cases of Fahr's syndrome caused by hypoparathyroidism had gradually increased in recent years. Most patients had neuropsychiatric symptoms or motor disorder, including seizure<sup>[13]</sup>, early onset dementia<sup>[14]</sup>, chorea<sup>[15]</sup>, *etc.* Furthermore, some rare complications have also been reported, such as cerebral hemorrhage<sup>[16]</sup> and thoracic ossification of the posterior longitudinal ligament<sup>[17]</sup>. In addition to hypoparathyroidism, Fahr's syndrome can also be observed in neuroferritinopathy, Kenny-Caffey syndrome type 1, intrauterine or perinatal infection (*e.g.*, toxoplasma gondii, rubella), tuberous sclerosis complex, brucella infection, *etc.*<sup>[2,18]</sup>. Fahr's disease refers to familial idiopathic basal ganglia calcification, which is a rare hereditary neurodegenerative disease. It has the following characteristics: Autosomal dominant inheritance; age of onset is concentrated in 40-60 years old; large, progressive, bilateral symmetrical calcification of the basal ganglia; exclusive of infection, trauma, or poisoning; exclusive of mitochondrial or metabolic diseases or other systemic diseases<sup>[2,18]</sup>. For the past years, some mutations in genes that are related to Fahr's disease had been identified, including *SLC20A2*, *PDGFRB*, *PDGFB*, and *XPR1*, together with novel mutations in the myogenic regulating glycosylase gene<sup>[19]</sup>.

Fahr's syndrome and Fahr's disease share similar clinical manifestations, mainly neurological signs (*e.g.*, loss of consciousness, tetany, and epilepsy)<sup>[3]</sup>, motor disorder (*e.g.*, clumsiness, involuntary movement, and muscle cramping)<sup>[20,21]</sup>, as well as neuropsychiatric features (*e.g.*, mild difficulty with concentration and memory, changes in personality or behaviors, psychosis, and dementia)<sup>[22,23]</sup>. In contrast to Fahr's disease, which has no effective treatment, Fahr's syndrome can be remarkably improved after correcting the primary etiology.

Calcium and vitamin D preparations are the basic treatment for hypoparathyroidism<sup>[24,25]</sup>. Therapeutic principle is based on the fact that deficiency or

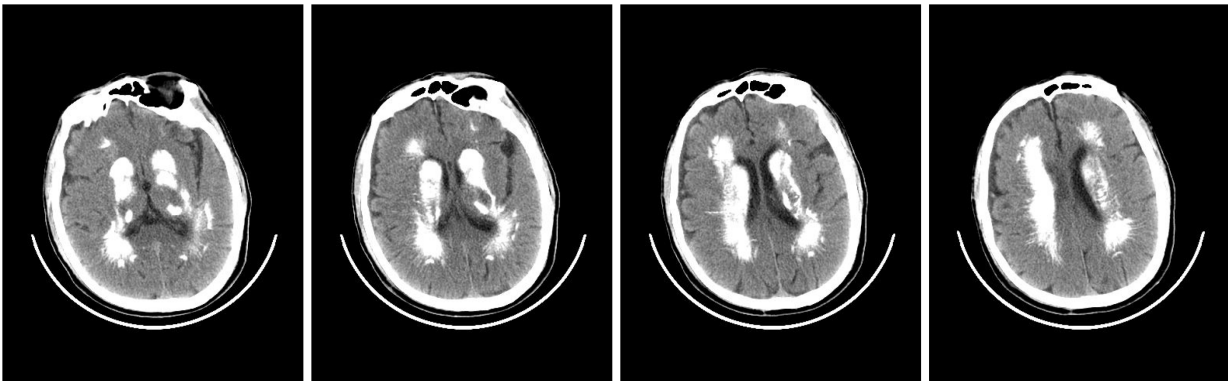


Figure 1 Computed tomography of the brain showed multiple calcifications in the dentate nucleus and basal ganglia of bilateral cerebellum hemispheres.

dysfunction of PTH may lead to a decrease in production of 1-25 (OH), an active metabolite of vitamin D, leading to a decrease in intestinal calcium uptake<sup>[26]</sup>. Calcium carbonate is the most commonly used calcium agent, containing 40% of elemental calcium<sup>[27]</sup>. It has been recommended to supplement calcium 500-1000 mg, 2-3 times/d. Active vitamin D preparations recommended are calcitriol (0.25-2 µg/d) and 1 alpha-hydroxy vitamin D (0.5-3 µg/d)<sup>[28-30]</sup>. If the patient has recurrent tetany, acute hypocalcemia is predicted. Slow intravenous infusion of 10% calcium gluconate 10-20 mL (90-180 mg elemental calcium, 10-20 min) usually relieves symptoms immediately. If the symptoms are repeated and difficult to alleviate, continuous intravenous drip of calcium is necessary, *i.e.*, 10% calcium gluconate 100 mL (930 mg elemental calcium) should be diluted to 5% calcium gluconate 1000 mL<sup>[31-32]</sup>. Routine supplementation of calcium and active vitamin D should be given after remission of acute symptoms. In this case, because of acute hypocalcemia and repeated symptoms at the beginning of admission, the patient was given continuous intravenous drip of calcium. Calcium carbonate and calcitriol were given routinely after the acute symptoms were relieved three days later. It is worth noting that if long-term supplementation of large doses of calcium and active vitamin D fails to meet the treatment target, PTH replacement therapy, such as rhPTH1-34 (Teriparatide)<sup>[7,33,34]</sup> or rhPTH1-84 (Natpara)<sup>[35-37]</sup>, may be a promising option. In addition, health education is also an important part of treatment. Patients and family members should acquire basic knowledge on clinical manifestations and treatment, and understand the importance of regular follow-up to prevent or delay the occurrence of long-term complications.

## CONCLUSION

In this case report, because the primary hospital is limited to temporary treatment of calcium supplement symptoms, the cause of the disease has not been further investigated and the relevant laboratory tests have not been improved, resulting in the patient tossing and turning for 10 years before the final diagnosis. Therefore, for patients with long-term hypocalcemia, recurrent tetany, or even epileptic-like psychiatric symptoms, clinicians should associate with the possibility of hypoparathyroidism in order to make early diagnosis and treatment. Hypoparathyroidism is a common cause of basal ganglia calcification in the majority of individuals. It is recommended to determine serum calcium, phosphorus, and PTH levels in all individuals with basal ganglia calcification and exclude hypoparathyroidism. In addition, hypoparathyroidism is often accompanied by other complications and comorbidities. It is important for clinicians, especially endocrinologists, to understand the clinical manifestations, diagnosis, and treatment of the disease.

Table 2 Blood electrolyte changes during treatment

Date	Potassium	Sodium	Chlorine	Total calcium	Free calcium	Phosphorus	Magnesium	Lactic acid
7.28	3.39	138	100	1.41	0.70	2.07	0.72	1.4
7.29 (06:30)	3.74	136	100	1.79	0.9	2.21	0.72	1.7
7.29 (15:00)	3.87	138	100	1.83	0.92	2.05	0.73	2.2
7.30 (06:00)	3.88	136	97	1.68	0.84	1.92	0.75	2.2
7.30 (16:00)	4.02	139	101	2.13	1.06	1.96	0.76	2.5
7.31	4.08	135	99	1.87	0.94	1.82	0.81	2.2
8.1	4.01	137	97	1.87	0.94	1.44	0.81	2.9
8.2	3.52	139	99	1.76	0.88	1.73	0.82	1.6
8.3	3.94	137	96	1.87	0.94	1.61	0.91	2.0
8.7	3.94	135	96	1.91	0.95	1.87	0.89	2.4

Normal ranges: Potassium, 3.5-5.3 mmol/L; Sodium, 137-147 mmol/L; Chlorine, 99-110 mmol/L; Total calcium, 2.04-2.39 mmol/L; Free calcium, 1-1.25 mmol/L; Phosphorus, 0.87-1.45mmol/L; Magnesium, 0.65-1.05 mmol/L; Lactic acid, 1.3-2.8 mmol/L.

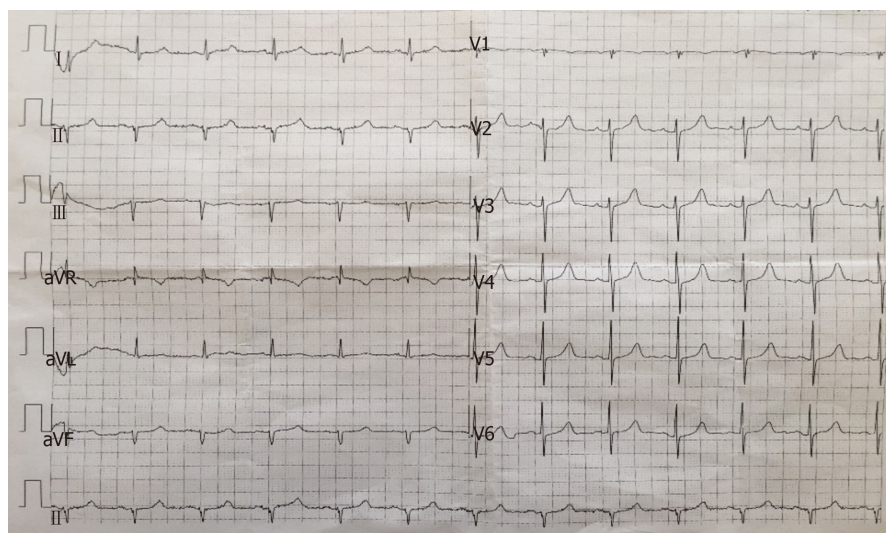


Figure 2 Electrocardiogram showing: (1) Sinus rhythm; (2) Electrocardiogram axis shifting  $-61^{\circ}$  to the left; and (3) QS type in the II, III, and aVF leads.

## REFERENCES

- 1 **Bilezikian JP**, Khan A, Potts JT, Brandi ML, Clarke BL, Shoback D, Jüppner H, D'Amour P, Fox J, Rejnmark L, Mosekilde L, Rubin MR, Dempster D, Gafni R, Collins MT, Sliney J, Sanders J. Hypoparathyroidism in the adult: epidemiology, diagnosis, pathophysiology, target-organ involvement, treatment, and challenges for future research. *J Bone Miner Res* 2011; **26**: 2317-2337 [PMID: 21812031 DOI: 10.1002/jbmr.483]
- 2 **Perugula ML**, Lippmann S. Fahr's Disease or Fahr's Syndrome? *Innov Clin Neurosci* 2016; **13**: 45-46 [PMID: 27672489]
- 3 **Saleem S**, Aslam HM, Anwar M, Anwar S, Saleem M, Saleem A, Rehmani MA. Fahr's syndrome: literature review of current evidence. *Orphanet J Rare Dis* 2013; **8**: 156 [PMID: 24098952 DOI: 10.1186/1750-1172-8-156]
- 4 **Levine MA**. An update on the clinical and molecular characteristics of pseudohypoparathyroidism. *Curr Opin Endocrinol Diabetes Obes* 2012; **19**: 443-451 [PMID: 23076042 DOI: 10.1097/MED.0b013e32835a255c]
- 5 **Nakamura Y**, Matsumoto T, Tamakoshi A, Kawamura T, Seino Y, Kasuga M, Yanagawa H, Ohno Y. Prevalence of idiopathic hypoparathyroidism and pseudohypoparathyroidism in Japan. *J Epidemiol* 2000; **10**: 29-33 [PMID: 10695258 DOI: 10.2188/jea.10.29]
- 6 **Shoback DM**, Bilezikian JP, Costa AG, Dempster D, Dralle H, Khan AA, Peacock M, Raffaelli M, Silva BC, Thakker RV, Vokes T, Bouillon R. Presentation of Hypoparathyroidism: Etiologies and Clinical Features. *J Clin Endocrinol Metab* 2016; **101**: 2300-2312 [PMID: 26943721 DOI: 10.1210/jc.2015-3909]
- 7 **Bilezikian JP**, Brandi ML, Cusano NE, Mannstadt M, Rejnmark L, Rizzoli R, Rubin MR, Winer KK, Liberman UA, Potts JT. Management of Hypoparathyroidism: Present and Future. *J Clin Endocrinol Metab* 2016; **101**: 2313-2324 [PMID: 26938200 DOI: 10.1210/jc.2015-3910]
- 8 **Clarke BL**, Brown EM, Collins MT, Jüppner H, Lakatos P, Levine MA, Mannstadt MM, Bilezikian JP, Romanischen AF, Thakker RV. Epidemiology and Diagnosis of Hypoparathyroidism. *J Clin Endocrinol Metab* 2016; **101**: 2284-2299 [PMID: 26943720 DOI: 10.1210/jc.2015-3908]

- 9 **Betterle C**, Garelli S, Presotto F. Diagnosis and classification of autoimmune parathyroid disease. *Autoimmun Rev* 2014; **13**: 417-422 [PMID: 24424178 DOI: 10.1016/j.autrev.2014.01.044]
- 10 **Schlingmann KP**, Weber S, Peters M, Niemann Nejsum L, Vitzthum H, Klingel K, Kratz M, Haddad E, Ristoff E, Dinour D, Syrrou M, Nielsen S, Sassen M, Waldegger S, Seyberth HW, Konrad M. Hypomagnesemia with secondary hypocalcemia is caused by mutations in TRPM6, a new member of the TRPM gene family. *Nat Genet* 2002; **31**: 166-170 [PMID: 12032568 DOI: 10.1038/ng889]
- 11 **Koratala A**, Morales Lappot J. Fahr's syndrome. *Intern Emerg Med* 2019; **14**: 483-484 [PMID: 30506211 DOI: 10.1007/s11739-018-1998-4]
- 12 **Illum F**, Dupont E. Prevalences of CT-detected calcification in the basal ganglia in idiopathic hypoparathyroidism and pseudohypoparathyroidism. *Neuroradiology* 1985; **27**: 32-37 [PMID: 3974864 DOI: 10.1007/bf00342514]
- 13 **Lee YJ**, Park S, Kim YW, Park KM, Kim IH, Park JH, Park BS. A Case of Seizure Revealing Fahr's Syndrome with Primary Hypoparathyroidism. *Am J Case Rep* 2018; **19**: 1430-1433 [PMID: 30504755 DOI: 10.12659/AJCR.913382]
- 14 **Kechaou I**, Boukhris I. [Hypoparathyroidism and early onset dementia: Fahr syndrome should be suspected]. *Pan Afr Med J* 2018; **30**: 82 [PMID: 30344866 DOI: 10.11604/pamj.2018.30.82.15587]
- 15 **Ramos-Lopes J**, Brás A, Morgadinho A, Moreira F. [Acute Generalized Chorea, Dystonia and Brain Calcifications: A Case Report]. *Acta Med Port* 2019; **32**: 402-406 [PMID: 31166902 DOI: 10.20344/amp.11026]
- 16 **Jang BH**, Son SW, Kim CR. Fahr's Disease With Intracerebral Hemorrhage at the Uncommon Location: A Case Report. *Ann Rehabil Med* 2019; **43**: 230-233 [PMID: 31072090 DOI: 10.5535/arm.2019.43.2.230]
- 17 **Jeon I**, Cho KH, Kim SW. Concomitant Fahr's syndrome and thoracic ossification of the posterior longitudinal ligament caused by idiopathic hypoparathyroidism - case report. *BMC Musculoskelet Disord* 2019; **20**: 362 [PMID: 31391033 DOI: 10.1186/s12891-019-2747-1]
- 18 **Ramos EM**, Oliveira J, Sobrido MJ, Coppola G. Primary Familial Brain Calcification. GeneReviews. Seattle (WA): University of Washington, Seattle 1993;
- 19 **Donzuso G**, Mostile G, Nicoletti A, Zappia M. Basal ganglia calcifications (Fahr's syndrome): related conditions and clinical features. *Neurol Sci* 2019 [PMID: 31267306 DOI: 10.1007/s10072-019-03998-x]
- 20 **Manyam BV**, Walters AS, Narla KR. Bilateral striopallidodentate calcinosis: clinical characteristics of patients seen in a registry. *Mov Disord* 2001; **16**: 258-264 [PMID: 11295778 DOI: 10.1002/mds.1049]
- 21 **Manyam BV**, Bhatt MH, Moore WD, Devleschoward AB, Anderson DR, Calne DB. Bilateral striopallidodentate calcinosis: cerebrospinal fluid, imaging, and electrophysiological studies. *Ann Neurol* 1992; **31**: 379-384 [PMID: 1586138 DOI: 10.1002/ana.410310406]
- 22 **Benke T**, Karner E, Seppi K, Delazer M, Marksteiner J, Donnemiller E. Subacute dementia and imaging correlates in a case of Fahr's disease. *J Neurol Neurosurg Psychiatry* 2004; **75**: 1163-1165 [PMID: 15258221 DOI: 10.1136/jnnp.2003.019547]
- 23 **Geschwind DH**, Loginov M, Stern JM. Identification of a locus on chromosome 14q for idiopathic basal ganglia calcification (Fahr disease). *Am J Hum Genet* 1999; **65**: 764-772 [PMID: 10441584 DOI: 10.1086/302558]
- 24 **Bollerslev J**, Rejnmark L, Marcocci C, Shoback DM, Sitges-Serra A, van Biesen W, Dekkers OM; European Society of Endocrinology. European Society of Endocrinology Clinical Guideline: Treatment of chronic hypoparathyroidism in adults. *Eur J Endocrinol* 2015; **173**: G1-20 [PMID: 26160136 DOI: 10.1530/EJE-15-0628]
- 25 **Brandi ML**, Bilezikian JP, Shoback D, Bouillon R, Clarke BL, Thakker RV, Khan AA, Potts JT. Management of Hypoparathyroidism: Summary Statement and Guidelines. *J Clin Endocrinol Metab* 2016; **101**: 2273-2283 [PMID: 26943719 DOI: 10.1210/jc.2015-3907]
- 26 **Holick MF**. Vitamin D deficiency. *N Engl J Med* 2007; **357**: 266-281 [PMID: 17634462 DOI: 10.1056/NEJMr070553]
- 27 **Heaney RP**, Dowell MS, Bierman J, Hale CA, Bendich A. Absorbability and cost effectiveness in calcium supplementation. *J Am Coll Nutr* 2001; **20**: 239-246 [PMID: 11444420 DOI: 10.1080/07315724.2001.10719038]
- 28 **Kooh SW**, Fraser D, DeLuca HF, Holick MF, Belsey RE, Clark MB, Murray TM. Treatment of hypoparathyroidism and pseudohypoparathyroidism with metabolites of vitamin D: evidence for impaired conversion of 25-hydroxyvitamin D to 1 alpha,25-dihydroxyvitamin D. *N Engl J Med* 1975; **293**: 840-844 [PMID: 170516 DOI: 10.1056/nejm197510232931702]
- 29 **Neer RM**, Holick MF, DeLuca HF, Potts JT. Effects of 1alpha-hydroxy-vitamin D3 and 1,25-dihydroxy-vitamin D3 on calcium and phosphorus metabolism in hypoparathyroidism. *Metabolism* 1975; **24**: 1403-1413 [PMID: 1196134 DOI: 10.1016/0026-0495(75)90055-4]
- 30 **Mortensen L**, Hyldstrup L, Charles P. Effect of vitamin D treatment in hypoparathyroid patients: a study on calcium, phosphate and magnesium homeostasis. *Eur J Endocrinol* 1997; **136**: 52-60 [PMID: 9037127 DOI: 10.1530/eje.0.1360052]
- 31 **Tohme JF**, Bilezikian JP. Hypocalcemic emergencies. *Endocrinol Metab Clin North Am* 1993; **22**: 363-375 [PMID: 8325292 DOI: 10.1016/S0889-8529(18)30171-3]
- 32 **Cooper MS**, Gittoes NJ. Diagnosis and management of hypocalcaemia. *BMJ* 2008; **336**: 1298-1302 [PMID: 18535072 DOI: 10.1136/bmj.39582.589433.BE]
- 33 **Winer KK**, Sinaii N, Reynolds J, Peterson D, Dowdy K, Cutler GB. Long-term treatment of 12 children with chronic hypoparathyroidism: a randomized trial comparing synthetic human parathyroid hormone 1-34 versus calcitriol and calcium. *J Clin Endocrinol Metab* 2010; **95**: 2680-2688 [PMID: 20392870 DOI: 10.1210/jc.2009-2464]
- 34 **Gafni RI**, Ibrahim JS, Andreopoulos P, Bhattacharyya N, Kelly MH, Brillante BA, Reynolds JC, Zhou H, Dempster DW, Collins MT. Daily parathyroid hormone 1-34 replacement therapy for hypoparathyroidism induces marked changes in bone turnover and structure. *J Bone Miner Res* 2012; **27**: 1811-1820 [PMID: 22492501 DOI: 10.1002/jbmr.1627]
- 35 **Mannstadt M**, Clarke BL, Vokes T, Brandi ML, Ranganath L, Fraser WD, Lakatos P, Bajnok L, Garceau R, Mosekilde L, Lagast H, Shoback D, Bilezikian JP. Efficacy and safety of recombinant human parathyroid hormone (1-84) in hypoparathyroidism (REPLACE): a double-blind, placebo-controlled, randomised, phase 3 study. *Lancet Diabetes Endocrinol* 2013; **1**: 275-283 [PMID: 24622413 DOI: 10.1016/S2213-8587(13)70106-2]
- 36 **Cusano NE**, Rubin MR, McMahon DJ, Zhang C, Ives R, Tulley A, Sliney J, Cremers SC, Bilezikian JP. Therapy of hypoparathyroidism with PTH(1-84): a prospective four-year investigation of efficacy and safety. *J Clin Endocrinol Metab* 2013; **98**: 137-144 [PMID: 23162103 DOI: 10.1210/jc.2012-2984]



- 37 **Palermo A**, Santonati A, Tabacco G, Bosco D, Spada A, Pedone C, Raggiunti B, Doris T, Maggi D, Grimaldi F, Manfrini S, Vescini F. PTH(1-34) for Surgical Hypoparathyroidism: A 2-Year Prospective, Open-Label Investigation of Efficacy and Quality of Life. *J Clin Endocrinol Metab* 2018; **103**: 271-280 [PMID: 29099939 DOI: 10.1210/jc.2017-01555]



Published By Baishideng Publishing Group Inc  
7041 Koll Center Parkway, Suite 160, Pleasanton, CA 94566, USA  
Telephone: +1-925-2238242  
E-mail: [bpgoffice@wjgnet.com](mailto:bpgoffice@wjgnet.com)  
Help Desk: <https://www.f6publishing.com/helpdesk>  
<https://www.wjgnet.com>

