

Solid variant ABC of long tubular bones: A diagnostic conundrum for the radiologist

Adarsh Ghosh, Anuradha Singh, Richa Yadav, Shah A Khan¹, Venkatesan S Kumar¹, Shivanand Gamanagatti

Departments of Radiodiagnosis and ¹Orthopaedics, All India Institute of Medical Sciences, New Delhi, India

Correspondence: Dr. Shivanand Gamanagatti, Department of Radiology, JPNA Trauma Center, AIIMS, New Delhi, India.
E-mail: shiv223@gmail.com

Abstract

Solid variant of aneurysmal bone cyst (sABC) is an extremely rare, reactive and non-neoplastic osseous lesion. On imaging it presents as a diaphyseal aggressive, eccentrically placed lytic and expansile lesion. However, differentiating this entity from the other possible malignant differentials is confounded by the histopathology mimicking several commoner lesions. We describe the distinctive MRI features of sABC of long bones from a series of four cases and briefly review the literature. We hope this review will educate all radiologists about this rare entity increasing their diagnostic confidence while formulating differentials for similar appearing lesions.

Key words: Aneurysmal bone cyst; MRI; solid Variant

Introduction

As first described by Sankerin *et al.* (1983),^[1] the solid variant of aneurysmal bone cyst (sABC) is an uncommon non-tumorous bone lesion.^[1-3] The predominant histological component in these tumours resemble the solid components found in a classical ABC.^[4] Musculoskeletal pathologists are well acquainted with this entity. sABC has been referred to variously as giant cell reparative granuloma (GCRG) and extra gnathic GCRG due to their histological similarities.^[5] sABC can masquerade as a malignancy with its clinical presentation, imaging and pathology confounding radiologists, pathologists and clinicians alike. While pathologists are usually the first to suggest this diagnosis, radiologists must be familiar with the imaging features of this otherwise innocuous condition, allaying clinical

concerns, thus avoiding unnecessary ancillary invasive diagnostic interventions and potentially radical therapies. We discuss the distinctive radiographic and MRI features of four histologically diagnosed cases of sABC of long bones.

Case Presentations

We encountered four cases of histologically proven solid variant of ABC: the demographic profile and radiologic features of which are summarised in Table 1.

Case 1

A 50-year-old female presented at the orthopedic out-patient department with progressively increasing painless swelling

This is an open access journal, and articles are distributed under the terms of the Creative Commons Attribution-NonCommercial-ShareAlike 4.0 License, which allows others to remix, tweak, and build upon the work non-commercially, as long as appropriate credit is given and the new creations are licensed under the identical terms.

For reprints contact: reprints@medknow.com

Cite this article as: Ghosh A, Singh A, Yadav R, Khan SA, Kumar VS, Gamanagatti S. Solid variant ABC of long tubular bones: A diagnostic conundrum for the radiologist. *Indian J Radiol Imaging* 2019;29:271-6.

Received: 01-Apr-2019
Accepted: 31-Aug-2019

Revision: 20-Jun-2019
Published: 30-Oct-2019

Access this article online	
Quick Response Code: 	Website: www.ijri.org DOI: 10.4103/ijri.IJRI_160_19

in the right arm for a year. Clinically, the swelling was bony hard and non-mobile. Radiograph of the right arm showed an eccentric, lytic and expansile lesion with thin shell in the mid-diaphyseal region of right humerus [Figure 1]. Subsequently the MRI showed cortical-based expansile lesion with heterogeneously hyperintense soft tissue component on fat-suppressed sequences with blood-fluid levels and extensive surrounding soft tissue and bone marrow oedema.

Case 2

A 27-year-old female presented with gradually progressive painless swelling in the left forearm of 6 months' duration. Radiograph of the forearm showed a cortical-based expansile lytic lesion with a thin shell located in the diaphysis of the ulna [Figure 2]. On MRI, the lesion showed heterogeneously hyperintense soft tissue component on

T2WI and STIR sequences with a single large blood-fluid level. Extensive marrow and soft tissue oedema were present around the tumour.

Case 3

A 30-year-old female presented with swelling in the right arm for 8 months. Though painless, the patient complained of an increase in size and associated cosmetic deformity. The radiograph showed an expansile, lytic lesion, eccentrically located in the mid-humeral diaphysis. The MRI showed heterogeneously hyperintense soft tissue on T2WI and STIR sequences with the predominant solid soft tissue component admixed with cystic areas having small blood-fluid levels. Akin to the above two cases, soft tissue and marrow oedema were characteristically present [Figure 3 and histopathology in Figure 4].

Table 1: Summary of demographic profile and radiological features of sABC cases

Demographic and Radiological features	Case number			
	1	2	3	4
Age (years)	50	27	30	16
Sex	Female	Female	Female	Female
Bone involved	Humerus	Ulna	Humerus	Radius
Location	Diaphysis	Diaphysis	Diaphysis	Diaphysis
Radiological features	Eccentric, cortical based, lytic expansile	Eccentric, cortical based, lytic expansile	Eccentric, cortical based, lytic expansile	Eccentric, cortical based, lytic expansile
MRI findings				
Soft tissue component	+	+	+	+
Bone marrow oedema	+	+	+	+
Soft tissue oedema	+	+	+	+
Blood-fluid levels	+	+	+	+

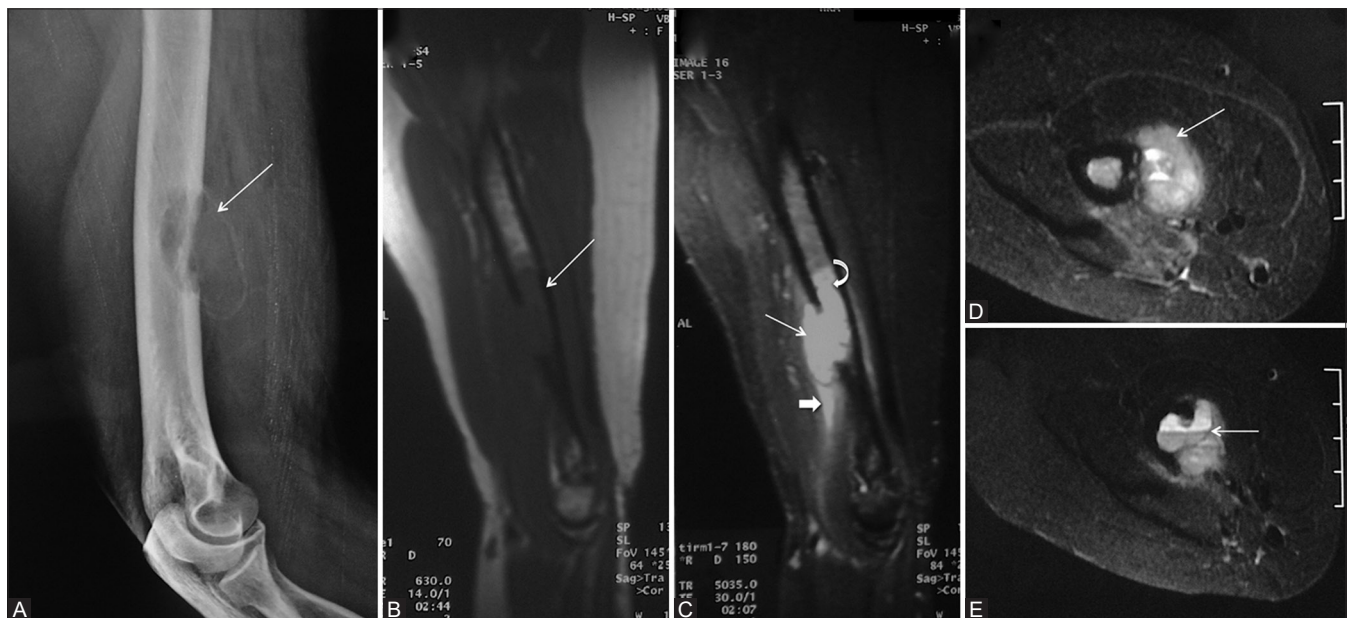

Figure 1 (A-E): A 50-year-old female with swelling in the right forearm (Case 1). (A) Lateral radiograph of arm including elbow showing expansile, eccentric, cortical-based lytic lesion with thin shell of cortex in lower diaphysis of right humerus (arrow) B-D: Sagittal T1W (B), T2W fat saturated (C), Axial T2W fat saturated (D and E) MR images is showing lesion in lower end of humerus which is hypointense on T1W (arrow, B), hyperintense on T2W (arrow, C) associated with a soft tissue component (D) having blood-fluid levels (arrow, E) with extensive marrow (curved arrow, C) and soft tissue edema (block arrow, C)

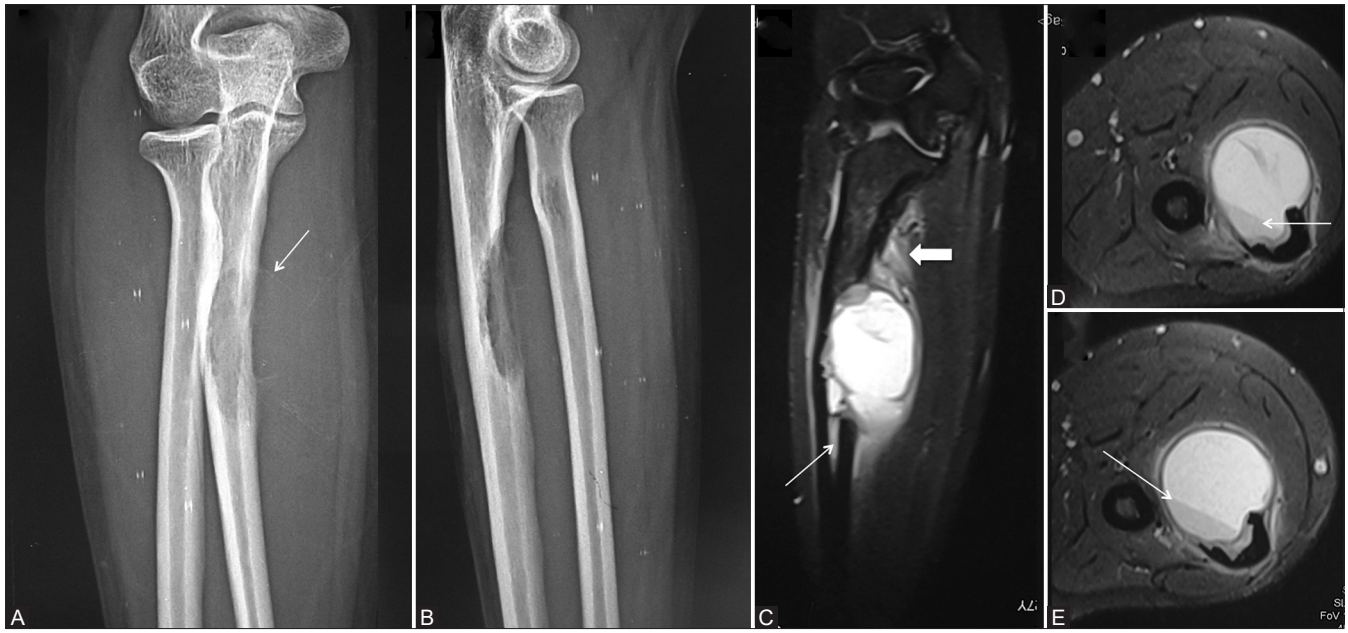


Figure 2 (A-E): A 27-year-old female with painless progressive swelling in the left forearm. (A and B) AP and lateral radiographs of the forearm including elbow joint showing expansile, eccentric lytic lesion with a thin shell of the cortex (arrow) arising from the proximal diaphysis of the ulna. (C-E) Coronal and axial T2W fat-saturated MR images are showing brightly hyperintense lesion having single blood-fluid level (arrow, D and E) associated with bone marrow (arrow, C) and adjacent soft tissue oedema (block arrow, C)

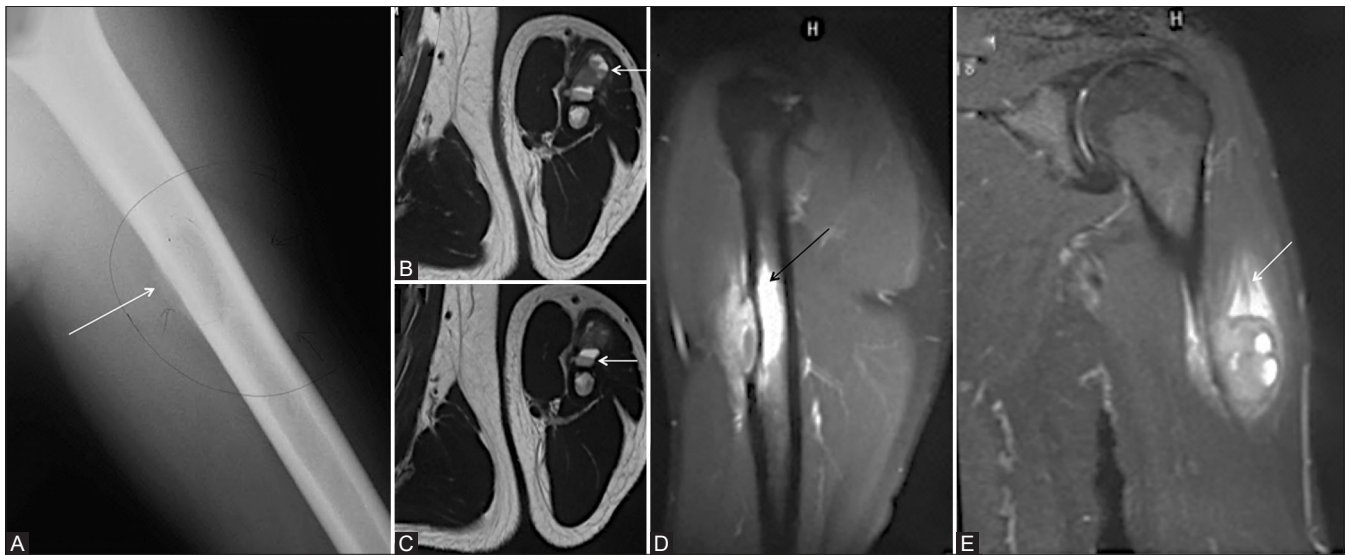


Figure 3 (A-E): A 30-year-old female with swelling in the left arm. AP radiograph of the left arm shows expansile, eccentric lytic lesion in mid-diaphysis of the left humerus (arrow, A). (B-E) Axial T2W, Sagittal T2W fat-saturated, and Coronal T2W fat saturated MR images showing large exophytic soft tissue component with blood-fluid levels (arrow, B and C) with extensive marrow (arrow, D) and soft tissue oedema (arrow, E)

Case 4

A 16-year-old female presented with progressive insidious onset swelling in the right forearm for 1-year duration. Clinically the lesion was painless and bony hard. Radiograph of the right forearm showed an expansile lytic lesion with a thin cortical shell in the radial diaphysis. The MRI for further characterization revealed a large soft tissue component with few blood-fluid levels as well as extensive bone marrow. Soft tissue oedema was also present [Figure 5].

Discussion

sABC is a rare non-neoplastic bone lesion accounting for 3.4%-7.5% of all ABC with a slight female predominance (1:1.5).^[3,6] In all of the four cases, the lesions were located in the diaphysis of the upper extremity long bones [Table 1]. On radiography, the lytic and expansile lesions were eccentrically located, with a cortical-based thin shell. However, the diaphyseal location and the demographic profile was inconsistent with classical

ABC and other differentials were considered. Since none of the patients had any history of renal disease, clinical features of hyperparathyroidism or a known malignancy – these possibilities were discounted. The MRI carried out for further characterization showed distinctive features of sABC with a predominantly solid soft tissue component and interspersed cystic areas showing few blood-fluid levels, which differentiated it from classic ABC. Furthermore, all the four cases showed

bone marrow and soft tissue oedema further ruling out classical ABC.

On radiography, sABC is usually eccentric, lytic and expansile with a variable degree of mineralization. A shell may also be present, mimicking a classic ABC. However, as opposed to classic ABC (which is epi-metaphyseal), sABC is usually meta-diaphyseal and can be cortical, periosteal or juxta-articular in location. While the textbook description of classic ABC is a “soap bubble lytic lesion” sABC in comparison may be non-cystic and up to a third of sABC may be non-expansile. Also, as opposed to classic ABC, multiple blood-fluid levels are not a consistent occurrence in sABC.^[1] Other radiographical differentials for such a lesion would include brown tumours, lytic metastasis from renal cell carcinoma, follicular thyroid carcinoma, telangiectatic osteosarcoma and fibrosarcoma.^[2,4,7,8] An aggressive extra-osseous tumour causing saucerisation of the bone may also be a differential in non-expansile non-cystic sABC on radiography.

MRI is quite instructive in differentiating sABC from conventional ABC. On T1WI, sABC is iso to slightly hyperintense to muscles with a predominant solid soft tissue component appearing heterogeneously hyperintense on T2WI or STIR images. Hypointensity on T2-weighted sequences may be caused by the mineralisation of the solid component. Cystic areas may also be variably present, more commonly seen in larger lesions which may also show blood-fluid levels. Presence of solid areas with blood-fluid level makes differentiating sABC from secondary ABCs a diagnostic dilemma. Presence of blood-fluid level has

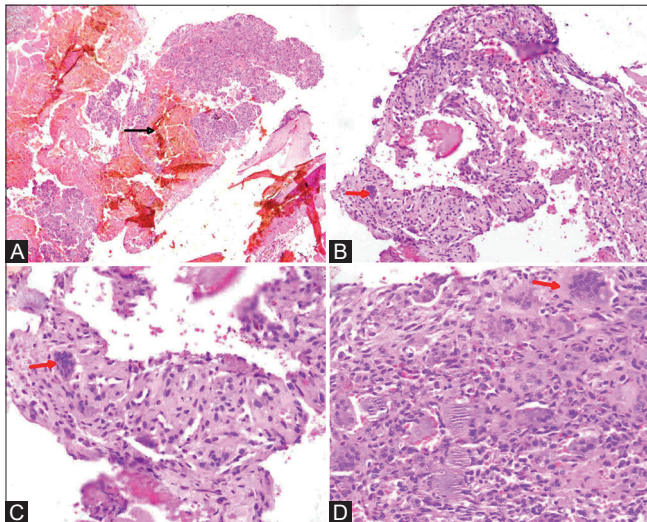


Figure 4 (A-D): (A) Microscopic sections show cystic spaces filled with blood (black arrow) (H and E, $\times 40$). (B) The fibrocollagenous wall containing giant cells (red arrow) forms intervening septa devoid of the endothelium (H and E, $\times 100$). (C and D) Fibrous septae contain bland spindle cells, scattered as well as the focal collection of osteoclastic giant cells (red arrow) (H and E, $\times 200$)

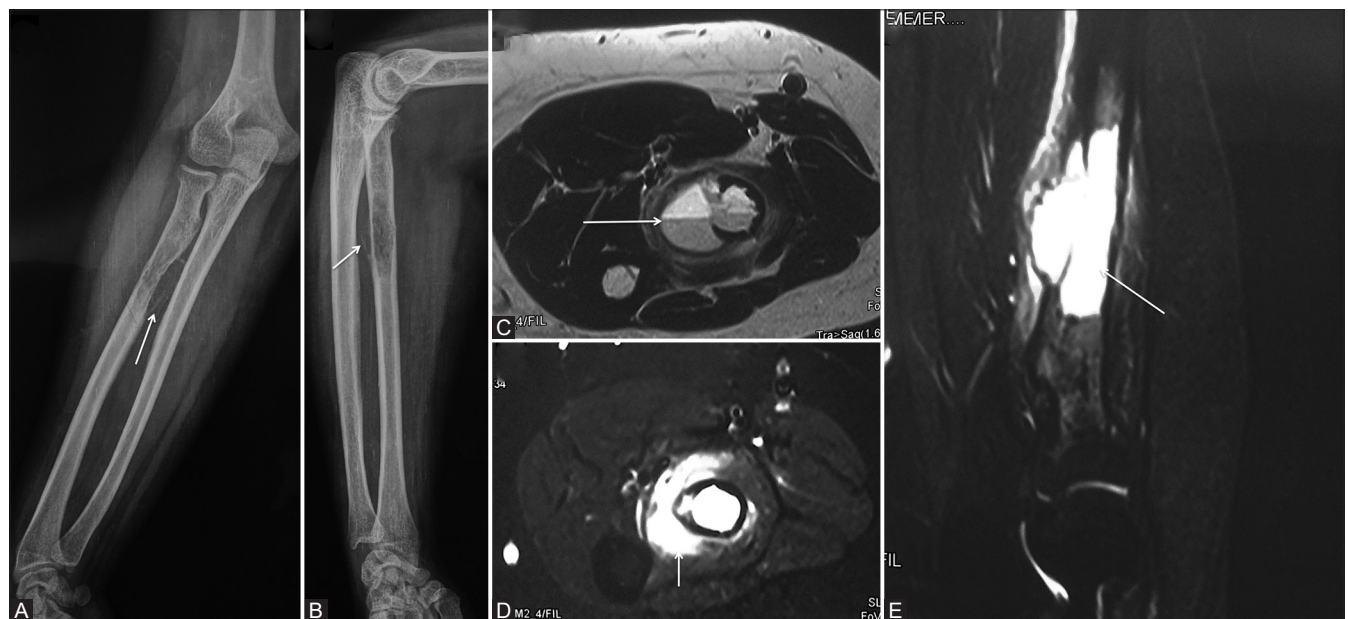


Figure 5 (A-E): A 16-year-old young female with swelling in the right forearm. (A and B) AP and lateral radiographs of the forearm showing expansile, eccentric cortical based lytic lesion with a thin-shelled cortex arising from the proximal diaphysis of radius (arrow, A and B). (C-E) Axial T2W, Axial T2W fat-saturated and Sagittal T2W fat-saturated MR images showing large exophytic soft tissue component with blood-fluid levels (arrow, C) with extensive soft tissue (arrow, D) and marrow oedema (arrow, E)

been postulated as an indicator of progression towards classical ABC.^[1,3] While conventional ABC shows septal enhancement, sABC shows solid enhancement of the constituent soft tissue.^[2]

Interestingly a characteristic feature of sABC is the extensive surrounding bone marrow and soft tissue oedema, attributed to the inflammatory response incited by the release of prostaglandins and COX-2 isozymes. While this feature is not found in classical-ABC, it can be found in up to 50% of sABC. The extensive surrounding oedema should not be mistaken for aggressiveness of this classically indolent lesion (osteoid osteoma, chondroblastoma, osteoblastoma and eosinophilic granuloma are a few other osseous lesions showing surrounding marrow oedema on MRI).

It is essential to differentiate telangiectatic osteosarcoma (TO) from sABC because of widely different prognosis, management and long-term therapeutic outcomes. sABC though aggressive on radiographs has less bone destruction compared to telangiectatic osteosarcoma (TO). Classically Telangiectatic osteosarcoma (TO) has geographic bone destruction, wide zones of transition and endosteal scalloping. Matrix mineralisation though seen in only 50% of radiographs would suggest a diagnosis of TO over sABC. Demonstration of a calcified matrix on CT or radiographs in the soft tissue component of the tumour would preclude a diagnosis of sABC. Extensive soft tissue involvement and cortical erosion demonstrated on MRI would weigh the diagnosis of TO over sABC.^[9]

Histopathologically [Figure 4], sABC show fibroblast proliferation without significant cellular or nuclear pleomorphism, osteoclast-like giant cells, with foci of calcifying matrix and a variable amount of blood-filled cystic spaces with a predominant fibrocollagenous wall. Though initially considered to be a reactive phenomenon occurring as the result of intraosseous haemorrhage inciting an inflammatory response, identifiable molecular genetics in the form of USP6/CDH11 and USP6/TRE7 translocations has established it as a neoplastic pathology.^[10] While GCRG (whose histology resembles sABC) involves the craniofacial skeleton and short tubular bones, sABC specifically refers to extra-gnathic GCRG which occurs in the long bones and the spine. While sABC of long tubular bones are rare, the bones around knee joint are the favoured sites.^[4]

There is a paucity of literature describing MRI findings of sABC. We recommend performing MRI in any lytic lesion on X-ray which does not fit into the demographic or anatomic profile of classic ABC. Radiologists must be well versed with the imaging appearance and histological appearance of sABC since sABC can be treated conservatively and a majority of sABC undergo spontaneous regression. Surgical resection and curettage with bone grafting are reserved for symptomatic lesions.

Conclusion

Though an eccentric diaphyseal cortical-based thin shelled expansile and lytic osseous lesion of long bones has several aggressive differentials, radiologists must be aware of sABC as a possible benign differential diagnosis. Presence of soft tissue component, marrow and soft tissue oedema (though alarming) with a paucity of blood-fluid levels can suggest sABC as a differential. While a primary biopsy would be essential to rule out a malignant aetiology: a diagnosis of sABC by the pathologist for such a lesion should not catch the radiologist unawares and should direct the clinical team towards less aggressive management of this benign lesion.

Teaching points about sABC

Female predominance.

MC site: Upper extremity.

Usual location within the bone: Diaphysis, eccentric, cortical based.

Characteristic MRI findings: Large soft tissue component with few blood-fluid levels (c.f. conventional ABC), extensive bone marrow and soft tissue oedema.

Declaration of patient consent

The authors certify that they have obtained all appropriate patient consent forms. In the form the patient(s) has/have given his/her/their consent for his/her/their images and other clinical information to be reported in the journal. The patients understand that their names and initials will not be published and due efforts will be made to conceal their identity, but anonymity cannot be guaranteed.

Financial support and sponsorship

Nil.

Conflicts of interest

There are no conflicts of interest.

References

1. Al-Shamy G, Relyea K, Adesina A, Whitehead WE, Curry DJ, Luerssen TG, *et al.* Solid variant of aneurysmal bone cyst of the thoracic spine: A case report. *J Med Case Rep* 2011;5:261.
2. Johnson EM, Caracciolo JT. Solid variant aneurysmal bone cyst in the distal fibular metaphysis: Radiologic and pathologic challenges to diagnosis. *Radiol Case Rep* 2017;12:555-9.
3. Ilaslan H, Sundaram M, Unni KK. Solid variant of aneurysmal bone cysts in long tubular bones: Giant cell reparative granuloma. *Am J Roentgenol* 2003;180:1681-7.
4. Sanerkin NG, Mott MG, Roylance J. An unusual intraosseous lesion with fibroblastic, osteoclastic, osteoblastic, aneurysmal and fibromyxoid elements. "Solid" variant of aneurysmal bone cyst. *Cancer* 1983;51:2278-86.

5. Yamaguchi T, Dorfman HD. Giant cell reparative granuloma: A comparative clinicopathologic study of lesions in gnathic and extragnathic sites. *Int J Surg Pathol* 2001;9:189-200.
6. Song W, Suurmeijer AJ, Bollen SM, Cleton-Jansen AM, Bovée JV, Kroon HM. Soft tissue aneurysmal bone cyst: Six new cases with imaging details, molecular pathology, and review of the literature. *Skeletal Radiol* 2019;48:1059-67.
7. Matcuk GR, Chopra S, Menendez LR. Solid aneurysmal bone cyst of the humerus mimics metastasis or brown tumor. *Clin Imaging* 2018;52:117-22.
8. Singh A. Solid variant of aneurysmal bone cyst masquerading as malignancy. *J Clin Diagn Res* 2017;11:ED35-6.
9. Discepola F, Powell TI, Nahal A. Telangiectatic osteosarcoma: Radiologic and pathologic findings. *Radio Graphics* 2009;29:380-3.
10. Agaram NP, LeLoarer FV, Zhang L, Hwang S, Athanasian EA, Hameed M, *et al.* USP6 gene rearrangements occur preferentially in giant cell reparative granulomas of the hands and feet but not in gnathic location. *Hum Pathol* 2014;45:1147-52.