

Clinico-Dermoscopic Pattern of Beard Alopecia Areata: A Cross-Sectional Study

Abstract

Background: Alopecia areata (AA) is an autoimmune condition affecting hair-bearing regions of the body. Few studies worldwide have focused exclusively on beard alopecia areata (BAA). **Aims:** To describe the clinical associations, comorbidities, and dermoscopy of BAA. **Materials and Methods:** Forty-six patients with BAA were recruited for this hospital-based cross-sectional study. Patients with disease onset of less than 1 month, patches showing extension, and appearance of new patches within the past 1 month were grouped under active disease. Dermoscopy was performed using handheld polarized dermoscope. Chi-square test was applied to know the various associations. *P* value <0.05 was considered statistically significant. STATA 11.2 was used for analysis of data. **Results:** The mean age was 31.07 ± 8.72 years. The majority (50%) belonged to 20–29 age group. Twenty-two (48%) patients had active disease. Fourteen (30.43%) patients had extra-beard manifestation of AA. Statistically significant association was noted between active disease and extra-beard manifestation (*P* = 0.034). Diabetes mellitus and hypertension were noted in one and three patients, respectively. Alcohol abuse was noted in six patients and smoking in five patients. Dermoscopic findings such as black dots, short vellus hair, tapering hair, nonfollicular white dots, regrowing hair, yellow dots, and black dots were similar to findings noted in AA. Uncommon findings such as peripilar sign, i-hair, perifollicular hemorrhage, and tulip hair were observed in BAA. **Limitations:** Small sample size, lack of follow-up. **Conclusion:** Trichoscopy of BAA may reveal newer nonfollicular findings, in addition to the follicular findings already described in literature for AA.

Keywords: Alopecia areata, alopecia barbae, beard, dermoscopy, trichoscopy

Introduction

Alopecia areata (AA) is an autoimmune-mediated T-cell attack on hair follicles resulting in patchy hair loss leading to unsightly appearance.^[1] With a prevalence rate of upto 0.2%, the lifetime risk of developing AA stands at 2%.^[2,3]

Although it can affect any hair-bearing region of the body, it is particularly noticeable when it involves cosmetically important areas such as the scalp, moustache, eyebrows, eyelashes, and beard. Very often, involvement of these sites can lead to psychological disturbances such as embarrassment, low self-esteem, and depression.^[4]

AA affecting the beard in postpubertal men is a distinct clinical entity, often necessitating timely assessment and management. Studies on dermoscopy of beard alopecia areata (BAA) are limited.^[5,6] Hence, this study was conducted to describe

This is an open access journal, and articles are distributed under the terms of the Creative Commons Attribution-NonCommercial-ShareAlike 4.0 License, which allows others to remix, tweak, and build upon the work non-commercially, as long as appropriate credit is given and the new creations are licensed under the identical terms.

For reprints contact: reprints@medknow.com

the clinical associations, comorbidities, and dermoscopy of BAA.

Materials and Methods

This study was conducted in the Department of Dermatology, Venereology and Leprosy of Justice K.S. Hegde Charitable Hospital attached to K.S. Hegde Medical Academy. Institutional ethical committee clearance was obtained prior to the start of this cross-sectional study. Written informed consent was taken from all the participants.

Inclusion criteria: (1) Smooth bald patches of nonscarring alopecia affecting the beard with no clinical evidence of erythema, scale, or crust. (2) Males above 16 years of age. **Exclusion criteria:** (1) Patients who had received treatment for the current episode of BAA in both topical and systemic forms. (2) Patients with alopecia universalis and alopecia totalis. (3) Patients with exclusive scalp, eyebrow, eyelash, or moustache involvement with

How to cite this article: Bhandary DJ, Girisha BS, Mahadevappa BN. Clinico-Dermoscopic pattern of beard alopecia areata: A cross-sectional study. Indian Dermatol Online J 2019;10:644-9.

Received: January, 2019. **Accepted:** March, 2019.

Delanthimar
Joshika Bhandary,
Banavasi
Shanmukha Girisha,
Basanna Nagargund
Mahadevappa

Department of Dermatology,
K.S. Hegde Medical Academy,
Mangalore, Karnataka, India

Address for correspondence:

Dr. Banavasi Shanmukha
Girisha,
Department of Dermatology,
K.S. Hegde Medical Academy,
OPD 4, Deralakatte,
Mangalore, Karnataka, India.
E-mail: drgirishbs@gmail.com

Access this article online

Website: www.idoj.in

DOI: 10.4103/idoj.IDOJ_508_18

Quick Response Code:



no bald patch on the beard region. (4) Clinical mimics of BAA were further excluded on dermoscopy; scarring alopecia was excluded by the presence of follicular openings and trichotillomania (TTM) by the absence of predominance of broken hair of different lengths and trichoptilosis.^[7] Those with disease onset of less than 1 month, patches showing extension, and appearance of new patches within the past 1 month were grouped under active disease. Dermoscopy was performed using a handheld polarized dermoscope (Dermlite DL4; 3Gen Inc., San Juan Capistrano, CA, USA) providing $\times 10$ magnification with the Focus Dial set to position "0." The images were captured with iPhone (iPhone 7; Apple Inc., CA, USA) and were then evaluated as saved photos on computer screen. The images were digitally zoomed up to $\times 20$ magnification while analyzing the findings.

Data was collected on a prestructured proforma regarding age, duration of BAA, activity, triggering event, comorbidities, substance abuse, number of lesions, pattern of alopecia, associated involvement of sites other than beard, and dermoscopic findings.

Statistical analysis of data was carried out using mean and range for continuous variables and frequencies for categorical variables. Chi-square test was applied to look for associations. P value < 0.05 was considered statistically significant. STATA 11.2 (Stata Corp., College Station, TX, USA) was used for analysis of data.

Results

A total of 46 subjects were enrolled in the study. The mean age of our patients was 31.07 ± 8.72 years. The youngest patient was 19 years of age and the oldest was 59 years of age. The majority (50%) of the patients belonged to 20–29 age group. The average duration of BAA prior to presentation was 5.73 ± 9.01 months. Twenty-two (48%) patients had active disease at the time of consultation.

Seven (15.22%) patients had a history of recurrence of AA. One (2.17%) patient had a family history of atopy. None of the patients had a personal history of atopy or family history of AA. Diabetes mellitus and hypertension were noted in one (0.17%) and three (6.52%) patients, respectively. Alcohol abuse was seen in six (13.04%) patients and smoking (10.84%) in five patients.

Twenty-nine (63.04%) patients had more than one alopecic patch, while 17 (36.95%) patients had a single patch [Figures 1 and 2].

Fourteen (30.43%) patients had extra-beard manifestation of AA. Scalp involvement was seen in 13 patients (28.26%), eyebrow and moustache involvement in 3 patients each (6.52%), while eyelash and limb involvement were noted in 2 patients each (4.35%). Of the 13 patients who had concomitant scalp involvement, 8 patients had vertex

involvement, 7 patients had occipital, 5 patients had frontal, and 4 patients had temporal and parietal involvement each. Statistically significant association was present between active disease and extra-beard manifestation ($P = 0.034$).

Four (8.69%) patients had nail findings such as pitting (2), longitudinal striations (1), and longitudinal melonychia (1).

On dermoscopy, the majority showed dermoscopic findings while four patients showed no dermoscopic findings apart from the presence of follicular openings [Figures 3-8]. The most common findings were black dots and short vellus hair noted in 18 (39.13%) patients each [Table 1].

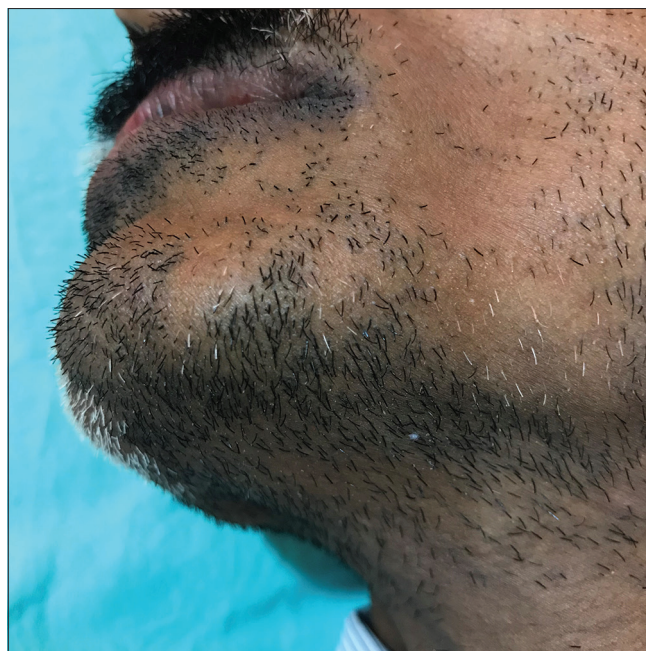


Figure 1: Clinical image of alopecia areata affecting the beard. Note the relative sparing of nonpigmented hair in the alopecic patch

Table 1: Dermoscopic findings in BAA

Dermoscopic findings	No. of patients (%)
Black dots	18 (39.13)
Short vellus hair	18 (39.13)
Tapering hair	14 (30.43)
White dots (nonfollicular)	14 (30.43)
Regrowing hair	14 (30.43)
Yellow dots	13 (28.26)
White dots (follicular oriented)	9 (19.57)
Broken hair	9 (19.57)
Blotchy erythema	8 (17.39)
Peripilar sign	8 (17.39)
Hem-like pigment pattern	5 (11.11)
Vascular network	3
Honeycomb pigment pattern	2
Coudability sign	2
i-hair	1
Perifollicular hemorrhage	1
Tulip hair	1

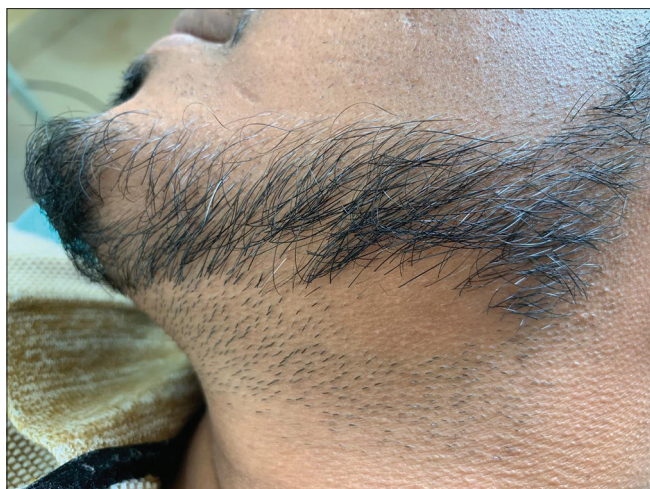

Figure 2: Clinical image of alopecia areata affecting the beard

Discussion

Globally, the incidence of AA varies from 0.57% to 3.8%.^[3,8] In India, it is 0.7% according to a hospital-based study.^[9] The mean age of onset of AA is in the fourth decade of life.^[2] However, in BAA the onset of disease can occur over a wide range of ages.^[6] In our study, it was 31.07 ± 8.72 years, which is in accordance with the mean age of 39.1 years as reported by Saceda-Corralo *et al.*^[5] and other studies with lesser number of BAA cases.^[10,11] It was also noted that 22 of 46 patients had active disease at the time of presentation, and statistically significant association was seen between active disease of BAA and extra-beard manifestation ($P = 0.034$). While there is a possibility of pathogenesis of BAA differing from that of AA, our observation further emphasizes the need to closely monitor these patients for development of new patches in other areas of the body.^[6]

Irrespective of site of involvement, AA is known to be a chronically relapsing condition and hence, recurrence is often reported.^[6,12] In our study, BAA recurrence was noted in 15.22% of patients, while Saceda-Corralo *et al.*^[5] documented recurrence of BAA in 25.5% of their patients.

It is interesting to note that none of our patients had personal history of atopy or family history of AA. In a multicenter study done at Spain, Saceda-Corralo *et al.*^[5] reported that 14.5% of the patients had some form of AA in their family, but none of our patients reported the same. In addition, none of our patients had a personal history of atopy. However, family history of atopy was noted in only 2.17% of the patients in this study.

AA is associated with an increased risk of development of other autoimmune conditions.^[3,13,14] BAA, particularly, has been reported to be associated with asthma, atopic dermatitis, Crohn's disease, hyperparathyroidism, psoriasis, thyroid disease, and vitiligo.^[5] Other case reports show evidence of a possible association of BAA with

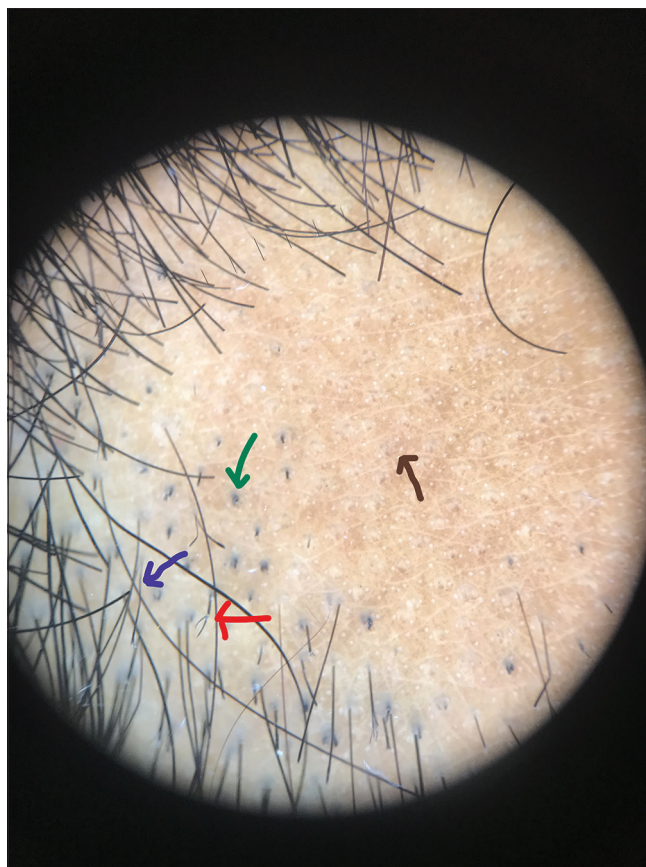


Figure 3: Dermoscopic image ($\times 10$ magnification polarized mode) showing black dots (green arrow), tapering hair (blue arrow), broken hairs with frayed ends (red arrow), and nonfollicular white dots (black arrow)

Helicobacter pylori infection,^[15] hemochromatosis,^[16] and primary cutaneous follicle center lymphoma.^[17] In our study, we noted systemic comorbid conditions such as hypertension and diabetes mellitus in three (6.52%) and one (0.17%) of the patients, respectively. In another study on 1137 Korean patients, it was found that 5.5% of subjects had hypertension and 2.5% had diabetes mellitus.^[18] In yet another study, diabetes mellitus was found in 11.1% of patients with AA.^[19]

Facial involvement is reported to be associated with depression, anxiety, and neurosis.^[20] It is speculated that low quality of life and difficulty in coping with socialization due to visible nature of dermatological conditions could lead to habit of tobacco smoking and alcohol use.^[21,22] Substance abuse like alcohol and smoking were noted in 13.04% and 10.84%, respectively, in our patients.

Extra-beard involvement of alopecic patches in BAA is a known phenomenon; it can either manifest concomitantly at the time of onset of BAA^[6] or may occur anytime in future.^[5] We noticed that 30.43% of our patients had concomitant involvement of sites other than beard, most commonly on the scalp followed by the eyebrow, eyelash, moustache, and limbs.

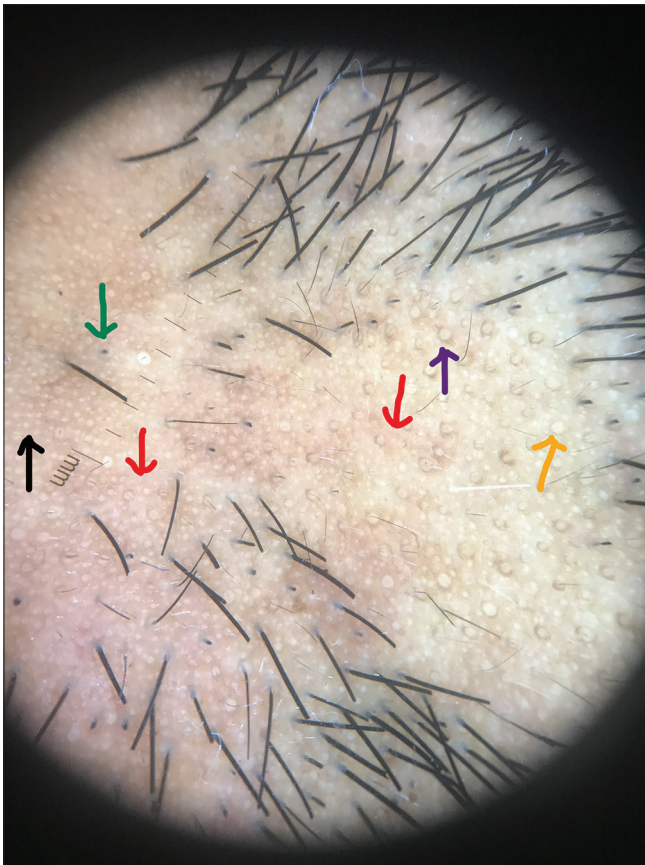


Figure 4: Dermoscopic image ($\times 10$ magnification polarized mode) showing nonfollicular white dots (black arrow), yellow dots (orange arrow), peripilar sign (purple arrow), black dots (green arrow), and blotchy erythema (red arrow)

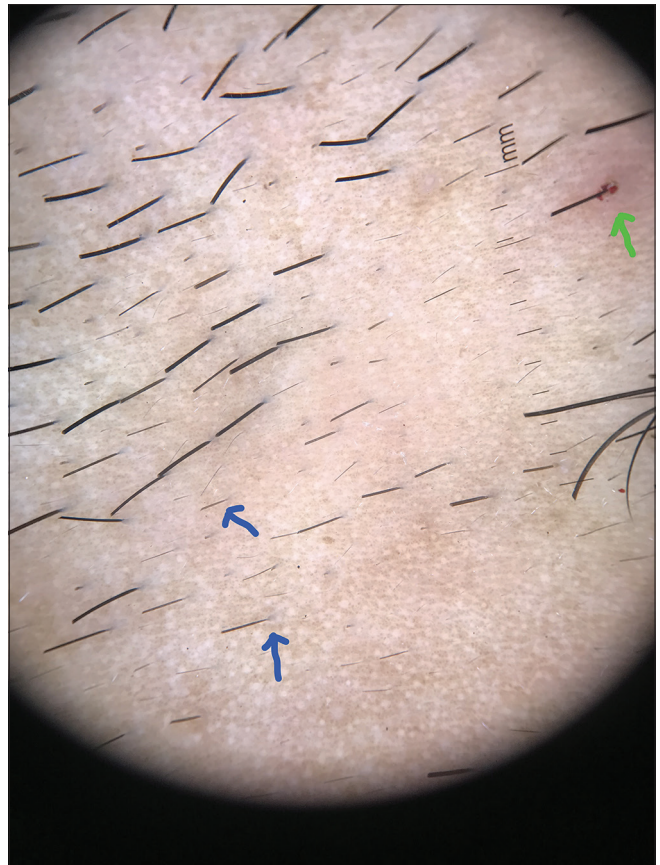


Figure 5: Dermoscopic image ($\times 10$ magnification polarized mode) showing perifollicular hemorrhage (green arrow) and tapering hair (blue arrow)

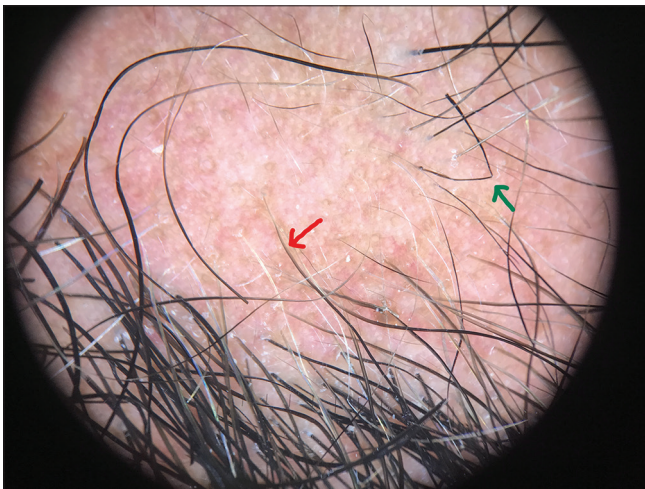


Figure 6: Dermoscopic image ($\times 10$ magnification polarized mode) showing coudability sign (green arrow) and tapering hair (red arrow)

In a retrospective study, it was observed that 45.5% of the patients with BAA subsequently developed scalp AA which was recorded during follow-up.^[5] In addition, AA was also seen to affect eyebrows and arms in their patients.^[5]

Nail findings in exclusive BAA are uncommon.^[6] However, nail changes like pitting, longitudinal striations, and

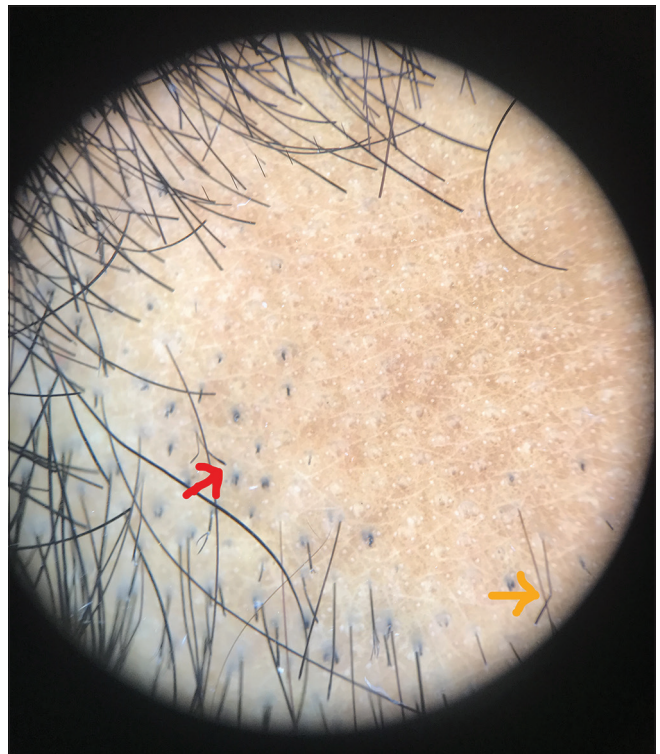


Figure 7: Dermoscopic image ($\times 10$ magnification polarized mode) showing tulip hair (red arrow) and coudability sign (orange arrow)

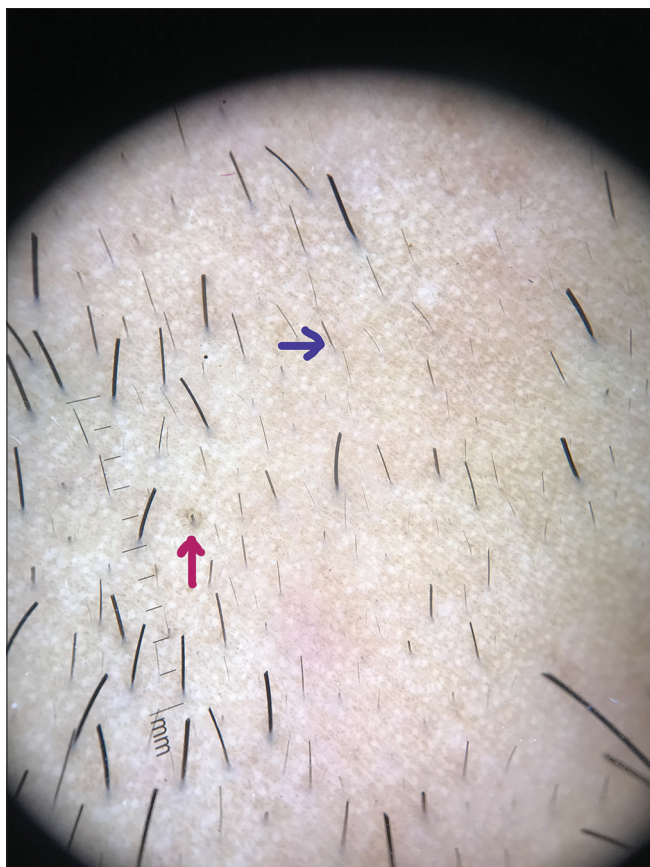


Figure 8: Dermoscopic image (x10 magnification polarized mode) showing ihair (magenta arrow) and tapering hair (blue arrow)

longitudinal melanonychia detected in our study have already been previously described in AA.^[23-25]

Dermoscopic findings in BAA such as black dots, short vellus hair, tapering hair, nonfollicular white dots, regrowing hair, yellow dots, and black dots were similar to findings noted in AA.^[26-29] Uncommon findings such as peripilar sign, i-hair, perifollicular hemorrhage, and tulip hair were also noted.

While follicular microhemorrhage has been described as a diagnostic sign in TTM,^[30] we observed this finding in one patient. Although a rare case of AA coexisting with TTM has been reported in a 6-year-old boy with a patch of hair loss in the occipital area,^[31] such an association in our patient could have been unlikely for three reasons: (1) facial hair is the least likely site affected in TTM,^[32] (2) presence of short vellus hair and tapering hair, and (3) absence of other characteristic dermoscopic features of TTM such as broken hair of different lengths and trichoptilosis.^[32] We are of the opinion that this isolated finding of follicular hemorrhage in our patient could be due to facial hair grooming practice like shaving.

Peripilar sign, which was previously described only in lichen planus pigmentosus, was also seen in 17.39% of our patients. These are believed to represent perifollicular

inflammation.^[33] Interfollicular findings such as blotchy erythema, hem-like pigment pattern, and honeycomb pigment pattern were also seen in our study. Honeycomb pattern is reportedly common in chronic sun-exposed areas and scalp of dark-skinned individuals.^[26,34] We surmise that the polarized filter of the dermoscope might have led to easier detection of these findings in our study. In addition, nonfollicular oriented white dots were seen in 30.43% of patients. These white dots could possibly represent the surface ductal openings of eccrine glands.^[35]

Limitations of the study

This study is limited by its small sample size, lack of follow-up, and Fitzpatrick skin type of the patients. Our patients had only Fitzpatrick skin types IV and V. We did not actively investigate the patients for other systemic comorbidities.

Conclusion

Despite these limitations, our study is the first single center study of the largest scale on male patients with BAA thus far. It is prudent to note that trichoscopy of BAA may perhaps reveal newer nonfollicular findings, in addition to the follicular findings already described in literature for AA. Hence, we recommend further studies in this regard.

Declaration of patient consent

The authors certify that they have obtained all appropriate patient consent forms. In the form the patients have given their consent for their images and other clinical information to be reported in the journal. The patients understand that their names and initials will not be published and due efforts will be made to conceal their identity, but anonymity cannot be guaranteed.

Financial support and sponsorship

Nil.

Conflicts of interest

There are no conflicts of interest.

References

- Hordinsky M, Ericson M. Autoimmunity: Alopecia areata. *J Invest Dermatol Symp Proc* 2004;9:73-8.
- Villasante Fricke AC, Miteva M. Epidemiology and burden of alopecia areata: A systematic review. *Clin Cosmet Investig Dermatol* 2015;8:397-403.
- Gilhar A, Etzioni A, Paus R. Alopecia areata. *N Engl J Med* 2012;366:1515-25.
- Hunt N, McHale S. Reported experiences of persons with alopecia areata. *J Loss Trauma* 2004;10:33-50.
- Saceda-Corralo D, Grimalt R, Fernandez-Crehuet P, Clemente A, Bernardez C, Garcia-Hernandez MJ, *et al.* Beard alopecia areata: A multicentre review of 55 patients. *J Eur Acad Dermatol Venereol* 2017;31:187-92.
- Cervantes J, Fertig RM, Maddy A, Tosti A. Alopecia areata

- of the beard: A review of the literature. *Am J Clin Dermatol* 2017;18:789-96.
7. Jain N, Doshi B, Khopkar U. Trichoscopy in alopecias: Diagnosis simplified. *Int J Trichology* 2013;5:170-8.
 8. Tan E, Tan YK, Goh CL, Chin Giam Y. The pattern and profile of alopecia areata in Singapore – A study of 219 Asians. *Int J Dermatol* 2002;41:748-53.
 9. Sharma VK, Dawn G, Kumar B. Profile of alopecia areata in Northern India. *Int J Dermatol* 1996;35:22-7.
 10. Emre S, Metin A, Caykoylu A, Akoglu G, Ceylan GG, Oztekin A, *et al.* Clinical characteristics and HLA alleles of a family with simultaneously occurring alopecia areata. *Cutis* 2016;97:E30-6.
 11. Eckert MMG, Gundin NL, Crespo RL. Alopecia areata: Good response to treatment with fractional laser in 5 cases. *J Cosmetol Trichol* 2016;2:108.
 12. Sehgal VN, Srivastava G, Aggarwal A, Sethi G, Adhikari T. Alopecia areata in the Indian subcontinent. *Skinmed* 2007;6:63-9.
 13. Muller SA, Winkelmann RK. Alopecia areata. *Arch Dermatol* 1963;88:290-7.
 14. Thomas EA, Kadyan RS. Alopecia areata and autoimmunity: A clinical study. *Indian J Dermatol* 2008;53:70-4.
 15. Campuzano-Maya G. Cure of alopecia areata after eradication of helicobacter pylori: A new association? *World J Gastroenterol* 2011;17:3165-70.
 16. Sredoja Tisma V, Bulimbasic S, Jaganjac M, Stjepandic M, Larma M. Progressive pigmented purpuric dermatitis and alopecia areata as unusual skin manifestations in recognizing hereditary hemochromatosis. *Acta Dermatovenerol Croat* 2012;20:181-6.
 17. Richmond HM, Lozano A, Jones D, Duvic M. Primary cutaneous follicle center lymphoma associated with alopecia areata. *Clin Lymphoma Myeloma* 2008;8:121-4.
 18. You HR, Kim SJ. Factors associated with severity of alopecia areata. *Ann Dermatol* 2017;29:565-70.
 19. Huang KP, Mullangi S, Guo Y, Qureshi AA. Autoimmune, atopic, and mental health comorbid conditions associated with alopecia areata in the United States. *JAMA Dermatol* 2013;149:789-94.
 20. Chu SY, Chen YJ, Tseng WC, Lin MW, Chen TJ, Hwang CY, *et al.* Psychiatric comorbidities in patients with alopecia areata in Taiwan: A case-control study. *Br J Dermatol* 2012;166:525-31.
 21. Chodorowska G, Kwiatek J. Psoriasis and cigarette smoking. *Ann Univ Mariae Curie Sklodowska Med* 2004;59:535-8.
 22. Asholan N, Priya P, Rejani PP. Severity of psoriasis among adult males is associated with smoking, not with alcohol use. *Indian J Dermatol* 2014;59:237-40.
 23. Gandhi V, Baruah MC, Bhattacharya SN. Nail changes in alopecia areata: Incidence and pattern. *Indian J Dermatol Venereol Leprol* 2003;69:114-5.
 24. Chelidze K, Lipner SR. Nail changes in alopecia areata: An update and review. *Int J Dermatol* 2018;57:776-83.
 25. Ferreira SB, Scheinberg M, Steiner D, Steiner T, Bedin GL, Ferreira RB. Remarkable Improvement of nail changes in alopecia areata universalis with 10 months of treatment with tofacitinib: A case report. *Case Rep Dermatol* 2016;8:262-6.
 26. Ross EK, Vincenzi C, Tosti A. Videodermoscopy in the evaluation of hair and scalp disorders. *J Am Acad Dermatol* 2006;55:799-806.
 27. Inui S, Nakajima T, Nakagawa K, Itami S. Clinical significance of dermoscopy in alopecia areata: Analysis of 300 cases. *Int J Dermatol* 2008;47:688-93.
 28. Kibar M, Aktan Ş, Lebe B, Bilgin M. Trichoscopic findings in alopecia areata and their relation to disease activity, severity and clinical subtype in Turkish patients. *Australas J Dermatol* 2015;56:e1-6.
 29. Mane M, Nath AK, Thappa DM. Utility of dermoscopy in alopecia areata. *Indian J Dermatol* 2011;56:407-11.
 30. Ise M, Amagai M, Ohyama M. Follicular microhemorrhage: A unique dermoscopic sign for the detection of coexisting trichotillomania in alopecia areata. *J Dermatol* 2014;41:518-20.
 31. Brzezinski P, Cywinska E, Chiriack A. Report of a rare case of alopecia areata coexisting with trichotillomania. *Int J Trichol* 2016;8:32-4.
 32. Ankad BS, Naidu MV, Beergouder SL, Sujana L. Trichoscopy in trichotillomania: A useful diagnostic tool. *Int J Trichol* 2014;6:160-3.
 33. Miteva M, Tosti A. Hair and scalp dermatoscopy. *J Am Acad Dermatol* 2012;67:1040-8.
 34. de Moura LH, Duque-Estrada B, Abraham LS, Barcaui CB, Sodre CT. Dermoscopy findings of Alopecia areata in an African-American patient. *J Dermatol Case Rep* 2008;2:52-4.
 35. Rudnicka L, Rakowska A, Olszewska M. Trichoscopy: How it may help the clinician. *Dermatol Clin* 2013;31:29-41.