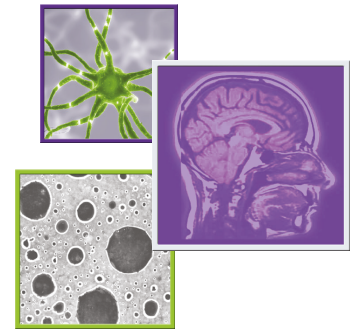


The role of chemotherapy in the treatment of central neurocytoma

Margaret O Johnson^{*1} , John P Kirkpatrick², Mallika P Patel³, Annick Desjardins¹, Dina M Randazzo¹, Henry S Friedman¹, David M Ashley¹ & Katherine B Peters¹

¹Department of Neurosurgery, Duke University Hospital, Durham, NC 27710, USA

²Radiation Oncology, The Preston Robert Tisch Brain Tumor Center, Duke University Medical Center, Durham, NC 27710, USA

³Department of Pharmacy, Duke University Hospital, Durham, NC 27710, USA

*Author for correspondence: Tel.: +919 684 5301; Fax: +919 684 6674; margaret.o.johnson@duke.edu

Aim: Central neurocytoma (CN) is a rare WHO grade II central nervous system (CNS) tumor. This is an update on chemotherapeutic agents used in its treatment. **Patients & methods:** An institutional review board-approved, chart review of patients seen at our institution resulted in a single case treated with chemotherapy and is herein included. We proceeded with a comprehensive literature review. **Results:** We identified 18 citations, representing 39 cases of adult and pediatric CN treated with chemotherapy. With the addition of our single case, the total number of recurrent CN patients treated with temozolomide (TMZ) is nine. **Conclusion:** There exists marked heterogeneity in chemotherapy used to treat CN. TMZ is incorporated into treatment regimens in the setting of tumor recurrence: its role merits further study.

First draft submitted: 2 July 2019; Accepted for publication: 2 September 2019; Published online: 5 November 2019

Keywords: atypical neurocytoma • central neurocytoma • chemotherapy • drug therapy • neurocytoma • radiosensitizer • temozolomide • therapy

Central neurocytoma (CN) is a rare WHO (Geneva, Switzerland) grade II central nervous system (CNS) tumor with a mostly favorable prognosis. Given its rarity, its management is typically described in relatively small case series. CNs are glioneuronal tumors, most commonly occurring in the lateral and third ventricles and often present with hydrocephalus. Treatment includes maximal safe surgical resection, but management with radiation therapy has also been well documented. However, in cases that are not amenable to surgical intervention or that exhibit more aggressive behavior, neuro-oncologists have utilized a variety of chemotherapies. The aim of this special report is to provide an exhaustive, yet focused review of chemotherapeutic agents used in the treatment of both pediatric and adult CN.

Background

CN is a neuroepithelial tumor with features of neuronal differentiation. The cell of origin is unknown but may be derived from neuroglial precursor cells [1]. In some instances, there are anaplastic features such as increased mitotic activity, microvascular proliferation and necrosis. These may be referred to as 'atypical' CN. Any CN with a Ki67 proliferation index of ≥ 2 or 3% is considered atypical [1]. Anaplastic histology has not been definitively associated with poorer prognosis. However, a mitotic count of ≥ 3 has been associated with increased rates of recurrence [2,3].

Molecular genetics of CN are not yet well characterized. A transcriptomic evaluation of CN showed overexpression of genes in the Wnt/B-catenin and sonic hedgehog signaling pathways [4]. There is growing interest in the potential role of Wnt signaling in malignant glioma pathogenesis and how it could be targeted therapeutically [5]. However, little is known about genetic drivers as potential therapeutic targets for CN. At present, there are no published reports of CN preclinical models.

There are no consensus guidelines for systemic chemotherapy in the treatment of CN. However, the role of surgery and radiation are better established. Maximal safe resection is the most common first-line therapy choice and, in the setting of subtotal resection (STR) and/or an elevated MiB index, there may be an indication for adjuvant radiotherapy (RT). Stereotactic radiosurgery (SRS) is recommended as a salvage treatment modality

for small recurrent tumors [6]. Given the lack of consensus guidelines and clinical trials on the role of systemic chemotherapy for CN, case reports and series serve as the main source of information for guidance on chemotherapy regimens and their success. These case reports are heterogeneous with regard to the type(s) of chemotherapy and timing of initiation (i.e., upfront treatment vs salvage therapy).

Lack of guidelines prompted our own retrospective institutional review, which identified only a single case of CN treated with chemotherapy. We proceeded with a critical review of the literature, where we identified multiple case reports of chemotherapeutic agents used to treat CN and updated the work of Leenstra *et al.* and Buchbinder *et al.* who previously summarized the use of chemotherapy in CN [2,7].

The introduction of temozolomide (TMZ) into the treatment regimens of CN was first reported in 2008 [8,9]. TMZ, an oral alkylating chemotherapy, was approved by the US FDA in 2005 for the treatment of adult patients with newly diagnosed glioblastoma concomitantly with radiotherapy, then further as adjuvant treatment. TMZ is employed as a radiosensitizer (i.e., an agent that when delivered with radiation improves the efficacy of radiotherapy), in addition to its role as an antineoplastic agent. It has become ubiquitous in the treatment of high-grade astrocytic tumors, both upfront and in the setting of tumor recurrence. Given its relatively favorable side effect profile, low risk of hematologic toxicity and capacity to penetrate the blood–brain barrier, neuro-oncology providers utilize TMZ with varying efficacy in the management of multiple brain tumor types including, but not limited to, ependymoma, primary CNS lymphoma, meningioma, prolactinoma and brain metastases. This special report devotes particular attention to the use of TMZ in the treatment of CN.

Patients & methods

We conducted a retrospective, institutional review board-approved, chart review of adult brain tumor patients seen at Duke University Medical Center (NC, USA) between 2004 and 2016 in order to identify treatment patterns in rare CNS tumors, including CN. MRI and pathology reports were reviewed and confirmed the diagnosis of all patients with CN. Each chart was reviewed by the first author and data regarding patient demographics, pathology, extent of resection and specific treatment details were extracted.

The PubMed database was systematically searched for studies using the search terms ‘neurocytoma’ and ‘central neurocytoma’. Manuscripts were reviewed in their entirety and were included if they described the use of chemotherapy at any point during the treatment course. Cases of extraventricular neurocytoma were specifically excluded. If a case was not specifically noted as central (versus extraventricular) neurocytoma, it was included and appropriately noted in this review. Preclinical studies and studies not written in English were also excluded. All studies that met inclusion criteria and were published in peer-reviewed journals were included, but published conference abstracts were excluded because they represent only a synopsis of scientific work that is presented in its entirety elsewhere. In order to be as comprehensive as possible, there were no restrictions regarding study design. Eligible studies were selected exclusively by the first author. Given the heterogeneity of the chemotherapy, small sample size and variable reporting of efficacy, a full analysis per preferred reporting items for systematic reviews and meta-analyses (PRISMA) guidelines was not deemed feasible.

Results

Our single institution review identified nine cases of pathologically confirmed CNs. All nine patients were alive as of July 2019. Of these nine patients, only a single case was treated with chemotherapy. This single patient, aged 40 at the time of diagnosis, was initially treated with gross-total resection (GTR). Given an elevated proliferative index (MiB1 = 20%), surgery was followed by 6 weeks of fractionated conformal RT (54 Gy to the resection bed plus margin). Approximately 6 years and 10 months later, she experienced recurrence and was treated with repeat GTR followed by TMZ 75 mg/m² and daily concurrent radiation for 5.5 weeks (50.4 Gy total in 1.8 Gy daily to the resection cavity and ependymal surfaces at risk via image-guided SRS). There was substantial overlap in the RT fields between the initial and salvage RT treatments. As of July 2019, 6 years and 9 months after first recurrence and almost 14 years after diagnosis, the patient remains clinically and radiographically stable. The patient’s neurocognitive testing demonstrated robust memory for contextual verbal information. However, there was notable impairment in visual memory, reduced processing speed and increased distractibility. The patient is still able to work part-time as an esthetician.

The subsequent literature search identified 18 citations reporting treatment of CN with chemotherapy (Table 1). These 18 references represent a total of 39 cases of both adult and pediatric CN. Chemotherapy was used as both an initial treatment and in the setting of recurrence. There was remarkable heterogeneity in chemotherapeutic regimens.

Table 1. Summary of chemotherapies used in the treatment (initial and at recurrence) of central neurocytoma.

Study (year) [Ref.]	Patients treated (N)	Age (y)/sex at diagnosis	Initial vs at recurrence	Chemotherapy
Louis (1990) [10]	2	17/M, 26/F	Initial	Cyclophosphamide and cisplatin ^{§,¶,♯}
Dodds (1997) [11]	1	15/M	Initial	Four 28-day cycles of: carboplatin (500 mg/m ²) D1–2 of week 1; etoposide (100 mg/m ²) D1–3 of week 1 and week 3; ifosfamide (3 g/m ²) D1–3 of week 3
Eng (1997) [12]	2	22/F, 22/F	Recurrence	Etoposide (60 mg/m ²) three-times per day; cisplatin (30 mg/m ²) D1–3; cyclophosphamide (1 g), D3 ^{§,♯}
Schild (1997) [13]	4	Unknown	Initial	Lomustine ^{§,¶,♯} Lomustine and cisplatin ^{§,¶,♯} Lomustine and carmustine ^{§,¶,♯} Lomustine and vincristine ^{§,¶,♯}
Sgouros (1998) [14]	1	19/F	Recurrence	Carboplatin ^{§,¶,♯}
Brandes (2000) [15]	3	43/F, 61/M, 22/F	Recurrence	Three or five 28-day cycles of: etoposide (40 mg/m ²), D1–4; cisplatin (25 mg/m ²), D1–4; cyclophosphamide (1000 mg/m ²), D4
Kulkarni (2002) [16]	6	21/M, 21/F, 14/F, 45/M, 38/M, 27/F	Initial	Seven to nine cycles of lomustine ^{§,¶,♯}
Von Koch (2003) [17]	1	15/F	Recurrence	Six cycles of: procarbazine hydrochloride (60 mg/m ²) [‡] , D8–21; lomustine (110 mg/m ²), D1; vincristine sulfate (1.4 mg/m ²), D8 and D29a
Coelho Neto (2003) [18]	1	6/M	Recurrence	Etoposide, carboplatin, doxorubicin and cyclophosphamide ^{§,¶,♯}
Ogawa (2006) [19]	2	71/F, 34/M	Initial Recurrence	ACNU ^{§,¶,♯} Cisplatin, etoposide and cyclophosphamide for three cycles ^{§,¶}
Leenstra (2007) [2]	6	25/M, 8/M, 23/F, 5/M, 17/F, 20/M	Initial Initial Initial Recurrence Recurrence	Cisplatin (50 mg/m ²), D1–3; ranimustine (50 mg/m ²), D1 ^{§,♯} Six cycles vincristine, platinum, prednisone ^{§,¶} Five cycles lomustine (200 mg/m ²), D1; carmustine (200 mg/m ²), D1 [§] Four cycles cisplatin (75 mg/m ²), D1; vincristine (1.5 mg/m ²), D7, D14; cyclophosphamide (1000 mg/m ²), D21, D22 [§] Two cycles lomustine ^{§,¶} Seven 28-day cycles etoposide (60 mg/m ²), D1–3; cisplatin (20 mg/m ²), D1–5; cyclophosphamide (500 mg/m ²) D1; four more cycles of same for recurrence; one cycle carboplatin (250 mg/m ²), D1; ifosfamide (1.35 g/m ²), D1–3
Amini (2008) [8]	1	5/M	Initial First recurrence Second recurrence Third recurrence Fourth recurrence	Five 28-day cycles vincristine, cisplatin, alternating with cyclophosphamide [¶] Surgical resection only Imatinib (200 mg/m ² twice daily) for 1 month without response; followed by temozolomide (75 mg/m ² /day) for 34 days with radiation; followed by 28-day cycles of temozolomide (175 mg/m ²) D1–5 [#] Intrathecal liposomalcytarabine (x2 doses) ^{§,¶} and SRS followed by temozolomide 'maintenance' ^{§,¶,♯} Intrathecal liposomal cytarabine (one dose) without response ^{§,¶,♯} ; 3 21-day cycles of topotecan (0.5 mg/m ²), D1–3; carboplatin (3 mg/ml/min), D1–3; ifosfamide (1800 mg/m ²), D1–5; 8 months later thiotepa (300 mg/m ²), carboplatin (500 mg/m ²), topotecan (2 mg/m ²) with autologous peripheral blood stem cell transplant
Jakacki (2008) [†] [9]	1	'Pediatric' (age not reported)/gender not reported	Recurrence	28-day cycle of erlotinib daily [¶] followed by 28-day cycles of: temozolomide (180–200 mg/m ²), D1–5 and erlotinib daily ^{¶,♯}
Buchbinder (2010) [7]	1	1/F	First recurrence Second recurrence Maintenance Third recurrence Maintenance Fourth recurrence	Three cycles of: vincristine (0.05 mg/kg), D1, D8; cisplatin (3.5 mg/kg), D2; etoposide (2.5 mg/kg), D1–3 a; followed by GCSF and 2 28-day cycles of temozolomide D1–5 [¶] Two cycles of: cyclophosphamide (55 mg/kg), D1–2 with MESNA discounted due to side effects ^{§,¶} . Resumed vincristine, cisplatin, etoposide (as above) Three cycles of: ifosfamide (1800 mg/m ²), D1–5; carboplatin (400 mg/m ²), D1–2; etoposide (100 mg/m ²), D1–5 discontinued due to side effects a. One cycle cyclophosphamide and topotecan per Pediatric Oncology Group Protocol 9464 Three 28-day cycles of: carboplatin (17 mg/kg), D0–1; thiotepa (10 mg/kg), D0–1 with stem cell rescue per Children's Cancer Group Protocol 99703 Eight 28-day cycles of: isotretinoin (8 mg/kg), D1–14; etoposide (3 mg/kg), D1–21 Temozolomide (5 days per week every 2 weeks); irinotecan (every 2 weeks) ^{§,¶,♯}

[†] Neurocytoma (intra vs extraventricular not specified).

[‡] Procarbazine discontinued after two cycles.

[§] Cycle duration not specified.

[¶] Dose not further described.

[#] Number of cycles not further described.

GCSF: Granulocyte colony stimulating factor; Gy: Gray; PCV: Procarbazine, lomustine, vincristine; RT: Radiotherapy; SRS: Stereotactic radiosurgery.

Table 1. Summary of chemotherapies used in the treatment (initial and at recurrence) of central neurocytoma (cont.).

Study (year) [Ref.]	Patients treated (N)	Age (y)/sex at diagnosis	Initial vs at recurrence	Chemotherapy
Hallock (2011) [20]	1	>18/F	Recurrence	PCV for three cycles followed by temozolomide ^{‡,§,¶,♣}
Stapleton (2012) [21]	1	3/M	Initial	Six of eight planned cycles of: vincristine and carboplatin per Children's Oncology Group low grade glioma protocol A9952 (regimen A)
Mozes (2014) [22]	1	40/M	Recurrence	28-day cycle of: temozolomide (200 mg/m ²) 'five-times per week' with RT dose of 22.5 Gy. Followed by 28-day cycles of temozolomide (200 mg/m ²) ^{‡,§,¶,♣}
Imber (2016) [6]	4	Not reported	Recurrence	Lomustine × six cycles ^{‡,§,¶,♣} Temozolomide ^{‡,§,¶,♣} Temozolomide ^{‡,§,¶,♣} Surgery plus temozolomide ^{‡,§,¶,♣}

† Neurocytoma (intra vs extraventricular not specified).
‡ Procarbazine discontinued after two cycles.
§ Cycle duration not specified.
¶ Dose not further described.
♣ Number of cycles not further described.
GCSF: Granulocyte colony stimulating factor; Gy: Gray; PCV: Procarbazine, lomustine, vincristine; RT: Radiotherapy; SRS: Stereotactic radiosurgery.

Table 2. Summary of temozolomide used in the treatment of central neurocytoma.

Study (year) [Ref.]	Initial vs at recurrence	Treatment	Number treated patients	Adult/pediatric	Response to treatment
Amini (2008) [8]	Recurrence (second and third)	Second recurrence: temozolomide (75 mg/m ² /day) for 34 days with radiation; followed by 28-day cycles of temozolomide (175 mg/m ²) D1-5 [‡] Third recurrence: intrathecal liposomal cytarabine (x2 doses) ^{‡,§} and SRS followed by 'maintenance' ^{‡,§,¶,♣}	1	Pediatric	Complete radiographic response and stable disease for 9 months No efficacy reported
Jackacki† (2008) [9]	Recurrence	One 28-day cycle of erlotinib daily [§] followed by 28-day cycles of: temozolomide (180–200 mg/m ²), D1-5 and erlotinib daily ^{§,¶}	1	Pediatric	Stable disease for 19 months
Buchbinder (2010) [7]	Recurrence (first and fourth)	First recurrence: three cycles of: vincristine (0.05 mg/kg), D1, D8; cisplatin (3.5 mg/kg), D2; etoposide (2.5 mg/kg), D1-3 a; followed by GCSF and two 28-day cycles of temozolomide D1-5 [‡] Fourth recurrence: temozolomide (5 days per week every 2 weeks); irinotecan (every 2 weeks) ^{‡,§,¶,♣}	1	Pediatric	Stable disease for 10 months Outcome not reported
Hallock (2011) [20]	Recurrence	PCV for three cycles followed by temozolomide ^{‡,§,¶,♣}	1	Adult	Progression 'shortly after'
Mozes (2014) [22]	Recurrence	One 28-day cycle of: temozolomide (200 mg/'five-times per week' with RT dose of 22.5 Gy. Followed by 28-day cycles of temozolomide (200 mg/m ²) ^{‡,§,¶,♣}	1	Adult	Stable disease for 12 months
Imber (2016) [6]	Recurrence	Temozolomide ^{‡,§,¶,♣} Temozolomide ^{‡,§,¶,♣} Surgery plus temozolomide ^{‡,§,¶,♣}	3	Adult and pediatric	Stable disease for 3 years 'Slow progressive growth' Outcome not reported
Our case	Recurrence	Temozolomide 75 mg/m ² daily × 42 days with concurrent radiation (5040 cGy)	1	Adult	Stable disease for 6 years and 9 months

† Neurocytoma (intra vs extraventricular not specified).
‡ Cycle duration not specified.
§ Dose not further described.
¶ Number of cycles not further described.
GCSF: Granulocyte colony stimulating factor; Gy: Gray; PCV: Procarbazine, lomustine, vincristine; RT: Radiotherapy; SRS: stereotactic radiosurgery.

Of these 18 citations, six reported the use of TMZ either alone or in combination with another chemotherapy. Interestingly, all TMZ use was in the setting of tumor recurrence (Table 2). With the addition of our single case treated with TMZ, the total number of recurrent CN patients treated at some point with TMZ is nine.

The use of TMZ in the treatment of CN was first reported in 2008. Amini *et al.* reported a pediatric case treated at second recurrence with local radiation therapy (50 Gy in 25 fractions over 34 days) and concurrent TMZ (75 mg/m²/day) [8]; this treatment resulted in a complete response. Chemotherapy was continued with TMZ 175 mg/m² daily for 5 days every 28 days. Despite TMZ maintenance therapy, 9 months after the complete response, the patient had disease recurrence. TMZ was restarted after intrathecal liposomal cytarabine and SRS with no clear benefit.

Jakacki *et al.* described a Phase I clinical trial of TMZ used in combination with erlotinib, an EGFR inhibitor for treatment-refractory solid tumors [9]. A single case of pediatric recurrent neurocytoma was included. Of note, the location of the neurocytoma was not specifically stated (central vs extraventricular), nor could we ascertain from the manuscript if the tumor expressed the EGFR. However, we chose to include it in this review. TMZ was dosed at 180–200 mg/m² daily and administered concomitantly on days 1 through 5 of each 28-day cycle of daily erlotinib. The single patient with neurocytoma had stable disease using this combination for 19 months but no further outcomes were reported for this patient.

Buchbinder *et al.* reported a case of an infant with CN treated initially with resection who experienced a disseminated recurrence 2 months later [7]. This patient was treated with high-dose chemotherapy including three cycles of vincristine, cisplatin and etoposide, followed by granulocyte colony stimulating factor with partial radiographic response. She was then given two cycles of TMZ for 5 days of a 28-day cycle. The second disease progression occurred 10 months later. Multiple lines of treatment were subsequently utilized (Table 1), some of which resulted in progression free survival greater than 10 months. Nonetheless, TMZ was again used, this time in combination with irinotecan at the fourth recurrence. Results from this combination regimen were not described.

Hallock *et al.* described a salvage chemotherapy regimen of procarbazine, lomustine and vincristine in an adult [20]. This was ‘switched to TMZ.’ They reported an initial radiographic response and progression shortly after, at which point the patient proceeded with surgical intervention. In this instance, there was no clear benefit from TMZ, nor was there more specific information about the dosing or the rationale for its use.

Mozes *et al.* reported a single case of CN in a 40-year-old initially treated with GTR and local radiotherapy that recurred after 3 years [22]. At recurrence, there was dissemination to the spine which was treated with surgery and total spine radiation. About 7 months later, after further progression in the cervical spine, the patient was treated with TMZ 200 mg/m² daily for 5 days per 28-day cycle, along with focal radiation. This TMZ monotherapy was continued for 12 months until subsequent recurrence.

A total of three patients treated with TMZ at recurrence were reported by Imber *et al.* [6]. Two of the patients were treated with TMZ monotherapy: one had 3 years of tumor stabilization and the other ‘slow progression.’ The third patient had a repeat surgery followed by TMZ, but that outcome was not reported. The dosing regimen was not specifically reported in the manuscript.

Discussion

The role of chemotherapy in the treatment of CN is not well defined. Kulkarni *et al.* hypothesized that neurocytomas typically have a low proliferative index and theoretically, the effect of chemotherapy is minimal [16]. However, some CNs may have elevated proliferative indices both at diagnosis and recurrence, making them more susceptible to the effects of chemotherapy. As demonstrated by the CN cases included in this review, some exhibit more aggressive behavior with multiple recurrences and dissemination throughout the neuroaxis. In these more aggressive cases, it is useful to understand what systemic therapies are most effective. The current evidence is anecdotal at best, as outlined in Tables 1 & 2.

An emerging theme that we identified was the more recent incorporation of TMZ into treatment regimens for CNs (Table 2). TMZ was used in both pediatric and adult patients exclusively in the setting of CN recurrence. We hypothesize that, since the evidence supports initial treatment with maximal safe resection and radiation in the case of STR or elevated proliferative index, chemotherapy may be reserved for ‘salvage’ cases.

In the single case from our institution, we described a patient with recurrent CN treated with repeat resection followed by 6 weeks of concurrent TMZ and reirradiation. Conceptually, TMZ was utilized with concurrent irradiation to exploit its function as a radiation sensitizer. Randomized clinical trials have demonstrated that the addition of TMZ to radiotherapy has led to improved survival in glioblastoma [23]. In 2008, Amini *et al.* 2008 used it similarly in a single pediatric patient and followed it with 5-day TMZ, essentially adapting the Stupp regimen [8,23]. To the best of our knowledge, ours is the first reported adult case of CN treated with TMZ and concurrent radiation.

Identifying radio-sensitizing agents in an ongoing area of interest in glioma. The mechanism of this sensitization in glioma by TMZ has been well described [24,25]. Ionizing radiation induces double-stranded DNA breaks (DSBs) which ultimately leads to cell death. DSBs lead to a DNA damage response. Therefore, a potential for radiation sensitization is to inhibit proteins used in DSB or DNA damage response repair [26].

No case reports of TMZ used concurrently with radiation at initial diagnosis were identified during our systematic literature review. In those cases that warrant radiation at diagnosis (i.e., STR or elevated MiB), it may be worth exploring the role of TMZ with concurrent radiation. However, we acknowledge the absence of preclinical or clinical data necessary to make a strong case. Rare tumors present a unique problem: traditional randomized prospective trials are not feasible. Therefore, consensus guidelines for rare tumor types, like CN, are lacking.

Conclusion

There exists marked heterogeneity in chemotherapy used to treat CNs. This is not surprising given the rarity of the tumor and the lack of consensus guidelines for chemotherapy in its treatment. There is a subjective trend noted that TMZ has been incorporated into treatment regimens in the setting of tumor recurrence. TMZ has become ubiquitous in the treatment of high-grade glioma; however, its merit in the treatment of CN is unclear. Its role warrants further study at the very least.

Future perspective

The study and treatment of rare tumors like CN will remain a challenge for neuro-oncologists. Online web-based surveys aimed at clinicians will identify practice patterns for rare cancers like CN. Data sharing across institutions in order to conduct retrospective analyses of rare primary CNS tumors will become more ubiquitous. The findings from aggregate data will continue to shape treatment paradigms for CN. Finally, in the evolving genomic landscape of cancer, additional actionable therapeutic targets for the treatment of CN will be identified. If this is the case, multinational prospective clinical trials will become essential to developing evidence-based treatment strategies for CN.

Summary points

- There are no consensus guidelines for systemic chemotherapy in the treatment of central neurocytoma (CN).
- The role of surgery and radiation are better established in CN, whereas the role of chemotherapy is limited to small case series.
- Chemotherapy is used predominantly to treat recurrent CNs when further surgery and/or radiation are not feasible.
- CNs may have elevated proliferative indices both at diagnosis and recurrence making them, theoretically, more susceptible to the effects of chemotherapy.
- Based upon our review of all reported adult and pediatric cases, chemotherapeutic regimens to treat CN are heterogeneous.
- We contribute a single case of CN treated with chemotherapy to this review.
- We perceive a recent trend toward incorporating temozolomide in the treatment of recurrent CN, but evidence is anecdotal at best.
- It may be worth exploring the role of temozolomide with concurrent radiation when radiation is indicated for treatment of CN.

Author contributions

M Johnson and K Peters were responsible for study conception and design. M Johnson was responsible for the initial literature search and creation of tables. All authors were responsible for drafting and revision of the manuscript.

Acknowledgments

We would like to acknowledge J Jackman, F McSherry and W Gentry for their contributions in editing.

Financial & competing interests disclosure

This research did not receive any specific grant from funding agencies in the public, commercial or not-for-profit sectors. KB Peters receives research funding from Eisai, Genentech, Merck, VBL Therapeutics, Agios, BioMimetix and Abbvie. A Desjardins also receives research funding from Genentech/Roche, Cellidex, Triphase Accelerator Corp., Lilly, Pfizer, Orbus Therapeutics and Symphogen.

KB Peters serves as advisor/speaker/consultant for Novocure, Agios and Abbvie. A Desjardins serves as advisor/speaker/consultant for Genentech/Roche and Celgene. HS Friedman serves as advisor/speaker/consultant for Genentech/Roche. A Desjardins holds stock/ownership interest with IST GmbH. A Desjardins and HS Friedman hold letters of patent for Oncolytic Polio virus human tumors. The authors have no other relevant affiliations or financial involvement with any organization or entity with a financial interest in or financial conflict with the subject matter or materials discussed in the manuscript apart from those disclosed.

No funded writing assistance was utilized in the production of this manuscript.

Ethical conduct of research

The authors state that they have obtained appropriate institutional review board approval or have followed the principles outlined in the Declaration of Helsinki for all human or animal experimental investigations. In addition, for investigations involving human subjects, informed consent has been obtained from the participants involved.

Open access

This work is licensed under the Attribution-NonCommercial-NoDerivatives 4.0 Unported License. To view a copy of this license, visit <http://creativecommons.org/licenses/by-nc-nd/4.0/>

References

Papers of special note have been highlighted as: ● of interest; ●● of considerable interest

1. Louis DN, Perry A, Reifenberger G *et al.* The 2016 World Health Organization Classification of tumors of the central nervous system: a summary. *Acta Neuropathol.* 131(6), 803–820 (2016).
2. Leenstra JL, Rodriguez FJ, Frechette CM *et al.* Central neurocytoma: management recommendations based on a 35-year experience. *Int. J. Radiat. Oncol. Biol. Phys.* 67(4), 1145–1154 (2007).
- **Summarizes the use of chemotherapy in the treatment of central neurocytoma (CN).**
3. Vasiljevic A, Francois P, Loundou A *et al.* Prognostic factors in central neurocytomas: a multicenter study of 71 cases. *Am. J. Surg. Pathol.* 36(2), 220–227 (2012).
4. Vasiljevic A, Champier J, Figarella-Branger D *et al.* Molecular characterization of central neurocytomas: potential markers for tumor typing and progression. *Neuropathology* 33(2), 149–161 (2013).
5. Mccord M, Mukoyama YS, Gilbert MR, Jackson S. Targeting WNT signaling for multifaceted glioblastoma therapy. *Front. Cell Neurosci.* 11, 318 (2017).
6. Imber BS, Braunstein SE, Wu FY *et al.* Clinical outcome and prognostic factors for central neurocytoma: twenty year institutional experience. *J. Neurooncol.* 126(1), 193–200 (2016).
- **Large single institution historical cohort of CN suggesting adjuvant radiotherapy after subtotal resection may improve progression free survival.**
7. Buchbinder D, Danielpour M, Yong WH, Salamon N, Lasky J. Treatment of atypical central neurocytoma in a child with high dose chemotherapy and autologous stem cell rescue. *J. Neurooncol.* 97(3), 429–437 (2010).
- **Summarizes the use of chemotherapy in the treatment of CN and describes a single case in detail.**
8. Amini E, Roffidal T, Lee A *et al.* Central neurocytoma responsive to topotecan, ifosfamide, carboplatin. *Pediatr. Blood Cancer* 51(1), 137–140 (2008).
- **A pediatric case of CN treated at second recurrence with local radiation therapy and concurrent temozolomide.**
9. Jakacki RI, Hamilton M, Gilbertson RJ *et al.* Pediatric phase I and pharmacokinetic study of erlotinib followed by the combination of erlotinib and temozolomide: a Children's Oncology Group Phase I Consortium Study. *J. Clin. Oncol.* 26(30), 4921–4927 (2008).
10. Louis DN, Swearingen B, Linggood RM *et al.* Central nervous system neurocytoma and neuroblastoma in adults – report of eight cases. *J. Neurooncol.* 9(3), 231–238 (1990).
11. Dodds D, Nonis J, Mehta M, Rampling R. Central neurocytoma: a clinical study of response to chemotherapy. *J. Neurooncol.* 34(3), 279–283 (1997).
- **Demonstrated an unequivocal response to chemotherapy in a single pediatric patient with CN.**
12. Eng DY, Demonte F, Ginsberg L, Fuller GN, Jaeckle K. Craniospinal dissemination of central neurocytoma. Report of two cases. *J. Neurosurg.* 86(3), 547–552 (1997).
13. Schild SE, Scheithauer BW, Haddock MG *et al.* Central neurocytomas. *Cancer* 79(4), 790–795 (1997).
- **One of the larger retrospective cohorts of CN in the literature that concludes postoperative radiotherapy improves local control in cases of subtotal resection.**
14. Sgouros S, Carey M, Aluwihare N, Barber P, Jackowski A. Central neurocytoma: a correlative clinicopathologic and radiologic analysis. *Surg. Neurol.* 49(2), 197–204 (1998).

15. Brandes AA, Amista P, Gardiman M *et al.* Chemotherapy in patients with recurrent and progressive central neurocytoma. *Cancer* 88(1), 169–174 (2000).
16. Kulkarni V, Rajshekhar V, Haran RP, Chandi SM. Long-term outcome in patients with central neurocytoma following stereotactic biopsy and radiation therapy. *Br. J. Neurosurg.* 16(2), 126–132 (2002).
17. Von Koch CS, Schmidt MH, Uyehara-Lock JH, Berger MS, Chang SM. The role of PCV chemotherapy in the treatment of central neurocytoma: illustration of a case and review of the literature. *Surg. Neurol.* 60(6), 560–565 (2003).
18. Coelho Neto M, Ramina R, De Meneses MS, Arruda WO, Milano JB. Peritoneal dissemination from central neurocytoma: case report. *Arq. Neuropsiquiatr.* 61(4), 1030–1034 (2003).
19. Ogawa Y, Sugawara T, Seki H, Sakuma T. Central neurocytomas with MIB-1 labeling index over 10% showing rapid tumor growth and dissemination. *J. Neurooncol.* 79(2), 211–216 (2006).
20. Hallock A, Hamilton B, Ang LC *et al.* Neurocytomas: long-term experience of a single institution. *Neuro Oncol.* 13(9), 943–949 (2011).
21. Stapleton CJ, Walcott BP, Kahle KT *et al.* Diffuse central neurocytoma with craniospinal dissemination. *J. Clin. Neurosci.* 19(1), 163–166 (2012).
22. Mozes P, Szanto E, Tiszlavicz L *et al.* Clinical course of central neurocytoma with malignant transformation—an indication for craniospinal irradiation. *Pathol. Oncol. Res.* 20(2), 319–325 (2014).
23. Stupp R, Mason WP, Van Den Bent MJ *et al.* Radiotherapy plus concomitant and adjuvant temozolomide for glioblastoma. *N. Engl. J. Med.* 352(10), 987–996 (2005).
24. Kil WJ, Cerna D, Burgan WE *et al.* *In vitro* and *in vivo* radiosensitization induced by the DNA methylating agent temozolomide. *Clin. Cancer Res.* 14(3), 931–938 (2008).
25. Zhang M, Chakravarti A. Novel radiation-enhancing agents in malignant gliomas. *Semin. Radiat. Oncol.* 16(1), 29–37 (2006).
26. Kesari S, Advani SJ, Lawson JD *et al.* DNA damage response and repair: insights into strategies for radiation sensitization of gliomas. *Future Oncol.* 7(11), 1335–1346 (2011).