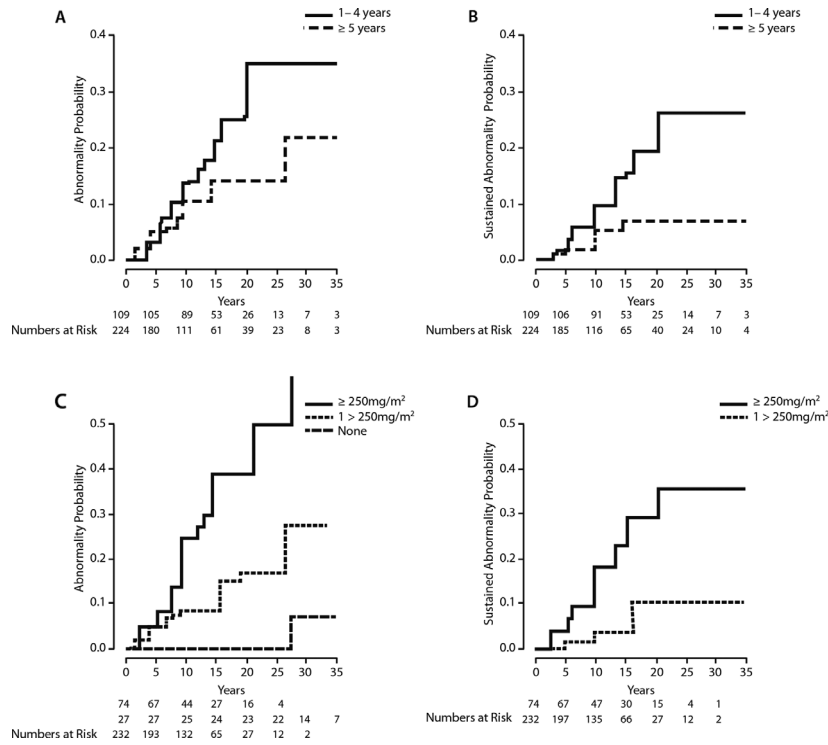
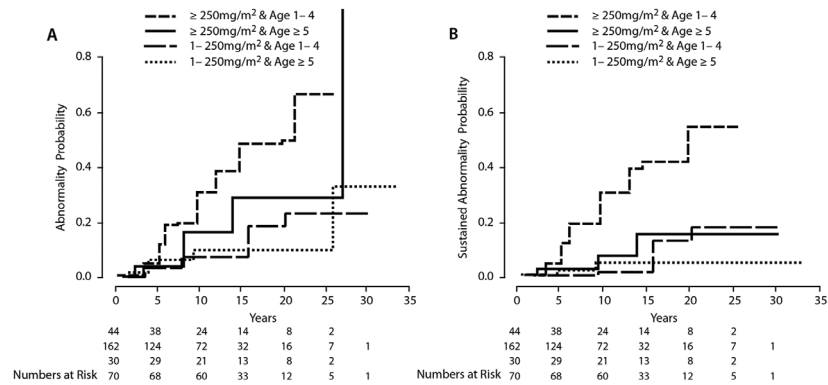


# Erratum: Correction to Ramjaun A, AIDuhaiby E, Ahmed S, et al.

An article that appeared in issue 62(12) [1] had two figure captions that were incorrectly worded. Please see below for the original figures and the corrected captions.



**FIGURE 2** Cumulative incidence of abnormal echocardiography stratified by age at treatment (A – Any abnormal echocardiogram; B – Sustained abnormal echocardiogram) and by anthracycline dose (C – Any abnormal echocardiogram; D – Sustained abnormal echocardiogram).



**FIGURE 3** Cumulative incidence of abnormal echocardiography stratified by age at treatment and by anthracycline dose (A – Any abnormal echocardiogram; B – Sustained abnormal echocardiogram).

**REFERENCE**

1. Ramjaun A, AIDuhaiby E, Ahmed S, et al. Echocardiographic detection of cardiac dysfunction in childhood cancer survivors: how long is screening required? *Pediatr Blood Cancer* 2015; 62:2197-2203.