

World Health Organization Grade III Supratentorial Extraventricular Ependymomas in Adults: Case Series and Review of Treatment Modalities

Abstract

Context: Supratentorial ependymomas and their anaplastic variants are relatively uncommon central nervous system neoplasms that afflict both adults and children. **Aims:** Discuss the clinical and pathological features of patients with anaplastic ependymomas involving an extraventricular supratentorial location and review modalities and options of treatment for those rare tumors. **Settings and Design:** Whereas the treatment algorithm in the pediatric population is well established, however, treatment in the adult population is less defined. Treatment options are exposed through the author's cases and review of the literature. **Subjects and Methods:** In our case series of two adult patients with supratentorial ependymomas World Health Organization (WHO) Grade III (anaplastic variant), patients presented in both cases in the emergency room after having a generalized tonic-clonic seizure at home the first case, and mild hemiparesis the second case. **Results:** Patients underwent surgical treatment, and a gross total resection was achieved in both cases. The histopathological examination revealed a diagnosis of anaplastic ependymoma (WHO Grade III). Both patients had additional radiotherapy, and in the first case, adjuvant platinum-based chemotherapy was administered due to leptomeningeal gliomatosis. **Conclusion:** In our experience, gross total resection was achieved in all patients with supratentorial extraventricular ependymomas WHO Grade III with additional radiotherapy and platinum-based chemotherapy. Patients require initial close serial imaging follow-up. The role of chemotherapy is still uncertain but may be necessary in younger patients and in tumors that behave more like the pediatric ependymomas.

Keywords: Anaplastic ependymomas, extraventricular, supratentorial, surgery, treatment

Introduction

Ependymomas are primary neoplasms of the central nervous system (CNS) that account for about 3%–5% of all adult intracranial gliomas.^[1,2] Ependymomas usually arise from the cells lining the ventricular system and central canal in the spinal cord.^[3–6] In a minority of cases, ependymomas arise from the supratentorial parenchyma and show no continuity with the ventricular system. These ependymoma variants are called ectopic, cortical, lobar, or extraventricular ependymomas. Only a few cases have been reported in the literature.^[7–17] In most of these cases, the tumors were difficult to diagnose before surgery. Although the pediatric population is predisposed to develop tumors below the tentorium, the tumors in adults have a predilection for the supratentorial space.^[17,18] A unique phenomenon that has been noted is the presence of

supratentorial ependymomas distant from the ventricular system within the actual cerebral parenchyma.^[4] In fact, 45%–65% of supratentorial ependymomas have been appreciated in this extraventricular site, and a correlation between distance of the neoplasm from the midline cerebral structures and worsening grade has also been suggested.^[17–19] Roughly, 70% of all ependymomas diagnosed in the pediatric population are histologically benign and are classified as the World Health Organization (WHO) Grade II, <2% are considered to be the WHO Grade I or subependymoma, and the remainder are classified as WHO Grade III or the anaplastic variant.^[20] In adults, however, the majority of supratentorial lesions are classified as WHO Grade III.^[17,19]

In regard to prognostic factors affecting long-term survival and despite the disagreements between different children's cancer groups,^[21–24] a defined treatment algorithm has been established within the

This is an open access journal, and articles are distributed under the terms of the Creative Commons Attribution-NonCommercial-ShareAlike 4.0 License, which allows others to remix, tweak, and build upon the work non-commercially, as long as appropriate credit is given and the new creations are licensed under the identical terms.

For reprints contact: reprints@medknow.com

How to cite this article: Kalfas F, Scudieri C. World Health Organization grade III supratentorial extraventricular ependymomas in adults: Case series and review of treatment modalities. Asian J Neurosurg 2019;14:1157-64.

**Fotios Kalfas,
Claudia Scudieri¹**

Department of Neurological Surgery, Galliera Hospitals, Genova, ¹Department of Neurosurgery and Gamma Knife Radiosurgery, IRCCS San Raffaele Scientific Institute, Vita-Salute University, Milan, Italy

Address for correspondence:

Dr. Fotios Kalfas,
Department of Neurological Surgery, Galliera Hospitals, Via delle Cappuccine, 16128, Genova, Italy.
E-mail: fkalfas@tiscali.it
Dr. Claudia Scudieri,
Department of Neurosurgery and Gamma Knife Radiosurgery, IRCCS San Raffaele Scientific Institute, Vita-Salute University, Via Olgettina, 60 20132, Milan, Italy.
E-mail: claudiascudieri@gmail.com

Access this article online

Website: www.asianjns.org

DOI: 10.4103/ajns.AJNS_239_18

Quick Response Code:



pediatric community.^[23,24] Conversely, there has been no consensus within the neuro-oncologic community regards to the best treatment for adult patients with supratentorial ependymomas and their anaplastic counterparts.^[11,25] Some centers treat adults with supratentorial ependymomas like their pediatric counterparts, and other institutions treat them as patients with any other supratentorial glioma. In this report, the authors discuss the clinical and pathological features of two adult patients with ependymomas (anaplastic variant) involving an extraventricular supratentorial location and discuss modalities and options of the treatment for those rare tumors.

Subjects and Methods

Case reports

Case 1

A 60-year-old female was admitted to our Department of Neurological Surgery because of an episode of partial seizure. At admission, neurological examination was

negative, but the patient referred bifrontal headaches increasing in frequency on a daily basis over the last month. A computed tomographic (CT) scan, revealed a cortical lesion of the left frontal lobe, with surrounding swelling with mass effect, homogeneously enhanced after contrast administration [Figure 1a]. On magnetic resonance imaging (MRI), the lesion was hypointense with the gray matter on the T2-weighted sequences, not well-circumscribed, homogeneously enhanced after gadolinium administration on the T1-weighted sequences with leptomeningeal dissemination [Figure 1b and c]. The neuroradiologic differential diagnosis included metastasis to the brain, neuroepithelial tumor, ganglioglioma, astroblastoma, and meningioma. A left frontal craniotomy was performed, and the mass was resected with MRI-guided navigational assistance. Grossly, the lesion was a firm gray tumor extending to the cortical surface. It was readily distinguishable from adjacent gyri, allowing clear planes of dissection between it and normal

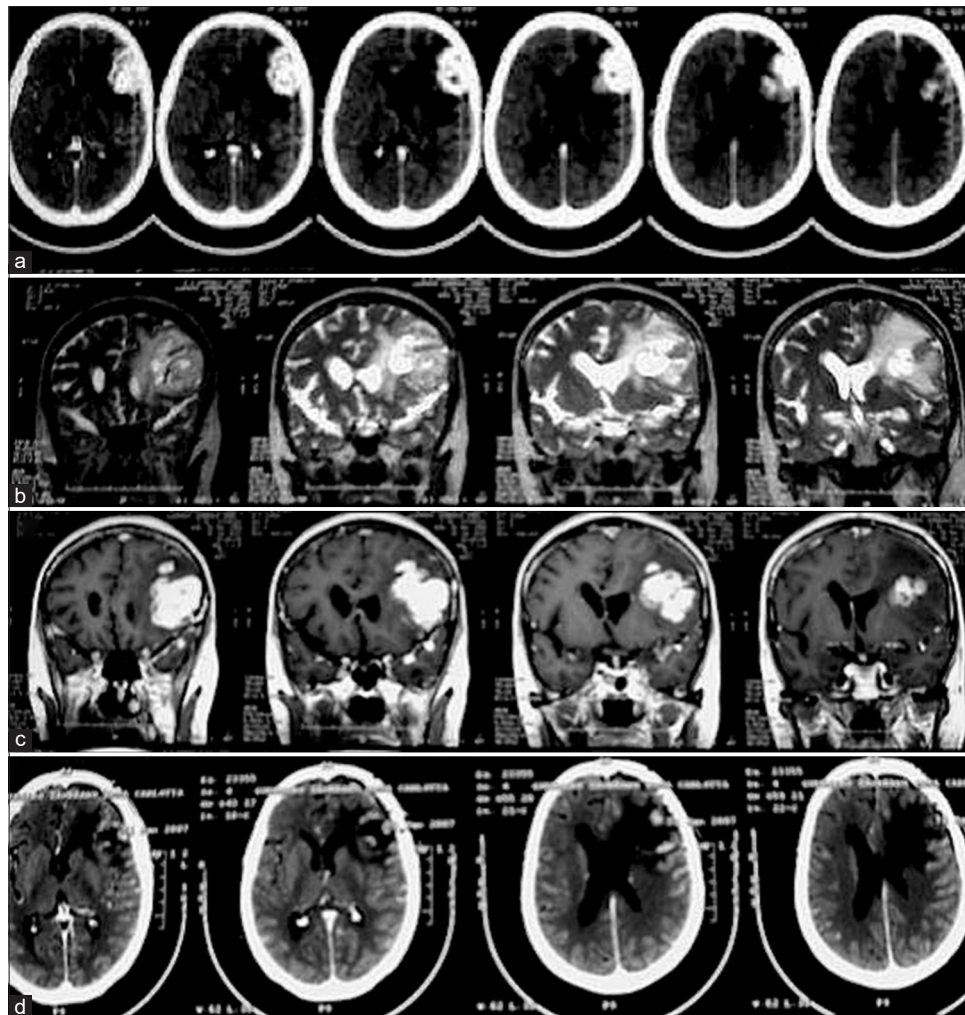


Figure 1: (a-d) Case 1: (a) Contrast-enhanced computed tomographic scan demonstrating a cortical lesion of the left frontal lobe, with surrounding edema with mass effect, homogeneously enhanced. (b) Coronal T2-weighted magnetic resonance imaging demonstrating a hypointense with the gray matter cortical lesion. (c) Coronal T1-weighted magnetic resonance imaging with gadolinium enhancement demonstrating left frontal not-well defined strongly enhancing mass with mass effect and leptomeningeal spread through Sylvian fissure. (d) Postoperative contrast enhanced computed tomographic scan demonstrating gross total excision

brain. A gross total resection was achieved [Figure 1d]. Histologically [Figure 2], the lesion demonstrated the features of Grade III cellular ependymoma (anaplastic ependymoma). Imaging of the remainder of her spinal axis was negative for further disease. Radiation was administered to the tumor bed and associated tumoral margins as adjuvant treatment at a total dose of 6000 cGy over 30 fractions at a dosage of 200 cGy per fraction. Because of the associated leptomeningeal gliomatosis, the patient underwent chemotherapy with five cycles of vincristine, carboplatin, cyclophosphamide (Cytoxan), and etoposide (VP-16). At her 6-month follow-up visit, the neurological examination revealed decreased dexterity in the patient's right hand and some word-finding difficulty. MRI demonstrated recurrence of the disease at the initial location and diffuse leptomeningeal gliomatosis. She and the family opted for palliative care, and she passed away 11 months after diagnosis.

Case 2

A 55-year-old-female was admitted to our Department of Neurological Surgery because of frequent headaches, speech, and deambulatory difficulties. At admission, neurological examination revealed mild right hemiparesis and dysphasia with word-finding difficulty. A CT scan revealed a left hemorrhagic front-insular lesion. On MRI, the lesion was hypointense with the gray matter on the T2-weighted sequences, not well-circumscribed, homogeneously enhanced after gadolinium administration on the T1-weighted sequences with surrounding swelling, mass effect and signs of previous hemorrhage [Figure 3a and b]. The neuroradiologic differential diagnosis included metastasis to the brain and neuroepithelial tumor. A left frontal-temporal craniotomy was performed, and the mass was resected with MRI-guided navigational assistance. Grossly, the lesion was a firm reddish and in part gray tumor. It

was readily distinguishable from adjacent white matter and gyri, allowing clear planes of dissection between it and normal brain. A gross total resection was achieved [Figure 3c and d]. Histologically [Figure 4], the lesion demonstrated the features of Grade III cellular ependymoma (anaplastic ependymoma), with clear cells in a sheet-like, papillary, or columnar to tubular arrangement. In addition, perivascular pseudorosettes were observed in the tumor. Immunohistochemical staining was focally positive for glial fibrillary acidic protein (GFAP) and epithelial membrane antigen. Moreover, the tumor cells had diffuse nuclear pleomorphism, high cellularity, hemorrhage, necrosis, and a relatively high Ki-67 index (approximately 10%). These factors, like in case 1, confirmed a diagnosis of anaplastic ependymoma. Whole-spine MRI was performed for cerebrospinal fluid (CSF) dissemination workup, and there was no evidence of dissemination. Radiation was administered to the tumor bed and associated tumor margins as adjuvant treatment at a total dose of 6000 cGy over 30 fractions at a dosage of 200 cGy per fraction. The patient did not undergo chemotherapy. At her 6-month follow-up visit, neurological examination revealed some residual word-finding difficulty with no other neurological deficits. MRI demonstrated no recurrence of the disease at the initial location. Thirteen months after surgery, the patient presented with persistent moderate headache and worsening of her previous speech deficit.

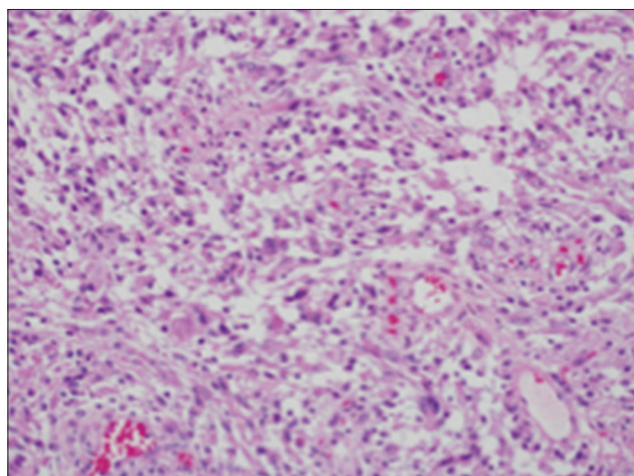


Figure 2: Case 1: Histopathological findings. Hematoxylin and eosin-stained section showing perivascular pseudorosettes (a nuclear zones formed by radially arranged tumor cell processes surrounding central blood vessels)

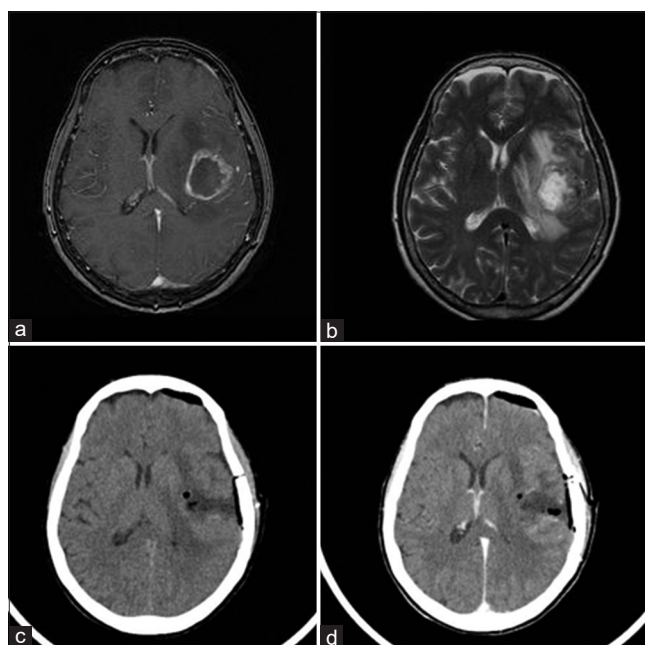


Figure 3: (a-d) Case 2: (a) Axial contrast-enhanced T1-weighted magnetic resonance imaging demonstrating a heterogeneous cystic enhancing mass located intra-axially and in the extraventricular space in the left temporo-insular region. **(b)** Axial T2-weighted magnetic resonance imaging demonstrating previous intratumoral hemorrhage. **(c and d)** Postoperative axial computed tomographic scan **(c)** and **(d)** contrast-enhanced computed tomographic scan demonstrating gross total resection

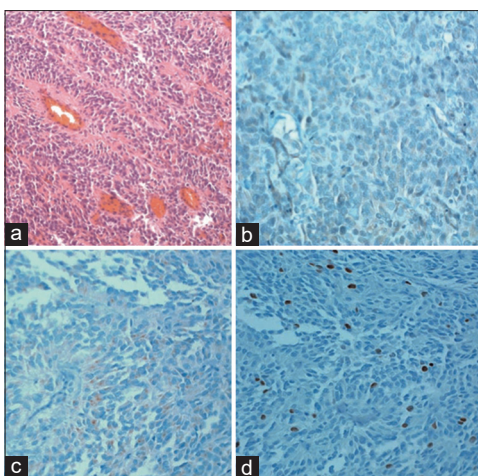


Figure 4: (a-d) Case 2: Histopathological findings. (a) Hematoxylin and eosin-stained section showing increased cellularity with perivascular pseudorosettes. (b-d) Immunohistochemical stainings for glial fibrillary acidic protein, epithelial membrane antigen, and Ki-67 labeling index revealing approximately 10%

A contrast-enhanced magnetic resonance revealed recurrence of the disease at the initial location. The patient refused surgical treatment.

Results

In the literature, only 12 case reports of supratentorial extraventricular anaplastic ependymoma, including the two present cases, have been reported [Table 1]. The mean age of the 12 patients was 41.66 years, and the male-to-female ratio was 7:5. The tumor was located in the frontal lobe in 4 cases, the parietal lobe in 1 case, the temporal lobe in 2 cases, the temporoparietal lobe in 2 cases, the parietooccipital lobe in 1 case, the occipital lobe in 1 case, and the front insular lobe in 1 case. In 8 cases, the tumors were contiguous with the brain surface as cortical ependymoma. In 6 of these cases, intratumoral hemorrhage was observed. Hemorrhage was observed in 5 cases of cortical ependymoma. Finally, only in one case (present case 1), leptomeningeal gliomatosis was observed at the time of the first neuroradiological diagnosis. All patients underwent surgical treatment, and gross-total resection was achieved in eleven of them. Adjuvant radiotherapy was added to the surgical resection in 11 of the twelve reported cases. Only in two cases, patients had platinum-based chemotherapeutic treatment.

Discussion

Supratentorial extraventricular ependymomas in adults are unusual lesions, more commonly found to be of the anaplastic variant.^[16,18] Clinically, these lesions present differently than infratentorial ones in the pediatric population. Infratentorial lesions typically are located intraventricularly, usually manifest with signs and symptoms suggestive of hydrocephalus, and generally are smaller at presentation.^[10,18] Supratentorial lesions generally present with seizures and with focal motor or sensory

deficits and headaches, as was true in our series.^[18,26] These lesions, particularly those that are anaplastic in nature, also tend to present with larger volume.^[10]

Histologically, ependymomas are thought to arise from the ependymal lining within the ventricular system. However, these extraventricular ependymomas arise in a remote area from the ventricular cavities. It is hypothesized that they arise either from fetal rests of ependymal cells that are located at the angle of the ventricles deep within the cerebral parenchyma or from the random distribution of fetal rests of ependymal cells that are located periventricular.^[17,19] Vernet *et al.*^[27] hypothesized that the pathogenesis of supratentorial extraventricular ependymomas could be described as follows: (a) tumors that develop from intraparenchymal or subarachnoid ependymal cysts that result from disorders of migration from the germinal matrix, (b) tumors that represent primitive neuroectodermal tumors that have differentiated extensively along the ependymal lineage, and (c) tumors that might be the result of neoplastic growth within an ectopic ependymal cell and that are the consequence of a migration error.

Anaplastic ependymomas (WHO Grade III) are defined, histologically, by the presence of 2 or more of the following characteristics: 4 mitoses per 10 high-power fields, hypercellularity, endothelial proliferation, and necrosis. On immunohistochemical staining, the phenotypic profiles of anaplastic ependymomas resemble those of ependymoma (WHO Grade II), but GFAP expression may be reduced. In the present cases, these criteria were fulfilled, and the lesions were confirmed as anaplastic ependymomas. Supratentorial extraventricular anaplastic ependymomas are extremely rare, and only 12 cases, including the present 2 cases, have been reported in the literature^[8] [Table 1].

Anaplastic ependymomas are occasionally accompanied by intratumoral hemorrhage. Intracranial tumors that cause hemorrhage are usually high-grade tumors, and hemorrhage is caused by their extensive and abnormal vascularization.^[28] Ernestus *et al.*^[21] reported that the factor that most commonly predisposes tumors to bleed seems to be extensive and abnormal vascularity, and endothelial proliferation or dilated, thin-walled vessels were common findings in ependymal tumors with spontaneous hemorrhages. Intratumoral hemorrhages were observed in 8 of the 12 reported cases of supratentorial extraventricular anaplastic ependymomas, including the current case 2.^[8,29,30]

Supratentorial ependymomas in adults are rare CNS tumors that continue to generate considerable controversy with regard to their clinical management.^[20,24] Several negative prognostic parameters have been identified, such as young age, incomplete tumor resection, histological anaplasia, and supratentorial localization.^[14,31,32] The supratentorial extraventricular ependymomas are more amenable to surgery than their ventricular and infratentorial

Table 1: Supratentorial extraventricular anaplastic ependymoma

Author (year)	Patient age/sex	Location	Haemorrhage	Enhancement on MRI	Treatment modality	Recurrence
Takeshima (2002)	70/female	Frontal	Yes (repeated)	Yes	Surgery: GTR RT: Yes ChT: No	No follow-up
Kojima (2003)	56/female	Temporoparietal	Yes	Yes	Surgery: STR RT: Yes ChT: No	Residual lesion
Moritani (2003)	50/female	Temporal	No	No description	Surgery: GTR RT: Yes ChT: No	Primary site
Miyazawa (2007)	32/male	Parietal	Yes	Yes	Surgery: GTR RT: Yes ChT: No	Primary site
Niazi (2009)	36/female	Frontal	No	Yes	Surgery: GTR RT: Yes ChT: No	No
Niazi (2009)	18/male	Temporoparietal	No	Yes	Surgery: GTR RT: Yes ChT: Yes	Primary site, spine
Hamano (2010)	15/male	Parietooccipital	No	Yes	Surgery: GTR RT: Yes ChT: No	No
Romero (2012)	23/male	Frontal	No	Yes	Surgery: GTR RT: Yes ChT: No	No
Iwamoto (2013)	61/male	Temporal	Yes (repeated)	Yes	Surgery: GTR RT: Yes ChT: No	Spine
Han (2014)	24/male	Occipital	Yes (repeated)	Yes	Surgery: GTR RT: Yes ChT: No	Cervicomedullary junction, spine
Present case 1	60/female	Frontal	No	Yes	Surgery: GTR RT: Yes ChT: Yes	Primary site
Present case 2	55/female	Front insular	Yes	Yes	Surgery: GTR RT: Yes ChT: No	Primary site

A list of 12 reported cases. MRI – Magnetic resonance imaging, ChT – Chemotherapy, RT – Radiotherapy, GTR – Gross-total resection, SRT – Subtotal resection

counterparts, with the exception of those tumors within eloquent regions of the cerebrum.^[18,33] Although there is no capsule associated with these lesions, there is a definite gradient of cells at their border ranging from tumoral in nature to normal tissue. This appears to be the case in our limited series as well. If gross total resection is to be achieved, resection of gross tumor, along with a wide peritumoral margin, is imperative.^[33]

Ependymomas recur more frequently in the initial location after local failure. Anaplastic ependymomas can disseminate within the CNS without local failure.

Anaplastic ependymomas also have a greater tendency to disseminate into the CSF, resulting in drop metastases. However, according to the recent guideline of the National Comprehensive Cancer Network, adjuvant local field radiation following total or subtotal resection is recommended when spinal MRI and CSF cytology are negative.^[13] In our series, recurrence at the primary site occurred without dissemination and drop metastases after adjuvant local field radiotherapy.

The use of postoperative radiotherapy for the treatment of supratentorial extraventricular ependymomas is

controversial.^[34] Roncaroli *et al.*^[14] concluded that cortically based low-grade supratentorial ependymomas should be treated with surgery alone, given that they are amenable to gross total resection and that they were not prone to local recurrence or leptomeningeal spread. They concluded that postoperative radiotherapy did not play a role in treatment. Unfortunately, their series of three patients did not include any with the WHO Grade III or anaplastic variant. Oya *et al.*^[35] examined a series of 48 patients with ependymomas, both infratentorial and supratentorial, that were treated with external beam irradiation with doses of 40–60 Gy. They found that the 10-year overall and relapse-free survival rates were 47% and 42%, respectively, and that the majority of relapse was at the initial tumor site. They found that tumor grade and extent of surgical resection were important prognostic predictors of survival, as those patients with gross total resection tended to fare better than those with subtotal resections. They also concluded that prophylactic whole spinal axis irradiation was of little utility in those patients with localized supratentorial ependymomas, regardless of tumor grade, due to the low incidence of these tumors seeding the spinal space. Mansur *et al.*^[36] studied a series of 60 patients, 40 with Grade II ependymomas and 20 with Grade III ependymomas; 80% of the tumors were found infratentorially. All patients in the study received postoperative radiotherapy to a median total dose of 50.4 Gy. The 5- and 10-year overall survival rates for all patients were 71.2% and 55%, respectively. Subtotal resection and a supratentorial tumor portended a worse outcome, regardless of tumor type. However, the authors were unable to demonstrate any statistically significant difference between the groups. They observed that half of the ependymoma patients will have disease recurrence so more effective treatments will be needed in the future, and currently, radiotherapy should be considered despite paucity of data. Paulino and Wen,^[37] examined the significance of radiotherapy treatment duration in intracranial ependymoma in a series of 34 patients, 23 of whom had infratentorial tumors and 11 of whom had supratentorial tumors. Those patients who had gross total resection and radiotherapy treatment duration of less than 50 days had a better treatment outcome than those patients who had >50 days of treatment.

Because of the differences between supratentorial and infratentorial ependymomas, it appears that they are two separate and unique disease processes that should not be treated similarly. In the pediatric population, gross total resection appears to be the best prognostic indicator of long-term survival in both WHO Grade II and WHO Grade III lesions.^[17,18,20,33] The authors agree that, in those patients with low-grade or WHO Grade II ependymomas, gross total resection with close surveillance is appropriate; however, we cannot extrapolate this treatment to the anaplastic variants. Because adults with supratentorial

ependymomas generally present at a higher grade than that seen in the pediatric population, any local recurrences will tend to be of a more aggressive nature than the initial tumor at presentation and more likely to present with craniospinal seeding.^[16,18,33] If radiotherapy can prevent this phenomenon, the benefits of adjuvant radiotherapy will outweigh the risks. Thus, we believe that radiotherapy is prudent even after gross-total resection and that an appropriate treatment regimen that does not expose patients to protracted doses of radiation should be implemented. Craniospinal irradiation should be limited to those patients that have documented leptomeningeal spread as evidenced by imaging or confirmed by cytopathological analysis of a sample of CSF.

There has been significant controversy in regard to whether histopathological features of ependymoma assigned at the time of diagnosis relate to long-term survival.^[38,39] In a retrospective review of 31 children, Foreman *et al.*^[38] concluded that there was no correlation between the grade of tumor at diagnosis and long-term survival. This has been reiterated in the literature by other authors;^[17,19,39] however, the diagnosis of the malignant variant is not easy, and the diagnosis varies widely depending on the expertise with ependymomas of the pathologists.^[39] For that reason, it seems that the best prognosticators of long-term survival and local recurrence are the degree and number of mitoses and dense cellularity regardless of the grade assigned at the time of diagnosis.^[38,39] In the present case 1 with leptomeningeal gliomatosis, the mitotic rate and cell density were higher than in case 2, and this correlated with outcome.

Despite ependymomas appear to be chemosensitive *in vitro*, the role of chemotherapy in the treatment of ependymomas is still undefined, due to the absence of a link between a survival advantage and chemotherapy.^[23,37-39] Valera *et al.*^[40] reported single-agent response rates to chemotherapy at 11%, with <5% complete response. Platinum-based chemotherapeutic agents have been in clinical trials for use in pediatric patients, especially for those under the age of 2 years who are not usually treated with radiotherapy because of the long-term cognitive side effects of that treatment modality. Valera *et al.*,^[40] also described the use of platinum-based chemotherapeutic agents in helping to achieve complete surgical resection in a 9-year-old boy with recurrent supratentorial anaplastic ependymoma with good success and a progression-free survival of 4 months. No similar studies have been performed in the adult population. Prospective randomized trials in adults with the use of chemotherapy as is being done with the pediatric population also need to be initiated to obtain a better idea of the benefits of chemotherapy in this patient population. In our limited experience, platinum-based chemotherapy was administered in the case with leptomeningeal gliomatosis; however, disease progression had occurred with local progression, diffuse leptomeningeal gliomatosis and even

though there was no craniospinal seeding, chemotherapy conferred little therapeutic advantage.

Conclusion

Each of the patients in our small case series underwent gross total resection and adjuvant radiotherapy. In one case with leptomeningeal gliomatosis, adjuvant platinum-based chemotherapy was administered. Although our case series is too small to draw firm conclusions, we believe that gross total resection and adjuvant radiotherapy are mandatory in adult patients with anaplastic WHO Grade III supratentorial extraventricular ependymomas. The role of chemotherapy is less defined, but this option should be considered in those patients with anaplastic tumors with an associated elevated mitotic rate, increase cell density and leptomeningeal gliomatosis. Meticulous MRI follow-up of the CNS is mandatory in adult patients with intracranial anaplastic ependymomas, even after gross total removal of the tumor.

Further experience with these tumors in the form of case reports and small clinical groups may further define uniform treatment algorithms, although the limited number of cases will make it unlikely that prospective trials could be completed without the cooperation of multiple institutions. A trial of this form should include morphologic information, proliferative index, and molecular characterization as well as treatment and outcome for developing firm treatment recommendations.

Declaration of patient consent

The authors certify that they have obtained all appropriate patient consent forms. In the form the patient(s) has/have given his/her/their consent for his/her/their images and other clinical information to be reported in the journal. The patients understand that their names and initials will not be published and due efforts will be made to conceal their identity, but anonymity cannot be guaranteed.

Financial support and sponsorship

Nil.

Conflicts of interest

There are no conflicts of interest.

References

- Amirian ES, Armstrong TS, Gilbert MR, Scheurer ME. Predictors of survival among older adults with ependymoma. *J Neurooncol* 2012;107:183-9.
- Metellus P, Barrie M, Figarella-Branger D, Chinot O, Giorgi R, Gouvernet J, *et al.* Multicentric French study on adult intracranial ependymomas: Prognostic factors analysis and therapeutic considerations from a cohort of 152 patients. *Brain* 2007;130:1338-49.
- Barone BM, Elvidge AR. Ependymomas. A clinical survey. *J Neurosurg* 1970;33:428-38.
- Coulon RA, Till K. Intracranial ependymomas in children: A review of 43 cases. *Childs Brain* 1977;3:154-68.
- Mork SJ, Loken AC. Ependymoma: A follow-up study of 101 cases. *Cancer* 1977;40:907-15.
- Swartz JD, Zimmerman RA, Bilaniuk LT. Computed tomography of intracranial ependymomas. *Radiology* 1982;143:97-101.
- Hamano E, Tsutsumi S, Nonaka Y, Abe Y, Yasumoto Y, Saeki H, *et al.* Huge supratentorial extraventricular anaplastic ependymoma presenting with massive calcification – Case report. *Neurol Med Chir (Tokyo)* 2010;50:150-3.
- Han MH, Park KS, Park SH, Hwang JH. Supratentorial extraventricular anaplastic ependymoma presenting with repeated intratumoral hemorrhage. *Brain Tumor Res Treat* 2014;2:81-6.
- Miyazawa T, Hirose T, Nakanishi K, Uozumi Y, Tsuzuki N, Shima K. Supratentorial ectopic cortical ependymoma occurring with intratumoral hemorrhage. *Brain Tumor Pathol* 2007;24:35-40.
- Molina OM, Colina JL, Luzardo GD, Mendez OE, Cardozo D, Velasquez HS, *et al.* Extraventricular cerebral anaplastic ependymomas. *Surg Neurol* 1999;51:630-5.
- Niazi TN, Jensen EM, Jensen RL. WHO grade II and III supratentorial hemispheric ependymomas in adults: Case series and review of treatment options. *J Neurooncol* 2009;91:323-8.
- Ono S, Ichikawa T, Ono Y, Date I. Large supratentorial ectopic ependymoma with massive calcification and cyst formation – Case report. *Neurol Med Chir (Tokyo)* 2004;44:424-8.
- Romero FR, Zanini MA, Ducati LG, Vital RB, de Lima Neto NM, Gabarra RC. Purely cortical anaplastic ependymoma. *Case Rep Oncol Med* 2012;2012:541431.
- Roncaroli F, Consales A, Fioravanti A, Cenacchi G. Supratentorial cortical ependymoma: Report of three cases. *Neurosurgery* 2005;57:E192.
- Nakamizo S, Sasayama T, Kondoh T, Inoue S, Shiomi R, Tanaka H, *et al.* Supratentorial pure cortical ependymoma. *J Clin Neurosci* 2012;19:1453-5.
- Schwartz TH, Kim S, Glick RS, Bagiella E, Balmaceda C, Fetell MR, *et al.* Supratentorial ependymomas in adult patients. *Neurosurgery* 1999;44:721-31.
- Shuangshoti S, Rushing EJ, Mena H, Olsen C, Sandberg GD. Supratentorial extraventricular ependymal neoplasms: A clinicopathologic study of 32 patients. *Cancer* 2005;103:2598-605.
- Mermuys K, Jeuris W, Vanhoenacker PK, Van Hoe L, D'Haenens P. Best cases from the AFIP: Supratentorial ependymoma. *Radiographics* 2005;25:486-90.
- Bunyaratavej K, Shuangshoti S, Tanboon J, Chantra K, Khaoroptham S. Supratentorial lobar anaplastic ependymoma resembling cerebral metastasis: A case report. *J Med Assoc Thai* 2004;87:829-33.
- Ward S, Harding B, Wilkins P, Harkness W, Hayward R, Darling JL, *et al.* Gain of 1q and loss of 22 are the most common changes detected by comparative genomic hybridisation in paediatric ependymoma. *Genes Chromosomes Cancer* 2001;32:59-66.
- Ernestus RI, Schröder R, Klug N. Spontaneous intracerebral hemorrhage from an unsuspected ependymoma in early infancy. *Childs Nerv Syst* 1992;8:357-60.
- Grundy RG, Wilne SA, Weston CL, Robinson K, Lashford LS, Ironside J, *et al.* Primary postoperative chemotherapy without radiotherapy for intracranial ependymoma in children: The UKCCSG/SIOP prospective study. *Lancet Oncol* 2007;8:696-705.
- Jaing TH, Wang HS, Tsay PK, Tseng CK, Jung SM, Lin KL, *et al.* Multivariate analysis of clinical prognostic factors in children with intracranial ependymomas. *J Neurooncol*

- 2004;68:255-61.
24. Kurt E, Zheng PP, Hop WC, van der Weiden M, Bol M, van den Bent MJ, *et al.* Identification of relevant prognostic histopathologic features in 69 intracranial ependymomas, excluding myxopapillary ependymomas and subependymomas. *Cancer* 2006;106:388-95.
 25. Metellus P, Figarella-Branger D, Guyotat J, Barrie M, Giorgi R, Jouvet A, *et al.* Supratentorial ependymomas: Prognostic factors and outcome analysis in a retrospective series of 46 adult patients. *Cancer* 2008;113:175-85.
 26. Van Gompel JJ, Koeller KK, Meyer FB, Marsh WR, Burger PC, Roncaroli F, *et al.* Cortical ependymoma: An unusual epileptogenic lesion. *J Neurosurg* 2011;114:1187-94.
 27. Vernet O, Farmer JP, Meagher-Villemure K, Montes JL. Supratentorial ectopic ependymoma. *Can J Neurol Sci* 1995;22:316-9.
 28. Kojima A, Yamaguchi N, Okui S, Kamiya M, Hirato J, Nakazato Y. Parenchymal anaplastic ependymoma with intratumoral hemorrhage: A case report. *Brain Tumor Pathol* 2003;20:85-8.
 29. Iwamoto N, Murai Y, Yamamoto Y, Adachi K, Teramoto A. Supratentorial extraventricular anaplastic ependymoma in an adult with repeated intratumoral hemorrhage. *Brain Tumor Pathol* 2014;31:138-43.
 30. Takeshima H, Kawahara T, Uchida H, Hirano H, Nakazato Y, Kuratsu J. Brain surface ependymoma with repeated episodes of intratumoral hemorrhage – Case report. *Neurol Med Chir (Tokyo)* 2002;42:166-9.
 31. Boström A, Boström J, Hartmann W, Pietsch T, Feuss M, von Lehe M, *et al.* Treatment results in patients with intracranial ependymomas. *Cent Eur Neurosurg* 2011;72:127-32.
 32. Kawabata Y, Takahashi JA, Arakawa Y, Hashimoto N. Long-term outcome in patients harboring intracranial ependymoma. *J Neurosurg* 2005;103:31-7.
 33. Palma L, Celli P, Mariottini A, Zalaffi A, Schettini G. The importance of surgery in supratentorial ependymomas. Long-term survival in a series of 23 cases. *Childs Nerv Syst* 2000;16:170-5.
 34. Kano H, Niranjana A, Kondziolka D, Flickinger JC, Lunsford LD. Outcome predictors for intracranial ependymoma radiosurgery. *Neurosurgery* 2009;64:279-87.
 35. Oya N, Shibamoto Y, Nagata Y, Negoro Y, Hiraoka M. Postoperative radiotherapy for intracranial ependymoma: Analysis of prognostic factors and patterns of failure. *J Neurooncol* 2002;56:87-94.
 36. Mansur DB, Perry A, Rajaram V, Michalski JM, Park TS, Leonard JR, *et al.* Postoperative radiation therapy for grade II and III intracranial ependymoma. *Int J Radiat Oncol Biol Phys* 2005;61:387-91.
 37. Paulino AC, Wen BC. The significance of radiotherapy treatment duration in intracranial ependymoma. *Int J Radiat Oncol Biol Phys* 2000;47:585-9.
 38. Foreman NK, Love S, Thorne R. Intracranial ependymomas: Analysis of prognostic factors in a population-based series. *Pediatr Neurosurg* 1996;24:119-25.
 39. Schiffer D, Chiò A, Giordana MT, Migheli A, Palma L, Pollo B, *et al.* Histologic prognostic factors in ependymoma. *Childs Nerv Syst* 1991;7:177-82.
 40. Valera ET, Machado HR, Santos AC, de Oliveira RS, Araújo D, Neder L, *et al.* The use of neoadjuvant chemotherapy to achieve complete surgical resection in recurring supratentorial anaplastic ependymoma. *Childs Nerv Syst* 2005;21:230-3.