

Available online at www.sciencedirect.com

ScienceDirect

journal homepage: www.e-jds.com

Correspondence

Clinical evaluation of multiple peri-implant bony defect management by Er:YAG laser-assisted bone regenerative therapy



Conventional mechanical debridement is the main procedure for treating plaque-induced peri-implantitis, such as using plastic/metallic curettes, sand blasting machines, polishing by rubber cup/pumice powder, ultrasonic scalers, and titanium brushes. However, it is difficult to completely remove bacterial plaque with these instruments, especially in the micro-threads area. Recently, use of Er:YAG laser in dental field has increased for periodontal and peri-implantitis therapy,^{1–3} because Er:YAG laser is able to effectively ablate soft and hard tissues as well as calculus, and it can effectively debride the titanium surface with minimal thermal damage under suitable energy output. Meanwhile, the blood clot forming in the superficial areas of grafted bone by Er:YAG laser irradiation without water spray is useful for bone regenerative procedure, which is so called the Er:YAG laser-assisted bone regenerative therapy (Er-LBRT) developed by Taniguchi et al.^{4,5} This case report demonstrated a perspective option for implant surface debridement and simultaneously bone regeneration by Er-LBRT technique without usage of membrane coverage.

The 55-year-old man came to the department of periodontology, Chung Shan Medical University Hospital, with the chief complaint of pain and persistent pus discharge at the #23 implant, which was placed several years ago at a local dental clinic. After periodontal examination and radiographic evaluation, the pocket depths around the #23 and #25 implants were over 12 mm and 8 mm, respectively (Fig. 1A and B). Bleeding on probing and crater-like bony defect were also observed (Fig. 1C). Following local anesthesia and flap elevation, we carefully removed the

granulation tissue and debrided the implant surface using Er:YAG laser (Erwin AdvErLTM, J. Morita Mfg. Co., Osaka, Japan) at 20 Hz and 50 mJ/pulse (Panel setting: 70 mJ/pulse) with water spray in near contact irradiation mode (Fig. 1D). No obvious thermal damage was noted on the implant surface after debridement (Fig. 1E). Then, bovine bone mineral (InterOss®, SigmaGraft) with blood was mixed and grafted into the bony defect to the crest of implant fixture platform (Fig. 1F). The blood clot forming procedure was performed by Er:YAG laser irradiation without water spray under non-contact mode (Fig. 1G), and then the flaps were sutured. After one-year follow-up, the soft tissue healing was favorable and the pocket depth reduced to 3 mm without bleeding on probing (Fig. 1H), and the bone-like dense tissue was evident around the implant surface and the original bone defects were successfully repaired under radiographic examination after one-year follow-up (Fig. 1I).

Er:YAG laser is a very useful instrument for granulation tissue and calculus removal on the implant surface without obvious thermal change under a suitable energy output with water spray. Moreover, the blood clot forming with grafted bone using ErLBRT procedure simplified the clinical procedure because the coagulation of blood could stabilize the grafted bone material following irradiation without water spray.^{4,5} The result of this case indicates that Er-LBRT technique is useful and effective for the management of multiple peri-implant bony defects. However, further studies are required to compare the difference between membrane coverage and this Er-LBRT procedure.

<https://doi.org/10.1016/j.jds.2019.07.001>

1991-7902/© 2019 Association for Dental Sciences of the Republic of China. Publishing services by Elsevier B.V. This is an open access article under the CC BY-NC-ND license (<http://creativecommons.org/licenses/by-nc-nd/4.0/>).

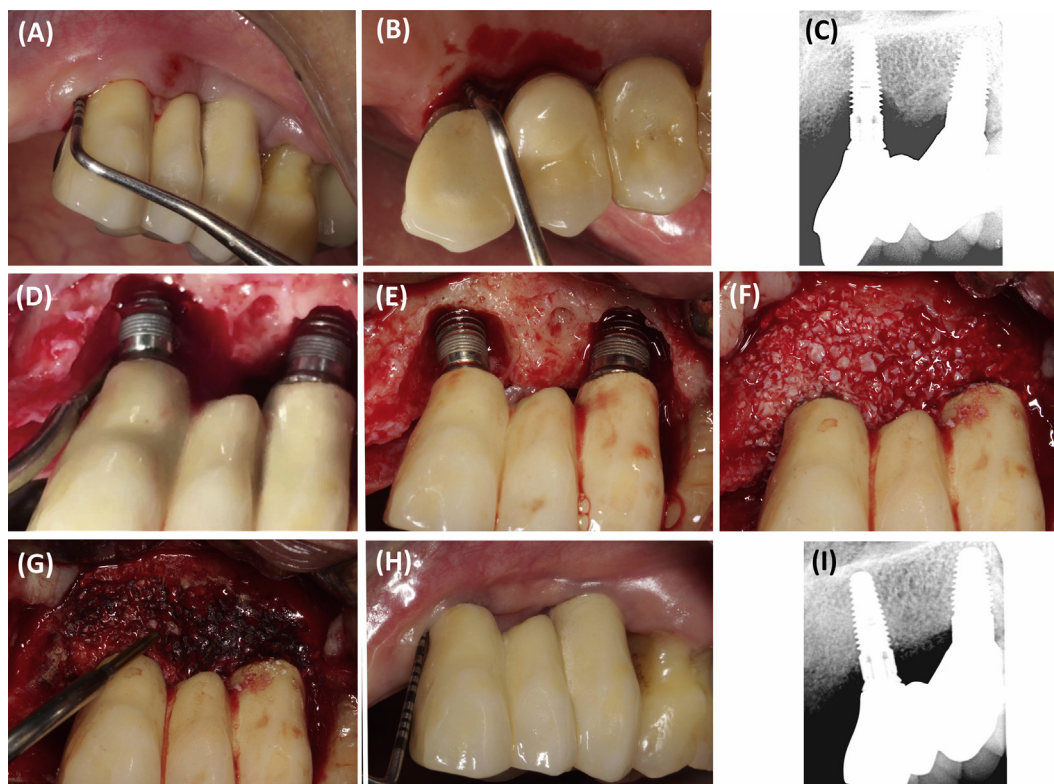


Figure 1 Clinical and radiographic photographs of our case. (A, B) The pocket depths around the #23 and #25 implants were over 12 mm and 8 mm, respectively. (C) Under radiographic evaluation, a crater-like bony defect was observed around the #23 and #25 implants. (D) Granulation tissue removal and implant surface debridement by the Er:YAG laser. (E) After debridement, no obvious thermal change was noted on the implant surface. (F) Bone material was grafted into the bony defect to the crest of #23 and #25 implant fixture platform. (G) Blood clot forming procedure was performed by Er:YAG laser irradiation without water spray under non-contact mode. (H) Soft tissue healing was favorable and the pocket depth reduced to 3 mm without bleeding on probing after 1 year. (I) A bone-like dense tissue was evident around the #23 and #25 implant surfaces and the original bone defects were successfully repaired under radiographic examination after one-year follow-up.

Conflicts of interest

The authors have no conflicts of interest relevant to this article.

References

1. Aoki A, Mizutani K, Schwarz F, et al. Periodontal and peri-implant wound healing following laser therapy. *Periodontol 2000* 2015;68:217–69.
2. Yu CH, Chang YC. Clinical efficacy of the Er:YAG laser treatment on hypersensitive dentin. *J Formos Med Assoc* 2014;113:388–91.
3. Lin TC, Wang KH, Chang YC. Er:YAG laser-assisted non-surgical approach for periodontal infrabony defects. *J Dent Sci* 2019;14:101–2.
4. Taniguchi Y, Aoki A, Sakai K, Mizutani K, Meinzer W, Izumi Y. A novel surgical procedure for Er:YAG laser-assisted periodontal regenerative therapy: case series. *Int J Periodontics Restor Dent* 2016;36:507–15.
5. Taniguchi Y, Aoki A, Takagi T, Mizutani K, Izumi Y. Development of Er:YAG laser-assisted bone regenerative therapy (Er-LBRT) in periodontal and peri-implantitis therapy. *J Jap Soc Laser Surg Med* 2019;40:45–55.

Taichen Lin
 School of Dentistry, Chung Shan Medical School, Taichung,
 Taiwan
 Department of Dentistry, Chung Shan Medical School
 Hospital, Taichung, Taiwan
 Department of Periodontology, Graduate School of Medical
 and Dental Science, Tokyo Medical and Dental University,
 Japan

Yoichi Taniguchi
*Department of Periodontology, Graduate School of Medical
and Dental Science, Tokyo Medical and Dental University,
Japan
Taniguchi Dental Clinic, Sapporo, Hokkaido, Japan*

Akira Aoki
*Department of Periodontology, Graduate School of Medical
and Dental Science, Tokyo Medical and Dental University,
Japan*

Yu-Chao Chang*
*School of Dentistry, Chung Shan Medical School, Taichung,
Taiwan*

*Department of Dentistry, Chung Shan Medical School
Hospital, Taichung, Taiwan*

*Corresponding author. School of Dentistry, Chung Shan
Medical University, 110, Sec. 1, Chien-Kuo N. Rd., Taichung,
Taiwan. Fax: +886 4 24759065.
E-mail address: cyc@csmu.edu.tw (Y.-C. Chang)

Received 3 July 2019
Final revision received 4 July 2019
Available online 22 July 2019