

[CASE REPORT]

Myeloid/Lymphoid Neoplasm with *PDGFRB* Rearrangement with t(5;10)(q33;q22) Harboring a Novel Breakpoint of the *CCDC6-PDGFRB* Fusion Gene

Miki Yamazaki¹, Chiaki Nakaseko^{1,2}, Masahiro Takeuchi¹, Shinichi Ozawa³, Yasuhiro Ishizuka³, Yasuhito Hatanaka¹, Nagisa Oshima-Hasegawa¹, Tomoya Muto¹, Shokichi Tsukamoto¹, Shio Mitsukawa^{1,4}, Chikako Ohwada¹, Yusuke Takeda¹, Naoya Mimura^{1,4}, Tohru Iseki^{1,4}, Motoharu Fukazawa³ and Emiko Sakaida¹

Abstract:

Myeloid/lymphoid neoplasms with *PDGFRB* rearrangement are a distinct type of myeloid neoplasms that occur in association with rearrangement of *PDGFRB* at 5q32. The hematological features most often show prominent eosinophilia. We herein report a patient with myeloid/lymphoid neoplasms with *PDGFRB* rearrangement with t(5;10)(q33;q22) who showed atypical chronic myeloid leukemia-like clinical features without eosinophilia and achieved an optimal response to imatinib. A sequence analysis showed a *CCDC6-PDGFRB* fusion gene with a new break point in the *PDGFRB* gene. This is the sixth case of myeloid/lymphoid neoplasm with *PDGFRB* rearrangement harboring a *CCDC6-PDGFRB* fusion gene, and it has a new breakpoint in the *PDGFRB* fusion gene.

Key words: myeloid/lymphoid neoplasms with *PDGFRB* rearrangement, atypical chronic myeloid leukemia, t(5;10)(q33;q22), *CCDC6-PDGFRB*, imatinib

(Intern Med 58: 3449-3453, 2019)

(DOI: 10.2169/internalmedicine.3220-19)

Introduction

Myeloid/lymphoid neoplasms with eosinophilia and rearrangement of *PDGFRA*, *PDGFRB* or *FGFR1* were defined in the World Health Organization (WHO) classification in 2008 as a distinct clinical entity with characteristic gene rearrangements (1). Later, *PCMI-JAK2* rearrangement was added to the category in WHO classification 2016 as a provisional entity (2-5). Within this category, some features are shared, while others differ, but all of the neoplasms are induced by the formation of a fusion gene, resulting in the expression of an aberrant tyrosine kinase and making the disease responsive to tyrosine kinase inhibitors. The disease category is now distinguished from atypical chronic myeloid

leukemia (aCML), *BCR-ABL1*-negative, the neoplastic cells of which do not have *PDGFRA*, *PDGFRB*, *FGFR1* or *PCMI-JAK2* (2, 5). Eosinophilia is characteristic but not crucial for the diagnosis (2, 6).

PDGFRA-related disorders usually present as chronic eosinophilic leukemia with prominent involvement of the mast cell lineage and sometimes the neutrophil lineage. The most common *PDGFRA* rearrangement is *FIP1L1-PDGFRB* (7, 8). In the setting of *PDGFRB*-related disease, the features of myeloproliferative neoplasm (MPN) are more variable but are often similar to those of chronic myelomonocytic leukemia (CMML) with eosinophilia. Myeloid/lymphoid neoplasm with *PDGFRB* rearrangement occurs in association with rearrangement of *PDGFRB* at 5q32. Among these variants, t(5;12)(q32;p13.2) with the formation of an

¹Department of Hematology, Chiba University Hospital, Japan, ²Department of Hematology, International University of Health and Welfare, Japan, ³Department of Hematology, JCHO Funabashi Central Hospital, Japan and ⁴Department of Transfusion Medicine and Cell Therapy, Chiba University Hospital, Japan

Received: April 22, 2019; Accepted: June 10, 2019; Advance Publication by J-STAGE: July 22, 2019

Correspondence to Dr. Chiaki Nakaseko, cnakaseko@iuhw.ac.jp

ETV6-PDGFRB fusion gene is the most common, and imatinib has been reported to be effective (9-12). In uncommon variants, other translocations with a 5q32 breakpoint lead to the formation of other fusion genes, also incorporating part of *PDGFRB*. Translocation with chromosome 10 is rare, and only five cases with t(5;10) translocation have been reported thus far (13-17). The translocation t(5;10) causes the fusion of the *PDGFRB* tyrosine kinase gene at the 5q33 region with *CCDC6* on chromosome 10q21.2 (13-18). These five cases had the same breakpoints of the *CCDC6-PDGFRB* fusion gene, but most were reported as aCML with eosinophilia before 2008 (5).

We herein report a patient with myeloid/lymphoid neoplasms with *PDGFRB* rearrangement with chromosomal reciprocal translocation t(5;10)(q33;q22) who showed aCML-like clinical features without eosinophilia and achieved an optimal response to imatinib. A sequence analysis showed the *CCDC6-PDGFRB* fusion gene with a new break point.

Case Report

A 53-year-old man was referred to our hospital due to leukocytosis. He had a medical history of hypertension without any family history. The patient had no symptoms, and his Eastern Cooperation Oncology Group (ECOG) performance status score was zero.

A physical examination revealed splenomegaly (3 cm below the costal margin). However, hepatomegaly was not observed. Complete blood count examination results showed the following: leukocyte count: $64.2 \times 10^9/L$ (blasts: 0.5%, promyelocytes: 1.0%, myelocytes: 2.5%, metamyelocytes: 6.0%, stab neutrophils: 7.5%, segmented neutrophils: 77.5%, eosinophils: 0.5%, basophils: 0.5%, monocytes: 1.5%, and lymphocytes: 2.5%), red blood cell count: $4.67 \times 10^9/L$, hemoglobin level: 13.5 g/dL, and platelet count: $290 \times 10^9/L$. Laboratory data showed that lactate dehydrogenase level increased to 375 U/L. Bone marrow (BM) aspiration results showed marked myeloid hypercellular marrow with a nucleated cell count of $80.5 \times 10^4/\mu L$ and high myeloid/erythroid ratio of 7.9. In addition, 1% myeloblasts and 9% promyelocytes were observed, indicating CML in the chronic phase. A flow cytometric analysis did not show any specific cell population. However, a chromosomal analysis of the BM showed that a majority of metaphases had reciprocal translocation of t(5;10)(q33;q22) in all cells that were analyzed [20/20]. Major and minor *BCR-ABL1* fusion genes were not detected via real-time polymerase chain reaction (RT-PCR). JAK2 V617F mutation was also negative. A fluorescence *in situ* hybridization (FISH) analysis using 3' and 5' probes of the *PDGFRB* gene showed that PDGFR β rearrangement was positive in 95% of granulocytes in BM cells and in 95% of those in peripheral blood cells. In contrast, cutaneous fibroblasts had no PDGFR β rearrangement. These data suggested that the patient had a myeloid/lymphoid neoplasm with *PDGFRB* gene rearrangement.

Materials and methods

To evaluate the molecular response, we identified the counterpart gene to the *PDGFRB* gene and its breakpoint. BM cells, peripheral blood cells, and cutaneous fibroblasts were obtained after the patient provided their informed consent.

Mononuclear cells were separated from the BM and peripheral blood via density gradient centrifugation using Ficoll-Paque PLUS (General Electronics Healthcare, Chicago, USA). Total RNA was extracted using the RNeasy Mini Kit (Qiagen, Hilden, Germany), and cDNA was generated by the reverse transcription of 200 ng RNA with PrimeScriptTM RT Reagent Kit (TaKaRa Bio, Shiga, Japan). The PCR protocol was as follows: 35 cycles for 30 seconds at 95°C, 30 seconds at 60°C, and 2 minutes at 74°C, with an initial 5 minutes at 95°C. Previous studies showed that *CCDC6* is fused at exon 7 (NM_005436.5) in frame to the *PDGFRB* gene beginning at exon 11 (NM_002609.4), so we selected sense and antisense primers directed to *CCDC6* exon 4 and *PDGFRB* exon 12, respectively (Figure A) (18). The primers were as follows: sense primer, 5'-AATCGCCTCTGGAAAAGGAT-3'; antisense primer, 5'-CCTTCCATCGGATCTCGTAA-3'. The PCR products were electrophoresed on 1.5% agarose gels.

The PCR products were subsequently subjected to direct sequencing with Big Dye terminator V 3.1 cycle sequencing reagents (Applied Biosystems, Waltham, USA) according to the manufacturer's protocol. For breakpoint identification, the samples were analyzed on an ABI PRISM 3,100 Genetic Analyzer (Applied Biosystems). Molecular monitoring of minimal residual disease was performed via RT-PCR.

Results

Detection of *CCDC6-PDGFRB* fusion gene and its breakpoint

CCDC6-PDGFRB chimeric mRNA was detected in the patient's RNA but not in the control RNA. The cDNA sequence was then compared with sequences in the National Center for Biotechnology Information (NCBI) RefSeq. We confirmed that *CCDC6* exon 7 is fused to *PDGFRB* exon 9. This suggests that the breakpoint in *CCDC6* occurred between exons 7 and 8 and resulted in in-frame fusion to *PDGFRB*. It also suggests that the breakpoint in *PDGFRB* was located between exons 8 and 9 (Figure B).

Clinical course

Based on the presence of *PDGFRB* rearrangement, treatment with imatinib at a daily dose of 400 mg was initiated. The therapy was well-tolerated, and serious adverse effects were not observed. A complete cytogenetic response to imatinib was achieved after three months of therapy as confirmed by chromosome and FISH analyses. An RT-PCR analysis showed no band at six months, indicating molecular

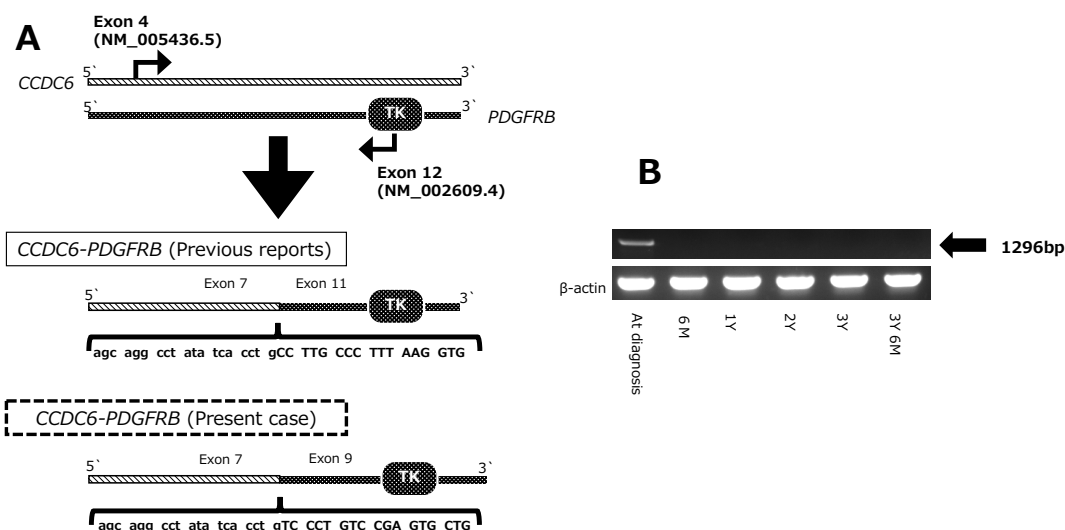


Figure. Detection of the *CCDC6-PDGFRB* fusion gene and identification of its breakpoint and effect of imatinib treatment. (A) Schematic illustration of real-time polymerase chain reaction (PCR) and DNA sequencing. To detect the *CCDC6-PDGFRB* fusion gene, sense and antisense primers directed at *CCDC6* exon 4 (NM_005436.5) and *PDGFRB* exon 12 (NM_002609.4), respectively, were used. By sequencing the PCR products [PCR band at the diagnosis in (B)], the novel breakpoint was identified. (B) Real-time PCR (RT-PCR) of the bone marrow samples at the diagnosis and at several time points after initiating imatinib. Six months after starting imatinib treatment, the RT-PCR results were negative and have remained the same since then.

Table. Characteristics of Patients with T(5;10) Chromosomal Abnormality.

No.	Diagnosis	Age (years)/sex	WBC count ($\times 10^9/L$)	Eos (%)	Immature leukocytes (%)	Cytogenetics	Breakpoint at the <i>CCDC6</i>	Breakpoint at the <i>PDGFRB</i>	Treatment	Response to imatinib	References (No.)
1	aCML	49/M	33	6	45	t(5;10)(q33;q22)	exon 7	exon 11	HU, Ara-C, 6-TG	NA	13, 18
2	aCML	48/M	94	7	NA	t(5;10)(q33;q21.2)	exon 7	exon 11	HU, Allo-SCT	NA	14
3	aCML	44/M	158	8	13	t(5;10)(q33;q22)	exon 7	exon 11	Imatinib	CCyR; 3 weeks	15
4	aCML	49/M	7.4	6	5	t(5;10)(q33;q21)	exon 7	exon 11	Imatinib	Failure; 12 weeks	17
5	CMMoL	NA	NA	NA	NA	t(5;10)(q33;q22)	exon 7	exon 11	Imatinib	CCyR; 24 months	16
6	aCML	53/M	64	0.5	10	t(5;10)(q33;q22)	exon 7	exon 9	Imatinib	CCyR; 6 months	Present case

aCML: atypical chronic myeloid leukemia, CMMoL: chronic myelomonocytic leukemia, M: male, WBC: white blood cell. Eos: eosinophil, HU: hydroxyurea, 6-TG: 6-thioguanine, Allo-SCT: allogeneic stem cell transplantation, CCyR: complete cytogenetic response, NA: not applicable

remission. The patient has remained RT-PCR-negative for three years with imatinib treatment.

Discussion

In this report, we identified a novel breakpoint in the *CCDC6-PDGFRB* fusion gene in a patient with myeloid/lymphoid neoplasm with *PDGFRB* gene rearrangement with t(5;10)(q33;q22). This enabled the monitoring of the molecular response, and the patient became RT-PCR-negative after six months of imatinib treatment and has continued with such treatment for three years.

Five cases involving the translocation of chromosomes 5

and 10 have been reported thus far (13-18). In WHO classification 2008, aCML was defined as a leukemic disorder with myelodysplastic as well as myeloproliferative features without *BCR-ABL1*, *PDGFRA*, *PDGFRB*, *FGFR1* or *PCMI-JAK2* rearrangements (1). However, before 2008, patients with myeloproliferative features having these gene rearrangements were diagnosed with aCML (19, 20). Therefore, four of these cases were reported as aCML with eosinophilia, and the other was reported as CMMoL (Table). Two cases had t(5;10)(q33;q21), and three had t(5;10)(q33;q22). The patients were all middle-aged men with mild eosinophilia, BM fibrosis, splenomegaly, and bone pain. A Southern blot analysis with *PDGFRB* cDNA probe was per-

formed, and the rearranged bands were detected in all cases. A sequencing analysis showed that these five cases had the same breakpoint of exon 7 at the *CCDC6* gene and exon 11 at the *PDGFRB* gene.

However, a sequencing analysis of the PCR products of the *CCDC6-PDGFRB* fusion gene in our patient showed that *CCDC6* exon 7 was fused to *PDGFRB* exon 9. The breakpoint in *CCDC6* was the same as that in the previously reported cases. However, the breakpoint in *PDGFRB* was different.

The *CCDC6* (also known as H4 or D10S170) gene encodes a 585-amino acid protein with no significant homology to known genes and an unknown function (13, 18). *CCDC6* rearrangement is observed in approximately 20% of human papillary carcinomas (18). *In vitro* studies have shown that the leucine zipper region of *CCDC6* included in the fusion is responsible for the dimerization of the PTC1 oncoprotein and is essential for tyrosine hyperphosphorylation and transformation *in vitro*. Of the myeloid/lymphoid neoplasm with *PDGFRB* rearrangements, *ETV6-PDGFRB* is the most common (21). Since the number of cases reported to have the *CCDC6-PDGFRB* fusion gene is extremely small, differences from cases with other fusion genes with *PDGFRB* have not been identified. Compared to the previously reported cases with the *CCDC6-PDGFRB* fusion gene, eosinophilia or granulocytic dysplasia and BM fibrosis were not observed in our patient. Whether or not this could be attributed to the differences in the breakpoint of the *CCDC6-PDGFRB* fusion gene was not clear.

The *PDGFRB* fusion gene encodes constitutively activated receptor tyrosine kinases that can be inhibited by imatinib. David et al. have shown durable hematologic and cytogenetic responses that were achieved with imatinib in a patient with *BCR-ABL*-negative chronic myeloproliferative disorder with the *PDGFRB* fusion gene (11). Three patients were treated with imatinib at a daily dose of 400 mg (15-17). Two achieved cytogenetic response after 3 weeks and 24 weeks of imatinib therapy (15, 16). One patient did not respond to imatinib and could not continue the treatment due to severe hematologic toxicity (17). Imatinib treatment was initiated three years from the onset. However, myelofibrosis was already observed in the BM. These findings suggested that starting imatinib therapy at an early stage is important for achieving a good response to imatinib. In the present case, the patient had a good response to imatinib. Differences in the breakpoint did not influence the effect of imatinib treatment.

To our knowledge, this is the sixth case of myeloid/lymphoid neoplasm with *PDGFRB* rearrangement harboring a *CCDC6-PDGFRB* fusion gene. Of note, a sequencing analysis revealed a novel breakpoint; however, whether or not the difference in the breakpoint is associated with clinical characteristics, such as dysplasia, eosinophilia, and fibrosis in the BM, is unclear at present. Further studies must be conducted in order to better understand myeloid/lymphoid neoplasm with *PDGFRB* rearrangement.

The authors state that they have no Conflict of Interest (COI).

References

- Vardiman JW, Thiele J, Arber DA, et al. The 2008 revision of the World Health Organization (WHO) classification of myeloid neoplasms and acute leukemia: rationale and important changes. *Blood* **114**: 937-951, 2009.
- Arber DA, Orazi A, Hasserjian R, et al. The 2016 revision to the World Health Organization classification of myeloid neoplasms and acute leukemia. *Blood* **127**: 2391-2405, 2016.
- Bousquet M, Quelen C, De Mas V, et al. The t(8;9)(p22;p24) translocation in atypical chronic myeloid leukaemia yields a new PCM1-JAK2 fusion gene. *Oncogene* **24**: 7248-7252, 2005.
- Reiter A, Walz C, Watmore A, et al. The t(8;9)(p22;p24) is a recurrent abnormality in chronic and acute leukemia that fuses PCM1 to JAK2. *Cancer Res* **65**: 2662-2667, 2005.
- Swerdlow SH, Campo E, Harris NL, et al. WHO Classification of Tumours of Haematopoietic and Lymphoid Tissues. Revised 4th ed. World Health Organization, 2017.
- Gotlib J. World Health Organization-defined eosinophilic disorders: 2017 update on diagnosis, risk stratification, and management. *Am J Hematol* **92**: 1243-1259, 2017.
- Cools J, DeAngelo DJ, Gotlib J, et al. A tyrosine kinase created by fusion of the PDGFRA and FIP1L1 genes as a therapeutic target of imatinib in idiopathic hypereosinophilic syndrome. *N Engl J Med* **348**: 1201-1214, 2003.
- Gotlib J, Cools J, Malone JM 3rd, Schrier SL, Gilliland DG, Coutre SE. The FIP1L1-PDGFRalpha fusion tyrosine kinase in hypereosinophilic syndrome and chronic eosinophilic leukemia: implications for diagnosis, classification, and management. *Blood* **103**: 2879-2891, 2004.
- Apperley JF, Gardembas M, Melo JV, et al. Response to imatinib mesylate in patients with chronic myeloproliferative diseases with rearrangements of the platelet-derived growth factor receptor beta. *N Engl J Med* **347**: 481-487, 2002.
- Reiter A, Gotlib J. Myeloid neoplasms with eosinophilia. *Blood* **129**: 704-714, 2017.
- David M, Cross NC, Burgstaller S, et al. Durable responses to imatinib in patients with PDGFRB fusion gene-positive and BCR-ABL-negative chronic myeloproliferative disorders. *Blood* **109**: 61-64, 2007.
- Golub TR, Barker GF, Lovett M, Gilliland DG. Fusion of PDGF receptor beta to a novel ets-like gene, tel, in chronic myelomonocytic leukemia with t(5;12) chromosomal translocation. *Cell* **77**: 307-316, 1994.
- Siena S, Sammarelli G, Grimoldi MG, et al. New reciprocal translocation t(5;10)(q33;q22) associated with atypical chronic myeloid leukemia. *Haematologica* **84**: 369-372, 1999.
- Kulkarni S, Heath C, Parker S, et al. Fusion of H4/D10S170 to the platelet-derived growth factor receptor beta in BCR-ABL-negative myeloproliferative disorders with a t(5;10)(q33;q21). *Cancer Res* **60**: 3592-3598, 2000.
- Garcia JL, Font de Mora J, Hernandez JM, et al. Imatinib mesylate elicits positive clinical response in atypical chronic myeloid leukemia involving the platelet-derived growth factor receptor beta. *Blood* **102**: 2699-2700, 2003.
- Drechsler M, Hildebrandt B, Kundgen A, Germing U, Royer-Pokora B. Fusion of H4/D10S170 to PDGFRbeta in a patient with chronic myelomonocytic leukemia and long-term responsiveness to imatinib. *Ann Hematol* **86**: 353-354, 2007.
- Bastie JN, Garcia I, Terre C, Cross NC, Mahon FX, Castaigne S. Lack of response to imatinib mesylate in a patient with accelerated phase myeloproliferative disorder with rearrangement of the platelet-derived growth factor receptor beta-gene. *Haematologica* **89**: 1263-1264, 2004.

- 18.** Schwaller J, Anastasiadou E, Cain D, et al. H4(D10S170), a gene frequently rearranged in papillary thyroid carcinoma, is fused to the platelet-derived growth factor receptor beta gene in atypical chronic myeloid leukemia with t(5;10)(q33;q22). *Blood* **97**: 3910-3918, 2001.
- 19.** Alimena G, Breccia M, Mancini M, et al. Clonal evolution in Philadelphia chromosome negative cells following successful treatment with Imatinib of a CML patient: clinical and biological features of a myelodysplastic syndrome. *Leukemia* **18**: 361-362, 2004.
- 20.** Breccia M, Biondo F, Latagliata R, Carosino I, Mandelli F, Alimena G. Identification of risk factors in atypical chronic myeloid leukemia. *Haematologica* **91**: 1566-1568, 2006.
- 21.** Cross NC, Reiter A. Tyrosine kinase fusion genes in chronic myeloproliferative diseases. *Leukemia* **16**: 1207-1212, 2002.

The Internal Medicine is an Open Access journal distributed under the Creative Commons Attribution-NonCommercial-NoDerivatives 4.0 International License. To view the details of this license, please visit (<https://creativecommons.org/licenses/by-nc-nd/4.0/>).

© 2019 The Japanese Society of Internal Medicine
Intern Med 58: 3449-3453, 2019