Molecular Vision 2019; 25:851-858 <http://www.molvis.org/molvis/v25/851>
Received 12 July 2019 | Accepted 17 December 2019 | Published 19 December 2019

© 2019 Molecular Vision

Long-term follow-up of retinal function and structure in *TRPM1*-associated complete congenital stationary night blindness

Haneen Al-Hujaili,[1,2] Ibrahim Taskintuna,[1] Christine Neuhaus,[3] Carsten Bergmann,[3,4,5] Patrik Schatz[1,6]

[1]Vitreoretinal Division, King Khaled Eye Specialist Hospital, Riyadh, Kingdom of Saudi Arabia; [2]Ohud General Hospital Madinah, Kingdom of Saudi Arabia; [3]Center for Human Genetics Bioscientia Ingelheim, Germany; [4]Department of Medicine, Freiburg University, Germany; [5]Limbach Genetics, Medizinische Genetik Mainz, Mainz, Germany; [6]Department of Ophthalmology, Clinical Sciences, Skane University Hospital, Lund University, Lund, Sweden

Purpose: *TRPM1*-associated congenital stationary night blindness (CSNB) is characterized by nystagmus and high myopia. We assessed retinal function and structure over long-term follow-up up to 10 years in two siblings from a family with the homozygous deletion c.2394delC in exon 18 that we previously identified. In addition, we describe retinal function and structure in two other siblings with the novel homozygous c.1394T>A (p.Met465Lys) missense mutation.
Methods: Clinical examination included full-field electroretinography, axial length measurements, and multimodal retinal imaging. Molecular genetic tests included next-generation sequencing and Sanger sequencing.
Results: All patients had non-recordable rod responses and electronegative configuration of the rod-cone responses at presentation. There was a median of 26% reduction in the dark- and light-adapted electroretinographic (ERG) amplitudes over 4 years. Myopia progressed rapidly in childhood but showed only a mild progression after the teenage years. Visual acuities were stable over time, and there was no sign of progressive retinal thinning. All patients had axial myopia. A novel homozygous c.1394T>A (p.Met465Lys) missense mutation in *TRPM1* was identified in two siblings.
Conclusions: Further prospective study in larger samples is needed to establish whether there is progressive retinal degeneration in *TRPM1*-associated CSNB. The associated myopia was found to be mainly axial, which has not been described previously. The mechanism of myopia development in this condition remains incompletely understood; however, it may be related to altered retinal dopamine signaling and amacrine cell dysfunction.

Transient receptor potential cation channel, subfamily m, member 1 (*TRPM1*; OMIM 603576)-associated congenital stationary night blindness (CSNB) is a form of complete congenital stationary night blindness (cCSNB or CSNB1), which is characterized by nystagmus, high myopia, and tilted optic discs or disc hypoplasia [1-3]. Because of these associated findings, CSNB may be initially misdiagnosed as congenital idiopathic nystagmus, Leber congenital amaurosis, ametropic amblyopia, and primary optic disc hypoplasia, among others [1-3]. Proper diagnosis requires confirmation with electroretinography, which should demonstrate retinal ON bipolar cell dysfunction in the form of an "electronegative electroretinogram (ERG)," where the b-wave amplitude is reduced compared to the a-wave amplitude, and molecular genetic testing.

TRPM1-associated CSNB affects an early and essential step in the retinal transmission of the electrical impulse generated by light, namely, the cone and rod ON bipolar cell synapse signaling where transient receptor potential melastatin-1 (TRPM1) is an ion channel in the postsynaptic dendritic tips of the bipolar cells, opening in response to light, leading to depolarization [4]. As an essential part of retinal and bipolar cell signaling, TRPM1 may play an important role in the development of optogenetics [5]. In addition, the protein has recently been implicated in cancer-associated retinopathy and may also play a role in the endoplasmic reticulum (ER) of the bipolar cells [6,7].

The pathogenesis of cCSNB or CSNB1 thus involves a disruption in the light signal transmission from the photoreceptors to the retinal ON bipolar cells. Previously, this form of CSNB was believed to be most commonly associated with X-linked variants in the nyctalopin (*NYX*; OMIM 300278) gene (encoding nyctalopin, located in close proximity to TRPM1 in the dendritic tips of the ON bipolar cell membrane) [8,9]. However, recessive *TRPM1* may be the most frequently incriminated gene in certain populations, especially if consanguineous marriages are highly prevalent [10].

We assessed retinal function and structure over long-term follow-up, up to 10 years, in two sibling pairs from two unrelated families with *TRPM1*-associated CSNB, to characterize the condition further. We also investigated the nature of the associated myopia, the cause of which has not been determined to date.

Correspondence to: Patrik Schatz, Vitreoretinal Division, King Khaled Eye Specialist Hospital, Al- Oruba Street, PO Box 7191 Riyadh 11462, Kingdom of Saudi Arabia. Phone: +966 11 482 1234 ext. 3773; FAX: +966 11 4821234 ext. 3773; email: pschatz@kkesh.med.sa

METHODS

This study was approved by the institutional research ethics committee and adhered to the tenets of the Declaration of Helsinki. For patients 3 and 4, molecular confirmation of homozygous mutations in *TRPM1* have been described by us previously [3]. For patient 1, molecular genetic testing included next-generation sequencing (NGS, performed by Center for Human Genetics Bioscientia, Ingelheim, Germany), performed for the following 77 genes known to be involved in autosomal recessive (AR) and autosomal dominant (AD) retinal dystrophies (Appendix 1)

These genes were enriched and sequenced in parallel as follows. Genomic DNA was fragmented, and the coding exons of the analyzed genes, as well as the corresponding exon-intron boundaries, were enriched using the Roche NimbleGen sequence capture approach, amplified and sequenced simultaneously with NGS using an Illumina HiSeq 1500 system (Illumina, San Diego, CA). For more than 99% of the regions of interest, 20-fold coverage was obtained. NGS data analysis was performed using bioinformatic analysis tools and JSI Medical Systems software (version 4.1.2). Identified variants and indels were filtered against external and internal databases, and filtered depending on their allele frequency, focusing on rare variants with a minor allele frequency (MAF) of 1% or less. Nonsense, frameshift and canonical splice site variants were primarily considered likely pathogenic. Variants that have been annotated as common polymorphisms in databases or in the literature were not considered further.

Putatively pathogenic differences between the wild-type sequence (human reference genome according to UCSC Genome Browser: hg19, GRCh37) and the patient sequences mentioned and interpreted in this report were validated using PCR amplification followed by conventional Sanger sequencing. Genomic DNA was isolated from EDTA blood and 0.5–1 mg of genomic DNA per sample was sheared using the Covaris S2 AFA system (Covaris Inc., Woburn, MA) and ligated to barcoded adaptors for multiplexing. Pre-capture amplified samples were pooled and hybridized to the customized in-solution capture library for 72 h, subsequently eluted and post-capture amplified by ligation-mediated (LM-) PCR. This amplified enriched DNA was used as input for emulsion PCR (emPCR) and subsequent sequencing on the Illumina system. The resulting sequence data for the *TRPM1* gene (OMIM 603576; locus: chromosome 15q13.3) were compared to the reference sequence NM_002420.5.

For patient 2 (sibling of patient 1) and the unaffected parents of patients 1 and 2, exon 12 of *TRPM1* were amplified with PCR and directly sequenced. The retinal structure was analyzed qualitatively and quantitatively with transfoveal horizontal spectral domain optical coherence tomography scans (Spectralis OCT, Heidelberg Engineering, Inc., Heidelberg, Germany). Measurement of the foveal retinal thickness, which was defined as the shortest distance from the top of the RPE line to the internal limiting membrane in the right eyes of patients, was obtained with calipers using the Heidelberg software. In addition, in one of the patients, the Spectralis macular raster consisting of 19 horizontal 6-mm line scans, was performed, despite nystagmus. This enabled the automated software algorithm to display with numeric averages of the macular thickness measurements for each of the nine map sectors as defined by the Early Treatment Diabetic Retinopathy Study (ETDRS) [11]. Retinal thickness in patients was compared to that of controls from a paper we previously published [12], using identical protocols (caliper measurement and the ETDRS map) in the patients and controls. Widefield imaging, including fundus autofluorescence, was performed in all patients (Optos PLC, Dunfermline, UK). Four of the patients (all except patient 2) underwent macular autofluorescence imaging with a fundus camera (Topcon TRC-50DX, Topcon Medical Systems, Inc., Oakland, NJ).

Retinal function was evaluated with full-field electroretinography (ffERG, using Nicolet Biomedical Instruments, Madison, WI, during the first visit for all patients and with Roland Consult, Brandenburg, Germany, during the most recent follow-up visit, in patients 3 and 4), in dark- and light-adapted states according to International Society for Clinical Electrophysiology of Vision (ISCEV) standards [13], with a few modifications as follows. Subjects' pupils were dilated with topical cyclopentolate 1%, and metaoxedrine 2.5% was applied for topical anesthesia. Subjects were dark adapted for 40 min. A corneal Burian Allen bipolar contact lens was used to record the ERGs, with a ground electrode applied to the forehead. Responses were obtained stimulating with single full-field flash (30 ms) with blue light (0.81 cd-s/m2: rod response) and with white light (10.02 cd-s/m^2: combined rod-cone response). In addition, the dark-adapted cone response was measured after stimulation with dim red light (3.93 cd-s/m2). Photopic responses were obtained with a background illumination of 3.4 cd-s/m^2 to saturate the rods. During the most recent visit, ffERG was obtained using Roland (Roland Consult) but with the same settings regarding flash duration and luminance. Axial length and keratometry were measured using Zeiss IOL master 500 (Carl Zeiss Meditec, AG Jena, Jena, Germany), Visual acuity was measured in the Snellen format.

RESULTS

The novel homozygous c.1394T>A (p.Met465Lys) mutation was identified with NGS in *TRPM1*-associated CSNB in patient 1. Additional heterozygous variants identified in patient 1, with NGS, are listed in Appendix 2. None of these variants would sufficiently explain the phenotype; however, a modifying effect cannot be ruled out (Appendix 2). Targeted sequencing revealed that the brother of patient 1 (patient 2) with *TRPM1*-associated CSNB, had the same homozygous mutation, while the parents were heterozygous carriers (Appendix 3). The variant is highly conserved, there is still no allele frequency in gnomAD (accessed on 27 March 2019), and it is not reported in the literature. The multimodal imaging findings of these two siblings with the novel mutation are presented in Figure 1 and Figure 2. Patients 3 and 4 were known to us previously with *TRPM1*-associated CSNB caused by the homozygous mutation homozygous deletion c.2394delC in exon 18 [3].

For patients 1 and 2, longitudinal data were obtained over a follow-up duration of 1 year, except the best-corrected visual acuity (BCVA) and refraction assessment of patient 1, which were performed over a follow-up period of 5 years, between the age of 4 years and 9 years (Appendix 4). For patients 3 and 4, the corresponding interval was 4 years for full-field electroretinography and optical coherence tomography, and 10 years for axial length and refraction.

FfERG at presentation was similar in all four patients, including a non-recordable rod response compatible with complete CSNB, an electronegative configuration with an intact a-wave in the dark-adapted rod-cone response compatible with a post-transductional defect. In patients 3 and 4, ffERG was performed again after 4 years of follow-up, showing a similar configuration, although different equipment was used. The dark-adapted rod-cone b-wave amplitude, the light-adapted single flash b-wave amplitudes, and the 30-Hz flicker amplitudes all seemed to be reduced (median change 26%, range 18–41%, for these parameters, for both patients, Appendix 4 and Appendix 5) compared to the initial examination 4 years previously. The change in the amplitudes over time, thus (more often than not), was more than 25%, which could be considered a considerable change [11]; however, the relevance of this apparent change remains unclear because of the different equipment that was used.

Refraction (spherical equivalent, SE) ranged between −8.25 diopter (D) and −10.5 D at presentation and −9.5 and −13.25 at follow-up (Appendix 4). Refraction changed most notably in patient 1 with progressive myopia ranging from SE−10.5 OU to −13.25 in both eyes during the years between age 4 years and age 9 years (Appendix 4). However, refraction was changed less in the older patients 3 and 4, during 10 years of follow-up between the age of 14 and 24 years old (range SEM −8.25 to SEM −10.5, Appendix 4).

Axial length was measured only once for all patients, during the most recent follow-up, with a median of 27.38, range 26.68–27.68 mm (Appendix 4). However, all K values (K1 and K2) ranged between 41.56 and 45.18 D, with a median 43.9. This result indicates that the myopia was mainly axial as opposed to corneal.

BCVA was measured during a follow-up period of 1 year for patients 1 and 2 and over 10 years for patients 3 and 4, ranging from 20/70 to 20/40 at presentation and from 20/80 to 20/25 at the most recent visit (Appendix 4). All eyes had an apparent improvement of BCVA with time except the right eye of patient 2 (Appendix 4).

High-quality spectral domain optical coherence tomography (SD-OCT) single line transfoveal horizontal scans were possible in all patients despite nystagmus, showing a reduction in the caliper- measured foveal thickness, compared to normal myopic material we previously published (healthy myopic subjects, myopia range 6–9 D, median 7.5 D, age range 20–30 years, median 22 years; Appendix 4) [3]. In addition, caliper measurements of OCT foveal thickness were possible in horizontal transfoveal single line scans in all patients. This measurement was obtained over 1 year of follow-up in patients 1 and 2, but for patients 3 and 4, there was a follow-up period of 4 years between the measurements. None of the patients showed any signs of progressive thinning of the retinas (Appendix 4). In one patient, patient 1, in addition, an OCT ETDRS map was possible, despite nystagmus, showing a macular central subfield thickness of 251 and 248 µm in the right and left eyes, respectively, which was in the lower range of our normal material (range 246–283), and all but three of the eight remaining ETDRS subfields values were less than normal for the right eye; however, only one of the remaining eight subfield values was less than normal for the left eye.

DISCUSSION

The main novel findings in this study are that the myopia in *TRPM1*-associated CSNB is mostly axial and the report of a novel homozygous missense c.1394T>A (p.Met465Lys) disease-causing mutation in the gene. The variant is highly conserved, there is still no allele frequency in gnomAD, and it is not reported in the literature. The mechanism of the exaggerated growth of the axial length in *TRPM1* retinopathy remains unknown. However, as discussed further below, taking into consideration results from other recent studies,

the axial myopia of *TRPM1*-associated CSNB may be driven by alterations of retinal dopamine levels.

Another interesting finding was that the dark-adapted rod-cone b-wave amplitudes, the light-adapted single-flash b-wave amplitudes, and the 30-Hz flicker amplitudes seemingly decreased over time (median change 26%, range 18–41%, for these parameters, for both patients, Appendix 4). The change in the ffERG amplitudes over time, thus, was more than 25%, which could be considered a considerable change [14]. Fishman et al. examined the variability in the

Figure 1. Multimodal retinal imaging findings in *TRPM1*-associated CSNB in patient 1 with the novel homozygous missense c.1394T>A (p.Met465Lys) mutation. **Top row**: Color fundus of patient 1 right and left fundi. **Middle row**: Location of the optical coherence tomography line scan on the fundus en face image. **Bottom row**: Transfoveal single line optical coherence tomography scans of the right and left eyes of patient 1 demonstrating preserved retinal lamination.

ffERG and concluded that the threshold for a significant increase or decrease in inter-visit ERG amplitudes at a 95% confidence level for patients with retinitis pigmentosa, and visually normal subjects was often at or above 25% [15]. No similar comparisons have been done in patients with CSNB. Furthermore, AlTalbishi et al. recently reported on a large cohort of patients with mutations in *TRPM1*, where the authors demonstrated, on average, a mild decline in 30-Hz flicker amplitudes with older age up to 45 years old [10].

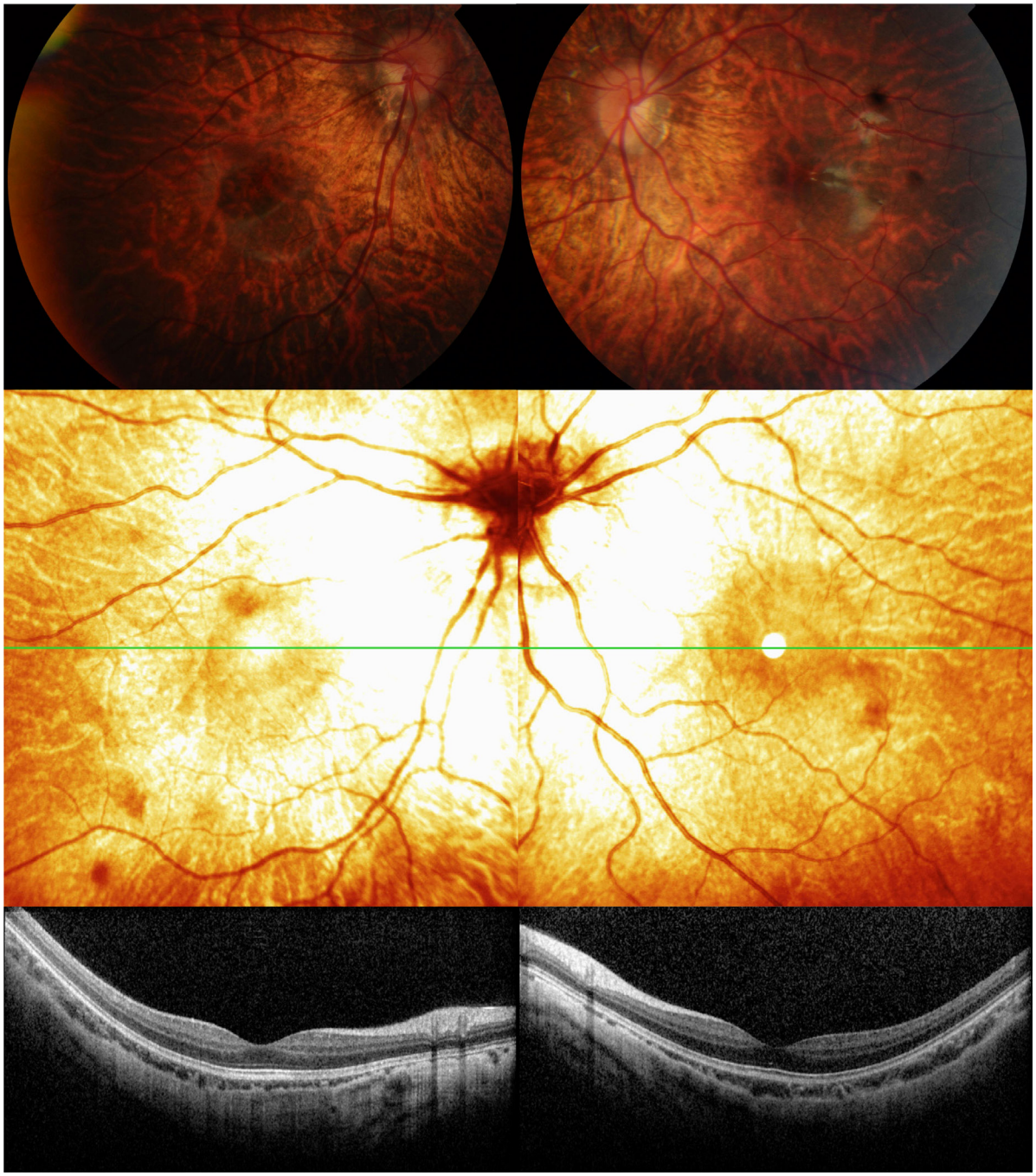

Figure 2. Multimodal retinal imaging findings in *TRPM1*-associated CSNB in patient 2 with the novel homozygous missense c.1394T>A (p.Met465Lys) mutation. **Top row**: Color fundus of patient 2 right and left fundi. **Middle row**: Location of the optical coherence tomography line scan on the fundus en face image. **Bottom row**: Transfoveal single line optical coherence tomography scans of the right and left eyes of patient 2 demonstrating preserved retinal lamination.

However, patients with cCSNB often have an almost absent b-wave. In addition, the b-wave intrudes on the negative potential of the a-wave. Appendix 5 demonstrates the rod-cone a-wave which may have drawn the (already small) b-wave down, making it even smaller, and therefore, a direct comparison of the b-waves on separate occasions may be difficult to interpret. Furthermore, the a-wave reflects the hyperpolarization of the photoreceptors, which means that an increase in a-wave amplitude may indicate improved photoreceptor function. An improvement in retinal function agrees with the improved visual acuity of the patients and the unchanged findings on OCT. In two siblings (patients 1 and 2), the novel homozygous missense c.1394T>A (p.Met465Lys) mutation was detected. In addition, a few other variants in other genes were identified with next-generation sequencing in patient 1, including a heterozygous mutation in tectonic family, member 1 (*TCTN1*; OMIM 609863; Appendix 2), which has previously, in a homozygous mode, been associated with Joubert syndrome [15]. This does not sufficiently explain the *TRPM1*-associated CSNB phenotype observed in this patient, but a modifying effect cannot be ruled out. Furthermore, it may imply carriership for Joubert syndrome [15]. However, the variant was not analyzed further in any of the other family members. Both patients had typical ffERG responses compatible with complete CSNB, including a non-recordable rod response and an electronegative dark-adapted combined rod-cone response.

Refraction changed more in patient 1 who was followed between the age of 4 and 9 years old than in patients 3 and 4 who were followed between 14 and 24 years old (Appendix 4). In addition, all patients had long eyes, with keratometry values that can be considered to lie within normal range, although we did not collect any normal reference material for this measure. Nevertheless, this implies that a substantial change in the refractive error in patients with *TRPM1*-associated CSNB is caused by an increase in axial length during growth, and that the myopia is axial rather than caused by an abnormal corneal curvature. However, this fact does not distinguish the myopia of this disorder compared to most other forms of myopia. For example, Olsen et al. found, by using linear regression, that when considering the contribution of axial length, lens power, and corneal power together, axial myopia can explain up to 96% of the variation in refraction in populations [16]. High-resolution cross-section and longitudinal imaging often revealed less-than-normal central retinal thickness; however, none of the patients showed any signs of progressive thinning of the retina, even after 4-year follow-up as in patients 3 and 4 (Appendix 4).

Miraldi Utz et al. recently investigated the presentation and longitudinal changes during a mean of 11 years of follow-up, in seven patients with *TRPM1*-associated CSNB [2]. They were able to obtain measurements of OCT central subfield thickness (CST) in at least one eye in six out of seven patients, showing thickness values (range 226–275 and one outlier measurement at 387 µm) similar to those found in patient 1 in this study. However, no reference material was presented, and there was no longitudinal follow-up of OCT data. The mean initial refraction in the study by Miraldi Utz et al. was −2.80 D, and the mean refraction at the most recent visit was −8.75 D, with the greatest rate of myopic shift before age 5 years. However, axial length measurements were not obtained [2]. To the best of our knowledge, axial length measurements have not been described previously in *TRPM1*-associated CSNB, and in the present study, we found that these patients have long eyes, indicating that the myopia is mainly axial. This further strengthens the idea that abolished ON bipolar signaling may lead to abnormal eye growth, which has been suggested previously, by Hendriks et al. who found that disorders leading to ON bipolar cell dysfunction were significantly associated with high myopia [17]. However, it is of interest that complete CSNB associated with mutations in *GRM6* (the gene encoding metabotropic glutamate receptor 6, mGluR6), which would be expected to lead to a similar mechanism regarding the ON bipolar cell dysfunction, often but not always leads to myopia and emmetropia as well as hyperopia have been described in single patients [9,18,19]. Among 101 patients with CSNB, Bijveld et al. found that all ten patients with mutations in *TRPM1* were myopic, as were all patients with mutations in *NYX* and *GPR179*. However, one patient with a mutation in *GRM6* had mild hyperopia [9]. This is in keeping with findings in a recent study by Kozuka et al. who found that deletion of *trpm1* in mice, but not of *mglur6*, resulted in a contraction of rod-bipolar terminals and in a reduction of the number dendritic branches and size of the cell bodies of the AII Amacrine cells [20]. Amacrine cells, in turn, are the source of production of retinal dopamine, decreased levels of which have been implicated in myopia development [21]. Thus, a decrease in retinal dopamine levels may be one mechanism that may contribute to the myopia in *TRPM1*-associated CSNB and possibly also in other forms of cCSNB.

In the study by Miraldi Utz et al., although individual changes in ffERG amplitudes were observed over time, as a group the amplitudes did not change significantly over time [2]. However, the finding of individual variations in ffERG responses over time may be significant, because it differs from other forms of CSNB, such as *CABP4*-related

retinopathy, where ffERGs were almost identical despite long-term follow-up, up to 12 years [12].

To conclude, the cause of myopia in *TRPM1*-associated CSNB is still incompletely understood. However, in this study we showed that the myopia is mostly axial as opposed to corneal or lenticular. Furthermore, taking into consideration the results of this study and previous studies, there may be a link between *TRPM1* dysfunction and amacrine cell dysfunction, leading to altered levels of retinal dopamine, in turn leading to axial myopia. This hypothesis requires further study, to examine the levels of retinal dopamine in *TRPM1*-associated CSNB, which, to our knowledge, has not been studied previously.

APPENDIX 1. 77 GENES KNOWN TO BE INVOLVED IN AUTOSOMAL RECESSIVE (AR) AND AUTOSOMAL DOMINANT (AD) RETINAL DYSTROPHIES ANALYZED BY NEXT GENERATION SEQUENCING.

To access the data, click or select the words "Appendix 1."

APPENDIX 2. ADDITIONAL VARIANTS DETECTED BY NEXT GENERATION SEQUENCING IN PATIENT 1, WITH TRPM1-ASSOCIATED CONGENITAL STATIONARY NIGHT BLINDNESS (CSNB).

To access the data, click or select the words "Appendix 2." None of these variants would be expected to sufficiently explain the phenotype, however a modifying effect cannot be rules out. ExAC (http://exac.broadinstitute.org/) was accessed on June 13, 2019.

APPENDIX 3. MUTATION SEGREGATION ANALYSIS IN A FAMILY WITH THE NOVEL HOMOZYGOUS MISSENSE C.1394T>A (P.MET465LYS) MUTATIONS DETECTED IN 2 SIBLINGS WITH CONGENITAL STATIONARY NIGHT BLINDNESS.

To access the data, click or select the words "Appendix 3."

APPENDIX 4. CLINICAL FINDINGS IN 4 PATIENTS (2 SIBLING PAIRS) WITH TRPM1-ASSOCIATED CONGENITAL STATIONARY NIGHT BLINDNESS (CSNB).

To access the data, click or select the words "Appendix 4."

APPENDIX 5. FULL-FIELD ELECTRORETINOGRAM DURING 4 YEARS OF FOLLOW-UP IN PATIENT 3 WITH TRPM1-ASSOCIATED CONGENITAL STATIONARY NIGHT BLINDNESS CAUSED BY THE HOMOZYGOUS C.2394DELC MUTATION.

To access the data, click or select the words "Appendix 5."

ACKNOWLEDGMENTS

Funding/support: None. We thank M_r Adolph Cabanas at the Design and Publications Department at King Khaled Eye Specialist Hospital for Skillful technical assistance. Author Contributions Statement: Design of the study (HH, IT, CN, CB, PS); Conduct of the study (HH, IT, CN, CB, PS); Collection, management, analysis, and interpretation of the data (HH, IT, CN, CB, PS); Preparation, review and final approval of the manuscript (HH, IT, CN, CB, PS);

REFERENCES

1. Li Z, Sergouniotis PI, Michaelides M, Mackay DS, Wright GA, Devery S, Moore AT, Holder GE, Robson AG, Webster AR. Recessive mutations of the gene TRPM1 abrogate ON bipolar cell function and cause complete congenital stationary night blindness in humans. Am J Hum Genet 2009; 85:711-9. [PMID: 19878917].
2. Miraldi Utz V, Pfeifer W, Longmuir SQ, Olson RJ, Wang K, Drack AV. Presentation of TRPM1-Associated Congenital Stationary Night Blindness in Children. JAMA Ophthalmol 2018; 136:389-98. [PMID: 29522070].
3. Al Oreany AA, Al Hadlaq A, Schatz P. Congenital stationary night blindness with hypoplastic discs, negative electroretinogram and thinning of the inner nuclear layer. Graefes Arch Clin Exp Ophthalmol 2016; 254:1951-6. [PMID: 27084085].
4. Agosto MA, Zhang Z, He F, Anastassov IA, Wright SJ, McGehee J, Wensel TG. Oligomeric state of purified transient receptor potential melastatin-1 (TRPM1), a protein essential for dim light vision. J Biol Chem 2014; 289:27019-33. [PMID: 25112866].
5. Simunovic MP, Shen W, Lin JY, Protti DA, Lisowski L, Gillies MC. Optogenetic approaches to vision restoration. Exp Eye Res 2019; 178:15-26. [PMID: 30218651].
6. Ueno S, Inooka D, Nakanishi A, Okado S, Yasuda S, Kominami T, Sayo A, Morimoto T, Kondo M, Katagiri S, Hayashi T, Terasaki H. Clinical course of paraneoplastic retinopathy with anti-TRPM1 autoantibody in Japanase cohort. Retina 2019; 39: 2410-2418. .
7. Agosto MA, Anastassov IA, Robichaux MA, Wensel TG. A Large Endoplasmic Reticulum-Resident Pool of TRPM1 in Retinal ON-Bipolar Cells. eNeuro 2018; 4:5-[PMID: 30027108].

8. Bech-Hansen NT, Naylor MJ, Maybaum TA, Sparkes RL, Koop B, Birch DG, Bergen AA, Prinsen CF, Polomeno RC, Gal A, Drack AV, Musarella MA, Jacobson SG, Young RS, Weleber RG. Mutations in NYX, encoding theleucine-rich proteoglycan nyctalopin, cause X-linked complete congenitalstationary night blindness. Nat Genet 2000; 26:319-23. [PMID: 11062471].

9. Bijveld MM, Florijn RJ, Bergen AA, van den Born LI, Kamermans M, Prick L, Riemslag FC, van Schooneveld MJ, Kappers AM, van Genderen MM. Genotype and phenotype of 101 dutch patients with congenital stationary night blindness. Ophthalmology 2013; 120:2072-81. [PMID: 23714322].

10. AlTalbishi A, Zelinger L, Zeitz C, Hendler K, Namburi P, Audo I, Sheffer R, Yahalom C, Khateb S, Banin E, Sharon D. TRPM1 Mutations are the Most Common Cause of Autosomal Recessive Congenital Stationary Night Blindness (CSNB) in the Palestinian and Israeli Populations. Sci Rep 2019; 9:12047-[PMID: 31427709].

11. . Early Treatment Diabetic Retinopathy Study Research Group. ETDRS Report Number 7: Early Treatment Diabetic Retinopathy Study Design and Baseline Patient Characteristics. Ophthalmology 1991; 98:741-56. [PMID: 2062510].

12. Schatz P, Abdalla Elsayed MEA, Khan AO. Multimodal imaging in CABP4-related retinopathy. Ophthalmic Genet 2017; 38:459-64. [PMID: 28635425].

13. McCulloch DL, Marmor MF, Brigell MG, Hamilton R, Holder GE, Tzekov R, Bach M. ISCEV Standard for full-field clinical electroretinography (2015 update). Doc Ophthalmol 2015; 130:1-12. [PMID: 25502644].

14. Fishman GA, Chappelow AV, Anderson RJ, Rotenstreich Y, Derlacki DJ. Short-term inter-visit variability of erg amplitudes in normal subjects and patients with retinitis pigmentosa. Retina 2005; 25:1014-21. [PMID: 16340532].

15. Alazami AM, Alshammari MJ, Salih MA, Alzahrani F, Hijazi H, Seidahmed MZ, Abu Safieh L, Aldosary M, Khan AO, Alkuraya FS. Molecular characterization of Joubert syndrome in Saudi Arabia. Hum Mutat 2012; 33:1423-8. [PMID: 22693042].

16. Olsen T, Arnarsson A, Sasaki H, Sasaki K, Jonasson F. On the ocular refractive components: the Reykjavik Eye Study. Acta Ophthalmol Scand 2007; 85:361-6. [PMID: 17286626].

17. Hendriks M, Verhoeven VJM, Buitendijk GHS, Polling JR, Meester-Smoor MA, Hofman A. RD5000 Consortium, Kamermans M, Ingeborgh van den Born L, Klaver CCW. Development of Refractive Errors-What Can We Learn From Inherited Retinal Dystrophies? Am J Ophthalmol 2017; 182:81-9. [PMID: 28751151].

18. Dryja TP, McGee TL, Berson EL, Fishman GA, Sandberg MA, Alexander KR, Derlacki DJ, Rajagopalan AS. Night blindness and abnormal cone electroretinogram ON responses in patients with mutations in the GRM6 gene encoding mGluR6. Proc Natl Acad Sci USA 2005; 102:4884-9. [PMID: 15781871].

19. Naeem MA, Gottsch AD, Ullah I, Khan SN, Husnain T, Butt NH, Qazi ZA, Akram J, Riazuddin S, Ayyagari R, Hejtmancik JF, Riazuddin SA. Mutations in GRM6 identified in consanguineous Pakistani families with congenital stationary night blindness. Mol Vis 2015; 21:1261-71. [PMID: 26628857].

20. Kozuka T, Chaya T, Tamalu F, Shimada M, Fujimaki-Aoba K, Kuwahara R, Watanabe SI, Furukawa T. The TRPM1 Channel Is Required for Development of the Rod ON Bipolar Cell-AII Amacrine Cell Pathway in the Retinal Circuit. J Neurosci 2017; 37:9889-900. [PMID: 28899920].

21. Zhou X, Pardue MT, Iuvone PM, Qu J. Dopamine signaling and myopia development: What are the key challenges. Prog Retin Eye Res 2017; 61:60-71. [PMID: 28602573].

Articles are provided courtesy of Emory University and the Zhongshan Ophthalmic Center, Sun Yat-sen University, P.R. China. The print version of this article was created on 19 December 2019. This reflects all typographical corrections and errata to the article through that date. Details of any changes may be found in the online version of the article.