

Pediatrics

Bilateral simultaneous RIRS for calculus anuria in a 4 months male baby



Chandra Mohan Vaddi^{a,*}, Paidakula Ramakrishna^a, Siddaliga Swamy PM^a,
Soundarya Ganesan^a, Hemnath Anandan^b

^a Preeti Urology and Kidney Hospital, Hyderabad, Telangana, 500072, India

^b Preeti Urology and Kidney Hospital, 307, Remedy Hospital Lane, MIG1, KPHB Colony, Kukatpally, Hyderabad, Telangana, 500072, India

ARTICLE INFO

Keywords:

Infantile anuria
Bilateral RIRS
Paediatric RIRS

ABSTRACT

Treatment of pediatric stone disease is a challenge, more so, in the case of infants. Infantile anuria due to calculus disease is rare, as pre-renal causes predominate. Retrograde intrarenal surgery is a less often sorted modality in infants, due to the lingering skepticism regarding handling pediatric ureters and urethra. We hereby present the first case report of bilateral simultaneous RIRS, in a 4 month old male child. With better stone free rates than ESWL and a lesser incidence of major complications, we opted for RIRS in this child, taking advantage of the pre-stented ureter.

Introduction

Treatment of paediatric stone disease is a challenge, more so, in the case of infants. Infantile anuria due to calculus disease is rare, as pre-renal causes predominate. Retrograde intrarenal surgery (RIRS) is a less often sorted modality in infants, due to the lingering skepticism regarding handling paediatric ureter and urethra. We hereby present the first case report of bilateral simultaneous RIRS, in a 4 month old male child presenting with calculus anuria.

Case presentation

A 4 months male baby, weighing 4.5 kg, presented with anuria, fever and vomiting 20 days back, at a private hospital. On evaluation, he was found to have elevated creatinine (1.22 mg %), bilateral ureteric and bilateral renal calculi. Bilateral Double J (DJ) stenting was done and referred to us for further management. Urine routine showed pyuria, urine culture showed growth of *Klebsiella pneumoniae*. Ultrasound abdomen and Non contrast CT revealed Right renal calculi – 10mm, 5mm, and left kidney with multiple (4–5) calculi largest measuring 8mm, with bilateral DJ stents in situ (Fig. 1).

After adequate treatment with antibiotics and culture became sterile, baby was taken up for Bilateral RIRS. Under General Anaesthesia, bilateral ureteroscopy was done using 6/7.5Fr Ureteroscope after DJ stent removal. Ureters were found accommodable and calculi had

migrated to kidney.

8.5 Fr Flexible URS (Flex XC, Karl Storz, Germany) was passed over 0.032" Terumo guide wire, without access sheath, under fluoroscopic guidance. Pelvi-ureteric junction kink on both sides was negotiated with difficulty. Stones were powdered with Holmium laser (200 μm fibre, 8–10Hz, 0.5–0.8J, Quanta) and 3.5Fr, 16cm DJ stent placed; similar procedure was done for the contralateral renal stones. Bladder pressure was maintained low by continuous suprapubic aspiration (Fig. 2) (Video 1). Stents were removed on the 10th post operative day. Low dose CT at 4 weeks showed complete stone clearance (Fig. 2). Complete metabolic evaluation revealed hyperuricosuria (135 mg/day; Reference range <10.7 mg/kg/day). Stone analysis by infrared spectroscopy revealed mixed Ammonium acid urate and Calcium oxalate stone. We advised increased fluids, Potassium citrate (1.5mEq/kg twice daily) and long term follow up.

Supplementary video related to this article can be found at <https://doi.org/10.1016/j.eucr.2019.101085>.

Discussion

Paediatric stone disease is on the rising trend globally, but calculus anuria in infants remains uncommon. Pre-renal causes like gastroenteritis and hypotension, urologic causes like ureteropelvic junction obstruction, trauma to solitary kidney and fungal bolus obstruction have been reported.¹

* Corresponding author.

E-mail addresses: vcmohon2001@yahoo.co.uk (C.M. Vaddi), paidakula@hotmail.com (P. Ramakrishna), drsidda@gmail.com (S. Swamy PM), drsoundarya.ganesan@gmail.com (S. Ganesan), hemu_dr@yahoo.co.in (H. Anandan).

<https://doi.org/10.1016/j.eucr.2019.101085>

Received 11 October 2019; Received in revised form 28 November 2019; Accepted 2 December 2019

Available online 20 December 2019

2214-4420/© 2019 The Authors.

Published by Elsevier Inc.

This is an open access article under the CC BY-NC-ND license

(<http://creativecommons.org/licenses/by-nc-nd/4.0/>).

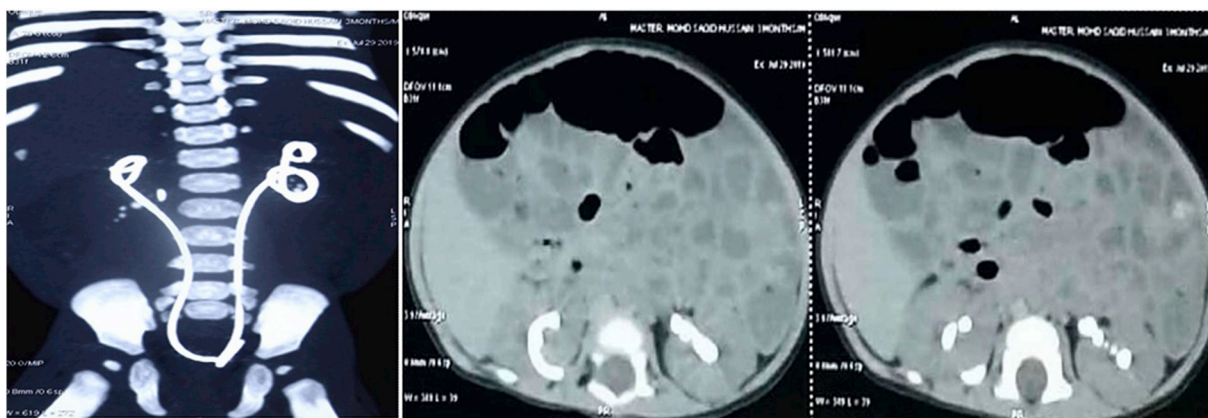

Fig. 1. Post Bilateral DJ stenting CT showing bilateral multiple renal calculi and bilateral DJ stent insitu.

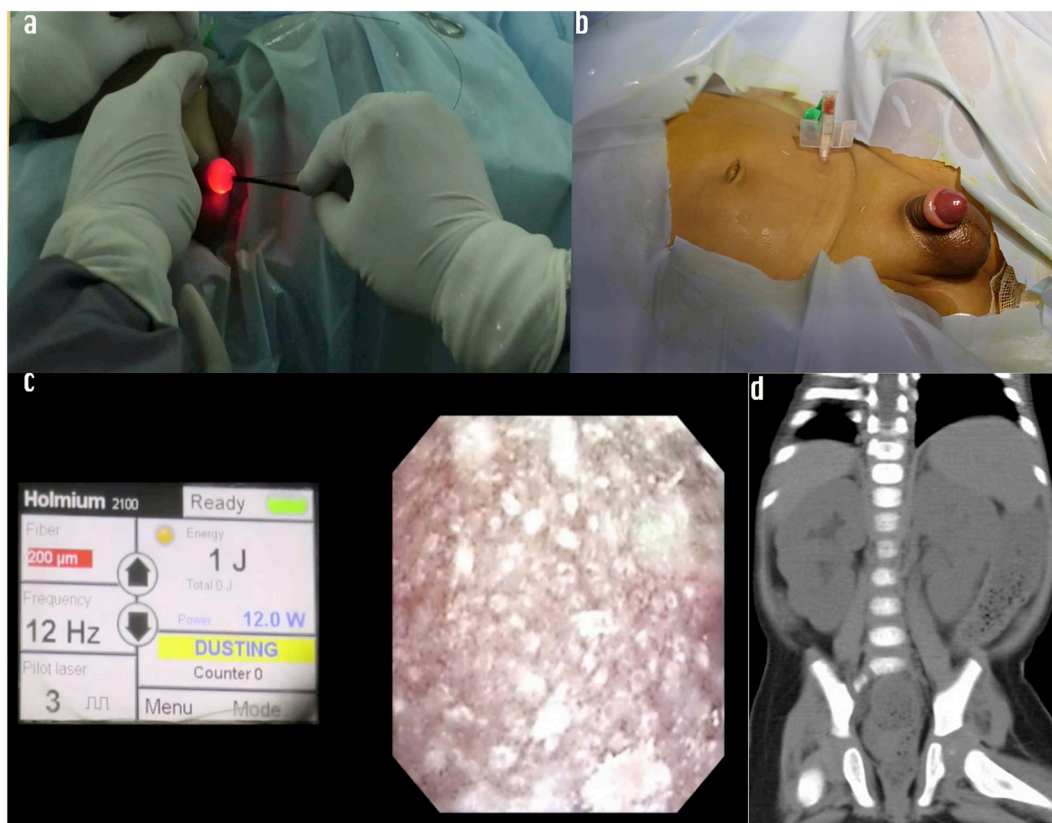


Fig. 2. (a) Intra-operative picture (b) Continuous bladder drainage by suprapubic aspiration (c) Laser settings and Popcorning (d) Post-operative CT showing no residual calculus.

Managing the renal stones in children is a tough task, as it is associated with anatomical or metabolic abnormalities and prone for recurrence. Although EAU and AUA guidelines recommend Shock wave lithotripsy as the first line for <10mm renal stones, it may not be the panacea in all circumstances. Up to 75% of the SWL patients would require multiple sessions, which would translate into multiple General anaesthesia sessions and radiation exposure. The high risk of steinstrasse especially with bilateral multiple renal stones is another major drawback. The chances of parenchymal damage, possible with Shockwave Lithotripsy (SWL), especially in such young kidneys, which are prone for recurrent stone formation, are a nightmare.

Jackman et al. underlined that creating a smaller tract will cause less tissue and nephron injury, and this was more important especially in pediatric patients with fragile kidneys of small sizes and described mini-

perc technique.² Despite all these modifications and high success rates, major complications such as adjacent organ injury, severe bleeding, and urosepsis have been reported up to 10% during Percutaneous Nephrolithotomy (PNL), and whether this method is actually a minimal invasive is still controversial.

Retrograde intrarenal surgery provides a higher immediate stone free rate and a lower additional treatment rate compared with SWL.³ Kim et al. reported on the largest series of paediatric RIRS (age group 3–218 months) for stone size averaging 6.1 mm and reported 100% success. He used access sheath in heavy stone burden cases only.⁴ Jun Li et al. evaluated the clinical value of flexible ureteroscopic lithotripsy for the treatment of upper urinary tract calculi in infants. They reported flexible URS in 55 infants (3–36 months) is a safe, highly efficient, minimally invasive, and reproducible surgery technique for therapy of

upper urinary tract calculi in infants.⁵

With the availability of miniature technology and expertise, advanced Laser technology and improved optics, we opted for bilateral RIRS in this child. Rarity of the association of obstruction bilaterally or unilaterally in a single functioning unit in infants within the first year of life may explain the shortage of publications.

Conclusion

With improved ureteroscopic access to the paediatric urinary tract and a lesser incidence of major complications, we opted for RIRS in this child, taking advantage of the pre-stented ureters and chance of offering better early complete stone clearance. This case is presented for the rarity in presentation and also to emphasise that bilateral simultaneous RIRS is a safe and feasible option in infants.

References

1. Aboutaleb H. Anuria in a 9-month-old infant resulting from ureteral cystine stones. *Korean J Urol.* 2011;52(9):647–649. <https://doi.org/10.4111/kju.2011.52.9.647>.
2. Jackman SV, Hedican SP, Peters CA, et al. Percutaneous nephrolithotomy in infants and preschool age children: experience with a new technique. *Urology.* 1998;52:697.
3. Wang W, et al. Comparing micro-percutaneous nephrolithotomy and retrograde intrarenal surgery in treating 1–2 cm solitary renal stones in pediatric patients younger than 3 years. *J Pediatr Urol.* 2019;15(5):517.e1–517.e6. <https://doi.org/10.1016/j.jpuro.2019.06.010>.
4. Kim SS, Kolon TF, Canter D, White M, Casale P. Pediatric flexible ureteroscopic lithotripsy: the children's hospital of Philadelphia experience. *J Urol.* 2008 Dec;180(6):2616–2619. <https://doi.org/10.1016/j.juro.2008.08.051>. discussion 2619, Epub 2008 Oct 31.
5. Li J, Xiao J, Han T, Tian Y, Wang W, Du Y. Flexible ureteroscopic lithotripsy for the treatment of upper urinary tract calculi in infants. *Exp Biol Med.* 2017;242(2):153–159. <https://doi.org/10.1177/1535370216669836>.