

Rupture of an isolated septal artery during diagnostic angiography in a patient with myocardial noncompaction

Myocardial noncompaction is characterized by prominent trabeculations, deep intertrabecular recesses, and a thick non-compacted endocardial myocardium. Its prevalence in the general population is still unclear, but echocardiography series report a prevalence rate of 0.05% (1). The coexistence of coronary anomaly and myocardial compaction is extremely rare (2). To the best of our knowledge, intramyocardial rupture of an isolated septal coronary artery was first defined in a patient with myocardial noncompaction and concurrent coronary anomalies.

In our case, coronary angiography was indicated because of effort dyspnea and regional wall motion abnormality on echocardiography. The right coronary artery (RCA) was normal (Video 1). On left coronary angiography, distal LAD was not observed in a usual route (Video 2). Beyond the RCA, two separate ostia were cannulated: a distal LAD (Video 3) and an isolated septal artery (Video 4). These conventional coronary angiography findings were also compatible with the findings of cardiac magnetic resonance imaging and computed tomography. Myocardial noncompaction was also confirmed by these imaging modalities (Fig. 1). Another LAD originating from a separate ostium in the right sinus and completing the missing part of distal LAD in the left coronary vasculature (Video 3) has been reported in a case (3). After cannulation of the RCA at left anterior oblique projection, the diagnostic catheter could be unintentionally engaged independently into the isolated septal artery. A relatively forceful injection, exceeding the capacity of the isolated septal artery (assumed to take a right anterior oblique image of the RCA), resulted in multiple intramyocardial ruptures that were treated conservatively and allowed to heal spontaneously (Video 5). Consequently, operators need to be careful if there is more than one ostium in the same sinus because the catheter tip might divert another ostium

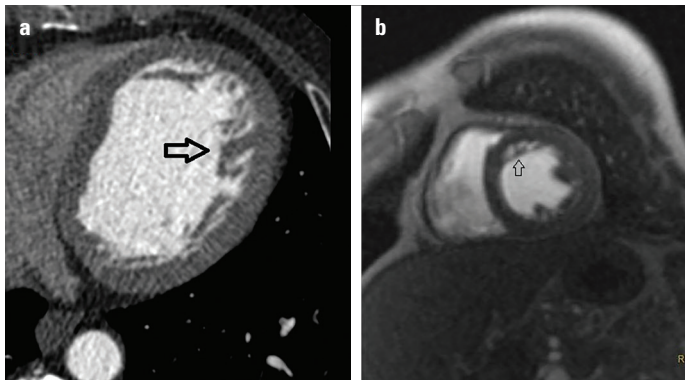


Figure 1. Multidetector computed tomography and cardiac magnetic resonance imaging confirmed the diagnosis of myocardial noncompaction (arrows)

independently and lead to coronary rupture owing to an unintentional forceful injection more than the capacity of the cannulated artery. Checking the catheter tip pressure prior to every injection could prevent such a complication during coronary angiography.

In conclusion, this is the first report to describe an iatrogenic rupture of an isolated septal artery by hand injection in a patient with coincidental myocardial and coronary anomalies.

Informed consent: Informed consent was obtained from the patient.

References

1. Ritter M, Oechslin E, Sütsch G, Attenhofer C, Schneider J, Jenni R. Isolated noncompaction of the myocardium in adults. *Mayo Clin Proc* 1997; 72: 26-31.
2. Mattsson G, Baroudi A, Tawfiq H, Magnusson P. Left ventricular non-compaction cardiomyopathy with coronary artery anomaly complicated by ventricular tachycardia. *BMC Cardiovasc Disord* 2017; 17: 263.
3. Daralammouri Y, Ghannam M, Lauer B. New congenital coronary artery anomaly-double supply of single left anterior descending coronary artery from the left and right coronary sinuses: a case report. *J Med Case Rep* 2016; 10: 211.

Video 1. Right coronary artery

Video 2. Left coronary system missing distal LAD

Video 3. Distal LAD originates from the right sinus

Video 4. Isolated septal artery originates from the right sinus

Video 5. Rupture of the isolated septal artery by hand injection during diagnostic coronary angiography

 **Mutlu Vural**,  **Fahrettin Katkat**

Department of Cardiology, Medical Sciences University, Bağcılar Training and Research Hospital; İstanbul-Turkey

Address for Correspondence: Dr. Mutlu Vural,

Sağlık Bilimleri Üniversitesi,
Bağcılar Eğitim ve Araştırma Hastanesi,
Kardiyoloji Bölümü,

Dr. Sadık Ahmet Cad., 34100,
İstanbul-Türkiye

Phone: +90 212 440 40 00

Fax: +90 212 440 42 42

E-mail: drmvural01@gmail.com

©Copyright 2019 by Turkish Society of Cardiology - Available online
at www.anatoljcardiol.com

DOI:10.14744/AnatolJCardiol.2019.47347