

REPLY TO SCOTT ET AL:

A closer look at the 3-rooted lower second molar of an archaic human from Xiahe

Shara E. Bailey^{a,b,1} , Kornelius Kupczik^b , Jean-Jacques Hublin^b, and Susan C. Antón^a

Scott et al. (1) take issue with our claim (2) that the presence of a 3-rooted lower molar (3RLM) in the Xiahe mandible (3) provides a morphological link between Denisovans and recent Asians. Below we address their main points:

- 1) Scott et al. (1) claim that our assessment is based on the “wrong” tooth. While it is true that the 3RLM is rare on M_2 , regardless of the tooth position, the 3RLM is strongly linked to Asia. At least one clinical study found the 3RLM on the M_2 to be 60% more frequent (2.8% vs. 1.7%) in Asian vs. non-Asian populations (4). Moreover, even if M_1 is the “key” tooth for the 3RLM, it does not follow that its presence on M_2 or M_3 represents a nonhomologous feature. There is precedence in the dental anthropological (5) and paleoanthropological (6) literature to view the same trait at different tooth positions as homologous.
- 2) Scott et al. (1) claim that Xiahe’s 3RLM is not equivalent to the “archetypal” 3RLM of Turner et al. (7). We reexamined the morphology of the Xiahe 3RLM using mCT coronal slices through the root and alveolus (Fig. 1 A–D). These scans show that the accessory root of the Xiahe M_2 has a mesial origin. In that sense, it might be considered different from the archetypal 3RLM of Turner et al. (7), which specifies a distolingual root. However, progressive sections through the root (Fig. 1 A–D) clearly show that Xiahe’s 3RLM is not a bifurcated mesial root, as Scott et al. (1) claim. The accessory root comprises a distinct radical that branches off lingually; and the mesial root maintains its 2 radicals and plate-like morphology throughout its length. Moreover, the accessory root sits squarely between the mesial and distal roots (Fig. 1 C and D).
- 3) Finally, we disagree with Scott et al.’s (1) claim that Xiahe’s 3RLM may be “simply the retention of an archaic trait” (emphasis ours). S.E.B. has not observed the 3RLM in any other fossil hominins from the Pliocene or Pleistocene. Furthermore, although we have not conducted a formal survey, we have not observed an accessory lingual root on any lower molars in the large collection of fossil hominin dental specimens CT scanned by the Department of Human Evolution of the Max Planck Institute for Evolutionary Anthropology.

In conclusion, while the slightly different morphological expression of the 3RLM of Xiahe may suggest some caution in our interpretation, we believe it is highly unlikely that these features are nonhomologous; and we find it an improbable coincidence that the nearly exclusively Asian 3RLM is also found (albeit in slightly different form) in Asian fossil hominins. A small difference in developmental timing can lead to slightly different expression of a genetically homologous trait. The answer to the questions of whether the 3RLM in Xiahe is homologous with the archetypal 3RLM and whether or not its occurrence in recent Asian groups is the result of introgression will ultimately lie in identifying the genetic mutation responsible (e.g., ref. 8).

^aCenter for the Study of Human Origins, New York University, New York, NY 10003; and ^bDepartment of Human Evolution, Max Planck Institute for Evolutionary Anthropology, 04103 Leipzig, Germany

Author contributions: S.E.B. designed research; S.E.B. performed research; S.E.B. analyzed data; and S.E.B., K.K., J.-J.H., and S.C.A. wrote the paper.

The authors declare no competing interest.

Published under the [PNAS license](#).

¹To whom correspondence may be addressed. Email: sbailey@nyu.edu.

First published December 17, 2019.

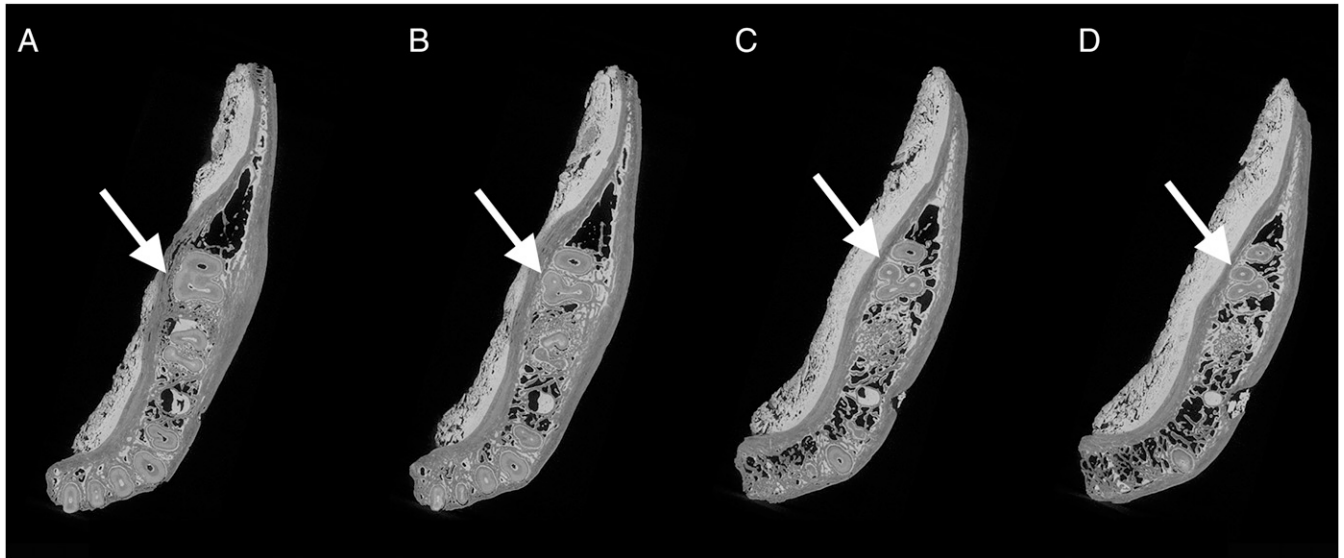


Fig. 1. Superior views of successive (neck-through-root: A–D) coronal mCT slices of the Xiahe mandible. Arrows point to the accessory root of the 3-rooted lower second molar, showing its origin from the mesial root (A), its separation (B), the maintenance of the mesial root with 2 radicals and a separate radical associated with the lingual accessory root (C), and lingual position of the accessory root between the mesial and distal roots (C and D).

- 1 G. R. Scott, J. D. Irish, M. Martín-Torres, Apples and oranges: A more comprehensive view of the Denisovan 3-rooted lower second molar from Xiahe. *Proc. Natl. Acad. Sci. U.S.A.* **117**, 37–38 (2020).
- 2 S. E. Bailey, J.-J. Hublin, S. C. Antón, Rare dental trait provides morphological evidence of archaic introgression in Asian fossil record. *Proc. Natl. Acad. Sci. U.S.A.* **116**, 14806–14807 (2019).
- 3 F. Chen *et al.*, A late Middle Pleistocene Denisovan mandible from the Tibetan Plateau. *Nature* **569**, 409–412 (2019).
- 4 J. A. B. Ferraz, J. D. Pécora, Three-rooted mandibular molars in patients of Mongolian, Caucasian and Negro origin. *Braz. Dent. J.* **3**, 113–117 (1993).
- 5 H. J. H. Edgar, Microevolution of African American dental morphology. *Am. J. Phys. Anthropol.* **132**, 535–544 (2007).
- 6 J. D. Irish, D. Guatelli-Steinberg, S. S. Legge, D. J. de Ruiter, L. R. Berger, Dental morphology and the phylogenetic “place” of *Australopithecus sediba*. *Science* **340**, 1233062 (2013).
- 7 C. G. Turner, II, C. R. Nichol, G. R. Scott, “Scoring procedures for key morphological traits of the permanent dentition: The Arizona State University Dental Anthropology System” in *Advances in Dental Anthropology*, M. Kelley, C. Larsen, Eds. (Wiley Liss, New York, NY, 1991), pp. 13–31.
- 8 E. Huerta-Sánchez *et al.*, Altitude adaptation in Tibetans caused by introgression of Denisovan-like DNA. *Nature* **512**, 194–197 (2014).