



## Protective effect of Yemeni green coffee powder against the oxidative stress induced by Ochratoxin A

Qais A. Nogaim<sup>a,1</sup>, Lakshmi Sai Pratyusha Bugata<sup>b,1</sup>, Prabhakar PV<sup>b</sup>, Utkarsh A. Reddy<sup>b</sup>, Mangala Gowri P<sup>b</sup>, Indu Kumari S<sup>b</sup>, Mahboob M<sup>b,\*</sup>

<sup>a</sup> Food Science and Technology Department, Ibb University, Yemen

<sup>b</sup> Toxicology Unit, Applied Biology Division, CSIR Indian Institute of Chemical Technology, Hyderabad, T.S., India

### ARTICLE INFO

#### Keywords:

Yemeni coffee  
Ochratoxin A  
Oxidative stress  
Toxicity  
Wistar rat

### ABSTRACT

The current study focusses on knowing the antioxidant effects of green Yemeni coffee powder on reducing the oxidative stress that was induced by Ochratoxin A in kidney, liver and brain of rats. The grouping of female albino Wistar rats was into 5 groups (5 rats/group). Rats of Group 1 designated Vehicle Control (only water), Group 2 (10 mg/kg Ochratoxin A); Group 3 designated Low dose (2000 mg/kg Coffee + 10 mg/kg Ochratoxin A); Group 4 designated High dose (4000 mg/kg Coffee + 10 mg/kg Ochratoxin A); Group 5 designated Coffee Control (1000 mg/kg Coffee) and orally administered with the above test materials repeatedly every day for 28 days. On termination of the study, liver, brain and kidney tissues were collected after dissection, oxidative stress biomarkers (Levels of Lipid Peroxidation and Reduced Glutathione, activities Superoxide Dismutase, Catalase and Glutathione Reductase enzymes) and histopathological studies were carried out. Treatment of Ochratoxin A alone (group 2 rats) significantly increased malondialdehyde content, catalase, and glutathione reductase activities with a decrease in the activity of superoxide dismutase enzyme and reduced glutathione level and in brain, kidney and liver. Whereas, low dose coffee (group 3) and high dose coffee (group 4) rats showed dose-dependent increase in antioxidant and less histopathological alterations. Concomitant treatment of Yemeni green coffee powder and Ochratoxin A brought dose-dependent protective effects against oxidative stress which was induced using Ochratoxin A in liver, brain, and kidney tissues of female rats.

### 1. Introduction

Coffee beans cultivation in tropical and sub-tropical countries [1]. Coffee is world's popular beverages traded and consumed food commodity [2]. Coffee is a complex drink containing, 1000 compounds other than caffeine, its lovely flavor, and aroma [3]. In the human diet, it is a source of caffeoyl-quinic acids known as intense antioxidant agents [4]. Studies with model frameworks demonstrated that among all active constituents of coffee, the carbohydrates are, for the most part, in charge of the development of oxygen scavenging substances [5].

Our interest is to find out the potential antioxidant activity of this Yemeni green coffee against the oxidative stress produced after induction using toxin. Ochratoxin A is produced by species of the fungal genera like *Penicillium* and *Aspergillus*, it is a mycotoxin found in products based on grains and cereals, and it has an oxidative stress-inducing property [6]. Ochratoxin A causes a toxicological effects like

genotoxicity, nephrotoxicity, nephron-carcinogenicity, teratogenicity, neurotoxicity, and immune-toxicity in animal models [7] and also found to cause embryotoxicity [8]. Ochratoxin A is a Class 2B carcinogen classified by the International Agency for Research on Cancer [9]. Till date Ochratoxin A stands out to be the highly potent renal carcinogen [10]. The mechanism of toxicity by Ochratoxin A is with inhibition of protein, RNA and DNA syntheses, DNA adducts formation, dysfunction of mitochondria, calcium homeostasis disruption, and the reactive oxygen species (ROS) production [11,12]. In a research work Ochratoxin A showed ROS formation, increased lipid peroxidation, and oxidative DNA damage [13]. In a study carried out on rat proximal tubular cells Ochratoxin A lead to an increased ROS levels, depleted reduced glutathione levels with an increased oxidative damage of cfDNA which was also observed in LLC-PK1 cells [13–15]. Several antioxidants got reported showing protection against Ochratoxin A-induced hepato-renal toxicity [15]. So, we have designed this present study to estimate the potency of Yemeni green coffee in showing the

\* Corresponding author at: Applied Biology Division, CSIR - Indian Institute of Chemical Technology, Hyderabad, 500 007, Telangana, India  
E-mail address: [mahboobm1983@gmail.com](mailto:mahboobm1983@gmail.com) (M. M).

<sup>1</sup> Authors contributed equally and considered as the first author

defensive activity against Ochratoxicosis in rats, by estimating the antioxidant parameters of brain, liver, and kidney tissues of rats administered with Ochratoxin A alone, in combination with different doses of coffee powder. Korean ginseng tea (KGT) consists of antioxidants like coffee resulted an increment in levels of lipid peroxidation and diminished levels in reduced glutathione, enzyme activities such as glutathione reductase, catalase, glutathione-S-transferase, glutathione peroxidase and superoxide dismutase found to be restored to ordinary levels. This KGT proved defensive activity against stress generated in rat models of ischemia [16]. Literature suggests the possible presence defensive activity in Yemen green coffee.

## 2. Materials and methods

### 2.1. Test compound

Yemeni green coffee beans (*Coffea Arabica*) were procured from Yemen Standardization Metrology and Quality Control Organization (YSMQCO), Yemen, 70 samples of Yemeni green coffee beans (*Coffea arabica* L.), were collected YSMQCO from many local places in some Yemeni Governorates during 2010/2011.

### 2.2. Chemicals and reagents

Glutathione reductase (GR), Ethylenediamine tetra acetic acid disodium salt, Nicotinamide adenine phosphate ( $\beta$ -NADPH), Pyrogallol, Trichloroacetic acid (TCA), 2-thiobarbituric acid (TBA), Sodium citrate, 1-chloro-2,4-dinitrobenzene, Reduced glutathione (GSH), Hydrogen peroxide ( $H_2O_2$ ), 5,5-dithiobis-2-nitrobenzoic acid (DTNB), 5-sulphosalicylic acid, Hydrochloric acid, Nitric acid, trace metals grade perchloric acid, and n-butanol were procured from Sigma Aldrich, USA.

### 2.3. Treatment and animals

The female albino Wistar rats which are 8–10 weeks old with body weights ranging between 100 and 130 g were bought from ICMR-NIN, India. These rats were allowed to acclimatize in our institutional animal house for a week before initiation of the experiment and were maintained with standard laboratory conditions like  $22 \pm 2^\circ C$  temperature, 50–60% of relative humidity, 12-h light and 12-h dark cycles, fed with pellet diet and water *ad libitum*. The doses and experimentation were designed following OECD guideline 407 [17]. These in-vivo experimental procedures were pre-approved by the Institutional Animal Ethics Committee of IICT holding File No: IICT/BIO/TOX/PG/21-03-2014.

### 2.4. Experimental design

Twenty-five female albino Wistar rats were grouped into five different treatment groups. Each group comprises five animals. Ochratoxin A and coffee powder were suspended in water, rats were treated orally by gavage daily for 28 days.

Group 1: Vehicle Control (water).

Group 2: Ochratoxin A  $\frac{1}{2}$  of  $LD_{50}$  (10 mg/kg bw).

Group 3: Low Dose Coffee (2000 mg/kg.bw) + Ochratoxin A (10 mg/kg bw).

Group 4: High Dose Coffee (4000 mg/kg.bw) + Ochratoxin A (10 mg/kg bw).

Group 5: Coffee control (1000 mg/kg).

During the treatment period of this study the body weight, feed intake and toxic symptoms in rats were recorded. Rats were sacrificed on the termination of study by cervical dislocation kidney, brain and liver tissues of rats from all the groups were dissected out, weighed, assayed for oxidative stress parameters and histopathology.

### 2.5. Oxidative stress estimation

#### 2.5.1. Lipid peroxidation

The end product of lipid peroxidation the Malondialdehyde (MDA) content formed was estimated in liver, brain and kidney tissues as per Wills [18] protocol with slight modifications. Tissue homogenate of the 200 ml aliquot was reacted with 2 ml of TBA and TCA reagent, after making up the volume to 3 ml with distilled water this mixture was subjected to boiling for 20 min at  $95^\circ C$  on a water bath. The end product of the reaction, i.e., TBA–MDA complex was extracted after the addition of n-butanol. The pink-coloured extract was measured at 532 nm using Spectramax Plus, Molecular Devices spectrophotometer. The level of MDA was determined using  $1.56 \times 10^5 M^{-1} cm^{-1}$  molar extinction coefficient expressed in nano moles of MDA formed per gram of wet tissue.

#### 2.5.2. Reduced glutathione

The GSH level was determined in the kidney, liver, and brain tissue homogenates according to the protocol of Jollow [19]. The GSH content was expressed in  $\mu g$  per gram wet tissue. Each tissue homogenate of 0.5 ml aliquot was allowed to incubate with 0.5 ml of sulfosalicylic acid (4% w/v) for 1 h in ice and centrifuged for 10 min at 10,000 rpm. 0.4 ml of DTNB (4 mg/ml in 5% sodium citrate) and 2.2 ml KPB (0.1 M, pH 7.4) was mixed with 0.4 ml supernatant. The developed yellow colour was measured at 412 nm. The GSH content was expressed as micrograms GSH per gram wet tissue.

#### 2.5.3. Superoxide dismutase

The activity of liver, kidney, and brain Superoxide Dismutase (SOD) was estimated by following the procedure of Marklund & Marklund [20]. A 3 ml aliquot of assay mixture composed of 50 mM Tris–HCl buffer, 1 mM diethylene triamine penta acetic acid, 45 ml of 10 mM pyrogallol in 10 mM HCl and 10 ml of tissue supernatant. The SOD activity was expressed in units per mg protein of tissues. A single unit of activity is the amount required for 50% inhibition of pyrogallol auto-oxidation. The content of protein in the tissue supernatant was estimated using standard Bovine serum albumin following the protocol of Lowry [21].

#### 2.5.4. Catalase

The activity of Catalase (CAT) enzyme was determined in kidney, liver and brain following Aebi's protocol [22], 3 ml of reaction mixture contained 0.1 M KPB, 0.063%  $H_2O_2$  and 10 ml of supernatant of tissue homogenate. The absorbance was read for 1 min at 240 nm. The CAT enzyme activity was expressed in mmole of  $H_2O_2$  decomposed per minute per milligram protein using  $43.6 M^{-1} cm^{-1}$  molar extinction coefficient. The CAT activity was expressed as units per milligram protein.

#### 2.5.5. Glutathione reductase

Glutathione reductase (GR) activity of the brain, kidney, and liver was determined by the procedure of Carlberg & Mannervik [23]. In 3 ml assay mixture consists 50 mM KPB, 1.0 mM oxidized glutathione, 0.15 mM  $\beta$ -NADPH and 0.01% (w/v) bovine serum albumin, 20 ml of tissue supernatant was added. This mixture was thoroughly mixed and the change in absorbance was recorded at 340 nm. The GR activity was expressed as micromoles  $\beta$ -NADPH decomposed per minute per milligram protein using  $6.22 \times 10^3 mmol^{-1} cm^{-1}$  molar extinction coefficient. This activity was given in units per milligram protein.

### 2.6. Histopathology

The brain, liver, and kidney tissues from control and all the treated rats were preserved in formalin and used for histopathology study. The Leica TP 1020 automatic tissue processor was used for processing tissues, embedder Leica EG 1160 for embedding in paraffin, a thin ribbon

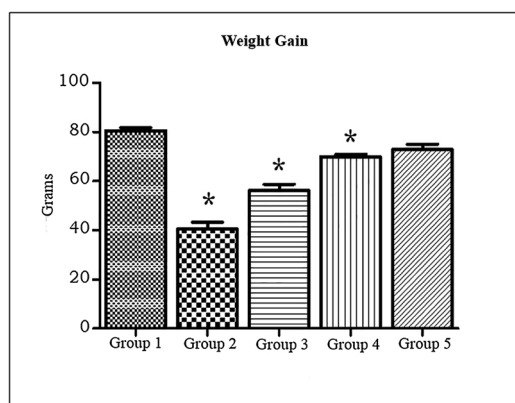


Fig. 1. Repeated dose effects of Ochratoxin A & Coffee on Body Weight Gain of rats, n = 5 in each group and \*P < 0.05.

of 3–5 micron was cut on a microtome (Microm HM 360), stained in strainer (Microm HMS-70) and finally, hematoxylin and eosin were used for staining the slides. The mounted slides were examined for tissue damage under the Olympus BX51 microscope.

### 2.7. Statistical analysis

Results were expressed in Mean  $\pm$  standard deviation (SD) format. The p-value was calculated using one-way ANOVA followed by a Dunnett's test to compare the treated groups with control groups (control vs. treated) by Graph Pad Prism statistical software. A value of P < 0.05 was taken to be significant.

## 3. Results

### 3.1. Body weights

Ochratoxin A alone treated rats showed significant body weight loss when compared to controls. Whereas, increase in the body weight gain in a dose-dependent manner was noted in rats treated with low dose and high dose of coffee when compared to controls (Fig. 1). The weight loss was about 50% in the toxin group, 29% and 13% weight loss was observed in toxin and coffee concomitantly treated in low and high doses when compared with control group.

### 3.2. Oxidative stress estimations

#### 3.2.1. Lipid peroxidation

Ochratoxin A treatment lead to a significantly increased levels of MDA in the kidney (36%), liver (57%), and brain (50%) tissues (Fig. 2).

Whereas, together treatment of Ochratoxin A and coffee brought a dose and tissue-dependent decrease, about 29% in liver, 18% in kidney, 11% in brain tissues of group3 when compared to control indicating decreased levels in comparison with group2 and no significant alteration in group 4 in comparison with control MDA level in kidney, liver and brain (Fig. 2 A, B, C).

#### 3.2.2. Reduced glutathione

Ochratoxin A significantly reduced the GSH levels when compared to that of the control group, 17% reduction in liver, 18% reduction in kidney, 27% reduction in brain, and simultaneous treatment of Ochratoxin A and coffee resulted to dose and a tissue-dependent increase in GSH level in liver, brain and kidney of rats when compared with toxin group, in comparison with controls group3 showed 11% reduction in liver GSH, 20% reduction in brain GSH and group4 didn't get reduced much when compared to controls indicating the coffee's dose-dependent antioxidant property (Fig. 3).

#### 3.2.3. Superoxide dismutase activity

Superoxide Dismutase activity in kidney, liver, and brain found to be decreased significantly upon treatment with Ochratoxin A which was about 43% decrement of activity in liver, 28% decrement of activity in the kidney, 33% decrement of activity in the brain (Fig. 4). However, the concomitant treatment of a low and high dose of coffee along with Ochratoxin A showed dose and tissue-dependent recovery in Superoxide Dismutase activity (Fig. 4 A, B, C) when compared with coffee controls.

#### 3.2.4. Catalase activity

The Catalase enzyme activity in kidney, brain and liver of Ochratoxin A treated rats was significantly increased showing 27% increased activity in liver, 30% increased activity in kidney, 33% increased brain CAT activity whereas; this CAT activity in animals treated with low and high doses of coffee along with Ochratoxin A revealed dose and tissue-specific recovering returning to the normal levels of CAT activity (Fig. 5 A, B, C).

#### 3.2.5. Glutathione reductase

The Glutathione reductase (GR) enzyme activity in the Ochratoxin A treated rat tissues was found to be significantly elevated whereas accompanying treatment of Ochratoxin A and coffee in both low and high doses normalized the Glutathione reductase activity almost nearer to controls (Fig. 6). The liver found to be more affected, followed by kidney and brain when compared to coffee control (Fig. 6 A, B, C).

### 3.3. Histopathology

Photomicrograph of the brain, liver, and kidney of Ochratoxin A,

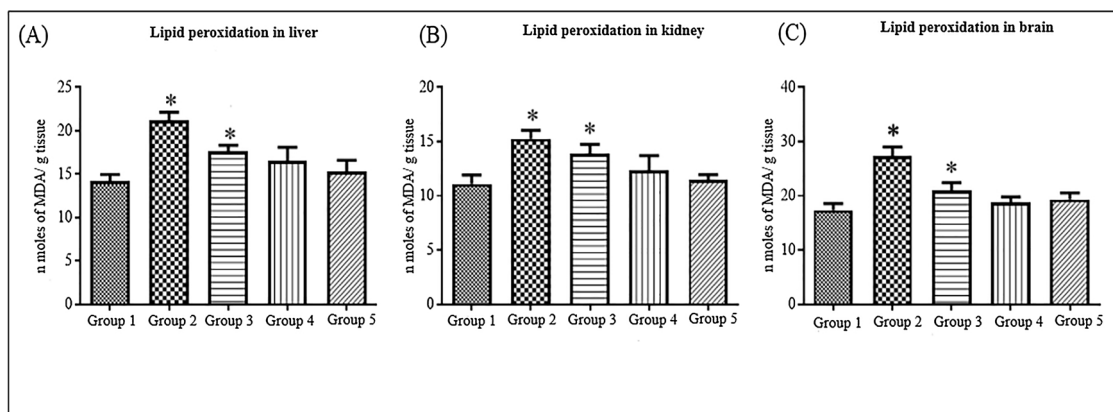


Fig. 2. Repeated dose effects of Ochratoxin A & Coffee on lipid peroxidation in (A) Liver, (B) Kidney and (C) Brain of rat, n = 5 in each group and \*P < 0.05.

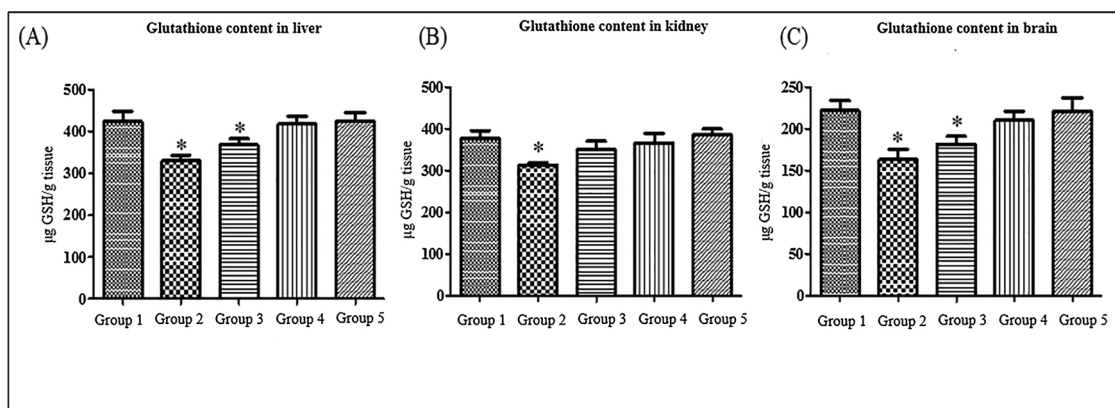


Fig. 3. Repeated dose effects of Ochratoxin A & Coffee on reduced glutathione level in (A) Liver, (B) Kidney and (C) Brain of rat,  $n = 5$  in each group and  $*P < 0.05$ .

Ochratoxin A + coffee low dose and Ochratoxin A + coffee high dose treated tissues are presented in Fig. 7. Ochratoxin A treated liver showed dilated vein and kidney revealed degeneration with necrosis and damaged to Bowman's capsule. Parallel treatment of Ochratoxin A and a high dose of coffee showed no histological changes in all the three tissues (liver, kidney, and brain), whereas Ochratoxin A and a low dose of coffee showed mild dilation in the liver and low necrosis in the kidney. However, brain revealed no histological changes in Ochratoxin A alone treatment and combined Ochratoxin A and coffee treated rats.

#### 4. Discussion

Coffee is the most much of the time devoured caffeine-containing beverage. It was reported that coffee possesses antioxidant activity [24]. Ochratoxin A showed to cause an imbalance between oxidant and antioxidant parameters in kidney and liver tissues of rat [25]. It also showed increased ROS production causing cytotoxicity in rat and monkey kidney cell lines [14].

The lipid peroxidation is a natural process occurring in the living system in small amount by several ROS. The current study revealed enhanced lipid peroxidation end product in Ochratoxin A treated rats that might have led to increase in the production of ROS such as  $O^{\cdot -2}$ ,  $H_2O_2$ , free radicals in the treated tissues. These ROS in turn might have attacked the polyunsaturated fatty acids belonging to the fatty acid membrane of liver, kidney and brain tissues and thus initiated a chain reaction which is self-propagating and destructed the lipid membrane and lipid peroxidation reactions, MDA levels of brain, liver, and kidney tissues finally affects the viability of cells of the tissues [26]. However, low and high doses of Coffee treatment brought dose, and tissue-specific reduction in MDA level showed a reversal of enhanced MDA level

towards normalization. The reduced glutathione is a powerful non-enzymatic antioxidant which prevents essential cellular components damage generally mediated by ROS. In the present investigation, Ochratoxin A treatment depleted the reduced glutathione level significantly in the treated tissues. This decrease in reduced glutathione level might be due to the high utilization of reduced glutathione for quenching ROS produced due to enhanced lipid peroxidation process observed in the treated rats. The study further suggests that low reduced glutathione content noted might also have hampered reduced glutathione-mediated detoxification of Ochratoxin A.

The superoxide dismutase enzyme is involved in catalyzing the breakdown of  $H_2O_2$  to  $H_2O$  and  $O_2$ . It is an essential enzymatic antioxidant for cells exposed to oxygen-free radicals. Our results showed a significant decrease in SOD activity in brain, liver and kidney tissues of Ochratoxin A treated rats. The SOD activity inhibition in treated tissues might be due to high catalytic activity of Superoxide dismutase for dismutation of  $O_2^{\cdot -}$  to  $O_2$ , and  $H_2O_2$  conversion to molecular oxygen produced by Ochratoxin A treatment. Superoxide dismutase is considered to be the first line of defense in detoxifying the oxygen radicals. Since Ochratoxin A treatment depleted the superoxide dismutase activity which might lower superoxide dismutase dependent protection of the cells against oxygen radicals. The significant induction of glutathione reductase and catalase activities of these enzymes noted in this study might be due to high utilization of these enzymes in catalytic conversion of a high quantity of  $H_2O_2$  to  $H_2O$  by catalase and regeneration of reduced glutathione from GSSG by the catalytic action of GR.

A past report that explored the antioxidant effect of coffee brew in rats subjected for 28-day treatment showed elevated activities of hepatic superoxide dismutase, catalase, and glutathione peroxidase, with

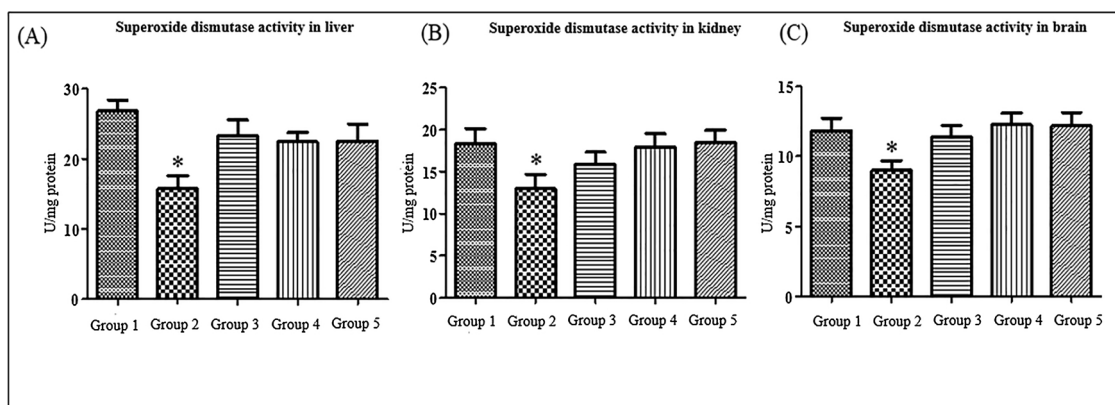


Fig. 4. Repeated dose effects of Ochratoxin A & Coffee on the activity of superoxide dismutase enzyme in (A) Liver, (B) Kidney and (C) Brain of rat,  $n = 5$  in each group and  $*P < 0.05$ .

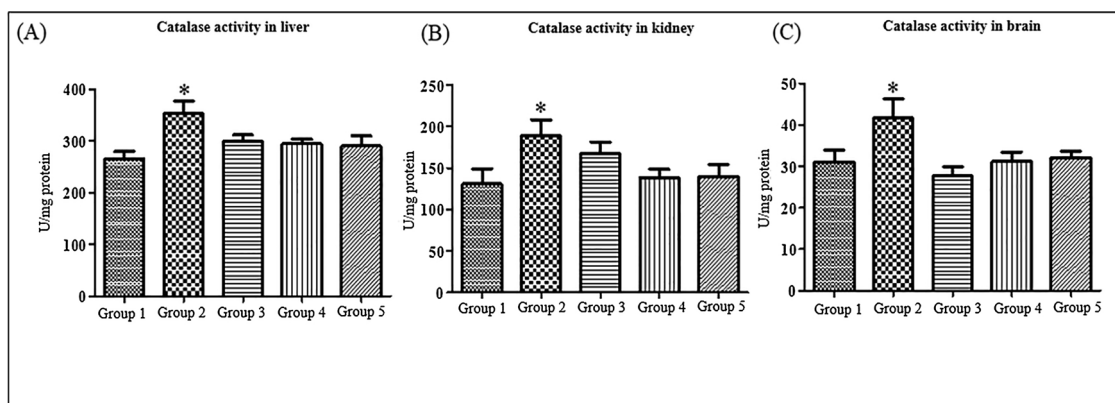


Fig. 5. Repeated dose effects of Ochratoxin A & Coffee on the activity of catalase enzyme in (A) Liver, (B) Kidney and (C) Brain of rat, n = 5 in each group and \*P < 0.05.

25.1% inclination of the total antioxidant capacity of the hepatic tissue, enhancing the protective effect against oxidative damage [27]. A study on the influence of plasma antioxidant capacity in humans disclosed that molecules like phenolic compounds are possibly causing increased plasma antioxidant capacity associated with coffee intake [24]. The antioxidant activity of green coffee was slightly higher than that of the roasted coffee [28].

Supplementation of low and high doses of coffee powder to the Ochratoxin A treated rats exhibited dose and tissue-dependent significant reversion of activities of SOD, CAT, GR and also MDA, and GSH levels. It was observed that the changes in the activities of these enzymes reaching to the control levels suggested that coffee treatment was restoring the normal levels of these enzymes and thus revealing beneficial and protective effects under adverse condition caused by Ochratoxin A treatment. These observations are clear evidence that coffee treatment increases the antioxidant capacity of the treated rats and thus capable of bringing antioxidant normalization. The alone coffee treatment did not show any significant modulation in any of the non-enzymatic and enzymatic antioxidant levels revealing that under oxidative stress condition only, coffee exhibit the beneficial effects and neutralize the increased ROS. In a study the results of cellular oxidative status markers such as GSH and MDA, ROS and enzyme activities of glutathione peroxidase (GPx) and GR showed prior treatment with 0.5–10 µg/mL doses of digested coffee melanoidin for a period of 2 or 20 h to HepG2 cells prevented damage to the cells caused by *tert*-butyl hydroperoxide (*t*-BOOH) [29]. Overall the results of current study reveals that Ochratoxin A has the potential to increase the ROS production due to enhancing LPO process, by modulation in the inherent antioxidants levels such as GSH, CAT, SOD, GR, causes histopathological effects and thus leads to oxidative damage in the treated kidney, liver,

and brain tissues of rat. On a contrast, the concomitant supplementation of different doses of coffee powder restored the antioxidant defenses significantly by bringing the antioxidants levels to the near control or optimum and by lowering the lipid peroxidation process. Our findings provide scientific evidence of the protective effects of coffee powder against oxidative damages caused by Ochratoxin A in the liver, brain and kidney of treated rats when Ochratoxin A was orally given for 28 days.

Treatment of animals with Ochratoxin A alone induced histological changes in liver tissue such as dilatation of the veins and necrosis, whereas, kidney and liver showed degeneration hampering the normal function of these tissues. In contrast, concomitant treatment of Ochratoxin A and coffee high dose showed no such changes indicating that Ochratoxin A not only upset the oxidant and antioxidant balance but also causing tissue injury. However low dose coffee and Ochratoxin A revealed slight histological changes indicating the low dose of coffee was not therapeutically efficient in suppression of histological changes induced by Ochratoxin A. It can also be concluded that antioxidant defensive activity of coffee might have been the possible cause for not showing any histological damage in liver, brain and kidney tissues in combined Ochratoxin A and coffee doses. In a study, Abnormal changes like patches of dilation and congestion of massive hyaline degeneration were observed in both liver and kidney functions and structural change in Ochratoxin A contaminated coffee seeds treated mice for 8 weeks [30]. Ochratoxin A treated rats showed glomerular capillaries narrowing and obliteration, with reduced and disappeared urinary space in glomeruli [12]. Histopathological evaluation revealed that Ochratoxin A alone treatment brought tissue damage, the liver and kidney showed tissue degeneration, hemorrhages, and tubular necrosis respectively. Similar results were reported such as formation of glomerular lesions,

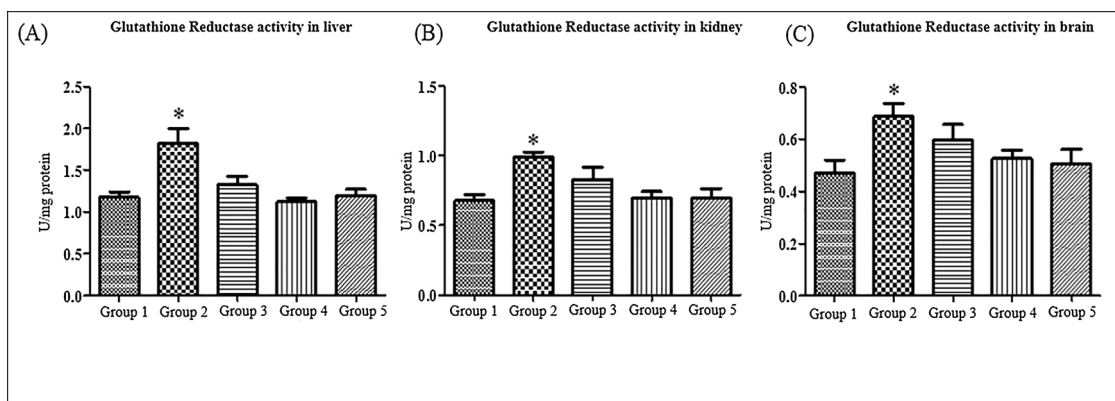


Fig. 6. Repeated dose effects of Ochratoxin A & Coffee on the activity of glutathione reductase enzyme in (A) Liver, (B) Kidney and (C) Brain of rat, n = 5 in each group and \*P < 0.05.

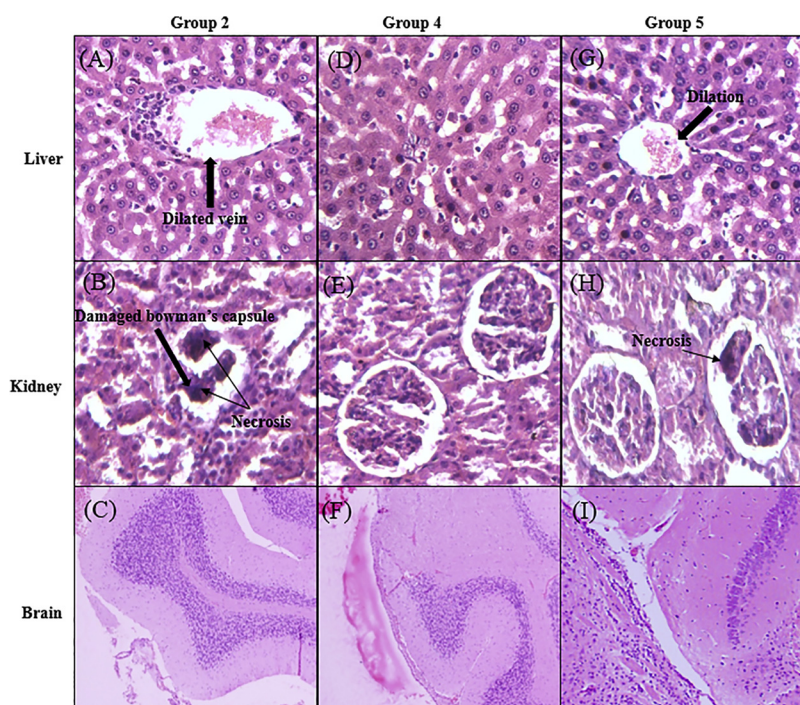


Fig. 7. Histopathology of rat tissues after 28 days repeated dosing of Ochratoxin A & Coffee, A, B, C – Liver, Kidney and Brain histopathology images of Ochratoxin A treated animals; D,E,F- Liver, Kidney and Brain histopathology images of animals treated with Ochratoxin A and high dose of coffee, G,H,I- Liver, Kidney and Brain histopathology images of animals treated with coffee.

renal corpuscular malfunction, reduction of kidney physiology leading to kidney failure [31]. It was reported that Ochratoxin-A showed histopathological alterations on kidney tissues where hydropic degeneration, vacuolar degeneration, and pyknotic nuclei were observed in tubular epithelial cells, hyaline casts and debris in tubular lumina were observed [32]. These histological changes can be the expected possible toxic response to Ochratoxin A [33].

From the present study based on the antioxidant parameters and histopathology studies carried out, it can be inferred that the antioxidant potential of coffee has provided the protective effect against oxidative stress induced by Ochratoxin A to a significant extent.

## 5. Conclusion

The results of the present biochemical oxidant parameters and histopathology study show that Yemeni green coffee alone, in concomitant treatment with toxin at high doses and low doses have increased antioxidant capacity with minor histological alteration when compared with toxin group. Yemeni green coffee has significantly suppressed the oxidative stress generated by Ochratoxin-A. Based on this we can presume that green Yemeni coffee powder represents a good functional food having a potential of boosting the antioxidant capacity in liver, brain, and kidney of rats in induced with toxicity using Ochratoxin A and thus protecting them from oxidative stress and tissue damage.

## Declaration of Competing Interest

This particular research has no conflict of interest.

## Acknowledgment

We the authors are thankful to the Director, CSIR-IICT, Hyderabad, for providing facilities and funding for this study. IICT Manuscript Communication Number is IICT/Pubs./2019/304.

## References

- [1] A.P. Davis, F. Rakotonasolo, New species of Coffea l. (Rubiaceae) from Madagascar, *Bot. J. Linn. Soc. Bot. J. Linn. Soc. Sci. Bot. J. Linn. Soc.* 142 (2003) 111–118
- [2] K. Fujioka, T. Shibamoto, Chlorogenic acid and caffeine contents in various commercial brewed coffees, *Food Chem.* 106 (2008) 217–221, <https://doi.org/10.1016/J.FOODCHEM.2007.05.091>.
- [3] E. Gonzalez de Mejia, M.V. Ramirez-Mares, Impact of caffeine and coffee on our health, *Trends Endocrinol. Metab.* 25 (2014) 489–492, <https://doi.org/10.1016/j.tem.2014.07.003>.
- [4] C.J. Dupas, A.C. Marsset-Baglieri, C.S. Ordonaud, F.M.G. Ducept, M.-N. Maillard, Coffee antioxidant properties: effects of milk addition and processing conditions, *J. Food Sci.* 71 (2006) S253–S258, <https://doi.org/10.1111/j.1365-2621.2006.tb15650.x>.
- [5] B. Cämmerer, L.W. Kroh, Antioxidant activity of coffee brews, *Eur. Food Res. Technol.* 223 (2006) 469–474, <https://doi.org/10.1007/s00217-005-0226-4>.
- [6] Y. Tao, S. Xie, F. Xu, A. Liu, Y. Wang, D. Chen, Y. Pan, L. Huang, D. Peng, X. Wang, Z. Yuan, Ochratoxin A: toxicity, oxidative stress and metabolism, *Food Chem. Toxicol.* 112 (2018) 320–331, <https://doi.org/10.1016/j.fct.2018.01.002>.
- [7] H.A. Clark, S.M. Snedeker, Ochratoxin a: its Cancer risk and potential for exposure, *J. Toxicol. Environ. Health B* 9 (2006) 265–296, <https://doi.org/10.1080/15287390500195570>.
- [8] M. Al Jabir, A. Barcaru, A. Latiff, M. Jaganjac, G. Ramadan, P. Horvatovich, Dietary exposure of the Qatari population to food mycotoxins and reflections on the regulation limits, *Toxicol. Reports.* 6 (2019) 975–982, <https://doi.org/10.1016/j.toxrep.2019.09.009>.
- [9] M. Kujawa, Some Naturally Occurring Substances: Food Items and Constituents, Heterocyclic Aromatic Amines and Mycotoxins. IARC Monographs on the Evaluation of Carcinogenic Risks to Humans, Vol. 56. Herausgegeben Von Der International Agency for Research on Cancer, world Health Organization. 599 Seiten, Zahr. Abb. Und Tab. World Health Organization. Geneva 1993. Preis: 95, — Sw.fr; 95,50 US \$, Food / Nahrung, (1994), <https://doi.org/10.1002/food.19940380335> 38 351–351.
- [10] M. Adler, K. Müller, E. Rached, W. Dekant, A. Mally, Modulation of key regulators of mitosis linked to chromosomal instability is an early event in ochratoxin A carcinogenicity, *Carcinogenesis.* 30 (2009) 711–719, <https://doi.org/10.1093/carcin/bgp049>.
- [11] M. Marin-Kuan, S. Nestler, C. Verguet, C. Bezençon, D. Piguet, R. Mansourian, J. Holzwarth, M. Grigorov, T. Delatour, P. Mantle, C. Cavin, B. Schilter, A toxicogenomics approach to identify new plausible epigenetic mechanisms of ochratoxin a carcinogenicity in rat, *Toxicol. Sci.* 89 (2006) 120–134, <https://doi.org/10.1093/toxsci/kfj017>.
- [12] E. Rached, G.C. Hard, K. Blumbach, K. Weber, R. Draheim, W.K. Lutz, S. Özden, U. Steger, W. Dekant, A. Mally, A. Ochratoxin, 13-week oral toxicity and cell proliferation in male F344/N rats, *Toxicol. Sci.* 97 (2007) 288–298, <https://doi.org/10.1093/toxsci/kfm042>.
- [13] A.R. Meki, A.A. Hussein, Melatonin reduces oxidative stress induced by ochratoxin A in rat liver and kidney, *Comp. Biochem. Physiol. C Toxicol. Pharmacol.* 130 (2001) 305–313 (accessed May 1, 2018), <http://www.ncbi.nlm.nih.gov/pubmed/11701387>.
- [14] G. Schaaf, S. Nijmeijer, R.F. Maas, P. Roestenberg, E. de Groene, J. Fink-Gremmels, The role of oxidative stress in the ochratoxin A-mediated toxicity in proximal tubular cells, *Biochim. Biophys. Acta - Mol. Basis Dis.* 1588 (2002) 149–158, [https://doi.org/10.1016/S0925-4439\(02\)00159-X](https://doi.org/10.1016/S0925-4439(02)00159-X).

- [15] A. Yenilmez, B. Isikli, E. Aral, I. Degirmenci, E. Sutken, C. Baycu, Antioxidant effects of melatonin and coenzyme Q10 on oxidative damage caused by single-dose ochratoxin A in rat kidney, *Chin. J. Physiol.* 53 (2010) 310–317 (accessed May 1, 2018), <http://www.ncbi.nlm.nih.gov/pubmed/21793342>.
- [16] Z.A. Shah, R.A. Gilani, P. Sharma, S.B. Vohora, Cerebroprotective effect of Korean ginseng tea against global and focal models of ischemia in rats, *J. Ethnopharmacol.* 101 (2005) 299–307, <https://doi.org/10.1016/j.jep.2005.05.002>.
- [17] Test No. 407: Repeated Dose 28-day Oral Toxicity Study in Rodents, OECD Publishing, 2008, <https://doi.org/10.1787/9789264070684-en>.
- [18] E.D. Wills, Lipid peroxide formation in microsomes. The role of non-haem iron, *Biochem. J.* 113 (1969) 333–341 [http://www.ncbi.nlm.nih.gov/entrez/query.fcgi?cmd=Retrieve&db=PubMed&dopt=Citation&list\\_uids=4390102](http://www.ncbi.nlm.nih.gov/entrez/query.fcgi?cmd=Retrieve&db=PubMed&dopt=Citation&list_uids=4390102).
- [19] D.J. Jollow, J.R. Mitchell, N. Zampaglione, J.R. Gillette, Bromobenzene-induced liver necrosis. Protective role of glutathione and evidence for 3,4-bromobenzene oxide as the hepatotoxic metabolite, *Pharmacology* 11 (1974) 151–169 (accessed October 25, 2017), <http://www.ncbi.nlm.nih.gov/pubmed/4831804>.
- [20] S. Marklund, G. Marklund, Involvement of the superoxide anion radical in the autoxidation of pyrogallol and a convenient assay for superoxide dismutase, *Eur. J. Biochem.* 47 (1974) 469–474 (accessed March 5, 2018), <http://www.ncbi.nlm.nih.gov/pubmed/4215654>.
- [21] O.H. Lowry, N.J. Rosebrough, A.L. Farr, R.J. Randall, PROTEIN MEASUREMENT WITH THE FOLIN PHENOL REAGENT\*, (n.d.). <http://devbio.wustl.edu/InfoSource/ISPDFs/Lowry1951.pdf> (accessed October 23, 2017).
- [22] H. Aebi, 13] Catalase in Vitro, (1984), pp. 121–126, [https://doi.org/10.1016/S0076-6879\(84\)05016-3](https://doi.org/10.1016/S0076-6879(84)05016-3).
- [23] I. Carlberg, B. Mannervik, Glutathione reductase, *Methods Enzymol.* 113 (1985) 484–490 (accessed May 1, 2018), <http://www.ncbi.nlm.nih.gov/pubmed/3003504>.
- [24] F. Natella, M. Nardini, I. Giannetti, C. Dattilo, C. Scaccini, Coffee drinking influences plasma antioxidant capacity in humans, *J. Agric. Food Chem.* 50 (2002) 6211–6216 (accessed May 1, 2018), <http://www.ncbi.nlm.nih.gov/pubmed/12358504>.
- [25] S.S. Palabiyik, P. Erkekoglu, N.D. Zeybek, M. Kizilgun, D.E. Baydar, G. Sahin, B.K. Giray, Protective effect of lycopene against ochratoxin A induced renal oxidative stress and apoptosis in rats, *Exp. Toxicol. Pathol.* 65 (2013) 853–861, <https://doi.org/10.1016/j.etp.2012.12.004>.
- [26] J.M. Gutteridge, Lipid peroxidation and antioxidants as biomarkers of tissue damage, *Clin. Chem.* 41 (1995) 1819–1828 (accessed May 6, 2018), <http://www.ncbi.nlm.nih.gov/pubmed/7497639>.
- [27] S.J.V. Vicente, E.Y. Ishimoto, E.A.F.S. Torres, Coffee modulates transcription factor Nrf2 and highly increases the activity of antioxidant enzymes in rats, *J. Agric. Food Chem.* 62 (2014) 116–122, <https://doi.org/10.1021/jf401777m>.
- [28] Maria Daglia, A.dele Papetti, Cesarina Gregotti, Francantonio Bertè, Gabriella Gazzani, In Vitro Antioxidant and Ex Vivo Protective Activities of Green and Roasted Coffee, (2000), <https://doi.org/10.1021/JF990510G>.
- [29] L. Goya, C. Delgado-Andrade, J.A. Rufián-Henares, L. Bravo, F.J. Morales, Effect of coffee Melanoidin on human hepatoma HepG2 cells. Protection against oxidative stress induced by tert-butylhydroperoxide, *Mol. Nutr. Food Res.* 51 (2007) 536–545, <https://doi.org/10.1002/mnfr.200600228>.
- [30] F. Bokhari, S.A.-A.B. Res, undefined, Effects of Ochratoxin A-contaminated Arabian Coffee Seeds on Liver and Kidney Functions and Structure in Mice: Protective Role of Roasting and Vitamin C, *Academia.Edu.*, 2008 (n.d.) (accessed May 1, 2018), [http://www.academia.edu/download/32594461/fardos\\_soad\\_pakistan.pdf\\_2.pdf](http://www.academia.edu/download/32594461/fardos_soad_pakistan.pdf_2.pdf).
- [31] S.B.A.-E.J. of N. Toxins, The Protective Role of Ajwa Date Against the Hepatotoxicity Induced by Ochratoxin A. undefined (n.d.). *Search.Ebscohost.Com*, 2011 <http://search.ebscohost.com/login.aspx?direct=true&profile=ehost&scope=site&authtype=crawler&jrnl=16872118&AN=96793723&h=%2Fi3qAqEVOscq2rGp6GPbqbEr9w2MChJvYfc2usvHOPU9fWUY8SAn85ITl6TbeH%2BINPBGXDr%2FvmtJiuRxr2gWZA%3D%3D&crl=c>; (accessed May 1, 2018).
- [32] F.A. Morsy, A.A.G. el Din, A.R.H. Farrag, M.A. Badawi, N.M. Shaffie, Ochratoxin a toxic effect on rat kidneys and the potential protective effect of ginseng: histopathologic, histochemical, and image analysis morphometric studies, *Maced. J. Med. Sci.* 5 (2012) 40–48, <https://doi.org/10.3889/MJMS.1857-5773.2012.0195>.
- [33] S. Abdu, A. Ali, S. Ansari, Cytotoxic effect of ochratoxin A on the renal corpuscles of rat kidney: could ochratoxin A cause kidney failure? *Histol. Histopathol.* 26 (2011) 543–549, <https://doi.org/10.14670/HH-26.543>.