

CASE REPORT

Open Access



# Massive obstetric hemorrhage during cesarean section in a patient after conception by frozen-thawed embryo transfer: a case report

Mai Ito, Kensuke Oshita, Kazuyuki Tanaka, Masato Hara and Teruyuki Hiraki\*

## Abstract

**Background:** Placenta accreta is a major cause of massive obstetric hemorrhage during cesarean section. In recent years, pregnancy by in vitro fertilization-embryo transfer has been reported as a risk factor for placenta accreta.

**Case presentation:** A 36-year-old G1P0 woman with systemic lupus erythematosus became pregnant by frozen-thawed embryo transfer. Emergency cesarean section was performed under general anesthesia due to the diagnosis of non-reassuring fetal status. The placenta invaded the myometrium and completely covered the entire anterior uterine wall. Following birth, 3000 mL of blood loss required rapid fluid infusion and blood transfusion. Total hysterectomy was performed because the placenta could not be separated from the uterine wall. Histological examination revealed placenta accreta/increta.

**Conclusions:** When performing cesarean section on patients who have undergone frozen-thawed embryo transfer, preoperative examinations to assess for placenta accreta should be performed, and the anesthetic management should include sufficient planning for massive obstetric hemorrhage.

**Keywords:** Cesarean section, Frozen-thawed embryo transfer, Placenta accreta, Systemic lupus erythematosus

## Background

Placenta accreta is a major obstetric complication in which the chorionic villi invade the myometrium, causing part of or the entire placenta to become strongly attached to the uterine wall. This makes placental detachment difficult, leading to massive hemorrhage following delivery or perinatal emergency hysterectomy. Risk factors include placenta previa, prior cesarean section, and prior uterine surgery. Assisted reproduction technology (ART) treatments, especially in vitro fertilization (IVF), have been recently reported as a new risk factor for placenta accreta [1, 2].

We report a primigravida with systemic lupus erythematosus (SLE) who became pregnant by frozen-thawed embryo transfer (FET) and underwent hysterectomy due to poor control of unexpected massive hemorrhage caused by placenta accreta during cesarean section. There have

only been a few reports describing the association between placenta accreta and SLE [3, 4].

## Case presentation

The patient was a 36-year-old woman (152 cm, 52 kg) who was G1P0 and had no history of gynecological surgery. She was diagnosed with SLE at the age of 19 and was maintained on prednisolone 15 mg daily. She also received subcutaneous injections of 2000 units of low-molecular-weight heparin for suspected antiphospholipid antibody syndrome. She had undergone infertility treatment for 8 years and had five ART treatments at another medical institution. The patient successfully became pregnant by FET at our institution. Although the pregnancy progressed smoothly, at 36 weeks and 3 days of gestation, emergency cesarean delivery was performed due to the diagnosis of non-reassuring fetal status. Preoperative ultrasound examination revealed a massive placenta covering the lower half of the uterine body; however, these findings were not considered placenta

\* Correspondence: [hiraki\\_teruyuki@kurume-u.ac.jp](mailto:hiraki_teruyuki@kurume-u.ac.jp)  
Department of Anesthesiology, Kurume University School of Medicine, 67  
Asahi-machi, Kurume, Fukuoka 830-0011, Japan

previa. Parts of the myometrium had become thin and placental lacunae were noted. Furthermore, the boundary between the myometrium and placenta was indistinct.

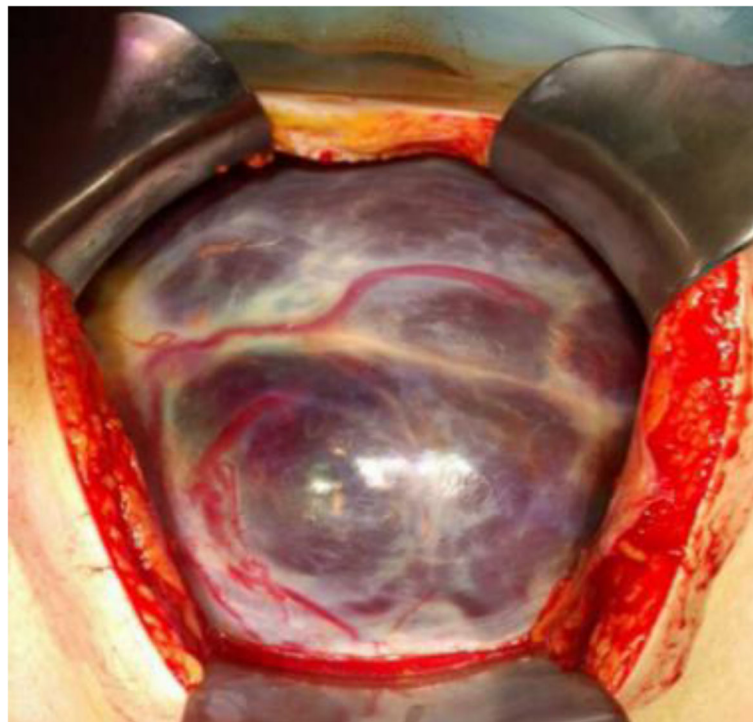
General anesthesia was employed because she had already received subcutaneous injection of low-molecular-weight heparin on the day of the operation. Anesthesia was induced by propofol 120 mg, remifentanyl 0.3 µg/kg/min, and rocuronium 50 mg and maintained with target controlled infusion of propofol at 2–3 µg/ml and remifentanyl 0.1–0.25 µg/kg/min with 60% oxygen after tracheal intubation. Intraoperatively, the myometrium of the anterior uterine wall was thin and the placenta, which extended over the entire anterior uterine wall, was observed through it (Fig. 1). Because massive hemorrhage was expected, additional intravenous access (18-gauge) was obtained, a radial arterial catheter was placed, and blood products were prepared. The fetus was delivered through the placenta. Following birth, systolic blood pressure rapidly dropped to approximately 60 mmHg, and 3000 mL of blood loss required rapid fluid infusion and blood transfusion. Emergency total hysterectomy was performed because the placenta was firmly attached to the uterine wall and was unable to separate, causing massive hemorrhage. Intraoperative blood loss was 5860 mL, including the amniotic fluid. She was transfused 10 units of packed red blood cells, 6 units of fresh frozen plasma, and 10 units of platelet concentrate. Apgar scores of the newborn were 6

and 8 at 1 and 5 min, respectively. The patient and the baby were both discharged without complications. Histological examination demonstrated multiple areas where the myometrium had become markedly thin and the placental villi had directly invaded the myometrium without the decidual layer, consistent with placenta increta.

## Discussion

Placenta accreta is defined as a placenta that in whole or in part invades the uterine wall and is inseparable from it [5]. Placenta accreta is one of the most serious obstetric complications and is associated with an increased risk of massive hemorrhage during cesarean section. Peripartum emergency hysterectomy is often required to control massive hemorrhage. Risk factors include a history of a cesarean section, placenta previa, maternal age, and a history of curettage [6].

In recent years, ART treatments, especially IVF, have been reported as a new risk factor for placenta accreta [1, 2]. Esh-Broder et al. reported that the rate of placenta accreta in the IVF group was 13.2-fold higher than that in the spontaneous pregnancy group [1]. FET in particular leads to a higher incidence of placenta accreta than fresh embryo transfer (0.27% and 0.09%, respectively) [7–9]. As our patient did not have conventional risk factors for placenta accreta, pregnancy achieved by FET may have been one of the risk factors for placenta



**Fig. 1** Uterus with placenta accreta visible at the time of laparotomy. The placenta was bulging through a thin myometrium on the anterior uterine wall. A massive placenta covers the anterior uterine wall with increased vascularity. The fetus was delivered through the placenta

accreta in this case. Anesthetic management for massive obstetric hemorrhage should be prepared for patients who underwent FET, even without a history of cesarean section or other uterine surgeries, because placenta accreta may only be diagnosed at the time of delivery. In our case, a preoperative definitive diagnosis of placenta accreta was unable to be made, although it was suggested by preoperative ultrasound imaging findings. Magnetic resonance imaging may have helped to confirm the diagnosis in this case. Also, measures to decrease intraoperative blood loss, e.g., intra-aortic balloon occlusion or iliac artery balloon catheter placement, should have been considered preoperatively.

This patient also had a background of SLE. In a study of 25 pregnant women with SLE complications, underdevelopment and dysfunction of the placental villi were observed and were likely caused by reduced blood flow in the intervillous space through the myometrium due to vascular abnormalities of the placenta [10]. Similar to the present study, hysterectomy was performed during cesarean section because of placenta accreta and myometrial thinning in a pregnancy with SLE complications [3, 4]. The relationships among SLE, myometrial thinning, and placenta accreta have not been elucidated. A larger number of cases and more data are necessary to determine such a relationship.

In conclusion, we report the case of a primigravida with a background of SLE who became pregnant by FET. Massive hemorrhage developed following delivery and emergency total hysterectomy was performed due to placenta accreta. When performing cesarean section on patients who have undergone FET, preoperative examinations to assess for placenta accreta should be performed, and the anesthetic management should include sufficient planning for massive hemorrhage. Further cases and data are necessary to clarify the association between placenta accreta and SLE.

#### Abbreviations

ART: Assisted reproductive technology; FET: Frozen-thawed embryo transfer; IVF: In vitro fertilization; SLE: Systemic lupus erythematosus

#### Acknowledgements

None

#### Authors' contributions

MI and KO were involved in patient care during the operation and prepared the manuscript. KT and MH carried out the anesthetic management and made substantial contributions to the drafting of the manuscript. TH helped to draft the manuscript. All authors have read and approved the final manuscript.

#### Funding

The authors declare that they have no funding.

#### Availability of data and materials

The data in this case report are available from the corresponding author upon reasonable request.

#### Ethics approval and consent to participate

Not applicable.

#### Consent for publication

Written informed consent was received from the patient for the publication of this case report.

#### Competing interests

The authors declare that they have no competing interests.

Received: 6 October 2019 Accepted: 30 December 2019

Published online: 06 January 2020

#### References

- Esh-Broder E, Ariel I, Abas-Bashir N, Bdolah Y, Celnikier DH. Placenta accreta is associated with IVF pregnancies: a retrospective chart review. *BJOG*. 2011; 118:1084–9.
- Fitzpatrick KE, Sellers S, Spark P, Kurinczuk JJ, Brocklehurst P, Knight M. Incidence and risk factors for placenta accreta/increta/percreta in the UK: a national case-control study. *PLoS One*. 2012;7(12):e52893.
- Mittal N, Pineda M, Lim B, Carey E. Placenta previa increta in an unscarred uterus with marked thinning of myometrium in the entire uterus in a patient with systemic lupus erythematosus. *Int J Gynecol Pathol*. 2018;37: 198–203.
- Wheeler TC, Anderson TL, Kelly J, Boehm FH. Placenta previa increta diagnosed at 18 weeks' gestation. Report of a case with sonographic and pathologic correlation. *J Reprod Med*. 1996;41:198–200.
- Banayan JM, Hofer JE, Scavone BM. Antepartum and postpartum hemorrhage. In: Chestnut D, Wong C, Tsen L, Ngan Kee WD, Beilin Y, Myhre J, Bateman BT, Nathan N, editors. *Chestnut's Obstetric Anesthesia: Principles and Practice*. 6th ed. Philadelphia: Elsevier; 2019. p. 913.
- Silver RM, Branch DW. Placenta accreta spectrum. *N Engl J Med*. 2018;378: 1529–36.
- Ishihara O, Araki R, Kuwahara A, Itakura A, Saito H, Adamson GD. Impact of frozen-thawed single-blastocyst transfer on maternal and neonatal outcome: an analysis of 277,042 single-embryo transfer cycles from 2008 to 2010 in Japan. *Fertil Steril*. 2014;101:128–33.
- Takeshima K, Jwa SC, Saito H, Nakaza A, Kuwahara A, Ishihara O, Irahara M, Hirahara F, Yoshimura Y, Sakumoto T. Impact of single embryo transfer policy on perinatal outcomes in fresh and frozen cycles-analysis of the Japanese Assisted Reproduction Technology registry between 2007 and 2012. *Fertil Steril*. 2016;105:337–46.e3.
- Kaser DJ, Melamed A, Bormann CL, Myers DE, Missmer SA, Walsh BW, Racowsky C, Carusi DA. Cryopreserved embryo transfer is an independent risk factor for placenta accreta. *Fertil Steril*. 2015;103:1176–84.e2.
- Nakamura Y, Yoshida K, Takada M. Morphological and immunohistochemical study of the placental villi in pregnancy complicated by systemic lupus erythematosus (in Japanese with English abstract). *Nihon Sanka Fujinka Gakkai Zasshi (Acta obstetrica et gynaecologica Japonica)*. 1992;44:469–76.

#### Publisher's Note

Springer Nature remains neutral with regard to jurisdictional claims in published maps and institutional affiliations.

Submit your manuscript to a SpringerOpen<sup>®</sup> journal and benefit from:

- Convenient online submission
- Rigorous peer review
- Open access: articles freely available online
- High visibility within the field
- Retaining the copyright to your article

Submit your next manuscript at ► [springeropen.com](https://www.springeropen.com)