

- 2 Teng JM, Cowen EW, Wataya-Kaneda M et al. Dermatologic and dental aspects of the 2012 International Tuberous Sclerosis Complex Consensus Statements. *JAMA Dermatol* 2014; **150**:1095–101.
- 3 Seibert D, Hong CH, Takeuchi F et al. Recognition of tuberous sclerosis in adult women: delayed presentation with life-threatening consequences. *Ann Intern Med* 2011; **154**:806–13, W-294.
- 4 Nathan N, Burke K, Moss J, Darling TN. A diagnostic and management algorithm for individuals with an isolated skin finding suggestive of tuberous sclerosis complex. *Br J Dermatol* 2017; **176**:220–3.
- 5 Tyburczy ME, Dies KA, Glass J et al. Mosaic and intronic mutations in TSC1/TSC2 explain the majority of TSC patients with no mutation identified by conventional testing. *PLOS Genet* 2015; **11**:e1005637.
- 6 Treichel AM, Hamieh L, Nathan NR et al. Phenotypic distinctions between mosaic forms of tuberous sclerosis complex. *Genet Med* 2019; <https://doi.org/10.1038/s41436-019-0520-3>.
- 7 Boronat S, Shaaya EA, Doherty CM, Caruso P, Thiele EA. Tuberous sclerosis complex without tubers and subependymal nodules: a phenotype-genotype study. *Clin Genet* 2014; **86**:149–54.
- 8 Tyburczy ME, Wang JA, Li S et al. Sun exposure causes somatic second-hit mutations and angiofibroma development in tuberous sclerosis complex. *Hum Mol Genet* 2014; **23**:2023–9.

This work was presented at the 2019 International Tuberous Sclerosis Complex Research Conference on June 20–22, 2019 in Toronto, Ontario, Canada.

Disclaimer: the opinions and assertions expressed herein are those of the author(s) and do not necessarily reflect the official policy or position of the Uniformed Services University, the Department of Defense or the National Institutes of Health.

Funding sources: research reported in this publication was supported in part by the Intramural Research Program, National Institutes of Health (NIH), National Heart, Lung, and Blood Institute (NHLBI); the NIH, National Institute of Arthritis and Musculoskeletal and Skin Diseases (award no. R01AR062080); NIH, NHLBI (award no. 1U01HL131022); the Doris Duke Charitable Foundation Clinical Research Mentorship (grant no. 2018042); and the Tuberous Sclerosis Alliance, Engles Fund for Research in TSC and LAM. Additionally, this work was made possible through the NIH Medical Research Scholars Program, a public-private partnership supported jointly by the NIH and generous contributions to the Foundation for the NIH from the Doris Duke Charitable Foundation, the American Association for Dental Research, the Colgate-Palmolive Company, Genentech, and other private donors. For a complete list, visit the foundation website at <http://www.fnih.org>.

Conflicts of interest: none to declare.

Leprosy in French Guiana 2007–2014: a re-emerging public health problem

DOI: 10.1111/bjd.18334

DEAR EDITOR, In 1991, the World Health Organization (WHO) set the aim of eliminating leprosy as a public health problem by decreasing world prevalence to < 1 case per 10 000

inhabitants.¹ This objective had been reached in French Guiana by the time an epidemiological study was performed in 2006.² French Guiana is a French overseas department in South America, and it enjoys a universal healthcare system and greater development than neighbouring countries (Brazil and Suriname). It has a population of 296 000, of mixed ancestries, including African American, Europeans and Amerindians. Many immigrants from Brazil have recently settled in French Guiana. They often work as illegal gold miners and experience very harsh working conditions in the isolated forest areas of the hinterland. The main objective of this study was to estimate the incidence and prevalence of leprosy in French Guiana.

Between 1 January 2007 and 31 December 2014, in all health centres of French Guiana, all new cases of histologically confirmed active leprosy and all patients on leprosy treatment were enrolled in the study. We defined autochthonous cases as adults born or living in French Guiana for more than 10 years, or children born and living in French Guiana. Incidence and prevalence rates were calculated on the basis of the 2012 census data.

During the study period, 125 new cases were recorded. The average annual incidence rate was 0.67 per 10 000 inhabitants (Fig. 1a). Children aged below 16 years represented 8.8% of cases. Most patients (88%) were from other countries (56% from Brazil). Of the 125 cases, 27 (21.6%) were autochthonous. Leprosy was multibacillary for 55% of patients. Clinical symptoms were present for more than 1 year for 34% of patients. Disability level (DL)1 and DL2 were present, respectively, in 37 (29.6%) and 18 (14.4%) patients. Of the patients with DL2, 60% were Brazilians, and these were mostly gold miners. Incomplete treatment was recorded for 47% of patients, while 6% received no treatment and 32% were lost to follow-up.

During the study period, 190 prevalent cases were followed in French Guiana. The average annual prevalence was 1.01/10 000 inhabitants. The annual prevalence ranged from 0.51 to 1.23/10 000 inhabitants in 2007–2014 (Fig. 1b). Between 2009 and 2014, this rate was always 1 or higher. Comparing the data from this study with the data of the previous period 1997–2006,² we observed a significant increase in the annual number of new cases ($P = 0.025$). There was also a significant increase in the proportion among Brazilian patients (30% vs. 56%; $P = 0.001$). A box and whisker plot comparing the incidence of leprosy during the two periods 1997–2006 and 2007–2014 can be obtained by direct application to the corresponding author.

In French Guiana, the annual incidence rate of leprosy has considerably decreased since the early 1980s, with < 1 case per 10 000 inhabitants between 1996 and 2005.² However, since 2006, there has been a significant increase of incidence, with two peaks of > 1 case per 10 000 inhabitants. Since 2009, the incidence of leprosy in French Guiana has exceeded the WHO threshold, and becoming a public health problem. In 2006, Domergue et al., using similar methodology, concluded that leprosy was no longer a public health problem in

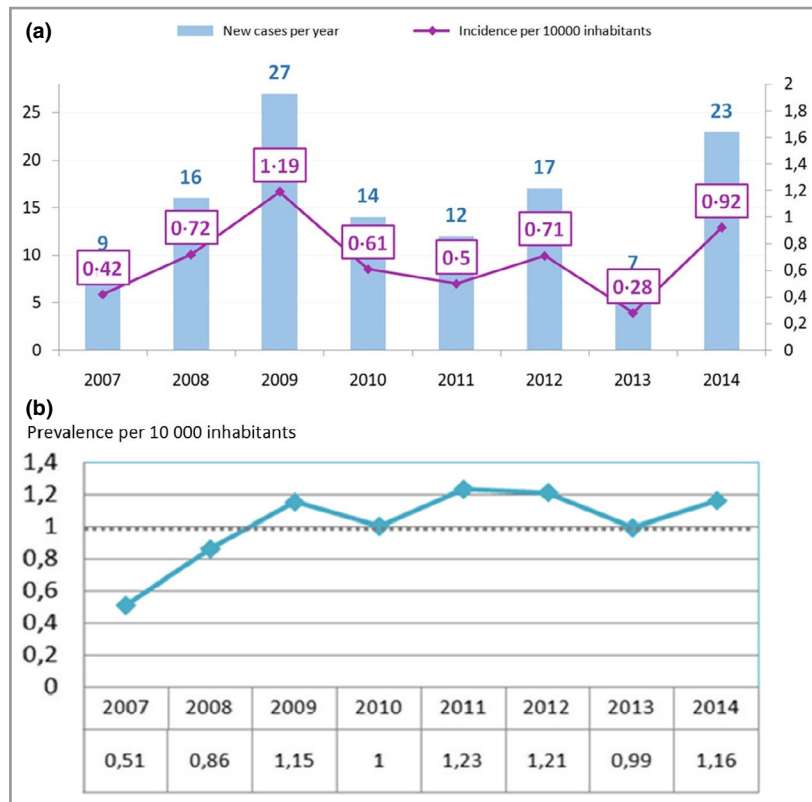


Fig 1. (a) Annual incidence and (b) annual prevalence of leprosy in French Guiana, 2007–2014.


French Guiana,² but our results suggest a re-emergence. The presence of locally acquired cases in our study suggests an autochthonous transmission. This finding is also supported by the proportion of children with leprosy, which is higher than in Brazilian³ or previous Guianan² studies.

During the second half of the 20th century, leprosy in French Guiana used to affect mostly Bushinengue (Maroon) people living on the Maroni river.² Our study shows a shift in epidemiological profile towards Brazilians (56% of new cases), probably reflecting the gradual increase in illegal gold mining in French Guiana.^{4,5} The proportion of patients with DL2 at the time of diagnosis was double that of the global or Brazilian reported rates (6.5%).^{1,3} The advanced presentations in this neglected population are probably linked to a lack of healthcare access.⁵ High proportions of multibacillary leprosy in our study suggest bacilli circulation and a greater risk of evolution towards DL2.⁶

A little more than half of all patients had received complete treatment according to WHO criteria. Untreated patients were generally patients lost to follow-up. This can be explained by the great mobility of isolated communities in French Guiana.

In conclusion, our study shows that over the past 8 years leprosy has re-emerged as a significant public health problem in French Guiana. Continuous epidemiological monitoring is necessary to update the situation of leprosy control in French Guiana and to help improving public health strategies. Special efforts should be dedicated to delivering appropriate care to

Brazilian gold miners. These results should make the international community aware of specific needs in these parts of the world.

J. Graille,¹ R. Blaizot ,^{1,2} A.S. Darrigade,¹ D. Sainte-Marie,¹ M. Nacher,³ R. Schaub³ and P. Couppié^{1,2}

¹Dermatology Department, Centre Hospitalier Andrée Rosemon, Cayenne, French Guiana; ²EA 3593, Ecosystèmes Amazoniens et Pathologies Tropicales, Université de Guyane, Cayenne, French Guiana; and ³Centre d'Investigation Clinique, CIC INSERM 1424, Centre Hospitalier Andrée Rosemon, Cayenne, French Guiana.
Correspondence: Romain Blaizot.

E-mail: blaizot.romain@gmail.com

References

- World Health Organization. Weekly epidemiological record. 2017; **92**:501–20. Available at: <https://www.who.int/wer/2017/wer9235/en/> (last accessed 31 August 2019).
- Domergue V, Clyti E, Sainte-Marie D et al. [Leprosy in French Guiana: a retrospective study from 1997 to 2006]. *Méd Trop* 2008; **1**:33–7 (in French).
- World Health Organization. Weekly epidemiological record. 2015; **90**:461–76. Available at: <http://www.who.int/wer/2015/wer9036/en/> (last accessed 31 August 2019).
- Taubira C. Rapport sur la lutte contre l'exploitation aurifère illégale dans les zones protégées ou d'intérêt patrimonial (n°2845) Available at: <http://www2.assemblee-nationale.fr/documents/notice/13/>

rappports/r3314/(index)/rappports/(archives)/index-rapports (last accessed 31 August 2019).

- 5 Douine M, Mosnier E, Le Hingrat Q et al. Illegal gold miners in French Guiana: a neglected population with poor health. *BMC Public Health* 2017; **18**:23.
- 6 Moschioni C, Antunes CM de F, Grossi MAF et al. Risk factors for physical disability at diagnosis of 19,283 new cases of leprosy. *Rev Soc Bras Med Trop* 2010; **1**:19–22.

J.G. and R.B. contributed equally to this work and are joint first authors.

Funding sources: none.

Conflicts of interest: none to declare.

Generalized skin hyperpigmentation as the only manifestation of X-linked adrenoleucodystrophy

DOI: 10.1111/bjd.18310

DEAR EDITOR, X-linked adrenoleucodystrophy (X-ALD) is a progressive genetic disorder caused by mutations in the *ABCD1* gene that result in the accumulation of very long-chain fatty

acids (VLCFAs) in all tissues throughout the body.¹ These VLCFAs are harmful to organs and primarily affect the brain, spinal cord and adrenal glands.² The spectrum and severity of the disease varies, ranging from isolated adrenal insufficiency and myelopathy to cerebral demyelination.² The possibility of cerebral X-ALD, which can be rapidly progressive and lethal, makes early diagnosis of the disease crucial. Herein, we describe a patient who presented with generalized skin hyperpigmentation as the first and only symptom of X-ALD.

A 19-year-old male patient presented with generalized skin hyperpigmentation that began in his early teens (Fig. 1a, b). The pigmentation was especially prominent on the gums, elbows and knees (Fig. 1c–e). Mild pigmentation of the palmar creases was also observed. The patient was otherwise healthy. He did not have hypotension and did not report any other symptoms such as fatigue, dizziness, vomiting or headaches. However, initial laboratory findings suggested adrenal insufficiency with an elevated level of adrenocorticotropic hormone (6315 pg mL⁻¹, normal range 0–60 pg mL⁻¹) and a subclinically low level of cortisol (4.5 µg dL⁻¹, normal range 2–12 µg dL⁻¹). Thyroid function and 17-hydroxyprogesterone tests were also performed, which all fell within normal range, thereby excluding congenital adrenal hyperplasia and hyperthyroidism from the differential diagnosis. At this point, adrenoleucodystrophy was suspected for the first time, rather than autoimmune adrenalitis or infectious adrenalitis, as

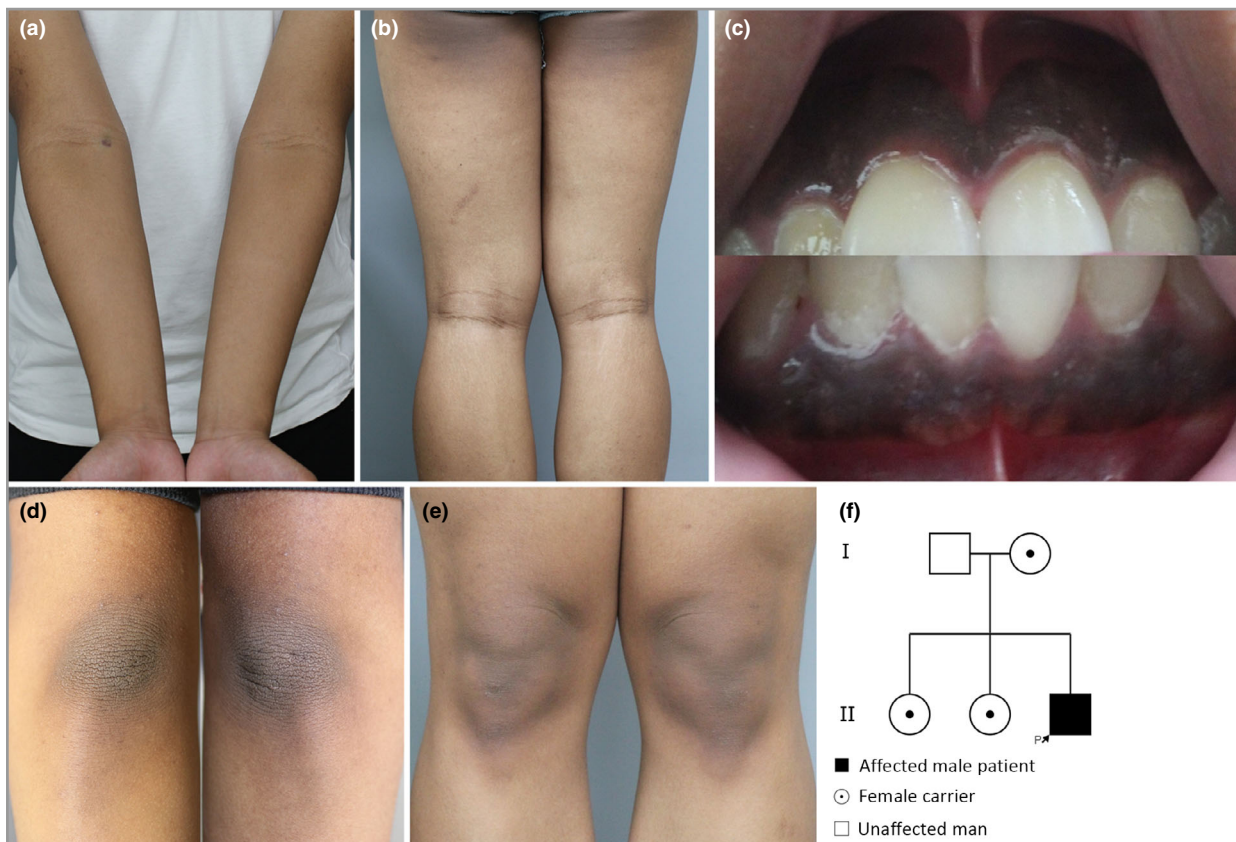


Fig 1. Clinical images of skin hyperpigmentation in the patient on (a) the arms, (b) legs, (c) gums, (d) elbows and (e) knees. (f) Pedigree showing X-linked inheritance pattern. The patient (P) is indicated with an arrow.