




CASE REPORT

**REVISED** Case Report: Cetuximab and nivolumab use in advanced cutaneous squamous cell carcinoma resistant to chemotherapy [version 2; peer review: 2 approved]

Alvise Sernicola , Salvatore Lampitelli, Federica Marraffa, Patrizia Maddalena, Sara Grassi, Antonio Giovanni Richetta, Stefano Calvieri

Unit of Dermatology, Sapienza University of Rome, Piazzale Aldo Moro 5, Rome, 00185, Italy

**v2** First published: 21 Jun 2019, 8:933 (<https://doi.org/10.12688/f1000research.19149.1>)  
 Latest published: 31 Dec 2019, 8:933 (<https://doi.org/10.12688/f1000research.19149.2>)

**Abstract**



We present the case of a 60-year-old man with unresectable cutaneous squamous cell carcinoma (cSCC) of the sternal area, which was not amenable to radiation therapy (stage III, T3N0M0). The treatment history of this patient is remarkable as the disease had progressed through all lines of conventional therapy established in the literature. The patient was treated with epidermal growth factor receptor (EGFR) inhibitor cetuximab for 35 cycles and restaged after 12 months of therapy with a whole body CT scan, documenting stage IV disease (T3N2bM1). The use of cetuximab as a single agent was effective for a limited time and we decided to initiate combination therapy with cetuximab and nivolumab. Restaging after six months of this combination regimen documented stable disease.



**Keywords**

cutaneous squamous cell carcinoma, cetuximab, EGFR, non-melanoma skin cancer

**Open Peer Review**

Reviewer Status  

	Invited Reviewers	
	1	2
<b>version 2</b> (revision) 31 Dec 2019	 report	 report
	↑	
<b>version 1</b> 21 Jun 2019	 report	

- 1 **Gregory A Daniels** , University of California San Diego, La Jolla, USA
- 2 **Gloria Orlando** , University of Padova, Padua, Italy

Any reports and responses or comments on the article can be found at the end of the article.

**Corresponding author:** Antonio Giovanni Richetta ([antoniorichetta@hotmail.com](mailto:antoniorichetta@hotmail.com))

**Author roles:** **Sernicola A:** Data Curation, Investigation, Writing – Original Draft Preparation; **Lampitelli S:** Investigation, Visualization; **Marraffa F:** Data Curation, Investigation, Writing – Review & Editing; **Maddalena P:** Data Curation, Investigation, Writing – Review & Editing; **Grassi S:** Supervision, Writing – Review & Editing; **Richetta AG:** Conceptualization, Supervision; **Calvieri S:** Conceptualization, Project Administration, Supervision

**Competing interests:** No competing interests were disclosed.

**Grant information:** Associazione Romana Ricerca Dermatologica covered the publication fees of this article as support to the authors. *The funders had no role in study design, data collection and analysis, decision to publish, or preparation of the manuscript.*

**Copyright:** © 2019 Sernicola A *et al.* This is an open access article distributed under the terms of the [Creative Commons Attribution License](#), which permits unrestricted use, distribution, and reproduction in any medium, provided the original work is properly cited.

**How to cite this article:** Sernicola A, Lampitelli S, Marraffa F *et al.* **Case Report: Cetuximab and nivolumab use in advanced cutaneous squamous cell carcinoma resistant to chemotherapy [version 2; peer review: 2 approved]** F1000Research 2019, 8:933 (<https://doi.org/10.12688/f1000research.19149.2>)

**First published:** 21 Jun 2019, 8:933 (<https://doi.org/10.12688/f1000research.19149.1>)

**REVISED Amendments from Version 1**

The article has been updated to include follow up of 80 weeks. Following progression to stage IV disease after one year of cetuximab, combination therapy with the addition of PD-1 blocker nivolumab was administered for another six months, achieving disease stability. This choice reflects recent advancements in the treatment scenario of advanced cSCC, with anti-PD-1 monoclonal antibody cemiplimab now established as the standard of care in immune-competent patients.

**Any further responses from the reviewers can be found at the end of the article**

**Introduction**

This case describes the effective use of cetuximab and nivolumab in an extensive thoracic cutaneous squamous cell carcinoma resistant to all previous lines of chemotherapy.

Non-melanoma skin cancer (NMSC) is the most common malignant neoplasm affecting Caucasian individuals, the main types of which are basal cell carcinoma (BCC) and squamous cell carcinoma (SCC). SCC has a lower incidence than BCC and the gold standard of treatment is surgical excision. Between 1–5% of SCCs exhibit biologically aggressive behavior and are resistant to surgery<sup>1</sup>.

The management of metastatic or locally advanced cutaneous SCC (cSCC), traditionally relying on conventional radiotherapy (alone or in combination with surgery) and systemic chemotherapy, benefited from the promising addition of targeted inhibitors of the epidermal growth factor receptor (EGFR) pathway and dramatically changed following the introduction of immunotherapy with checkpoint inhibitors<sup>2</sup>. Anti-EGFR monoclonal antibody cetuximab, at the standard weekly dosage of 250mg/m<sup>2</sup>, provides an off-label treatment option with potential clinical value in advanced cSCC<sup>3</sup>.

In 2018, a study by Migden *et al.* dramatically changed the previous scenario establishing the new standard of care with PD-1 blockade in immunocompetent patients, in the absence of

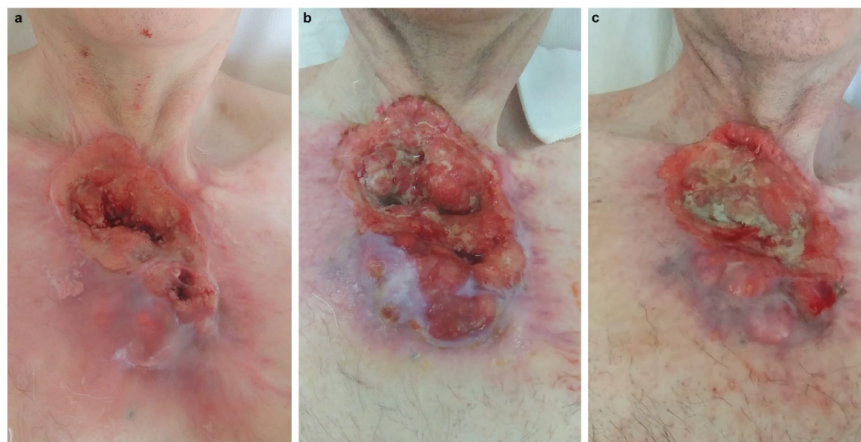
contraindications to immunotherapy<sup>4</sup>. Anti-PD1 monoclonal antibody cemiplimab was consequently approved for use in Europe in July 2019.

**Case presentation**

A 60-year-old Caucasian man, currently unemployed, presented to our dermatology department complaining of the recurrence of a thoracic cSCC. Physical examination revealed an extensive ulcerative skin lesion of the sternal area covered by necrotic and fibrinous tissue. The patient reported intermittent pain and bleeding (Figure 1).

The onset of a nodular skin lesion in the same site dated back to 2000, but an initial diagnosis of BCC was made only in 2013, when a single biopsy was performed (see Table 1 for timeline). A computerized tomography (CT) scan followed, demonstrating a high local burden of disease, with destructive osteo-muscular infiltration, preventing a surgical or radiation approach, and the patient was treated with vismodegib (150 mg daily). After 12 months of apparent clinical remission, a local relapse was observed, and the histologic examination of an excisional biopsy diagnosed SCC. Surgical removal of the tumor was not radical, and the patient was referred for adjuvant chemotherapy, failing four consecutive cytotoxic regimens, until the personal decision of the patient to withdraw from treatment.

A stage III-disease (T3N0M0, Figure 2a)<sup>5</sup> advised the use of anti-PD-1 therapy. Even if PDL-1 testing is not required, immunohistochemistry was performed on the previous biopsy sample documenting no/low expression of PDL-1. Being cemiplimab not yet available, we resorted to cetuximab, the use of which is off-label for cSCC. We administered cetuximab at an initial single dose of 400mg/m<sup>2</sup>, followed by 250mg/m<sup>2</sup> every week, for seven cycles, and every two weeks, for 35 total cycles. Follow-up assessment with periodic CT at three (Figure 2b and 2c) and six months documented stable locally advanced disease. Therapy was well tolerated, with the only complaint of an acneiform eruption, which began after one week of treatment and was managed with clindamycin 1% gel twice a day and oral minocycline 100mg twice a day for four weeks.

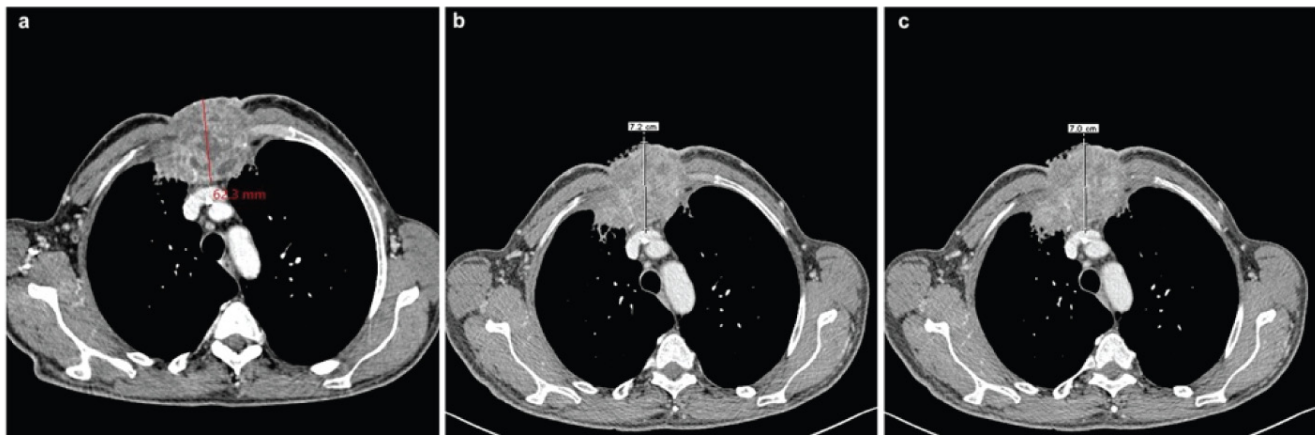


**Figure 1.** Clinical presentation before cetuximab (a) and after six (b) and 12 weeks of therapy (c).

**Table 1. Timeline of interventions and outcomes.**

Timeline	Medical history and past interventions	
	No family history of skin cancer 1999: total gastrectomy for gastric adenocarcinoma	
	<b>Diagnostic testing and interventions</b>	
Past Interventions 2013 – 2017	2000: Patient reports onset of nodular skin lesion 2013: Incisional biopsy: BCC CT scan (23-Jan-2013): high local burden of disease (50mm AP diameter), with destructive osteo-muscular infiltration - <i>vismodegib</i> 150mg daily from Feb to Nov-2013 2014: relapse of nodular skin lesion Excision biopsy (Feb-2014): SCC Wide surgical excision (22-May-2014): not radical Adjuvant chemotherapy: - <i>cisplatin</i> 100mg/m <sup>2</sup> day 1 with <i>fluorouracil</i> 1000mg/m <sup>2</sup> for four days of 21-day-cycles, Aug – Sep-2014 - <i>radio-chemotherapy with gemcitabine</i> Dec-2014 – Jan-2015 - <i>cisplatin</i> 100mg/m <sup>2</sup> day 1 with <i>docetaxel</i> 75mg/m <sup>2</sup> day 1 of 21-day-cycles Aug-2016 – Nov-2016 - <i>gemcitabine monotherapy</i> 3000mg/m <sup>2</sup> on day 1 and 15 of 28-day-cycles Dec-2016 – Jul-2017	
31-Jan-2018	Baseline assessment stage III T3N0M0, ECOG 0	Immunohistochemistry: low/no PD-L1 expression CT scan (31-Jan-2018): DT×DAP×DL 120×62×110mm
19-Apr-2018	Cetuximab monotherapy 35 cycles	- <i>cetuximab</i> initial single dose of 400mg/m <sup>2</sup> followed by - <i>cetuximab</i> 250mg/m <sup>2</sup> weekly for seven cycles followed by - <i>cetuximab</i> 250mg/m <sup>2</sup> every two weeks CT scan (28-May-2018): DAP 72mm CT scan (10-Sep-2018): DT×DAP×DL 135×70×110mm CT scan (12-Dec-2018): DT×DAP×DL 153×70×120mm
20-Feb-2019	Restaging stage IV T3N2bM1 ECOG 1	CT scan (20-Feb-2019) unchanged dimension, development of lymphadenopathies, the greater of which in the right paratracheal region DT 16mm and in the right supra- and sub-clavicular region DT 15mm, right axillary lymph node 6×6mm, development of secondary osteolytic lesions of D8 and D9 vertebral bodies
22-May-2019	Cetuximab/nivolumab combination therapy 13 cycles of each agent	- <i>cetuximab</i> single dose of 250mg/m <sup>2</sup> Q2W and <i>nivolumab</i> single fixed dose of 240mg Q2W administered at alternating weeks CT scan (13-May-2019) unchanged dimensions (DAP 60mm), slight reduction of previous lymphadenopathies DM 13mm and DM 10mm respectively, increased right axillary lymph node 10×8mm, stable secondary lesions of D8 and D9 vertebral bodies with marked reduction of pre- and paravertebral tissue involvement compared to previous exam CT scan (06-Aug-2019) slight dimensional increase with DL×DT×DAP 59×43×67mm
18-Nov-2019	Restaging stage IV T3N2bM1 ECOG 1	CT scan (18-Nov-2019) DL×DT×DAP 78×60×85mm, unchanged lymphadenopathies DM 13mm and DM 10mm respectively, stable secondary lesions of D8 and D9 vertebral bodies

BCC, basal cell carcinoma; CT, computerized tomography; DAP, anterior-posterior diameter; DL, longitudinal diameter; DM, maximum diameter; DT, transverse diameter; PDL-1, programmed cell death ligand-1; SCC, squamous cell carcinoma.



**Figure 2.** CT scan performed at baseline (a), after six (b) and 12 weeks of therapy (c), highlighting the anterior-posterior diameter of the tumor.

The patient was restaged after 44 weeks with a whole-body CT scan that demonstrated progression to stage IV disease (T3N2bM1) with metastatic involvement. Combination therapy with the addition of PD-1 blocker was planned and we employed locally available anti-PD1 monoclonal antibody nivolumab according to the following scheme: cetuximab single dose of 250mg/m<sup>2</sup> Q2W and nivolumab single fixed dose of 240mg Q2W administered at alternating weeks. Sequential CT assessments after 12 and 26 weeks showed stable disease at best, with slight increase of the primitive lesion and unchanged nodal and metastatic localizations.

## Discussion

In our report, response to cetuximab as a single agent and in combination with nivolumab was assessed for as long as 80 weeks.

We were challenged to select an effective treatment in this advanced case and resorted to EGFR inhibitor therapy. Cetuximab is approved for the treatment of locally or regional advanced SCC of the head and neck region (in combination with radiation) or for recurrent or metastatic disease (alone or in association with platinum). Its use in cSCC of other regions is currently off-label but our choice of drug was extensively supported by evidence in published literature<sup>3</sup>. A phase II study of unresectable cSCC treated with cetuximab for at least six weeks registered 25% objective response and 42% disease stabilization<sup>6</sup>. A diffuse papulopustular acneiform eruption is the most common cutaneous reaction pattern to EGFR inhibitors, reported in over two-thirds of treated subjects but severe in only 5–10% of cases. Cutaneous toxicity is suggested to be a proxy for response to cetuximab<sup>7</sup>.

Immune checkpoint inhibition revolutionized the management of advanced cSCC and anti-PD-1 monoclonal antibody cemiplimab is currently the preferred first line therapy, following registration for this specific indication in the US in July 2018 and in Europe in July 2019. Response to cemiplimab was reported in 50% of patients in the expansion cohorts of the phase 1 study and in 47% of patients in the metastatic-disease cohort of the phase 2 study, with response exceeding 6 months in 57% of cases<sup>4,8</sup>.

Nivolumab monotherapy is indicated for the treatment of recurrent or metastatic SCC of the head and neck in adults progressing on or after platinum-based therapy. In a patient without access to cemiplimab clinical trials, nivolumab was our agent of choice due to the biological similarity to SCC of the head-neck district<sup>9</sup>.

Recent experience from the literature attributes long-term remission and good tolerability to PD-1 checkpoint inhibition with nivolumab in cSCC. A series of three patients with advanced cSCC treated with nivolumab reported partial response in two subjects and stable disease in the third<sup>10</sup>.

Chen *et al.* recently reported a case of clinical regression of invasive cSCC after six months of dual treatment with cetuximab weekly and nivolumab biweekly and hypothesized the mechanisms underlying a synergistic action of these two agents<sup>11</sup>.

## Conclusions

- Serial biopsies are mandatory for advanced BCC candidates prior to vismodegib treatment to exclude foci of multiple differentiation<sup>12</sup>.
- Prior to the introduction of cemiplimab, no drugs were approved specifically for cSCC.
- The efficacy of cetuximab is limited as a single agent, with modest durations for stable disease.
- Low PDL-1 expression does not preclude the efficacy of checkpoint inhibitors; in fact, cemiplimab is approved without requirement for testing.
- PD-1 blockade is the new standard of care in advanced cSCC in immunocompetent patients.

## Data availability

All data underlying the results are available as part of the article and no additional source data are required.

## Consent

Written informed consent for publication of their clinical details and clinical images was obtained from the patient.

## References

1. Que SKT, Zwald FO, Schmults CD: **Cutaneous squamous cell carcinoma: Management of advanced and high-stage tumors.** *J Am Acad Dermatol.* United States; 2018; **78**(2): 249–61. [PubMed Abstract](#) | [Publisher Full Text](#)
2. Stratigos A, Garbe C, Lebbe C, *et al.*: **Diagnosis and treatment of invasive squamous cell carcinoma of the skin: European consensus-based interdisciplinary guideline.** *Eur J Cancer.* England; 2015; **51**(14): 1989–2007. [PubMed Abstract](#) | [Publisher Full Text](#)
3. Jalili A, Pinc A, Pieczkowski F, *et al.*: **Combination of an EGFR blocker and a COX-2 inhibitor for the treatment of advanced cutaneous squamous cell carcinoma.** *J Dtsch Dermatol Ges.* Wiley/Blackwell (10.1111); 2008; **6**(12): 1066–9. [PubMed Abstract](#) | [Publisher Full Text](#)
4. Migden MR, Rischin D, Schmults CD, *et al.*: **PD-1 Blockade with Cemiplimab in Advanced Cutaneous Squamous-Cell Carcinoma.** *N Engl J Med.* 2018; **379**(4): 341–51. [PubMed Abstract](#) | [Publisher Full Text](#)
5. Arid M, editor: **Part II Head and Neck.** In: *AJCC Cancer Staging Manual.* 8th ed. New York, NY, USA: Springer; 2018; 53.
6. Maubec E, Petrow P, Scheer-Senyarich I, *et al.*: **Phase II study of cetuximab as first-line single-drug therapy in patients with unresectable squamous cell carcinoma of the skin.** *J Clin Oncol.* United States; 2011; **29**(25): 3419–26. [PubMed Abstract](#) | [Publisher Full Text](#)
7. Jatoi A, Green EM, Rowland KM Jr, *et al.*: **Clinical predictors of severe cetuximab-induced rash: observations from 933 patients enrolled in north central cancer treatment group study N0147.** *Oncology.* 2009; **77**(2): 120–3. [PubMed Abstract](#) | [Publisher Full Text](#) | [Free Full Text](#)

8. Papadopoulos KP, Owonikoko TK, Johnson ML, *et al.*: **REGN2810: A fully human anti-PD-1 monoclonal antibody, for patients with unresectable locally advanced or metastatic cutaneous squamous cell carcinoma (CSCC)—Initial safety and efficacy from expansion cohorts (ECs) of phase I study.** *J Clin Oncol. American Society of Clinical Oncology.* 2017; **35**(15\_suppl): 9503.  
[PubMed Abstract](#) | [Publisher Full Text](#)
9. Malm IJ, Bruno TC, Fu J, *et al.*: **Expression profile and *in vitro* blockade of programmed death-1 in human papillomavirus-negative head and neck squamous cell carcinoma.** *Head Neck.* United States; 2015; **37**(8): 1088–95.  
[PubMed Abstract](#) | [Publisher Full Text](#) | [Free Full Text](#)
10. Blum V, Müller B, Hofer S, *et al.*: **Nivolumab for recurrent cutaneous squamous cell carcinoma: three cases.** *Eur J Dermatol.* 2018; **28**(1): 78–81.  
[PubMed Abstract](#)
11. Chen A, Ali N, Boasberg P, *et al.*: **Clinical Remission of Cutaneous Squamous Cell Carcinoma of the Auricle with Cetuximab and Nivolumab.** *J Clin Med.* 2018; **7**(1): pii: E10.  
[PubMed Abstract](#) | [Publisher Full Text](#) | [Free Full Text](#)
12. Zhu GA, Sundram U, Chang AL: **Two different scenarios of squamous cell carcinoma within advanced Basal cell carcinomas: cases illustrating the importance of serial biopsy during vismodegib usage.** *JAMA Dermatol.* United States; 2014; **150**(9): 970–3.  
[PubMed Abstract](#) | [Publisher Full Text](#)

# Open Peer Review

Current Peer Review Status:  

---

## Version 2

Reviewer Report 27 January 2020

<https://doi.org/10.5256/f1000research.23781.r58223>

© 2020 Orlando G. This is an open access peer review report distributed under the terms of the [Creative Commons Attribution License](#), which permits unrestricted use, distribution, and reproduction in any medium, provided the original work is properly cited.



**Gloria Orlando** 

Department of Medicine, Unit of Dermatology, University of Padova, Padua, Italy

This is a well written and interesting paper describing the effective use of cetuximab and nivolumab in an extensive thoracic cutaneous squamous cell carcinoma resistant to all previous lines of chemotherapy.

The authors provide a detailed description of the case with its findings comprehensively summarized in the Table.

I think it is a useful publication describing current therapeutic strategies for NMSC and encouraging readership to perform serial biopsies in skin cancers where collision tumours may be present.

**Is the background of the case's history and progression described in sufficient detail?**

Yes

**Are enough details provided of any physical examination and diagnostic tests, treatment given and outcomes?**

Yes

**Is sufficient discussion included of the importance of the findings and their relevance to future understanding of disease processes, diagnosis or treatment?**

Yes

**Is the case presented with sufficient detail to be useful for other practitioners?**

Yes

**Competing Interests:** No competing interests were disclosed.

**Reviewer Expertise:** Dermatology



**I confirm that I have read this submission and believe that I have an appropriate level of expertise to confirm that it is of an acceptable scientific standard.**

Reviewer Report 07 January 2020

<https://doi.org/10.5256/f1000research.23781.r58066>

© 2020 Daniels G. This is an open access peer review report distributed under the terms of the [Creative Commons Attribution License](#), which permits unrestricted use, distribution, and reproduction in any medium, provided the original work is properly cited.



**Gregory A Daniels** 

Department of Medicine, Division of Hematology/Oncology, University of California San Diego, La Jolla, CA, USA

No further comments.

**Is the background of the case's history and progression described in sufficient detail?**

Yes

**Are enough details provided of any physical examination and diagnostic tests, treatment given and outcomes?**

Yes

**Is sufficient discussion included of the importance of the findings and their relevance to future understanding of disease processes, diagnosis or treatment?**

Yes

**Is the case presented with sufficient detail to be useful for other practitioners?**

Yes

**Competing Interests:** No competing interests were disclosed.

**Reviewer Expertise:** Medical oncology.

**I confirm that I have read this submission and believe that I have an appropriate level of expertise to confirm that it is of an acceptable scientific standard.**

---

**Version 1**

Reviewer Report 03 September 2019

<https://doi.org/10.5256/f1000research.20985.r53108>



© 2019 Daniels G. This is an open access peer review report distributed under the terms of the [Creative Commons Attribution License](#), which permits unrestricted use, distribution, and reproduction in any medium, provided the original work is properly cited.



**Gregory A Daniels**

Department of Medicine, Division of Hematology/Oncology, University of California San Diego, La Jolla, CA, USA

The case of this 60 y/o man with a history of at least two non-melanoma skin cancers details the use of targeted hedgehog inhibitors for the initial BCC histology followed by cytotoxic chemotherapy and ultimately EGFR directed treatment for what now appears to be cuSCC at the same location. The authors raise the important point of re-biopsy at progression particularly in skin cancers where blended histologies or collision tumors may occur.

The use of Cetuximab has been a strategy for some time. The results outlined here are consistent with what is known—relatively modest clinical value. As referenced, the largest series found a relatively low response rate with modest durations for stable disease. The follow up here is short and the three month assessment is stable disease at best. Thus, the use of Cetuximab is of limited benefit as a single agent.

Anti-PD1 therapy is referenced as an option at progression. For usual advanced cuSCC in elderly not immune suppressed patients, this is actually the preferred first line therapy. The monoclonal Cemiplimab was approved for use in Europe in July of 2019 and prior to that in the US following the NEJM publication by Migden et al July 2018.<sup>1</sup> The field has dramatically changed and the case should be updated to reflect this change. In the absence of a contra-indication of immune therapy, anti-PD1 therapy is standard of care.

It would be very interesting to see an update to this case and the progress of this patient. At that point, the case would provide more information to clinicians.

Specific suggestions:

1. Include the NEJM paper outlining use of Cemiplimab in cuSCC not amenable to curative surgery or radiation.
2. Provide longer follow up than the 12 weeks reported.
3. Outline if the patient was treated with anti-PD1 therapy and why not.
4. Comment on toxicity of therapies.
5. The authors are correct in making the statement that PDL1 testing may not be needed for response to anti-PD1 therapy in this disease. In fact, Cemiplimab is approved without the requirement for testing.
6. If available, it would be interesting to see NGS on the tumor. The tumor mutation burden for cuSCC is very high with some usual mutations (i.e. p53 and NOTCH). As this was a confusion in the case, this data may help clarify the origin of this tumor.

## References

1. Migden M, Rischin D, Schmults C, Guminski A, Hauschild A, Lewis K, Chung C, Hernandez-Aya L, Lim A, Chang A, Rabinowits G, Thai A, Dunn L, Hughes B, Khushalani N, Modi B, Schadendorf D, Gao B, Seebach F, Li S, Li J, Mathias M, Booth J, Mohan K, Stankevich E, Babiker H, Brana I, Gil-Martin M, Homsí J, Johnson M, Moreno V, Niu J, Owonikoko T, Papadopoulos K, Yancopoulos G, Lowy I, Fury M: PD-1 Blockade with Cemiplimab in Advanced Cutaneous Squamous-Cell Carcinoma. *New England Journal of Medicine*. 2018; **379** (4): 341-351 [Publisher Full Text](#)

**Is the background of the case's history and progression described in sufficient detail?**

Yes

**Are enough details provided of any physical examination and diagnostic tests, treatment given and outcomes?**

Partly

**Is sufficient discussion included of the importance of the findings and their relevance to future understanding of disease processes, diagnosis or treatment?**

No

**Is the case presented with sufficient detail to be useful for other practitioners?**

Yes

**Competing Interests:** I consult for Regeneron and Sanofi who manufacture and market Cemiplimab

**Reviewer Expertise:** Medical oncology.

**I confirm that I have read this submission and believe that I have an appropriate level of expertise to confirm that it is of an acceptable scientific standard, however I have significant reservations, as outlined above.**

Author Response 03 Dec 2019

**Alvise Sernicola**, Sapienza University of Rome, Piazzale Aldo Moro 5, Rome, Italy

Dear reviewer,

Thank you for your very accurate review of our paper. We have carefully reviewed all of your suggestions and corrections and revised the manuscript accordingly. Our responses are given in a point-by-point manner below.

We hope the revised version is now suitable for publication and look forward to hearing from you.

Specific suggestions:

1. Include the NEJM paper outlining use of Cemiplimab in cuSCC not amenable to curative surgery or radiation.

**Reference to the paper by Migden was added to the introduction: "In 2018, a study by Migden et al. dramatically changed the previous scenario establishing the new standard of care with PD-1 blockade in immune-competent patients, in the absence of**

**contra-indications to immunotherapy (4). Anti-PD1 monoclonal antibody cemiplimab was consequently approved for use in Europe in July 2019.”**

2. Provide longer follow up than the 12 weeks reported.

**We have provided a follow up of up to 80 weeks of treatment with cetuximab as a single agent (54 weeks) and in combination with nivolumab (26 weeks).**

3. Outline if the patient was treated with anti-PD1 therapy and why not.

**Following progression to stage IV disease during cetuximab therapy, “Combination therapy with the addition of PD-1 blocker was planned and we employed locally available anti-PD1 monoclonal antibody nivolumab according to the following scheme: cetuximab single dose of 250mg/m<sup>2</sup> Q2W and nivolumab single fixed dose of 240mg Q2W administered at alternating weeks.” (case presentation)**

4. Comment on toxicity of therapies.

**Adverse events to cetuximab has been added to the case presentation: “Therapy was well tolerated, with the only complaint of an acneiform eruption, which began after one week of treatment and was managed with clindamycin 1% gel twice a day and oral minocycline 100mg twice a day for four weeks.”**

**Toxicity has been commented in the discussion: “A diffuse papulopustular acneiform eruption is the most common cutaneous reaction pattern to EGFR inhibitors, reported in over two-thirds of treated subjects but severe in only 5-10% of cases. Cetuximab cutaneous toxicity is suggested to be a proxy for treatment response (10).”**

5. The authors are correct in making the statement that PDL1 testing may not be needed for response to anti-PD1 therapy in this disease. In fact, Cemiplimab is approved without the requirement for testing.

**Thank you, this has been made explicit in the conclusions: “Low PDL-1 expression does not preclude the efficacy of checkpoint inhibitors; in fact, cemiplimab is approved without requirement for testing.”**

6. If available, it would be interesting to see NGS on the tumor. The tumor mutation burden for cuSCC is very high with some usual mutations (i.e. p53 and NOTCH). As this was a confusion in the case, this data may help clarify the origin of this tumor.

**Thank you for your suggestion, NGS assessment of tumor mutation burden was not available.**

***Competing Interests:*** No competing interests were disclosed.

The benefits of publishing with F1000Research:

- Your article is published within days, with no editorial bias
- You can publish traditional articles, null/negative results, case reports, data notes and more

- The peer review process is transparent and collaborative
- Your article is indexed in PubMed after passing peer review
- Dedicated customer support at every stage

For pre-submission enquiries, contact [research@f1000.com](mailto:research@f1000.com)

**F1000Research**