

Melanonychia: Etiology, Diagnosis, and Treatment

Abstract

Melanonychia is a very worrisome entity for most patients. It is characterized by brownish black discoloration of nail plate and is a common cause of nail plate pigmentation. The aetiology of melanonychia ranges from more common benign causes to less common invasive and in situ melanomas. Melanonychia especially in a longitudinal band form can be due to both local and systemic causes. An understanding of the epidemiology, pathophysiology and clinical details is necessary for adequate patient care and counseling. It not only helps in the early recognition of melanoma but also prevents unnecessary invasive work up in cases with benign etiology. An early diagnosis of malignant lesion is the key to favourable outcome. Though there are no established guidelines or algorithms for evaluating melanonychia, a systematic stepwise approach has been suggested to arrive at a probable etiology. We, hereby, review the aetiology, clinical features, diagnostic modalities and management protocol for melanonychia.

Keywords: *Dermoscopy, longitudinal melanonychia, melanonychia, nail, onychoscopy, pigmentation*

Definition

Melanonychia refers to the Greek word “Melas” meaning black (or brown colour) and “Onyx” meaning nail. It is characterized by brown-black discoloration of the nail plate and the pigment referred to is conventionally melanin. It may involve single or multiple nails, both in finger and toenails.

Epidemiology

Melanonychia is a common cause of nail discoloration accounting for nearly half of the cases of chromonychia.^[1] Longitudinal melanonychia is the commonest morphological pattern.^[1] The data on prevalence of melanonychia comes from the studies on melanonychia striata and varies with the region and population of study. In a recent study from China, the prevalence was found to be 0.8%, equal among male and female.^[2] While in Poland, melanonychia was observed in 19.46% with the mean age being 49 years,^[3] Kawamura *et al.*^[4] reported melanonychia in 11.4% with highest prevalence in people aged 21–26 years and Tasaki *et al.*^[5] found the prevalence to be 20% in males and 23% in females. The number of nails involved and the width of the pigmented lesions differ according to causative factors. While drug

This is an open access journal, and articles are distributed under the terms of the Creative Commons Attribution-NonCommercial-ShareAlike 4.0 License, which allows others to remix, tweak, and build upon the work non-commercially, as long as appropriate credit is given and the new creations are licensed under the identical terms.

For reprints contact: reprints@medknow.com

exposure, dermatological diseases, and racial pigmentation typically involve multiple nails, lentigines and nail matrix nevus are monodactylic (involving single nail/digit).

Morphological Classification

A simple morphological classification of melanonychia is given in [Table 1 and Figures 1-3].

Pathogenesis

Though melanocytes are present in both nail matrix and bed, majority of them lie quiescent or dormant.^[6] Melanocyte activation following trauma, infection, or inflammation initiates melanin synthesis and then the melanin-rich melanosomes are transferred to the differentiating matrix cells through dendrites. These matrix cells migrate distally and eventually become nail plate onychocytes, resulting in visible pigmentation in the nail plate.^[6,7] Alternatively, melanonychia may also result from nail matrix melanocyte proliferation with (nevus) or without nest formation (lentigine).

Etiology

There are two main mechanisms of melanonychia [Figure 4]

1. **Melanocytic activation**—Refers to increased melanin production from

How to cite this article: Singal A, Bisherwal K. Melanonychia: Etiology, Diagnosis, and Treatment. *Indian Dermatol Online J* 2020;11:1-11.

Received: April, 2019. **Revised:** May, 2019.

Accepted: June, 2019. **Published:** January, 2020.

Archana Singal,
Kavita Bisherwal¹

Department of Dermatology and STD, University College of Medical Sciences and GTB Hospital, ¹Department of Dermatology and STD, Lady Hardinge Medical College and SSK Hospital, New Delhi, India

Address for correspondence:

Dr. Archana Singal,
Department of Dermatology and STD, University College of Medical Sciences and GTB Hospital (University of Delhi), Delhi - 110 095, India.
E-mail: archanasingal@hotmail.com

Access this article online

Website: www.idoj.in

DOI: 10.4103/idoj.IDOJ_167_19

Quick Response Code:



normal number of activated melanocytes in the nail matrix.^[8] It is also known as melanocyte stimulation and results from numerous causes listed in Figure 4

2. **Melanocyte proliferation**—Means increased melanin pigment secondary to increased number of melanocytes in the nail matrix.^[8] The melanocytic hyperplasia or proliferation can be benign or malignant.

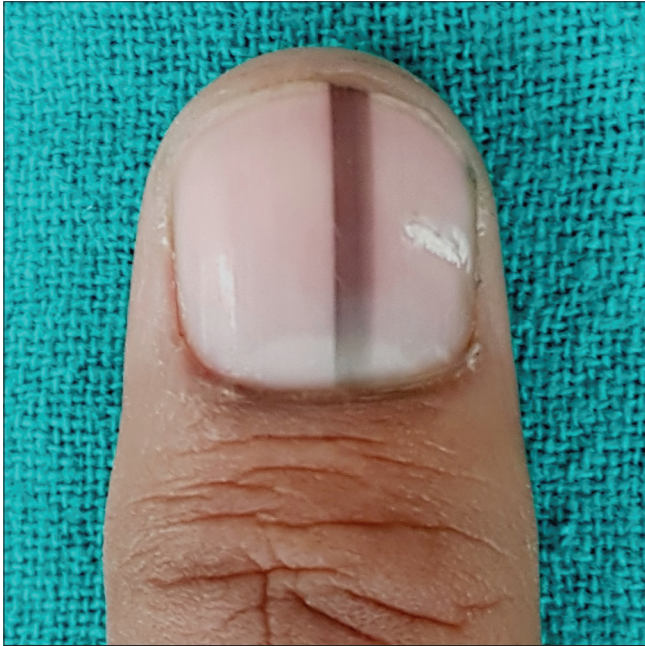

Figure 1: Longitudinal pigmented band in an adult involving solitary digit

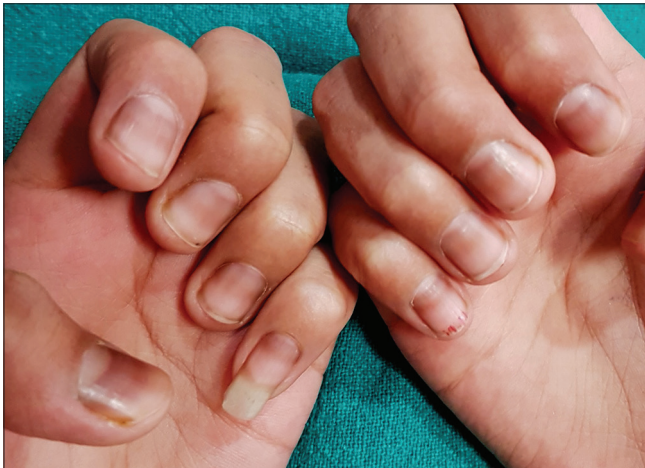

Figure 3: Transverse band of melanonychia in a young patient receiving chemotherapy

Nail matrix nevus and constitutional nail pigmentation are the most common causes.^[1] The percentage distribution of the aforesaid causes varies in different population. The most common cause in a study evaluating melanonychia of all morphologies was found to be subungual hemorrhage (29.1%), followed by nail matrix nevus (21.8%), trauma (14.5%), lentigo (11.6%), and race (8.0%).^[9] While in a study evaluating only longitudinal melanonychia, racial melanonychia was seen in 68.6%, trauma in 8.5%, fungal in 7.1%, and mixed etiology in 4.5% of cases.^[10] Benign melanocytic

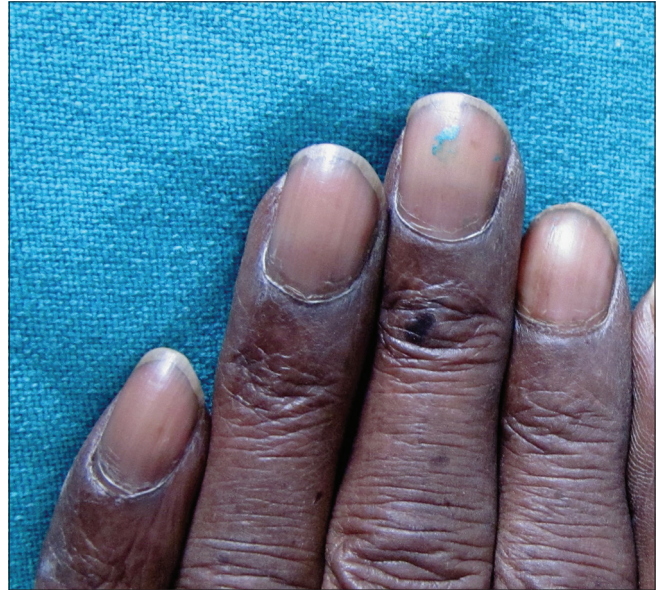

Figure 2: Diffuse nail plate pigmentation in an HIV-positive male patient

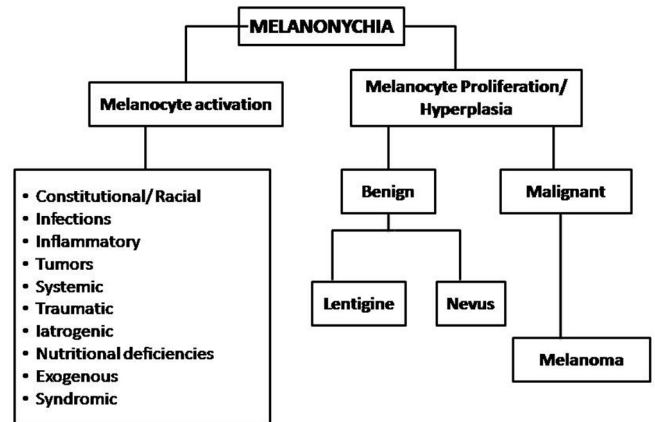


Figure 4: Etiology of melanonychia

Table 1: Morphological classification of melanonychia

Pattern of nail pigmentation	Clinical feature	Causes
Longitudinal melanonychia or melanonychia striata [Figure 1]	Longitudinal brown-black/grey band extending proximally from nail matrix or cuticle to distal free edge of the nail plate	Lentigine, nevus, melanoma
Diffuse or Total melanonychia [Figure 2]	Involvement of the entire nail plate by melanin	Constitutional/racial, drugs, infections
Transverse melanonychia [Figure 3]	Transverse band running across the width of nail plate	Drugs

hyperplasia and nail apparatus malignancy contributed to 5.7% cases each.

Clinical Features

Melanocytic activation

Constitutional

Racial melanonychia

It is commonly encountered in skin phototypes IV, V, and VI, that is, darkly pigmented races including Blacks, Asians, Middle-East, and Hispanics.^[11] The incidence reportedly varies from 1% in whites, 10%–20% in Japanese and Asians, and 77–100% in African Americans.^[7] Racial melanonychia is more common in fingers (thumb, index finger), generally involves multiple nails [Figure 5] and the band width increasing with age.

Pregnancy

Skin hyperpigmentation is of common occurrence during pregnancy. Longitudinal melanonychia may also be associated with pregnancy and generally involves several finger and/or toe nails. It is thought to result from the activation of nail matrix melanocytes and may resolve or persist following delivery.^[12,13]

Infections

Fungal melanonychia

Fungal melanonychia may be caused by both dematiaceous and nondematiaceous fungi; most common being *Trichophyton rubrum* and *Scytalidium dimidiatum*, followed by *Alternaria* and *Exophiala*.^[14] It is commonly seen in males with frequent involvement of toenails. Fungi produce soluble, nongranular melanin which gets incorporated into the nail plate.^[14] The involved nail typically has brown to black bands better seen with dermoscopy^[15] and subungual hyperkeratosis with or without

periungual inflammation. The pattern of nail involvement may indicate the causative agent. Longitudinal melanonychia is more common with dermatophytes like *Trichophyton rubrum* while diffuse pigmentation is seen with molds such as *Scytalidium*, *Aspergillus niger* [Figure 6], and *Alternaria*.^[14]

Bacterial melanonychia

This is frequently caused by Gram negative pathogens; *Pseudomonas aeruginosa*, *Klebsiella* and *Proteus*.^[16] The risk factors include wet work and an immunocompromised state. The pattern of nail involvement can be longitudinal streaks with wider proximal edge or diffuse which starts from the junction of proximal and lateral nail folds and spreads with irregular medial border.^[16]

Viral

HIV patients may show diffuse melanonychia or multiple longitudinal or transverse bands in multiple fingers and toenails, often associated with hyperpigmentation of palms, soles and mucous membranes.^[17] Longitudinal melanonychia can also be seen with ART drugs like zidovudine.^[17]

Inflammatory disorders

Inflammatory skin conditions like psoriasis, lichen planus, amyloidosis, chronic radio dermatitis, and chronic paronychia in and around nail unit leads to melanocytic activation resulting in melanonychia.^[7,18] Longitudinal melanonychia has also been seen in connective tissue diseases like systemic sclerosis and SLE.^[19,20]

Tumors

Longitudinal melanonychia can also occur due to melanocytic activation by nonmelanocytic benign and malignant tumors

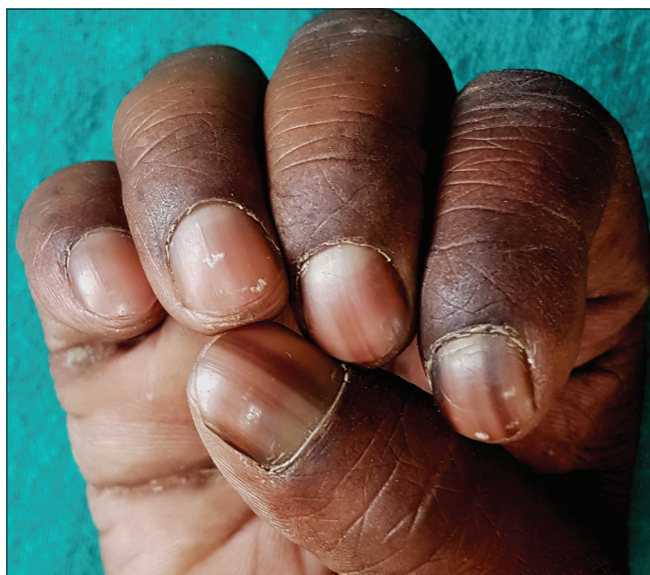

Figure 5: Racial melanonychia in an adult male with type 5 skin type

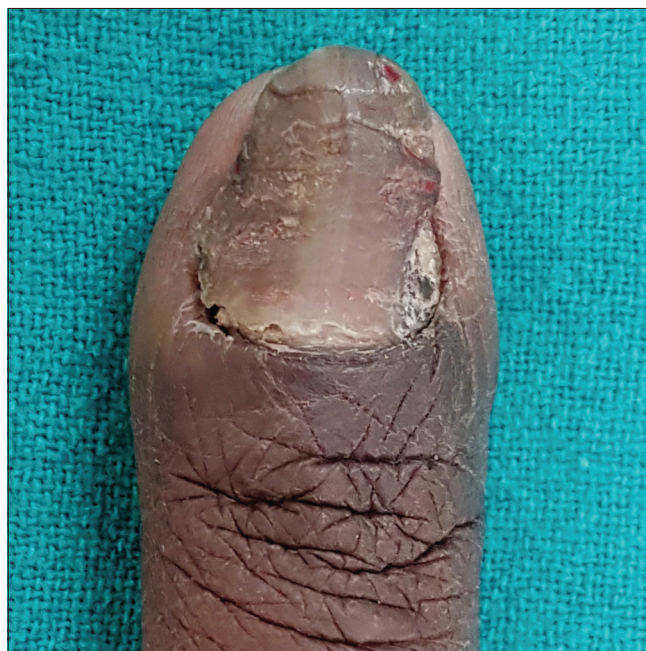

Figure 6: Fungal melanonychia caused by *Aspergillus niger*

such as onychomatricoma, Bowen's disease, squamous cell carcinoma, basal cell carcinoma, subungual fibrous histiocytoma, verruca vulgaris and subungual keratosis.^[11,21]

Systemic Diseases

Melanonychia in systemic diseases tends to involve multiple finger and toe nails, and generally presents as either diffuse melanonychia or multiple bands. It is uncommon and is seen in endocrine disorders (Addison's disease, Cushing's syndrome, hyperthyroidism and acromegaly), alkaptonuria, hemosiderosis, hyperbilirubinemia, and porphyria. It can also be seen in Graft Versus Host Disease (GVHD) and AIDS patients.^[18,22]

Traumatic Melanonychia

Repeated trauma as seen in onychotillomania, onychophagia, or friction may lead to melanonychia.

Onychotillomania and onychophagia

Trauma to the nail matrix due to nail biting, picking, chewing or pulling leads to nail matrix melanocytes activation. This results in diffuse or regular longitudinal gray parallel bands of nail plate pigmentation, often accompanied by nail plate and periungual signs of trauma [Figure 7].^[21]

Frictional

Chronic friction or pressure of ill fitted, tight, or pointed shoes leads to brown pigmentation of a part or whole of the great toe, fourth, and/or fifth toenails without any associated nail plate abnormalities.^[21] This is also seen in athletes due to trauma to the proximal nail fold overlying the matrix.^[21]

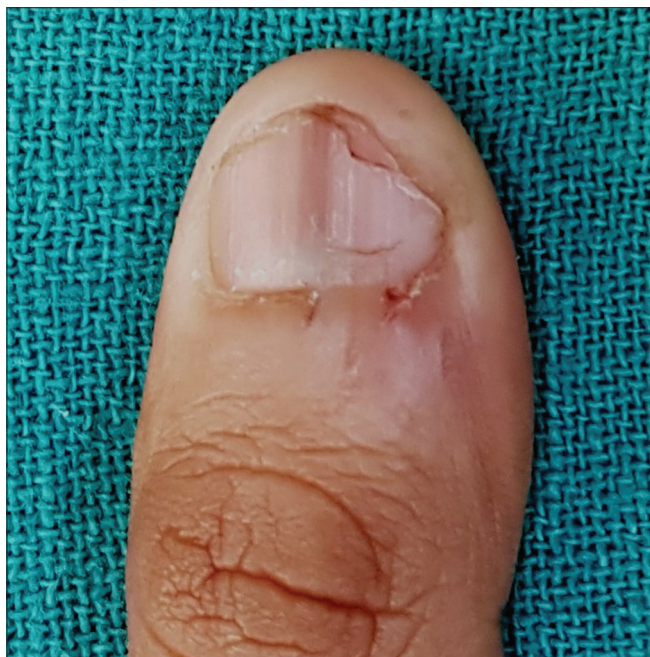

Figure 7: Longitudinal melanonychia in a male patient with onychophagia; note damaged cuticle and hang nails

Iatrogenic Melanonychia

Melanonychia involving several finger and toe nails may be caused by phototherapy, electron beam therapy, X-ray exposure, radiodermatitis, and drugs. The pattern of nail involvement can be diffuse, transverse, or longitudinal.

Drug-induced melanonychia

Drug-induced melanonychia is often associated with other mucosal and cutaneous pigmentations. The type of melanonychia varies with the causative drug; nail bed pigmentation, transverse bands, and longitudinal melanonychia can be seen either alone or together.^[7] Transverse melanonychia, although uncommon, is seen almost exclusively due to drugs.^[11] The pigmentation involves several nails that fade either partially or completely following drug withdrawal^[3] in 6–8 weeks but may take several months to years.^[7] The list of common drugs causing melanonychia and their features are listed in Table 2.^[7,11] Chemotherapeutic drugs are the most common agents.^[7] Intermittent administration of chemotherapy can result in alternating bands of pigmentation.^[23]

Nutritional Deficiencies

Longitudinal melanonychia is seen in malnutrition especially protein energy malnutrition and vitamin D deficiency.^[24] Vitamin B12 deficiency produces reversible nail pigmentation that can be longitudinal, diffuse bluish or reticulate probably due to reduced glutathione levels resulting in disinhibition of tyrosinase enzyme involved in melanogenesis.^[25]

Exogenous Pigmentation

Brown to black pigmentation of nails can be seen due to exogenous agents like henna, dirt, tobacco, potassium permanganate, tar, and silver nitrate.^[16] It presents as a horizontal band with the distal border parallel to the proximal nail fold and tends to move out with the nail plate [Figure 8].^[16] Silver nitrate presents with a dark color band with irregular medial border and staining of adjacent skin of nail folds.^[16]

Syndromes Associated with Melanonychia

Laugier–Hunziker syndrome, Peutz–Jegher and Touraine syndrome are characterized by LM along with pigmented macules in oral mucosa and lips.^[7] LM involves several nails, generally finger nails with one or more bands. Laugier–Hunziker syndrome appears between 20 and 40 years of age and has no family history. On the contrary, Peutz–Jeghers and Touraine show autosomal dominant inheritance; the pigmented macules usually appear early during childhood and both are associated with intestinal polyposis and an increased risk for gastrointestinal and pancreatic malignancies.^[7]

Sub-ungual Hematoma

Hematoma is the most common cause of nail brown-black pigmentation. It can be either acute (following single heavy trauma) or chronic (repeated, micro trauma). While acute

Table 2: Drug-induced melanonychia

Drugs	Features
Chemotherapeutic agents-Cyclophosphamide, doxorubicin, hydroxyurea, busulfan, taxanes, capecitabine, cisplatin, bleomycin, daunorubicin, dacarbazine, 5-FU, methotrexate	Seen 1-2 months after initiation One or more transverse or longitudinal bands Cyclophosphamide-Diffuse black, longitudinal, or dark gray pigmentation of proximal nail plate ^[14] Doxorubicin: Alternating bands of dark brown and white lines, and transverse bands ^[14] Hydroxycarbamide: Distal or diffuse, dark brown ^[14] Diffuse blue-brown, transverse or longitudinal bands Fingernails > toenails. Appears after 3-8 weeks Reversible within 6-8 weeks, may persist for months Melanonychia due to melanin and ferric dyschromia ^[3] Diffuse pigmentation, multiple nails
ART-Zidovudine, Lamivudine	
Antimalarials-Amodiaquine, chloroquine, mepacrine, quinacrine Others-Biologicals, clofazimine, infliximab, psoralens, phenytoin, fluconazole, cyclins, ketoconazole, phenothiazines, sulphonamides Metals-Arsenic, Thallium, Mercury	




Figure 8: Exogenous melanonychia due to henna; note the advancing margin parallel to the PNF

subungual hematoma has a deep red/purple band and do not reach the free margin of the nail [Figure 9],^[16] chronic subungual hematoma has a red brown, elliptical shape mimicking a longitudinal streak.^[16] A true longitudinal band is seen very rarely. Small, round blood globules are seen at the periphery of hematoma on dermoscopy.

Melanocytic Proliferation/hyperplasia

Benign Melanocytic Hyperplasia

It can be either due to nevus or lentigo. Lentigines are often seen more than nevi in adults while nevi are more common than lentigines in children.^[11]

Nail matrix nevus

Nail matrix nevus may be congenital or acquired, majority being junctional. Nevus represents 12% of LM in adults and 48% of LM in children.^[8,26] It generally presents as a light brown to black, 3–5 mm broad longitudinal band on

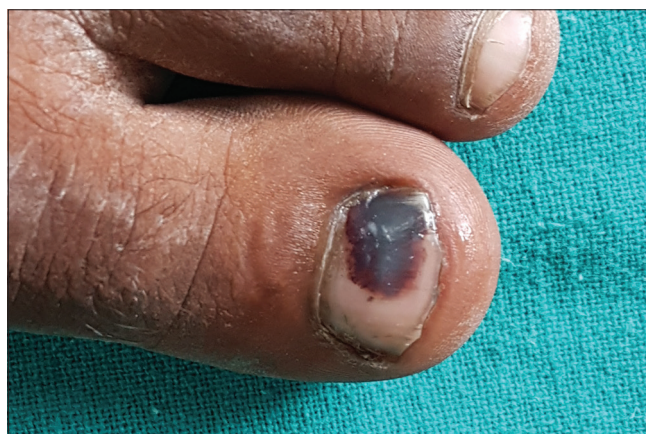

Figure 9: Melanonychia due to subungual hematoma following acute blunt injury

fingernails especially thumb [Figure 10a].^[21] The pigmentation is generally homogenous in intensity and color but dark bands may arise on light background, appreciated better on onychoscopy [Figure 10b]. Darker bands may be associated with periungual pigmentation (pseudo Hutchinson's sign) in one-third of the cases.^[7,21] Histologically, nevus is characterized by the formation of nest of melanocytes.^[7]

Lentigo

Lentigo is characterized by melanocytic hyperplasia with absence of melanocyte nests. Increased melanocytes (5–31 mm) are present within nail matrix epithelium. Lentigo in the nail matrix is more common in adults [Figure 11] and is observed in around 9% of all LM cases in adults.^[8,26]

Malignant Melanocytic Hyperplasia

Melanoma

Nail unit melanoma (NUM) is rare. It comprises about 0.7%–3.5% of all cases of cutaneous melanoma in the western world.^[27] The incidence is variable in different races

with a higher incidence (10%-25%) reported from Asian countries including Japan, China, and Korea.^[27,28] The peak incidence is seen in 5th to 7th decades of life. Thumb, great toe, and middle finger are common sites.^[7,28] LM is the first manifestation of NUM in 38%–76% of the cases.^[27] Variegation in color, irregular/blurred borders of the band, crisscrossing, periungual pigmentation (Hutchinson sign), nail dystrophy, and ulceration or blood spots indicate malignant change [Figure 12] and a biopsy should be considered.^[6,16] In rapidly growing melanomas, the proximal end of the band may be wider than the distal portion known as pyramidal sign [Figure 13]. NUM carries a poor prognosis as compared to cutaneous melanomas probably due to delay in diagnosis, the average delay being 2 years.^[7,29] The five-year survival rate is 51%; 88% for a Breslow thickness of 2.5 mm or less and 44% for a thickness greater than 2.5 mm.^[30]

Evaluation of Melanonychia

History

A detailed history including patient's age, history of trauma/any triggering factor, exogenous substance exposure,

occupational history, hobbies, drug history, medical and family history is important. The onset (gradual/sudden), duration (short/long), rate of progression of melanonychia, and change in color or width of band must be enquired.

Clinical examination

Examination of all finger and toe nails and a complete muco-cutaneous examination is important for evaluation of melanonychia. One should note:

- Number and location of involved nails—single/multiple
- Morphology of LM—whether similar or different, if multiple nails involved

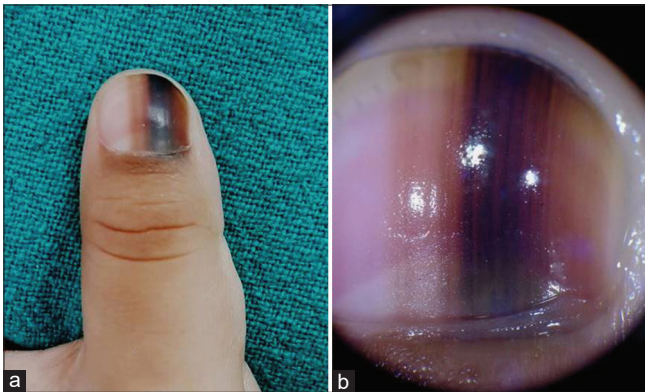


Figure 10: Longitudinal melanonychia due to nail matrix nevus of the right thumb in 2.5 years-old boy. The band is 4 mm wide and brown in color (a). Dermoscopy shows regularly placed parallel lines of variable color. Note the pigment is visible on the PNF under the cuticle (b)

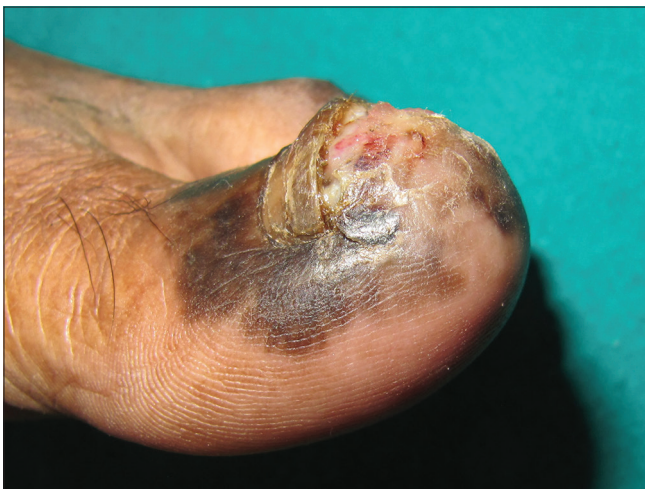

Figure 12: Subungual malignant melanoma with nail plate dystrophy, ulceration, and Hutchinson's sign

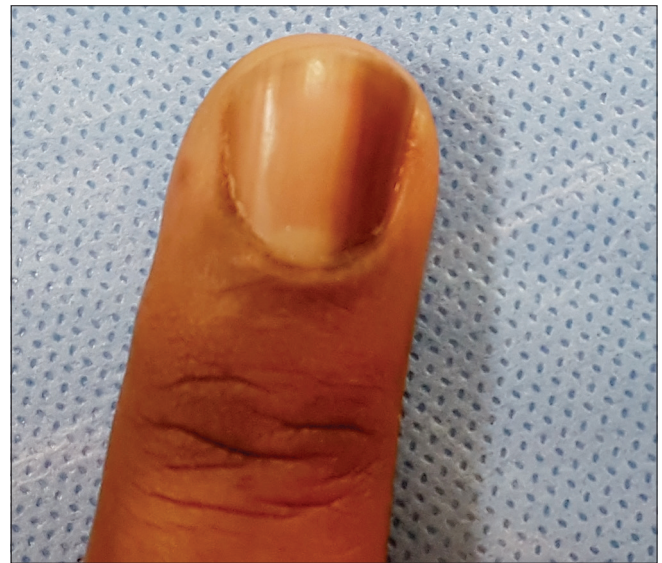

Figure 11: Lentigo of nail matrix presenting as longitudinal melanonychia in a 55-years old man

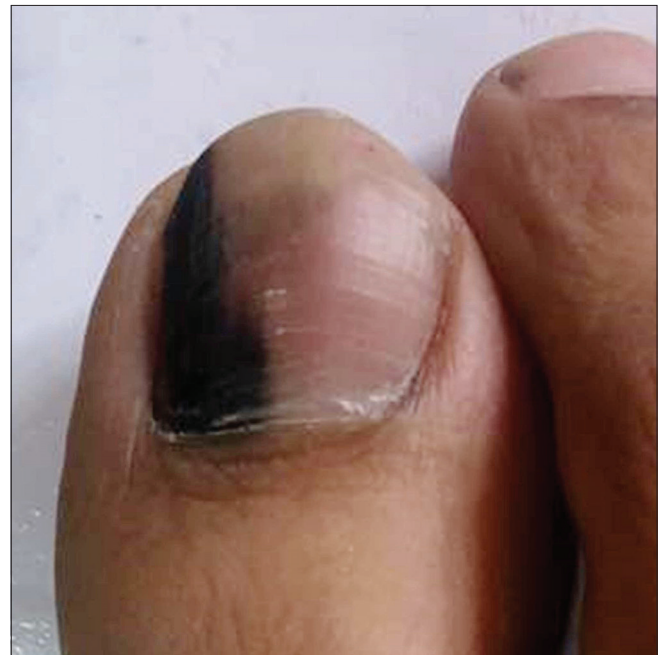

Figure 13: Longitudinal pigmented band with broad proximal and narrow distal ends

- Site or location of melanonychia on the nail plate—above, within, or beneath. Examination of the distal free edge of the nail plate or hyponychium might indicate the origin of pigment. Ventral nail plate pigmentation originates from the distal matrix while the dorsal nail plate from proximal matrix.^[21] The localization of pigment helps in selecting the anatomic site for exploration and biopsy, and can prevent a visible definitive nail dystrophy if the surgery is confined to the distal matrix^[21]
- Pattern of melanonychia—complete, longitudinal, or transverse.
Complete melanonychia—The extent and configuration (proximal and distal end including shape of proximal end of pigmentation with respect to proximal nail fold)
Longitudinal melanonychia (LM)—Color, homogeneity, regularity, width, whether wider proximally or distally, shape, margins and lateral borders of the band. Pyramid-shaped melanonychia with base toward proximal nail fold is suggestive of NUM
- Other nail signs—Nail dystrophy, nail plate changes (abrasion, splitting or fissuring) and periungual pigmentation, bleeding are pointers to NUM. In addition, nail dystrophy and nail plate changes and pigmentation may be seen in fungal melanonychia
- Other mucocutaneous sites for any inflammatory disorders, syndromic associations.

The ABCDEF rule helps to distinguish alarming LM from the nonalarming ones:^[31] [Box 1]

Laboratory evaluation

Nail plate sampling by nail clipping or punch biopsy can be done in doubtful cases about the nature of the pigment and in cases suspicious of fungal melanonychia.^[18] The samples are sent for direct microscopy and culture (to exclude onychomycosis) and for histopathology (to confirm melanic pigmentation by Fontana stain).^[18]

Dermoscopy of nail apparatus (Onychoscopy)

Onychoscopy has become an indispensable tool in the evaluation of pigmented nail lesions as it helps in validating the clinical findings. Onychoscopic examination of nail plate and distal edge is usually done with a magnification of 10 × with a handheld dermoscope or a digital videodermoscope.^[32] Polarizing filters are less efficient in evaluation of nail plate due to their optical properties. Due to the convexity of nail plate, oil or gel immersion is required for visualization.^[32] Distal edge onychoscopy generally requires more immersion gel or oil.^[33] There are three basic steps:^[34]

1. Differentiate the melanin and nonmelanin pigmentations.^[35,36] [Table 3]. It is of utmost importance to identify subungual hematoma by the history of trauma and characteristic onychoscopic appearance. A subungual hematoma is identified by

globules of various sizes and color—from bright red, brown to black depending upon the depth and duration of hemorrhage [Figure 14]. However, it should be remembered that subungual hemorrhage does not rule out melanoma

2. Determine the cause of pigmentation—melanocytic activation or proliferation.^[24,25] [Table 4]
3. Distinguish benign and malignant proliferations.^[35,36] [Table 4].

Limitations of Onychoscopy in melanonychia^[21]

1. Overlap in various onychoscopic patterns exists. The brown background with lines irregular in color, width, and spacing are not indicative of melanoma in children. Benign lesions in adults can present with irregular lines and spacing
2. No established accurate onychoscopic patterns in the diagnosis of NUM
3. No criteria for frequency of onychoscopic follow-up in patients with LM
4. No precise onychoscopic criteria for deciding the precise time for biopsy.

Box 1: The ABCDEF rule in LM

The ABCDEF rule in LM

A (*age, Afro-Americans, native Americans, and Asians*): 5th and 7th decades

B (*nail band*): brown to black colour, ≥3 mm wide, irregular borders

C (*change*): rapid ↑ in size of band and/or change in morphology

D (*digit involved*): thumb > hallux > index finger, dominant hand, single digit

E (*extension*): Hutchinson's sign

F (*family*): Personal or familial history of nevi dysplastic syndrome and melanoma.

Table 3: Onychoscopic features of pigmentation

Type of pigmentation	Onychoscopic features
Melanin pigmentation	Brown-black, within nail plate, generally as a longitudinal band
Exogenous pigmentation (blood, henna, nail paint)	Substances adhering to or below nail plate, no longitudinal appearance, homogenous and located near nail folds with advancing margin running parallel to PNF

Table 4: Onychoscopic features of cause of melanonychia

Cause	Onychoscopic features
Melanocytic activation	Involvement of several nails, pale bands. Homogeneous grayish coloration of the background with regular gray lines is typical
Benign melanocytic proliferation	Brown background with brown-black parallel longitudinal lines of identical color, regular spacing and width
Malignant melanocytic proliferation	Variegate brown background with longitudinal brown to black lines that are irregular in width, spacing and demonstrate loss of parallelism.

Intraoperative onychoscopy (nail bed and matrix)—This is indicated in suspicious cases while performing nail matrix biopsy. It allows direct visualization of various dermoscopic patterns [Box 2] in nail bed and matrix.^[37,38] It also helps in selecting the surgical margins for complete excision of the lesion.^[37,38]

Biopsy

Whenever there is a doubt of NUM on clinical features and onychoscopy, histopathological diagnosis is the gold standard for confirmation of NUM. The preoperative diagnostic accuracy of melanoma ranges from 46% to 55%.^[39]

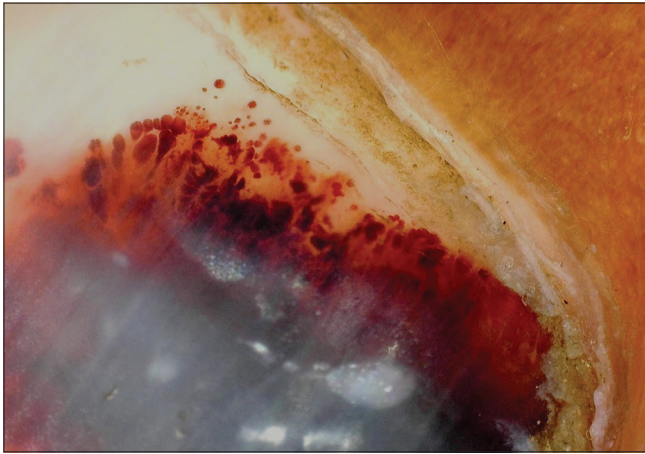


Figure 14: Onychoscopy of subungual hematoma; note globules of varying size and color at the margin (DermLite, non-polarized, non-contact; x10x)

Box 2: Features of intraoperative onychoscopy

Pattern	Etiology
Regular gray	Melanocytic activation
Regular brown	Lentigo
Regular brown with globules (cell nests) or blotches (large pigment)	Melanocytic nevus
Irregular	Melanoma

There are no standard guidelines or algorithm for indications and time of biopsy in LM. It is suggested that any unexplained melanonychia of a single digit in white races should be biopsied to rule out NUM. On the contrary, LM of single digit in other races or LM in multiple nails may be followed up and biopsied whenever required.^[6,39] In children, management is generally conservative as NUM is rare in this age group.

The type and site of biopsy depends upon the morphological characteristics of LM—its width and location of pigmentation in the matrix.^[18] The sites and type of biopsies for melanonychia are listed in Table 5.^[11,16,18,40] The biopsy sample should be of good quality, representative, adequate and from right location for proper diagnosis. An excisional biopsy whenever possible is recommended and matricial origin of pigmentation should be removed completely. Full-thickness matrix biopsy avoids any misdiagnosis and aids in prognosis by assessing Breslow depth. Nail matrix biopsy can cause nail scarring and deformity. To minimize these, distal nail matrix biopsy is preferred over proximal and the resultant defect of >3 mm should be sutured.^[11]

The histopathological features in different causes of melanonychia are listed in Table 6.^[41,42]

Imaging

Nail unit ultrasound and MRI can help in the diagnosis of melanonychia suspected due to nail tumors. They can also help in delineating the extent of lesion and involvement of adjacent structures.

Differential Diagnoses and Approach to Melanonychia

The following are the differential diagnoses of melanonychia according to the presentation.^[34]

1. Nonmelanin pigmentation: The first and essential step is to establish the melanin or nonmelanin (e.g., exogenous, infections, hematoma) etiology

Table 5: Biopsy considerations in melanonychia

Characteristics of LM	Type of biopsy	Site of biopsy
LM <2.5-3 mm, distal matrix origin	Punch biopsy	From the origin and deep until periosteum
LM <2 mm, proximal matrix origin	Punch biopsy/shave excision	At the origin, deep till periosteum
LM 3-6 mm wide, distal 2/3 rd matrix origin	Transverse elliptical incision/shave excision	Proximal matrix remains intact, thin nail plate regenerates postoperatively
LM 3-6 mm, proximal 1/3 rd matrix	Releasing flap method	Leaves post-surgical dystrophy (longitudinal nail splitting)
Bands >6 mm or Proximal matrix origin of any width or Lesions less suspicious of melanoma	Tangential/shave excision	
Pigmentation on lateral one-third of nail	Lateral longitudinal excision	Allows sampling of all components of the nail unit
High likelihood of invasive melanoma	Full thickness excision or biopsy	
Full thickness nail pigmentation	Excision biopsy or en bloc excision of nail apparatus	

Table 6: Histopathological features in melanonychia

Cause of melanonychia	Histopathological features
Melanocytic activation	Epithelial hyperpigmentation, Normal melanocytic number and structure (4-9 mm interval or 200 mm ²), Dendritic melanocytes, Scattered melanophages, No mitosis
Lentigo	Increased melanocytes (10-31 mm segment) with abnormal location, Full-thickness pigmentation in matrix epithelium and nail plate, Dendritic melanocytes, Mild cytological atypia, Few melanophages, No cell nests and suprabasal melanocytes. No epithelial hyperplasia and pagetoid spread in matrix
Melanocytic nevus	Junctional nevus with lentiginous pattern, Melanocytic proliferation, Irregular or slightly confluent cell nests. Suprabasal pagetoid spread, Mild nuclear pleomorphism, Minimal cytological atypia, dermal inflammation, and nail plate involvement
In-situ melanoma	Infiltrative edge, Increased melanocyte proliferation and suprabasal melanocytes, Irregular distribution and asymmetry of melanocytes, Tendency of fusion in nests and epidermal consumption, Cytological atypia, Dermal lymphoid cell infiltration
Invasive melanoma	Atypical melanocytic proliferation (39-136/mm), Irregular distribution of melanocytes, Confluent and irregularly dispersed cell nests with suprabasal scatter, Cytological atypia, Increased mitosis, Lymphocytic infiltrate and anisodendrocytosis

- Multiple nail involvement—Racial, systemic causes, or frictional
- Single nail explained by skin and nail diseases—Trauma, inflammatory disorders, or tumors
- LM in children—Nail matrix nevus, Regular follow ups required
- LM in adults—Histopathology may be needed if doubtful.

A comprehensive approach to melanonychia has been summarized in Figure 15.

Treatment

Treatment of melanonychia depends on the underlying cause. The treatment of associated systemic or locoregional disease, withdrawal of offending drug, avoidance of trauma, treatment of infections or correction of nutritional deficiencies may cause regression of pigmentation. Benign causes do not necessitate treatment and can be kept in follow up. Depending on thickness and histopathological characteristics, subungual melanoma may be managed by functional surgical treatment (wide local excision) or digit amputation with or without sentinel lymph node mapping/biopsy.^[43]

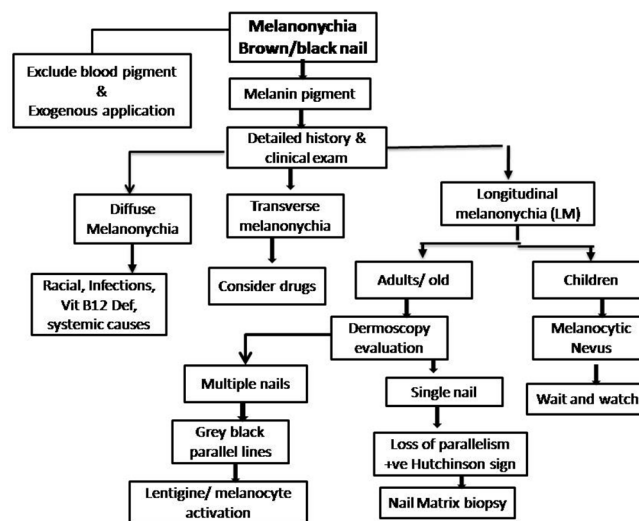


Figure 15: A comprehensive approach to evaluate melanonychia

Prognosis and Follow up

Prognosis of melanonychia depends on its etiology and its benign or malignant nature. Benign lesions can be followed up while NUM may carry a poor prognosis as discussed in the section. There is still no consensus for follow-up of melanonychia which requires periodic

medical examinations and photographic and dermoscopic documentations. Onychoscopy can be used for follow ups but there are no precise criteria for its frequency in patients with LM. Good-quality clinical as well as onychoscopic photographs highlighting the involved nail and the pigment morphology, color, and extent is necessary for follow ups. Patients should be counselled for self-examination and to report whenever any morphological change in pigmentation is noticed.

Conclusions

Melanonychia is a challenging symptom for the clinician, irrespective of the patient's age. With careful history, clinical examination and investigations, it is possible to delineate an etiology; benign or malignant, in majority. Onychoscopy has become an indispensable tool in the evaluation of pigmentary nail disorders and should be performed in all cases. In suspected cases, one should have a low threshold for performing nail matrix biopsy as tissue diagnosis remains the gold standard.

Financial support and sponsorship

Nil.

Conflicts of interest

There are no conflicts of interest.

Reference

- Bae SN, Young LM, Lee JB. Distinct patterns and aetiology of chromonychia. *Acta Derm Venereol* 2018;98:108-13.
- DLeung AK, Robson WL, Liu EK, Kao CP, Fong JH, Leong AG, *et al.* Melanonychia striata in Chinese children and adults. *Int J Dermatol* 2007;46:920-2.
- D Sobjanek M, Michajlowski I, Wlodarkiewicz A, Roszkiewicz J. Longitudinal melanonychia in a northern Polish population. *Int J Dermatol* 2014;53:e41-2.
- Kawamura T, Nishihara K, Kawasaki S. Pigmentatiolongitudinalis striata unguium and the pigmentation of nail plate in Addison disease. *Jpn J Dermatol* 1958;68:76-88.
- Tasaki K. On band or linear pigmentation of the nail. *Jpn J Dermatol* 1933;33:568.
- Perrin C, Michiels JF, Pisani A, Ortonne JP. Anatomic distribution of melanocytes in normal nail unit: An immunohistochemical investigation. *Am J Dermatopathol* 1997;19:462-7.
- Andre J, Lateur N. Pigmented nail disorders. *Dermatol Clin* 2006;24:329-39.
- Tosti A, Baran R, Piraccini BM, Cameli N, Fanti PA. Nail matrix nevi: A clinical and histopathological study of twenty-two patients. *J Am Acad Dermatol* 1996;34:765-71.
- Jin H, Kim JM, Kim GW, Song M, Kim HS, Ko HC, *et al.* Diagnostic criteria for and clinical review of melanonychia in Korean patients. *J Am Acad Dermatol*. 2016;74:1121-7.
- Dominguez-Cherit J, Roldan-Marin R, Pichardo-Velazquez P, Valente C, Fonte-Avalos V, Vega-Memije ME, *et al.* Melanonychia, melanocytic hyperplasia, and nail melanoma in a Hispanic population. *J Am Acad Dermatol* 2008;59:785-91.
- Jefferson J, Rich P. Melanonychia. *Dermatol Res Pract* 2012;2012:952186.
- Monteagudo B, Suárez O, Rodríguez I, Ginarte M, Leon A, Pereiro M, *et al.* Longitudinal melanonychia in pregnancy. *Actas Dermosifiliogr* 2005;96:550.
- Fryer JM, Werth VP. Pregnancy-associated hyperpigmentation: Longitudinal melanonychia. *J Am Acad Dermatol* 1992;26:493-4.
- Finch J, Arenas R, Baran R. Fungal melanonychia. *J Am Acad Dermatol* 2012;66:830-41.
- Wang YJ, Sun PL. Fungal melanonychia caused by *Trichophyton rubrum* and the value of dermoscopy. *Cutis* 2014;94:E5-6.
- Haneke E, Baran R. Longitudinal melanonychia. *Dermatol Surg* 2001;27:580-4.
- Cribier B, Mena ML, Rey D, Partisani M, Fabien V, Lang JM, *et al.* Nail changes in patients infected with human immunodeficiency virus. *Arch Dermatol*. 1998;134:1216-20.
- Lateur N, Andre J. Melanonychia: Diagnosis and treatment. *Dermatol Ther* 2002;15:131-41.
- Skowron F, Combemale P, Faisant M, Baran R, Kanitakis J, Dupin M. Functional melanonychia due to involvement of the nail matrix in systemic lupus erythematosus. *J Am Acad Dermatol* 2002;47(Suppl 2):187-8.
- Baran R. Longitudinal melanonychia in localized scleroderma: Report of four cases. *J Am Acad Dermatol* 2004;50:e11-3.
- Tosti A, Piraccini BM, de Farias DC. Dealing with melanonychia. *Semin Cutan Med Surg* 2009;28:49-54.
- Baran R, Dawber RPR, Richert B. Physical signs. In: Baran R, Dawber RPR, Deberker DAR, Haneke E, Tosti A, editors. *Baran and Dawber's diseases of the nails and their management*. 3rd ed. Oxford: Blackwell Science; 2001. p. 85-96.
- Robert C, Sibaud V, Mateus C, Verschoore M, Charles C, Lanoy E, *et al.* Nail toxicities induced by systemic anticancer treatments. *Lancet Oncol* 2015;16:e181-9.
- Seshadri D, De D. Nails in nutritional deficiencies. *Indian J Dermatol Venereol Leprol* 2012;78:237-41.
- Niiyama S, Mukai H. Reversible cutaneous hyperpigmentation and nails with white hair due to vitamin B12 deficiency. *Eur J Dermatol* 2007;17:551-2.
- Goettmann-Bonvallot S, Andre J, Belaich S. Longitudinal melanonychia in children: A clinical and histopathologic study of 40 cases. *J Am Acad Dermatol* 1999;41:17-22.
- Thai KE, Young R, Sinclair RD. Nail apparatusmelanoma. *Australas J Dermatol* 2001;42:71-81.
- Singal A, Pandhi D, Gogoi P, Grover C. Subungual melanoma is not so rare: Report of four cases from India. *Indian Dermatol Online J* 2017;8:471-4.
- Klausner JM, Inbar M, Gutman M, Weiss G, Skornick Y, Chaichik S, *et al.* Nail-bed melanoma. *J Am Acad Dermatol* 2007;56:803-10.
- Banfield CC, Redburn JC, Dawber RP. The incidence and prognosis of nailapparatus melanoma. A retrospective study of 105 patients in fourEnglish regions. *Br J Dermatol* 1998;139:276-9.
- Levit EK, Kagen MH, Scher RK, Grossman M, Altman E. The ABC rule for clinical detection of subungual melanoma. *J Am Acad Dermatol* 2000;42:269-74.
- Ronger S, Touzet S, Ligeron C, Balme B, Viillard AM, Thomas L. Dermoscopic examination of nail pigmentation. *Arch Dermatol* 2002;138:1327-33.
- Braun RP, Baran R, Saurat JH, Thomas L. Surgical pearl: Dermoscopy of the free edge of the nail to determine the level of nail plate pigmentation and the location of the probable origin in the proximal or distal nail matrix. *J Am Acad Dermatol* 2006;55:512-3.

34. Piraccini BM, Dika E, Fanti PA. Nail disorders: Practical tips for diagnosis and treatment. *Dermatol Clin* 2015;33:185-95.
35. Piraccini BM, Alessandrini A, Starace M. Onychoscopy: Dermoscopy of the Nails. *Dermatol Clin* 2018;36:431-8.
36. Lencastre A, Lamas A, Sa D, Tosti A. Onychoscopy. *Clin Dermatol* 2013;31:587-93.
37. Hirata SH, Yamada S, Almeida FA, Tomomori-Yamashita J, Enokihara MY, Paschoal FM, *et al.* Dermoscopy of the nail bed and matrix to assess melanonychia striata. *J Am Acad Dermatol* 2005;53:884-6.
38. Hirata SH, Yamada S, Almeida FA, Enokihara MY, Rosa IP, Enokihara MM, *et al.* Dermoscopic examination of the nail bed and matrix. *Int J Dermatol* 2006;45:28-30.
39. Di Chiacchio N, Hirata SH, Enokihara MY, Michalany NS, Fabbrocini G, Tosti A. Dermatologists' accuracy in early diagnosis of melanoma of the nail matrix. *Arch Dermatol* 2010;146:382-7.
40. Jellinek N. Nail matrix biopsy of longitudinal melanonychia: Diagnostic algorithm including the matrix shave biopsy. *J Am Acad Dermatol* 2007;56:803-10.
41. Guneş P, Goktay F. Melanocytic Lesions of the Nail Unit. *Dermatopathology* 2018;24:98-107.
42. Ruben BS. Pigmented lesions of the nail unit: Clinical and histopathologic features. *Semin Cutan Med Surg* 2010;29:148-58.
43. Dika E, Patrizi A, Fanti PA, Chessa MA, Reggiani C, Barisani A, *et al.* The Prognosis of Nail Apparatus Melanoma: 20 Years of Experience from a Single Institute. *Dermatology* 2016;232:177-84.