

OPEN

Malassezia furfur Emergence and Candidemia Trends in a Neonatal Intensive Care Unit During 10 Years

The Experience of Fluconazole Prophylaxis in a Single Hospital

I-Ting Chen, MD; Chih-Cheng Chen, MD; Hsin-Chun Huang, MD; Kuang-Che Kuo, MD

ABSTRACT

Background: Because *Candida* spp is a major cause of mortality and morbidity in preterm infants, fluconazole prophylaxis has been suggested by some experts and hospital policy. In our hospital, fluconazole prophylaxis was used in eligible preterm infants and set as the neonatal intensive care unit (NICU) practice in 2014.

Purpose: This study focused on fungal bloodstream infections and aimed to evaluate the benefit and harm of fluconazole prophylaxis.

Methods/Search Strategy: This retrospective, descriptive study involved medical record reviews in our hospital from April 2005 to October 2016. NICU patients were included if *Candida* species, yeast-like organisms, or *Malassezia* species were cultured from their venous catheter tips or blood cultures.

Findings/Results: After fluconazole prophylaxis, cases of *Candida* spp decreased and those of *Malassezia furfur* emerged. We reviewed 19 cases of catheter-related *M furfur* colonization and 1 case of *M furfur* fungemia. The gestational age was 27.3 ± 2.0 weeks and birth weight was 959.2 ± 229.8 g. Hyperalimentation with lipid infusion was used in all cases. All of the neonates survived with antifungal agent use.

Implications for Practice: This study highlights that prophylactic fluconazole may be an associated factor of *Malassezia* colonization; *M furfur* remains a potential concern for fungemia in the care of premature infants and thus requires our attention.

Implications for Research: Future studies should further investigate the incidence and impact of noncandidal fungal infections with fluconazole prophylaxis use in premature infants.

Key Words: candidemia, fluconazole prophylaxis, *Malassezia furfur*, neonatal, prematurity

BACKGROUND AND SIGNIFICANCE

Preterm infants are more vulnerable to fungal infections than full-term infants because of their immature immune systems and poorly developed epithelial skin and mucosal barriers, as well as the high rate of invasive procedures such as central venous catheter insertion and intubation. *Candida* spp has emerged as a common cause of infections in preterm infants admitted to the neonatal intensive care unit

(NICU). In very low birth-weight (VLBW) infants (below 1500 g), *Candida albicans* is the third most common cause of neonatal late-onset sepsis, which occurs after the first 72 hours of life.¹ Invasive candidal infections are associated with a significant risk of death, neurodevelopmental impairment, and increased healthcare costs. Because *Candida* spp is a major cause of mortality and morbidity in preterm infants, prophylaxis with antifungal agents in premature infants or those with extremely or very low birth-weight (ELBW or VLBW) has been suggested by some experts and hospital policy. The Infectious Diseases Society of America guidelines recommended the use of intravenous or oral fluconazole prophylaxis 3 to 6 mg/kg twice weekly for 6 weeks in neonates with birth weights less than 1000 g in nurseries with high rates (>10%) of invasive candidiasis.² The overall incidence of candidiasis in the NICU appears to decrease with the increased use of fluconazole prophylaxis in ELBW infants.^{3,4} Our institution has used fluconazole prophylaxis for premature infants since 2014.

Although fungal infections other than those caused by *Candida* species are uncommon, the incidence of noncandidal fungal infections, including *Malassezia*

Author Affiliation: Department of Pediatrics, Kaohsiung Chang Gung Memorial Hospital and Chang Gung University College of Medicine, Kaohsiung, Taiwan, ROC.

The authors declare no conflicts of interest.

This is an open-access article distributed under the terms of the Creative Commons Attribution-Non Commercial-No Derivatives License 4.0 (CCBY-NC-ND), where it is permissible to download and share the work provided it is properly cited. The work cannot be changed in any way or used commercially without permission from the journal.

Correspondence: Kuang-Che Kuo, MD, Division of Infectious Disease, Department of Pediatrics, Kaohsiung Chang Gung Memorial Hospital and Chang Gung University College of Medicine, No. 123, Dapi Rd, Niasong District, Kaohsiung City 833, Taiwan, ROC (light@cgmh.org.tw).

Copyright © 2019 The Authors. Published by Wolters Kluwer Health, Inc. on behalf of the National Association of Neonatal Nurses

DOI: 10.1097/ANC.0000000000000640

spp, appears to be increasing in preterm infants. *Malassezia furfur* is one species that mainly colonizes the skin and occasionally the respiratory tract and may cause neonatal infections.^{5,6} It requires exogenous long-chain fatty acids for growth, which may explain the associated risk of this infection in premature infants who receive intralipid emulsions.⁷ *Malassezia* spp may cause fungemia, localized infections such as pneumonia, or severe systemic infections, especially in immunocompromised and premature infant hosts.⁸⁻¹² Therefore, they may result in significant mortality and morbidity in preterm infants. In 1981, the first case of a neonatal *Malassezia* spp infection was reported in a preterm infant receiving intralipid emulsion therapy.¹³ Ilahi et al¹⁴ described a *Malassezia* spp outbreak in neonates that stopped after infection control measures, including the prohibition of a lipid-rich moisturizing hand cream used by the healthcare staff, were implemented.

Since 2014, several cases of catheter-related *M furfur* colonization have emerged in the NICU of Kaohsiung Chang Gung Memorial Hospital (KCGMH). During the same period, *Malassezia* spp did not emerge in other intensive care units of our hospital. The cluster has been consecutively investigated by the Department of Infection Control. In addition to hand hygiene measures, further surveillance involving environment, equipment, and medical staff was conducted. The cases were considered endogenous infections or colonization. According to literature review, risk factors related to *M furfur* colonization or infection have been well described, including prematurity, receipt of intralipid emulsions, and administration of broad-spectrum antibiotics. However, the risk factors remained the same as before but catheter-related *M furfur* colonization has emerged since 2014. As a result, we assumed that other factors related to clinical practice were associated with this kind of fungal outbreak in our NICU. This outbreak is worth paying attention because *M furfur* may cause invasive fungal infection as previously reported.⁸⁻¹⁰

Here we report our first clinical investigation of *M furfur* catheter-related colonization or infection and candidemia trends in our NICU over the past decade. This study focused on fungal bloodstream infections and aimed to evaluate the benefit and harm of fluconazole prophylaxis.

What This Study Adds

- Prophylaxis with antifungal agents in premature infants effectively diminishes the invasive candidal infection, which is one of the major causes of mortality and morbidity in preterm infants.
- *Malassezia furfur* remains a potential concern for fungemia in the care for premature infants and thus requires our attention.

METHODS

We collected data from the patient database of the NICU of KCGMH including those with bloodstream fungal infections or colonization via peripheral central venous catheter (pCVC) tip and blood cultures. The institutional review board (IRB) of the Chang Gung Medical Foundation approved this retrospective, descriptive study of all medical information with IRB approval. All medical records were anonymized and de-identified prior to the analysis. KCGMH is a medical center in southern Taiwan with a 30-bed NICU. The average number of NICU inpatients was 781 per year, which was the highest census of NICUs in southern Taiwan from 2005 to 2016. Prophylactic fluconazole (6 mg/kg per dose every 72 hours) has been routinely administered to the neonates in our NICU with a birth weight less than 1000 g or 1000-1250 g with pCVC since 2014 to prevent fungal infections. The clinical practice of our NICU requires that each pCVC removed from patients be subjected to tip culture, especially in cases of difficult removal, discharge, or erythematous changes at the insertion site. The blood sample is cultured in lipid-enriched fungal medium, and the BacT/Alert system is implemented by adding lipid substrates to increase the method sensitivity.

We conducted this retrospective, descriptive study of medical records from April 2005 to October 2016. During these years, patients were included if *Candida* species, yeast-like organisms, or *Malassezia* species were cultured from the pCVC tip or a blood culture. All cases were recorded with their clinical manifestations and demographic characteristics, including gestational age, birth weight, lipid infusion duration, prophylactic antifungal agent receipt, broad-spectrum antibiotic use, and hospitalization outcomes.

RESULTS

Eight cases of candidemia were reported between 2005 and 2013. Blood cultures revealed *C albicans* in 7 of the 8 cases and *Candida parapsilosis* in 1 case. The characteristics of the 8 cases of candidemia are shown in Table 1. The gestational age of the 8 cases was 28.3 ± 6.3 weeks (mean \pm standard deviation) and birth weight was 1570.6 ± 1236.4 g. All had pCVC with broad-spectrum antibiotic treatment and lipid infusion supplementation. No neonates received prophylactic fluconazole. All had invasive candidal infections with sepsis; 2 infants died.

We also obtained data including 19 cases of catheter-related *M furfur* colonization and 1 case of *M furfur* fungemia between 2014 and 2016. The characteristics of the 20 cases are described in Table 2. In the 19 cases of *M furfur* colonization, the male to female ratio was 9:10. The gestational age was

TABLE 1. Characteristics of 8 Cases of Candidemia

	Sex	GA, wk	BBW, g	Duration of SMOF, ^a d	Broad-Spectrum Antibiotics	Prophylactic Fluconazole ^b	Candida spp of the Blood Culture	Mortality
1	F	29 + 1	1260	12	Yes	Nil	<i>C albicans</i>	Survival
2	M	40 + 2	4000	8	Yes	Nil	<i>C albicans</i>	Survival
3	F	24 + 1	725	4	Yes	Nil	<i>C albicans</i>	Expired
4	M	23 + 3	670	23	Yes	Nil	<i>C albicans</i>	Survival
5	M	27 + 2	1150	32	Yes	Nil	<i>C parapsilosis</i>	Survival
6	F	37	3000	15	Yes	Nil	<i>C albicans</i>	Survival
7	M	25 + 3	910	4	Yes	Nil	<i>C albicans</i>	Survival
8	F	25 + 4	850	49	Yes	Nil	<i>C albicans</i>	Expired

Abbreviations: BBW, birth body weight; F, female; GA, gestational age; M, male; SMOF, soybean oil, medium-chain triglycerides, olive oil, and fish oil.

^aLipid infusion routinely used at our neonatal intensive care unit.

^bProphylactic fluconazole: 6 mg/kg every 72 hours.

TABLE 2. Characteristics of 20 Cases of Catheter-Related *Malassezia furfur* Colonization or Fungemia

	Sex	GA, wk	BBW, g	Duration of SMOF, ^a d	Broad-Spectrum Antibiotics	Prophylactic Fluconazole ^b	Culture of <i>M furfur</i>	Outcome	Mortality
1	F	27	880	18	Yes	Yes	pCVC tip	Unaffected	Survival
2	M	28 + 3	1080	38	Yes	Yes	pCVC tip	Unaffected	Survival
3	M	28 + 5	1140	9	Yes	Nil	pCVC tip	Unaffected	Survival
4	M	27 + 6	920	23	Yes	Yes	pCVC tip	Unaffected	Survival
5	F	27 + 5	710	30	Yes	Yes	pCVC tip	Unaffected	Survival
6	F	26 + 3	780	44	Yes	Yes	pCVC tip	Unaffected	Survival
7	M	28	770	48	Yes	Yes	pCVC tip	Unaffected	Survival
8	M	31	1420	28	Yes	Yes	pCVC tip	Unaffected	Survival
9	F	27 + 6	910	33	Yes	Yes	pCVC tip	Unaffected	Survival
10	M	25 + 3	760	32	Yes	Yes	pCVC tip	Unaffected	Survival
11	M	26 + 4	840	49	Yes	Yes	pCVC tip	Unaffected	Survival
12	F	29 + 1	1215	64	Yes	Yes	pCVC tip	Unaffected	Survival
13	F	26 + 3	990	27	Yes	Yes	pCVC tip	Unaffected	Survival
14	F	27	680	102	Yes	Yes	pCVC tip	Unaffected	Survival
15	M	24 + 5	660	62	Yes	Yes	pCVC tip	Unaffected	Survival
16	M	28 + 6	1170	48	Yes	Yes	Blood	Affected ^c	Survival
17	M	29 + 2	1090	52	Yes	Yes	pCVC tip	Unaffected	Survival
18	F	29 + 3	1320	62	Yes	Yes	pCVC tip	Unaffected	Survival
19	F	31 + 1	1260	25	Yes	Yes	pCVC tip	Unaffected	Survival
20	M	24 + 3	800	47	Yes	Yes	pCVC tip	Unaffected	Survival

Abbreviations: BBW, birth body weight; F, female; GA, gestational age; M, male; pCVC, percutaneous central venous catheter; SMOF, soybean oil, medium-chain triglycerides, olive oil, and fish oil.

^aLipid infusion routinely used at our neonatal intensive care unit.

^bProphylactic fluconazole: 6 mg/kg every 72 hours.

^cLonger stay with longer total parenteral nutrition support due to feeding intolerance during the period of invasive infection and subsequently with higher healthcare costs.

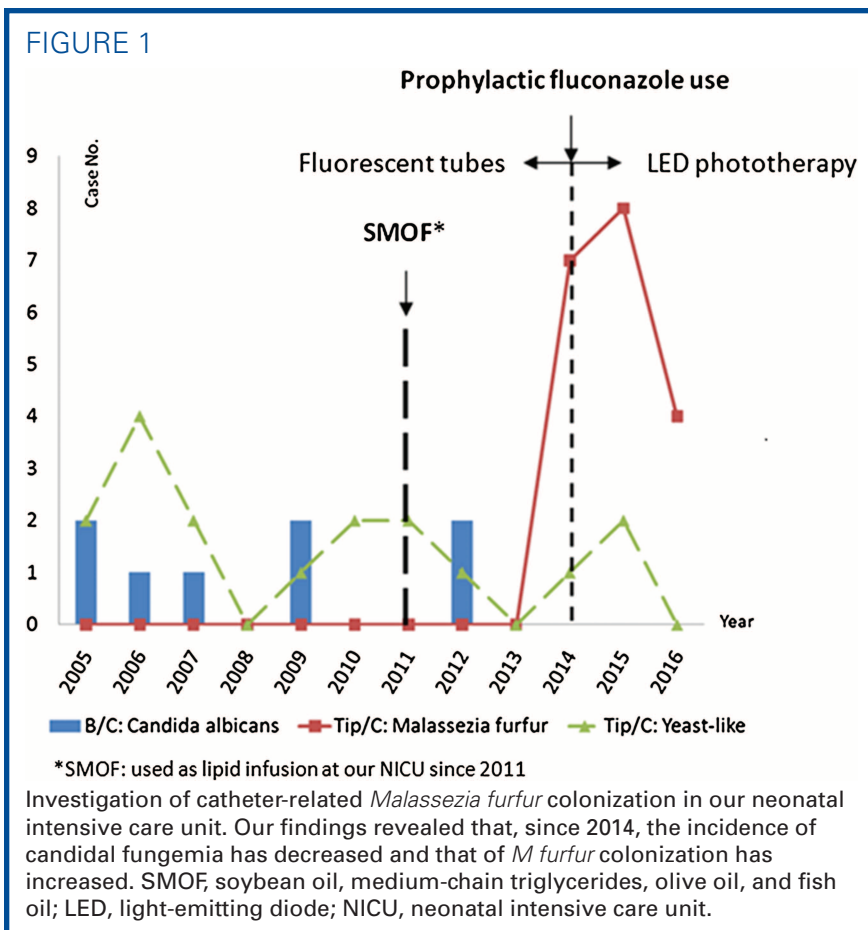
27.3 ± 2.0 weeks and birth weight was 959.2 ± 229.8 g. Twelve neonates were ELBW (<1000 g), whereas the other 7 were VLBW (1000-1500 g). Prophylactic fluconazole was administered to all but one patient, whose birth weight was 1140 g and who did not undergo central catheter placement immediately after birth. Lipid infusion was used in all neonates for a duration of 9 to 102 days. All underwent phototherapy for neonatal jaundice.

In all 20 cases, the only case of *M furfur* fungemia was treated with amphotericin B (1 mg/kg/d). For the other 19 neonates with positive tip cultures and negative blood culture, the initial management included pCVC removal. Eight of the 19 neonates remained on fluconazole at a prophylactic dose. In 7 of the 19 neonates, the prophylactic fluconazole dose was changed to a treatment dose (12 mg/kg/d). Four of the 19 neonates were administered amphotericin B (1 mg/kg/d).

Regarding the outcomes of the 19 cases with positive tip culture results, we reviewed the results of the blood cultures, manifestations of *M furfur* infection, and mortality rates. There was no fungemia or clinical manifestations of *M furfur* infection, including localized infection and fungemia-related symptoms observed in the 19 cases. The only case of *M furfur*

fungemia presented some nonspecific symptoms including apnea, bradycardia, and thrombocytopenia. This case required a longer duration of total parenteral nutrition support due to feeding intolerance during the period of the invasive infection and subsequently had higher healthcare costs. Ultimately, all 20 neonates survived and were discharged.

In the investigation of the catheter-related *M furfur* colonization or infection in our NICU, some possibly related factors were also reviewed, including soybean oil, medium-chain triglycerides, olive oil, and fish oil (SMOF), which is used as the routine lipid infusion in our NICU, the evolution of the phototherapy, and the clinical practice of the prophylactic fluconazole (Figure 1). First, we found that intrafat, which contains soybean oil and medium-chain triglycerides, was used for the lipid infusions before May 2011 in our NICU. Since 2011-2012, the intrafat was replaced by a combination of oils (SMOF) that are good for brain and retina development in prematurity. However, SMOF also contains olive oil, which is an important growth factor for *M furfur*.¹⁵ Furthermore, SMOF is used as a lipid emulsion only in the NICU of our hospital. In contrast, a lipid emulsion without olive oil has been used in our adult



ICU, in which no cases of *M furfur* colonization or infection have been observed. Figure 1 shows that *M furfur* colonization or infection emerged after SMOF was first used as routine lipid infusion at our NICU. Second, we found that the phototherapy light sources in our NICU had changed in recent years. Since 2014, light-emitting diodes (LEDs) have replaced fluorescent tubes for phototherapy since the narrower wavelength provides better treatment of neonatal jaundice. On the contrary, compared with the fluorescent tubes, the power consumption and heating caused by super LEDs are very low.^{16,17} Phototherapy using LEDs might reduce insensible water loss in neonates and preserve the environmental humidity. *Malassezia furfur* colonization or infection has emerged since LEDs were widely used (Figure 1). Third, both ELBW infants (birth weight <1000 g) and VLBW infants (1000-1250 g) who underwent central venous catheter placement were administered prophylactic fluconazole after 2014 in our NICU. Figure 1 shows that there have been no cases of candidemia in our NICU since 2014 and that the number of candidemia infections has reduced. In contrast, *M furfur*, which had never been previously identified in culture, has emerged since then.

DISCUSSION

Candida species are important hospital-acquired pathogens in NICU patients. Because of the poor clinical outcomes of neonates with candidemia, we modified the recommendations of the Infectious Diseases Society of America and set our own guidelines according to the clinical conditions, although the rate of invasive candidiasis in our NICU did not exceed 10%. On the basis of our study and literature review, we concluded that the use of prophylactic fluconazole reduced the incidence of invasive candidal infection in ELBW infants who are at high risk of systemic fungal infection. However, concerns regarding the short- and long-term safety of antifungal prophylaxis remain unresolved.¹⁸ Data regarding the long-term outcomes of prophylactic fluconazole use are limited because of short follow-up periods and small case numbers.

Our study revealed that the use of prophylactic fluconazole for preventing invasive candidal infection in preterm infants may enhance selective pressure for other fungal growth, including *Malassezia* spp. Al-Sweih et al¹⁹ observed that the use of prophylactic fluconazole resulted in decreased fungal infection rates but increased rates of resistant *Malassezia pachydermatis*. Chen et al²⁰ also described that there was a decrease in the total fungal infection rate after fluconazole prophylaxis for VLBW neonates but the infections of fluconazole-resistant *M pachydermatis* increased. Studies of antifungal susceptibility of *Malassezia* species found that high minimum inhibitory concentrations (MICs) for azole drugs tested were

for *M furfur*. High MICs ($\geq 8 \mu\text{g/mL}$) and wide MIC ranges (≤ 0.125 to $>64 \mu\text{g/mL}$) were obtained with fluconazole, whereas ketoconazole, itraconazole, and voriconazole were the most active drugs against *Malassezia* species.²¹ Thus, the routine use of prophylactic fluconazole combined with the potential risk factors of prematurity might lead to resistant strains related to *M furfur* colonization.

Malassezia spp are lipophilic yeasts; *M furfur* is one of 14 species. They are associated with a wide spectrum of clinical manifestations ranging from benign skin conditions to invasive fungemia in immunocompromised hosts. All of our 20 neonate cases shared the same risk factors of *M furfur* colonization and infection, including prematurity, increased NICU length of stay, receipt of intralipid emulsions, central venous catheters, and administration of broad-spectrum antibiotics.^{7,22-27} According to these features of the *Malassezia* spp, we assumed that our clinical factors, SMOF rich in olive oil and LED phototherapy to preserve humidity, might be correlated with the phenomenon of *M furfur* emergence in our NICU (Figure 1). Limited studies describe the relationship between phototherapy and the incidence of *M furfur*. Further studies with longer study periods and more cases are needed.

Regarding the management of cases of *M furfur* colonization and infection, catheter-related *Malassezia* infections are usually treated with catheter removal, discontinuation of the lipid infusion, and the administration of antifungal therapy.²⁸ However, there are reports of successful eradication of infection with antifungal therapy without catheter removal and with catheter removal without systemic antifungal treatment.^{29,30} Based on our study and the literature review,²⁹ whether antifungal agents administered or not, catheter removal and discontinuation of intravenous lipids generally produce a favorable outcome in neonates with catheter-related *M furfur* colonization. For fungemia with *M furfur*, amphotericin B treatment is recommended because of the potential risk of mortality and morbidity.

The limitations of this study include its small case number and a short investigation period, which prevented further analysis of the factors contributing to the phenomenon of *M furfur* colonization, including antibiotic resistance. Moreover, selection and information bias might have been introduced by the study's retrospective nature.

In conclusion, here we observed that candidemia subsided after the routine use of prophylactic fluconazole; however, *M furfur* colonization gradually emerged. In addition to the risk of prematurity, SMOF supplementation, and broad-spectrum antibiotic use, prophylactic fluconazole may be correlated with *Malassezia* colonization. Future clinical practice studies should further investigate the incidence of fluconazole-resistant strains. Regardless of

Summary of Recommendations for Practice and Research

What we know:	<ul style="list-style-type: none"> • <i>Candida</i> is one of the major causes of mortality and morbidity in preterm infants. • Fluconazole prophylaxis in premature infants has been suggested by some experts and hospital strategies. • <i>Malassezia</i> species are associated with a wide spectrum of clinical manifestations ranging from benign skin conditions to fungemia in immunocompromised hosts.
What needs to be studied:	<ul style="list-style-type: none"> • Evaluation of the benefit and harm of the prophylactic fluconazole for preventing the invasive candidal infection. • The possible relationship between prophylactic fluconazole and emerging <i>M furfur</i> colonization.
What can we do today:	<ul style="list-style-type: none"> • The outcome of catheter-related <i>M furfur</i> colonization was favorable following removal of the catheter. • <i>M furfur</i> remains a potential concern for fungemia in the care for premature infants and thus requires our attention.

the use of antifungal treatment, the outcomes of catheter-related *M furfur* colonization were favorable after catheter removal. However, *M furfur* remains a potential concern for fungemia, which might cause mortality and morbidities in premature infants and thus requires our attention.

References

1. Stoll BJ, Hansen N, Fanaroff AA, et al. Late-onset sepsis in very low birth weight neonates: the experience of the NICHD Neonatal Research Network. *Pediatrics*. 2002;110:285-291.
2. Pappas PG, Kauffman CA, Andes DR, et al. Clinical practice guideline for the management of candidiasis: 2016 update by the Infectious Diseases Society of America. *Clin Infect Dis*. 2016;62:e1-e50.
3. Chitnis AS, Magill SS, Edwards JR, Chiller TM, Fridkin SK, Lessa FC. Trends in *Candida* central line-associated bloodstream infections among NICUs, 1999-2009. *Pediatrics*. 2012;130:e46.
4. Aliaga S, Clark RH, Laughon M, et al. Changes in the incidence of candidiasis in neonatal intensive care units. *Pediatrics*. 2014;133:236.
5. Ashbee HR, Leck AK, Puntis JW, Parsons WJ, Evans EG. Skin colonization by *Malassezia* in neonates and infants. *Infect Control Hosp Epidemiol*. 2002;23:212-216.
6. Aschner JL, Punsalang A Jr, Maniscalco WM, Menegus MA. Percutaneous central venous catheter colonization with *Malassezia furfur*: incidence and clinical significance. *Pediatrics*. 1987;80:535-539.
7. Gupta P, Chakrabarti A, Singhi S, Kumar P, Honnavar P, Rudramurthy SM. Skin colonization by *Malassezia* spp. in hospitalized neonates and infants in a tertiary care centre in North India. *Mycopathologia*. 2014;178:267-272.
8. Marcon MJ, Powell DA. Epidemiology, diagnosis, and management of *Malassezia furfur* systemic infection. *Diagn Microbiol Infect Dis*. 1987;7:161-175.
9. Gonzalez-Cuevas A, Alayeto J, Juncosa T, Garcia-Fructuoso MT, Moreno J, Latorre C. Neonatal sepsis by *Malassezia furfur*. *Rev Iberoam Micol*. 1999;16:158-160.
10. Shek YH, Tucker MC, Viciano AL, Manz HJ, Connor DH. *Malassezia furfur*—disseminated infection in premature infants. *Am J Clin Pathol*. 1989;92:595-603.
11. Mickelsen PA, Viano-Paulson MC, Stevens DA, Diaz PS. Clinical and microbiological features of infection with *Malassezia pachydermatis* in high-risk infants. *J Infect Dis*. 1988;157:1163-1168.
12. Larocco M, Dorenbaum A, Robinson A, Pickering LK. Recovery of *Malassezia pachydermatis* from eight infants in a neonatal intensive care nursery: clinical and laboratory features. *Pediatr Infect Dis J*. 1988;7:398-401.
13. Redline RW, Dahms BB. *Malassezia* pulmonary vasculitis in an infant on long-term intralipid therapy. *N Engl J Med*. 1981;305:1395-1398.
14. Ilahi A, Hadrich I, Goudjil S, et al. Molecular epidemiology of a *Malassezia pachydermatis* neonatal unit outbreak. *Med Mycol*. 2018;56:69-77.
15. Shparago NI, Bruno PP, Bennett J. Systemic *Malassezia furfur* infection in an adult receiving total parenteral nutrition. *J Am Osteopath Assoc*. 1995;95:375-377.
16. Sherbiny HS, Youssef DM, Sherbini AS, El-Beheidy R, Sherief LM. High-intensity light-emitting diode vs fluorescent tubes for intensive phototherapy in neonates. *Paediatr Int Child Health*. 2016;6:1-7.
17. Mohammadzadeh M, Eliadarani FK, Badiie Z. Is the light-emitting diode a better light source than fluorescent tube for phototherapy of neonatal jaundice in preterm infants? *Adv Biomed Res*. 2012;1:51.
18. Patel RM. Does fluconazole prophylaxis reduce death or invasive *Candida* infection in extremely preterm infants? *Acta Paediatr*. 2017;106:844-845.
19. Al-Sweih N, Ahmad S, Joseph L, Khan S, Khan Z. *Malassezia pachydermatis* fungemia in a preterm neonate resistant to fluconazole and flucytosine. *Med Mycol Case Rep*. 2014;5:9-11.
20. Chen IL, Chiu NC, Chi H, et al. Changing of bloodstream infections in a medical center neonatal intensive care unit. *J Microbiol Immunol Infect*. 2017;50:514-520.
21. Rojas FD, Sosa Mde L, Fernández MS, Cattana ME, Córdoba SB, Giusiano GE. Antifungal susceptibility of *Malassezia furfur*, *Malassezia sympodialis*, and *Malassezia globosa* to azole drugs and amphotericin B evaluated using a broth microdilution method. *Med Mycol*. 2014;52:641-646.
22. Alexander P, Alladi A, Correa M, D'Cruz AJ. Neonatal colonic mucormycosis—a tropical perspective. *J Trop Pediatr*. 2005;51:54-59.
23. Gupta AK, Kohli Y, Li A, Faergemann J, Summerbell RC. In vitro susceptibility of the seven *Malassezia* species to ketoconazole, voriconazole, itraconazole and terbinafine. *Br J Dermatol*. 2000;142:758-765.
24. Papavassilis C, Mach KK, Maysen PA. Medium-chain triglycerides inhibit growth of *Malassezia*: implications for prevention of systemic infection. *Crit Care Med*. 1999;27:1781-1786.
25. Chryssanthou E, Broberger U, Petrini B. *Malassezia pachydermatis* fungemia in a neonatal intensive care unit. *Acta Paediatr*. 2001;90:323-327.
26. Ahtonen P, Lehtonen OP, Kero P, Tunnela E, Havu V. *Malassezia furfur* colonization of neonates in an intensive care unit. *Mycoses*. 1990;33:543-547.
27. Richet HM, McNeil MM, Edwards MC, Jarvis WR. Cluster of *Malassezia furfur* pulmonary infections in infants in a neonatal intensive-care unit. *J Clin Microbiol*. 1989;27:1197-1200.
28. Surmont I, Gavilanes A, Vandepitte J, Devlieger H, Eggermont E. *Malassezia furfur* fungemia in infants receiving intravenous lipid emulsions. A rarity or just underestimated? *Eur J Pediatr*. 1989;148:435-438.
29. Morrison VA, Weisdorf DJ. The spectrum of *Malassezia* infections in the bone marrow transplant population. *Bone Marrow Transplant*. 2000;26:645-648.
30. Barber GR, Brown AE, Kiehn TE, Edwards FF, Armstrong D. Catheter-related *Malassezia furfur* fungemia in immunocompromised patients. *Am J Med*. 1993;95:365-370.