

RESEARCH ARTICLE

Evaluation of cranial tibial translation in dogs: Diagnostic accuracy of radiographic method using a simple device

Adolfo Maria Tambella^{1*}, Luca Omini², Anna Rita Attili¹, Cecilia Vullo¹, Stefano Martin¹

1 University of Camerino, School of Biosciences and Veterinary Medicine, Matelica (MC), Italy, **2** Clinica Veterinaria Omini Luca, Chiaravalle (AN), Italy

* adolfo maria.tambella@unicam.it



Abstract

A hand-made, radiolucent, custom-designed device having a mobile and a non-mobile platforms was used to objectively quantify the *in vivo* cranial tibial translation, in order to assess the functional status of cranial-cruciate-ligament (CrCL) in dogs. The hypothesis was that changes in CrCL integrity would result in detectable changes in tibial translation. To validate the diagnostic method, data from injured (PA, n = 32), contralateral (CO, n = 32) and healthy stifles (HE, n = 32) were compared. Normalized tibial translation (Δ_N) of each stifle was measured in medio-lateral radiographic projection obtained before and during standard thrust force application, in PA (43.59±12.97%), CO (20.32±6.69%) and HE (12.22±3.77%). Comparing PA with HE and CO (Δ_N cut-off value: 29.73%), diagnosis could be issued with very high probability. Comparing HE with CO (Δ_N cut-off value: 14.80%), high performance was obtained. The translator device could be a useful tool to objectively quantify the *in vivo* tibial translation in dogs with CrCL rupture, before surgery and during post-operative follow-up.

OPEN ACCESS

Citation: Tambella AM, Omini L, Attili AR, Vullo C, Martin S (2020) Evaluation of cranial tibial translation in dogs: Diagnostic accuracy of radiographic method using a simple device. PLoS ONE 15(2): e0228621. <https://doi.org/10.1371/journal.pone.0228621>

Editor: John Leicester Williams, University of Memphis, UNITED STATES

Received: April 29, 2019

Accepted: January 20, 2020

Published: February 11, 2020

Copyright: © 2020 Tambella et al. This is an open access article distributed under the terms of the [Creative Commons Attribution License](https://creativecommons.org/licenses/by/4.0/), which permits unrestricted use, distribution, and reproduction in any medium, provided the original author and source are credited.

Data Availability Statement: All relevant data are within the manuscript and its Supporting Information files.

Funding: The authors received no specific funding for this work.

Competing interests: The authors have declared that no competing interests exist.

Introduction

The major role of the cranial cruciate ligament (CrCL) to prevent cranial tibial translation is well established by scientific literature [1–4].

Physical and radiographic examination techniques are commonly used to diagnose CrCL deficiency. Clinical detection of tibial translation by cranial drawer test and tibial compression test can aid revealing stifle joint instability as a result of CrCL injury. However, diagnosis of CrCL insufficiency using these tests is subjective and difficult to quantify accurately [5,6].

In order to thoroughly assess the joint stability as well as joint stabilization after surgery, it is imperative to compare joint stability between and within subjects over time. There are several descriptions of radiographic techniques to assess translational stifle stability and CrCL integrity in dogs, but they do not include a specific joint angle or controlled force application to accomplish tibial translation [7,8]. Lopez described a radiographic technique to measure the tibial translation in intact, partially and completely ruptured CrCL [9]. Kim et al. quantified cranial tibial subluxation by means of implantation of radio-opaque markers at the femoral and tibial attachments of the CrCL [10], but this may not be practical to implement in clinical

patients. Bielecki et al. measured tibial subluxation in normal cadavers after ligament transection and during gradually increasing tibial thrust by manual flexing the hock joint [11]. Castaneda et al. used normal cadaveric canine pelvic limbs to investigate a measurement technique for assessing the degree of cranial tibial displacement, at varying degree of stifle flexion, in intact, partially and completely transected conditions while manually flexing the tarsal joint [6]. A special joint-testing machine was used *ex vivo* to evaluate radiographically and electromagnetically the passive laxity of normal canine stifle before and after cutting the CrCL, and also after surgical treatment [12]. Recently, Srisuwanporn et al. examined the accuracy of a new stress radiographic device for measuring tibial translation in diagnosing anterior cruciate ligament tear in people [13]. Plesman et al. described radiographic landmarks for measurement of cranial tibial subluxation in normal canine pelvic limb before and after transection of cranial cruciate ligament [14]. Other studies investigated potential predictive value for canine CrCL rupture from radiographic risk factors, such as the severity of synovial effusion and osteophytes [15], the status of infrapatellar fat pad [16], or the conformation factors of pelvic limb [17].

In order to assess the integrity of CrCL, this study was designed to objectively quantify the *in vivo* cranial canine stifle translation using a simple, hand-made, radiolucent translator device keeping fixed the joint angle during the thrust. The hypothesis was that changes in CrCL integrity would result in detectable changes in tibial translation. If the hypothesis is confirmed, the radiographic method using this simple instrument could be included, after validation, in the evaluation protocols of orthopaedic studies, potentially representing a concrete help for researchers and clinicians in the specific area.

Materials and methods

In this prospective study, the principles of STARD guidelines (Standards for Reporting of Diagnostic Accuracy Studies) were followed (STARD checklist in [S1 Table](#)) [18,19].

The protocol was approved by the Institutional Ethics Committee for the protection of animals used for experimental or other scientific purposes of the University of Camerino in accordance with Good Scientific Practice guidelines and national legislation (Approval No. 122014).

Inclusion criteria

The study took place at the Veterinary Teaching Hospital, School of Biosciences and Veterinary Medicine, University of Camerino between May 2017 and December 2018.

Adult dogs of all breeds and gender, weighing more than 15 kg were included in the study.

All the animals had to be assigned to American Society of Anesthesiologists (ASA) categories I or II on the basis of a thorough physical and hematological evaluation. Exclusion criteria were animals in ASA categories III to V, pregnant or lactating bitches, and presence of other orthopedic problems beyond the complete CrCL rupture.

For each dog enrolled in the study, informed owner consent was obtained.

Test groups

Three groups of stifles were included in the study to validate the diagnostic method: canine stifles with intact CrCL (healthy, Group HE); canine stifles with naturally occurring, unilateral, complete CrCL rupture (pathological, Group PA); contralateral stifles of affected dogs (contralateral, Group CO). Group PA had to show clinical signs related to the CrCL rupture, positive drawer sign both in extension and flexion, and positive cranial tibial thrust tests, with no radiographic signs of degenerative joint disease (DJD) or with a degree of DJD not exceeding the mild level [20]; Groups HE and CO did not have to show clinical signs or positive tests. Group

PA had the diagnosis of CrCL rupture confirmed subsequently by inspection of the ligament at arthrotomy during a therapeutic surgical procedure. Group HE consisted of a consecutive series of healthy dog anaesthetized for reason other than for investigation of stifle lameness; they were with no sign of stifle abnormality, as evaluated by normal physical examination and confirmed by orthopaedic and radiographic examinations.

Anaesthesia procedure

Food but not water was withheld for 10 hours before anaesthesia. Following determination of baseline data, a catheter was aseptically placed into a cephalic vein and dogs were premedicated with an endovenous (IV) injection of 3 µg/kg dexmedetomidine (Dexdomitor; Orion Pharma, Italy) and 0.2 mg/kg methadone (Semfortan; Dechra, Italy) mixed in the same syringe. Ten minutes after the premedication, anaesthesia was induced with IV propofol (Propovet; Vetfol, Italy) to effect before intubation. The dogs were connected to a small animal rebreathing circuit and anaesthesia was maintained with isoflurane (Isoflo; Zoetis, Italy) in 100% oxygen.

After performing the radiographic study, anaesthesia was extended for surgery using isoflurane. Immediately before surgery 1.0 mg/kg of tramadol (Altadol; Formevet, Italy), diluted in distilled water to a final volume of 0.22 ml/kg, was administered epidurally at the lumbo-sacral space. During surgery the dogs received a loading dose of 2 mg/kg lidocaine (Lidocaine 2%; Ati, Italy) followed by a constant rate infusion of 100 µg/kg/minute administered throughout anaesthesia and surgery.

Evaluation procedure

A handmade, radiolucent, custom-designed device having a mobile and a non-mobile platforms was used in each dog to objectively quantify the *in vivo* cranial tibial translation, keeping 135° of joint angle, which is typically considered as the average standing angle of the canine stifle [21–23] and as performed by Lopez and collaborators [9].

Dogs under general anaesthesia were positioned in lateral recumbence with the hind limb on the translator device: femur was allocated on the immobile platform while tibia was secured to the mobile platform with polystyrene blocks in the respective housings (Fig 1A).

A force was manually applied to the tibial platform in caudal direction to limit the risk of spontaneous cranial positioning of the tibia at rest, obtaining a zero point for the translation measurement.

Medio-lateral radiographic projections were obtained in each stifle, before and during standard force application (49 N, horizontal plane, cranial direction) to the mobile tibial platform, in order to thrust the tibia cranially. The central radiographic beam was consistently centered on each stifle.

The standard force of 49 N used in this study was the result of the sum of the force already used by Lopez and collaborators (44.5 N) [9] and the average static sliding friction of the mobile tibial platform on the radiologic table surface (4.5 N) previously measured in two dogs weighing 15 and 45 kg. The force was measured using a digital dynamometer (mini crane scale) and it was applied and maintained during the execution of the radiographs by using a weight corresponding to the force required to perform the test.

The cranial tibial translation was measured digitally on each radiographic image (Fujifilm, FCR-Capsula-V-View). Two vertical, parallel lines were drawn perpendicularly to the vector force and tangent to the apex of tibial crest or the caudal edge of femoral condyles respectively. The distance between these two lines was measured in mm before (D_1 in Fig 1B) and during force application (D_2 in Fig 1C).

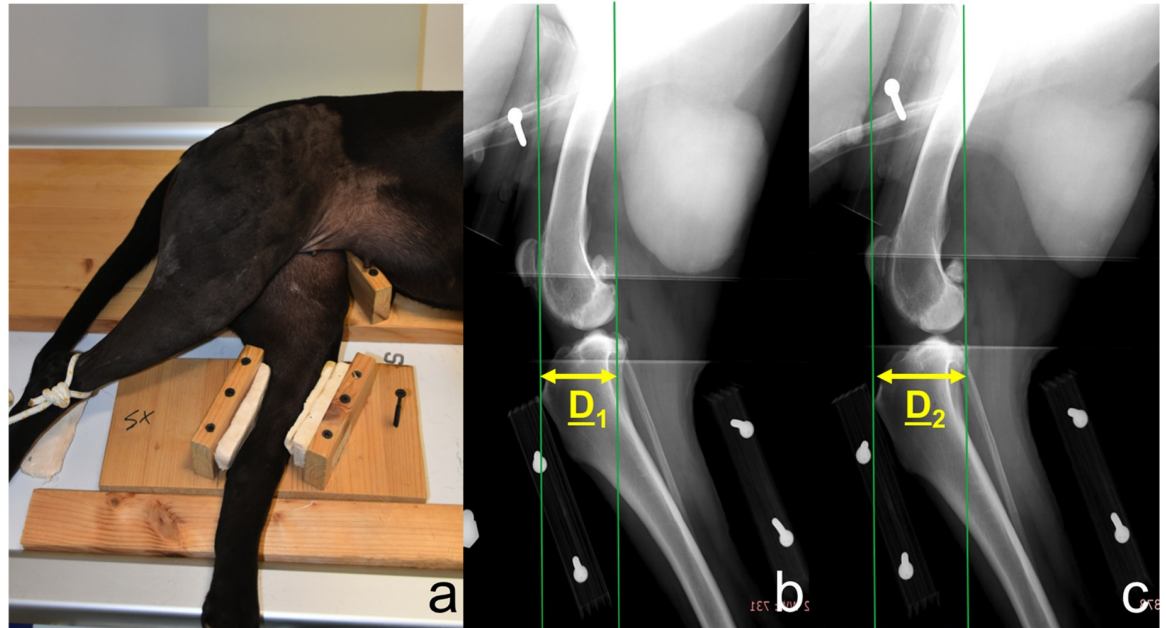


Fig 1. Positioning of dog on the translator device during the test (a); medio-lateral radiographic projections of the stifle using the translator device before (b) and during standard force application (c) in order to thrust the tibia cranially. Green vertical lines represent reference lines for measurements. Yellow arrows indicate the distance between reference lines before (D_1) and during force application (D_2).

<https://doi.org/10.1371/journal.pone.0228621.g001>

The difference between D_2 and D_1 expressed the absolute tibial translation (Δ_S) [$\Delta_S = D_2 - D_1$]. Δ_S was normalized to obtain data regardless of dog's size. Tibial width (TW) was measured in mm in medio-lateral projection on the distal portion of the tibial crest, perpendicularly to the long axis of the tibia. Normalized tibial translation (Δ_N) was obtained as relative percentage of TW [$\Delta_N = \Delta_S / TW \times 100$] as performed in other studies [9,24,25].

Two operators, who did not come into contact with dogs and were unaware of the clinical condition of the single stifle, blindly performed radiographic measurements.

Once all radiographic measurements have been completed, the blind was opened and cut-off values were identified, obtaining boundary thresholds between positive and negative results.

Outcome parameters of diagnostic accuracy and statistical analysis

To identify the Δ_N cut-off between PA and clinically healthy stifles, the sensitivity was privileged identifying all the pathologic stifles avoiding false negatives. The Δ_N cut-off between HE and CO groups was identified giving equal weights to sensitivity and specificity, obtaining the cut-off using receiver-operating characteristic (ROC) methodology.

To carry out a validation of the translator device, as unit of analysis the single stifle was considered. Data from the three groups were compared calculating sensitivity, specificity, positive and negative predictive values, accuracy and ROC analysis with measurement of area under the ROC curve (AUC).

In order to evaluate thresholds and predictivity of Δ_N on groups, generalized linear mixed models (GLMM), with binomial distribution family and logit link, were used. In the GLMMs the "group" was used as fixed factor in order to explicitly quantify its effect, and "ID of the

dog” was used as random factor, so addressing variability of stifles in the same dog and taking into account dependence of data. Predictions of the GLMMs were used to build ROC curves.

Specificity and sensitivity was used to evaluate the ability of the procedure to correctly identify pathological and healthy joints respectively; positive and negative predictive values were used to assess the probability to have a correct evaluation for a pathological and a healthy joint; accuracy was used to assess the proportion of observations classified correctly by the diagnostic procedure; AUC was used to summarize the overall performance of the diagnostic procedure.

In order to quantify the differences of Δ_N on the three groups, a linear mixed model (LMM) was fitted considering “group” and “DJD” as fixed factors and the “ID of the dog” as random factor to correct the statistical model taking into account the dependence of data. Post-hoc multiple comparisons of means were performed with Tukey contrasts test.

Potential within-dog association between joint instability (Δ_N values) and time since CrCL rupture (chronicity) or the presence of DJD, were evaluated with a linear model with “time in weeks” and “DJD” as predictors, together with their interaction. Significance of variables was obtained with family-wise confidence interval estimation.

A difference with a P -value ≤ 0.05 was considered statistically significant. R project for statistical computing, version 3.6.2, was used.

Results

A total of 96 stifles were included in this study (32 in Group PA, 32 in Group CO, 32 in Group HE) (Fig 2).

Population with unilateral CrCL rupture (Groups PA and CO) consisted of 17 males and 15 females; the mean age was 5.75 ± 2.02 years (range 2–11, median 5.5); the mean weight was 35.69 ± 11.59 Kg (range 15–57, median 36.5); the frequency of canine breeds represented in Groups PA and CO was: German shepherd and Rottweiler, 18.7% for each breed; Mix-breed, 15.6%; English bulldog, Épagneul breton, Labrador retriever and Pitbull, 6.2% for each breed; Alaskan malamute, Bullmastiff, Dogo canario, Golden retriever, Italian corso, Maremma shepherd and Leonberger, 3.1% for each breed.

Population of Group HE consisted of 8 males and 8 females; the mean age was 5.31 ± 2.27 years (range 2–10, median 4.5); the mean weight was 31.44 ± 10.56 Kg (range 16–51, median 29.0); the frequency of canine breeds represented in Group HE was: Mix-breed, 18.7%; Labrador retriever, Maremma shepherd and German shepherd, 12.5% for each breed; Boxer, Doberman, English bulldog, Épagneul breton, Italian hound, Pitbull and Rottweiler, 6.2% for each breed.

The predictivity of Δ_N values resulted: highly significant on Group PA *versus* Group HE; statistically significant on Group PA *versus* Group CO; at the limit of statistical significance on Group HE *versus* Group CO (Table 1).

The general results of the linear mixed model fitted to quantify differences of Δ_N on the three groups are summarized in the Table 2.

Significant differences between groups were observed in the LMM comparing Δ_N values ($R^2 = 84.67\%$, $P < 0.000$). A large discrepancy in Δ_N values between HE ($12.22 \pm 3.77\%$, range 5.90–19.00, median 11.12) and PA ($43.59 \pm 12.97\%$, range 29.73–66.67, median 38.16) was observed ($P < 0.000$). The Δ_N values of CO ($20.32 \pm 6.69\%$, range 8.57–35.00, median 21.52) showed middle level between HE and PA stifles, while presenting statistical difference with both groups ($P = 0.000125$ and $P < 0.000$ with HE and PA respectively).

In Group PA, 12 stifles did not show radiographic signs of DJD and 20 stifles showed mild degree of DJD; the average time since CrCL rupture (chronicity) was 6.31 ± 3.58 weeks (range 2–16, median 6). The within-dog analysis of the association between joint instability (Δ_N

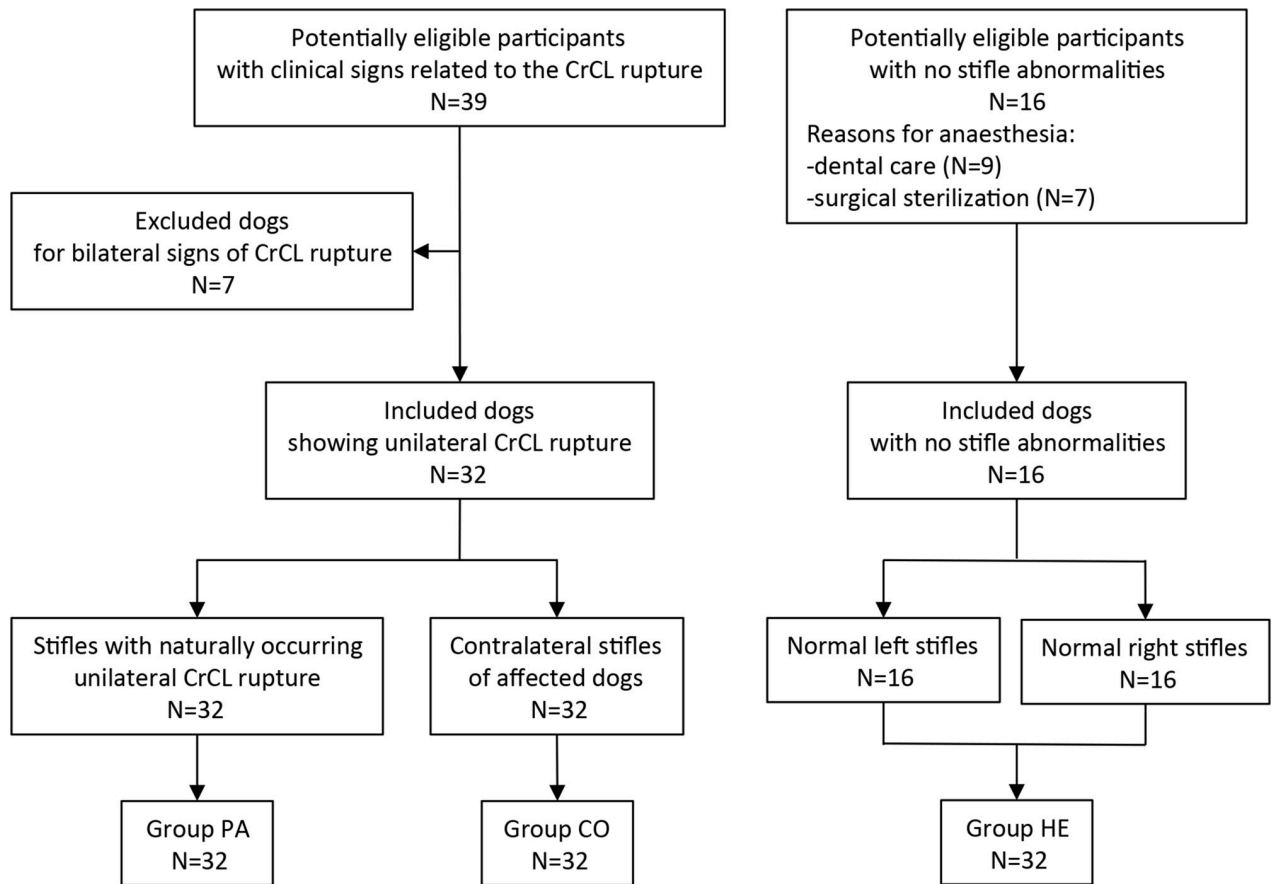


Fig 2. Flow of participants: STARD diagram.

<https://doi.org/10.1371/journal.pone.0228621.g002>

values) and chronicity or presence of DJD shows that chronicity has relatively low significance in joint instability ($P = 0.0691$), and the biggest impact is from DJD ($P < 0.001$). However, since the interaction is significant, chronicity effect is also relevant due to its combined effect with DJD ($P = 0.0372$) (Table 3).

The Δ_N cut-off value between PA and clinically healthy stifles resulted to be 29.73%. The Δ_N cut-off value between HE and CO stifles resulted to be 14.80% (Fig 3).

The results of the Δ_N measured in Groups PA, CO and HE are summarized in the box-plot graph (Fig 4).

Table 1. Summary of the generalized linear mixed model (GLMM) assessing the predictivity of Δ_N values considering the “group” as fixed factor and the “ID of the dog” as random factor.

Groups	Variable	Estimate	Standard Error	P-value
PA vs HE	Intercept	-47.63	0.005319	<2e-16
	Δ_N	1.873563	0.005313	<2e-16
PA vs CO	Intercept	-15.6694	4.8733	0.00130
	Δ_N	0.5249	0.1602	0.00105
CO vs HE	Intercept	-29.006	14.685	0.0482
	Δ_N	2.103	1.081	0.0516

Δ_N : normalized tibial translation; PA: pathological stifles; CO: contralateral stifles; HE: healthy stifles.

<https://doi.org/10.1371/journal.pone.0228621.t001>

Table 2. General summary of the linear mixed model (LMM) considering the “group” and the “presence of DJD” as fixed factor and the “ID of the dog” as random factor.

Variable	Estimate	Standard Error	P-value
Intercept	12.220	1.466	9.95e-11
Group CO	7.951	1.960	0.000143
Group PA	40.824	2.523	2.e-16
DJD	-15.355	2.537	3.90e-08

PA: pathological stifles; CO: contralateral stifles; HE: healthy stifles; DJD: degenerative joint disease.

<https://doi.org/10.1371/journal.pone.0228621.t002>

The results of the diagnostic validation of the translator device are summarized in [Table 4](#).

No adverse events were recorded during or after the use of the translator device in radiographic evaluations. The entire radiographic procedure, including the premedication and preparation of dogs and the acquisition of radiographs in both stifles, was always completed within 30 minutes.

Discussion

A validation assessment of the diagnostic method was performed to assess potential use in clinical trials.

With the systematic application of this procedure, using the achieved cut-off, a diagnosis of CrCL rupture could be issued with very high probability being certainly possible to discriminate (Accuracy and AUC) a healthy joint (Specificity) and an affected joint (Sensitivity) being all parameters at maximum levels.

Although both groups of stifles were considered not pathological, comparing HE with CO it was possible to obtain significant levels of sensitivity, specificity, positive and negative predictive values and accuracy, as also shown the high level of accuracy evidenced by the AUC method.

Measurements of Δ_N allowed to differentiate HE from PA and to accept the hypothesis that changes in CrCL integrity resulted in detectable changes on tibial translation.

In addition, a significant difference of Δ_N between CO and HE stifles was showed. The laxity of the CO stifles could be related to the high frequency of CrCL rupture in the contralateral stifles of unilaterally affected dogs [15–17,26,27].

The first cut-off value (29.73%) allowed identifying all stifles affected by CrCL rupture, maximizing the sensitivity at a slight expense of specificity. Few contralateral stifles exceeded this cut-off value; they did not show clinical cranial translation but showed a high Δ_N (false positives). In Group CO stifles, although showing higher radiographic translation than Group HE stifles, clinicians had the inability to palpate a cranial drawer sign. One potential reason for this finding is that the force applied manually by a clinician may not suffice to generate a cranial tibial displacement sufficient for clinical detection, as supposed by other author [28]. It

Table 3. General summary of the linear model to assess potential within-dog association between joint instability and time since CrCL rupture (chronicity) or the presence of DJD.

Variable	Estimate	Standard Error	P-value
Time	-5.113	2.369	0.0691
DJD	-40.165	9.940	<0.001
Time-DJD	6.078	2.478	0.0372

Time: time in weeks since CrCL rupture; DJD: degenerative joint disease; Time-DJD: interaction Time and DJD.

<https://doi.org/10.1371/journal.pone.0228621.t003>

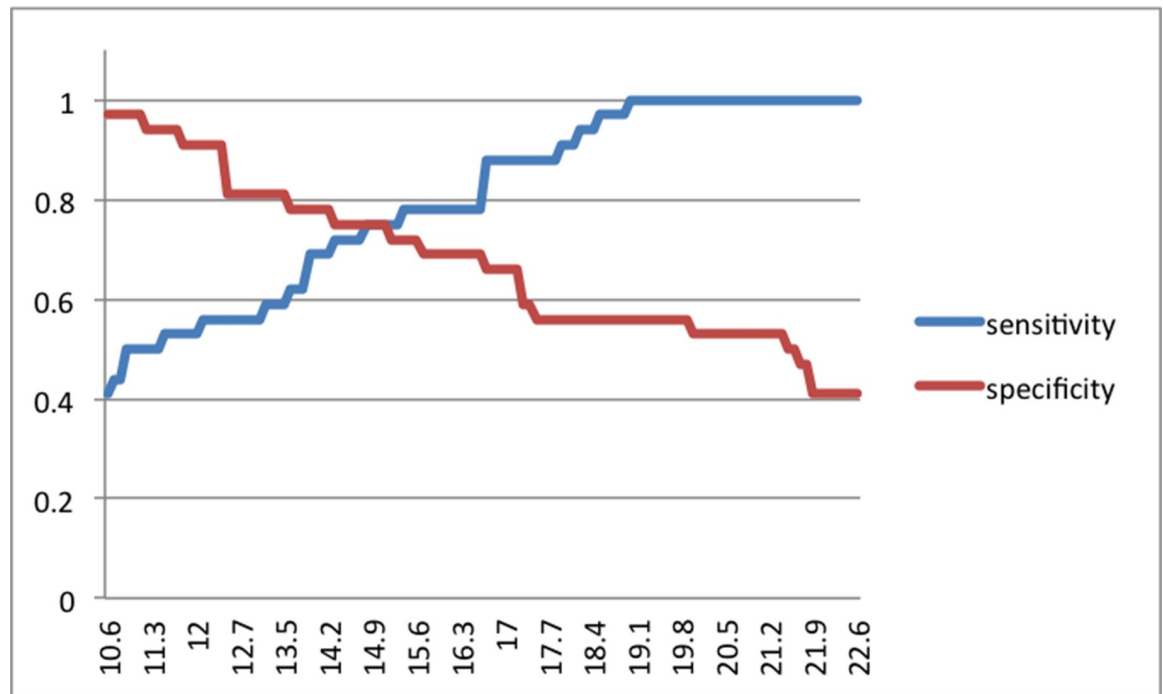


Fig 3. Two-graph ROC curve of the diagnostic sensitivity and specificity as a function of the test result (normalized tibial translation, Δ_N , %) showing the Δ_N optimal cut-off between HE and CO groups.

<https://doi.org/10.1371/journal.pone.0228621.g003>

therefore appears conceivable that, in our study, the absence of cranial drawer sign in Group CO reflected insufficient loading and lack of sensitivity of the cranial drawer test compared to the objective data generated during radiographic method testing. It could be hypothesized that the measured radiographic instability may be considered a potential high risk factor for CrCL rupture.

The second cut-off (14.80%), adopted getting a compromise between sensitivity and specificity, allowed the identification of stifles with low Δ_N and with low potential predisposition to CrCL rupture.

A potential limitation of the study is that affected stifles (Group PA) were confirmed by direct inspection of the damaged CrCL at arthrotomy during therapeutic surgery. Contralateral and healthy stifles (Groups CO and HE) were considered normal on the basis of clinical and radiographic examinations. However, because Groups CO and HE did not undergo CrCL inspection for ethical reasons, there is a possibility of false negatives or partial CrCL tears in these groups, and this could be considered a potential source of bias, which could potentially influence the analysis of diagnostic accuracy of this radiographic method.

A number of *ex vivo* biomechanical studies assessed the ability of several surgical techniques to control joint stability after cruciate ligament rupture [25,28,29]. This suggests that the evaluation of the degree of joint stability could be considered of crucial importance in clinical cases.

The translator device could be considered a simple, easy-to-use, inexpensive and useful tool to objectively quantify the *in vivo* cranial tibial translation in dogs with CrCL rupture. The procedure could be used in veterinary clinical practice to evaluate canine stifle stability; nevertheless, it could be particularly useful in clinical trials by including it among objective evaluation protocols to be used before/after surgery and during post-operative follow-up. It could be used in clinical trials evaluating intra-articular or extra-articular stabilization techniques.

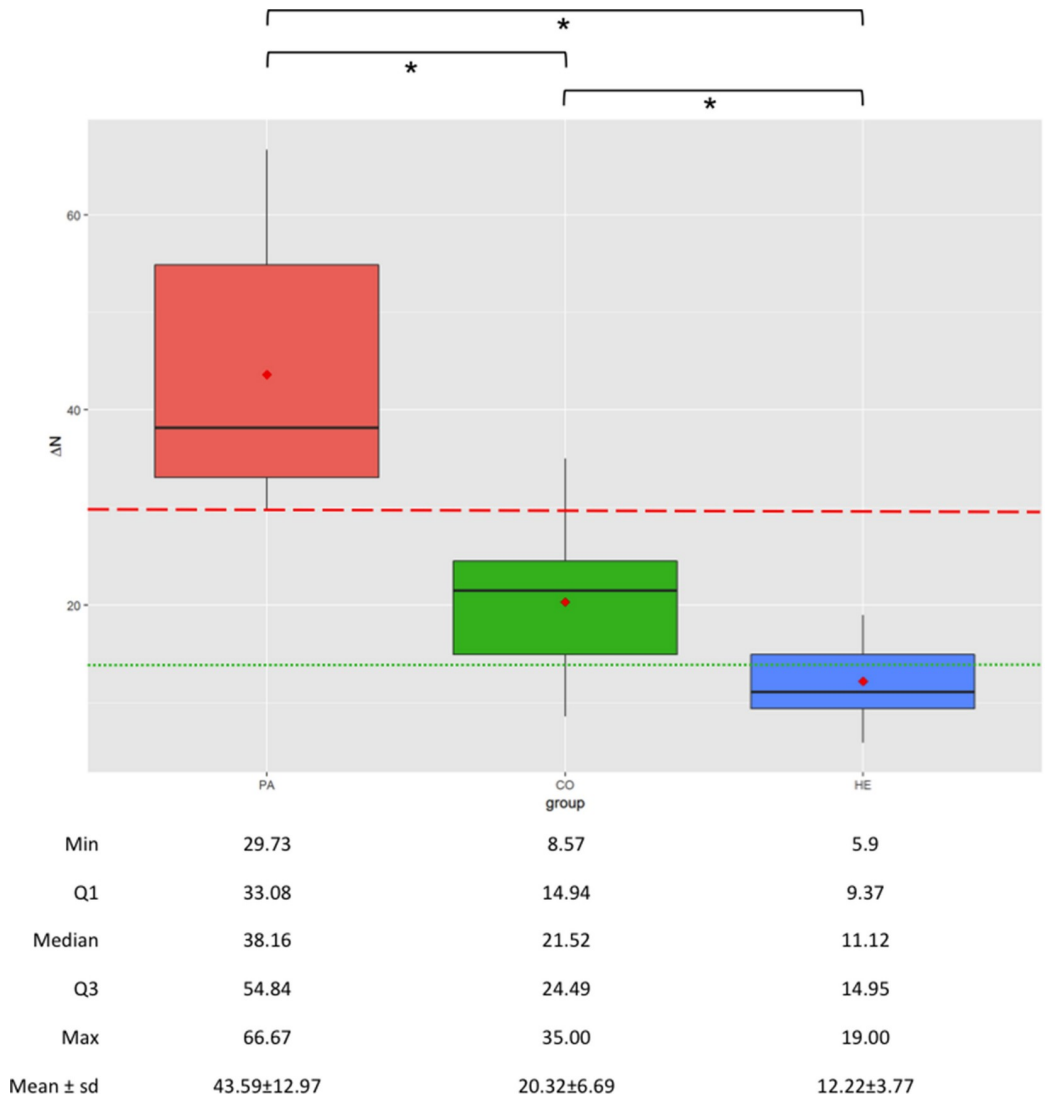


Fig 4. Boxplots showing the normalized tibial translation (Δ_N , %) in groups PA (pathological, canine stifles with naturally occurring uni-lateral CrCL rupture), CO (contralateral stifles of affected dogs) and HE (healthy, canine stifles with intact CrCL); the ends of the whiskers show minimum (Min) and maximum (Max) values of Δ_N ; boxes show the median, the first and the third quartile (Q1 and Q3 respectively); red dots show the mean; dashed red line represents Δ_N cut-off between PA and clinically healthy stifles; dotted green line represents Δ_N cut-off between HE and CO groups; * indicates statistically significant differences.

<https://doi.org/10.1371/journal.pone.0228621.g004>

Although it has not been investigated in this study, the procedure may be apparently less indicated for tibial osteotomy techniques (e.g. TPLO, TTA), as they purportedly tend to restore dynamically the biomechanics of the joint [12,30,31]. However, the still not clear scientific knowledge and the growing development of research in this field [12,29–33] could warrant further studies using the device even before/after osteotomy techniques.

Further long-term follow-up retrospective study will be necessary to confirm the hypothesized predictive value for CrCL rupture in dogs.

Table 4. Validity assessment of the translator device.

Groups under comparison	PA vs HE	PA vs CO	CO vs HE
Prob. thresholds	0.499876	0.411041	0.4984901
SE	1.0 (0.999, 1)	0.9375 (0.816, 0.992)	1.0 (0.905, 1)
SP	1.0 (0.999, 1)	1.0 (0.991, 1)	1.0 (0.910, 1)
PPV	1.0 (0.999, 1)	1.0 (0.986, 1)	1.0 (0.985, 1)
NPV	1.0 (0.999, 1)	0.9412 (0.809, 0.957)	1.0 (0.985, 1)
ACC	1.0 (0.999, 1.0)	0.9688 (0.892, 0.996)	1.0 (0.944, 1.0)
AUC	100 (100, 100)	94.77 (86.41, 96.88)	100 (100, 100)
ROC curves	S1 Fig	S2 Fig	S3 Fig

Δ_N : normalized tibial translation; Prob.: probability; PA: pathological stifles; CO: contralateral stifles; HE: healthy stifles; vs: *versus*; SE: sensitivity; SP: specificity; PPV: positive predictive value; NPV: negative predictive value; ACC: accuracy; AUC: area under the ROC (receiver-operating characteristic) curve; in brackets: 95% confidence interval.

<https://doi.org/10.1371/journal.pone.0228621.t004>

Supporting information

S1 Table. STARD checklist.

(PDF)

S1 Fig. ROC curve of normalized tibial translation (Δ_N) considering Group PA (pathological stifles) and Group HE (healthy stifles).

(PDF)

S2 Fig. ROC curve of normalized tibial translation (Δ_N) considering Group PA (pathological stifles) and Group CO (contralateral stifles).

(PDF)

S3 Fig. ROC curve of normalized tibial translation (Δ_N) considering Group CO (contralateral stifles) and Group HE (healthy stifles).

(PDF)

Acknowledgments

The authors thank Mr. Filippo Vannucci for the manufacture of the custom-designed device.

Author Contributions

Conceptualization: Adolfo Maria Tambella, Luca Omini.

Data curation: Adolfo Maria Tambella, Anna Rita Attili, Stefano Martin.

Formal analysis: Adolfo Maria Tambella, Anna Rita Attili.

Investigation: Adolfo Maria Tambella, Luca Omini, Stefano Martin.

Methodology: Adolfo Maria Tambella, Stefano Martin.

Project administration: Adolfo Maria Tambella.

Resources: Adolfo Maria Tambella, Luca Omini.

Software: Adolfo Maria Tambella.

Supervision: Anna Rita Attili, Cecilia Vullo.

Validation: Adolfo Maria Tambella, Luca Omini, Anna Rita Attili, Cecilia Vullo, Stefano Martin.

Visualization: Adolfo Maria Tambella, Stefano Martin.

Writing – original draft: Adolfo Maria Tambella, Luca Omini, Anna Rita Attili, Cecilia Vullo, Stefano Martin.

Writing – review & editing: Adolfo Maria Tambella, Luca Omini, Anna Rita Attili, Cecilia Vullo, Stefano Martin.

References

1. Moore KW, Read RA. Rupture of the cranial cruciate ligament in dogs. *Compend Contin Educat Pract Vet.* 1996; 18(3): 223–233.
2. Xerogeanes JW, Fox RJ, Takeda Y, Kim HS, Ishibashi Y, Carlin GJ, et al. A functional comparison of animal anterior cruciate ligament models to the human anterior cruciate ligament. *Ann Biomed Eng.* 1998; 26(3): 345–352. <https://doi.org/10.1114/1.91> PMID: 9570217
3. Korvick DL, Pijanowski GJ, Schaeffer DJ. Three-dimensional kinematics of the intact and cranial cruciate ligament-deficient stifle of dogs. *J Biomech.* 1994; 27(1): 77–87. [https://doi.org/10.1016/0021-9290\(94\)90034-5](https://doi.org/10.1016/0021-9290(94)90034-5) PMID: 8106538
4. Tinga S, Kim SE, Banks SA, Jones SC, Park BH, Pozzi A, et al. Femorotibial kinematics in dogs with cranial cruciate ligament insufficiency: a three-dimensional in-vivo fluoroscopic analysis during walking. *BMC Vet Res.* 2018; 14(1): 85. <https://doi.org/10.1186/s12917-018-1395-2> PMID: 29530093
5. Carobbi B, Ness MG. Preliminary study evaluating tests used to diagnose canine cranial cruciate ligament failure. *J Small Anim Pract.* 2009; 50(5): 224–226. <https://doi.org/10.1111/j.1748-5827.2008.00723.x> PMID: 19425171
6. Castaneda KA, Hudson CC, Beale BS. Ex vivo preliminary investigation of radiographic quantitative assessment of cranial tibial displacement at varying degrees of canine stifle flexion with or without an intact cranial cruciate ligament. *BMC Vet Res.* 2018; 14(1): 270. <https://doi.org/10.1186/s12917-018-1599-5> PMID: 30176906
7. De Rooster H, Van Ryssen B, Van Bree H. Diagnosis of cranial cruciate ligament injury in dogs by tibial compression radiography. *Vet Rec.* 1998; 142(14): 366–368. <https://doi.org/10.1136/vr.142.14.366> PMID: 9587199
8. De Rooster H, Van Bree H. Radiographic measurement of craniocaudal instability in stifle joints of clinically normal dogs and dogs with injury of a cranial cruciate ligament. *Am J Vet Res.* 1999; 60(12): 1567–1570. PMID: 10622170
9. Lopez MJ, Hagquist W, Jeffrey SL, Gilbertson S, Markel MD. Instrumented measurement of in vivo anterior-posterior translation in the canine knee to assess anterior cruciate integrity. *J Orthop Res.* 2004; 22(5): 949–954. <https://doi.org/10.1016/j.orthres.2003.10.017> PMID: 15304264
10. Kim SE, Lewis DD, Pozzi A, Seibert RL, Winter MD. Radiographic quantitative assessment of cranial tibial subluxation before and after tibial plateau leveling osteotomy in dogs. *Am J Vet Res.* 2011; 72(3): 410–416. <https://doi.org/10.2460/ajvr.72.3.410> PMID: 21355746
11. Bielecki MJ, Schwandt CS, Scharvogel S. Effect of tibial subluxation on the measurements for tibial tuberosity advancement in dogs with cranial cruciate ligament deficiency. *Vet Comp Orthop Traumatol* 2014; 27: 470–477. <https://doi.org/10.3415/VCOT-14-02-0018> PMID: 25327754
12. Ober CA, Factor G, Meiner Y, Segev G, Shipov A, Milgram J. Influence of tibial plateau leveling osteotomy and tibial tuberosity advancement on passive laxity of the cranial cruciate deficient stifle in dogs. *Vet Surg.* 2019; 48(3): 401–407. <https://doi.org/10.1111/vsu.13177> PMID: 30773653
13. Srisuwanporn P, Wachiratarapadorn S, Panyasakulwong R, Thuntong B, Cheechareern S, Precha W. Accuracy of a new stress radiographic device in diagnosing anterior cruciate ligament tear. *J Med Assoc Thai.* 2016; 99(4): 394–399. PMID: 27396223
14. Plesman R, Sharma A, Gilbert P, Campbell J, Johnson JD, Shmon C, et al. Radiographic landmarks for measurement of cranial tibial subluxation in the canine cruciate ligament deficient stifle. *Vet Comp Orthop Traumatol.* 2012; 25(6): 478–487. <https://doi.org/10.3415/VCOT-12-02-0017> PMID: 22828667
15. Chuang C, Ramaker MA, Kaur S, Csomos RA, Kroner KT, Bleedom JA, et al. Radiographic risk for contralateral rupture in dogs with unilateral cranial cruciate ligament rupture. *PLoS One.* 2014; 9(9): e106389. <https://doi.org/10.1371/journal.pone.0106389> PMID: 25254499

16. Fuller MC, Hayashi K, Bruecker KA, Holsworth IG, Sutton JS, Kass PH, et al. Evaluation of the radiographic infrapatellar fat pad sign of the contralateral stifle joint as a risk factor for subsequent contralateral cranial cruciate ligament rupture in dogs with unilateral rupture: 96 cases (2006–2007). *J Am Vet Med Assoc*. 2014; 244(3): 328–338. <https://doi.org/10.2460/javma.244.3.328> PMID: 24432965
17. Griffon DJ, Cunningham D, Gordon-Evans WJ, Tanaka R, Brueker KA, Boudrieau RJ. Evaluation of a scoring system based on conformation factors to predict cranial cruciate ligament disease in Labrador Retrievers. *Vet Surg*. 2017; 46(2): 206–212. <https://doi.org/10.1111/vsu.12593> PMID: 28029702
18. Bossuyt PM, Reitsma JB, Bruns DE, Gatsonis CA, Glasziou PP, Irwig L, et al. STARD 2015: an updated list of essential items for reporting diagnostic accuracy studies. *BMJ*. 2015; 351: h5527. <https://doi.org/10.1136/bmj.h5527> PMID: 26511519
19. Cohen JF, Korevaar DA, Altman D, Bruns DE, Gatsonis CA, Hooft L, et al. STARD 2015 guidelines for reporting diagnostic accuracy studies: explanation and elaboration. *BMJ Open*. 2016; 6(11): e012799. <https://doi.org/10.1136/bmjopen-2016-012799> PMID: 28137831
20. Wessely M, Brühshwein A, Schnabl-Feichter E. Evaluation of intra- and inter-observer measurement variability of a radiographic stifle osteoarthritis scoring system in dogs. *Vet Comp Orthop Traumatol*. 2017; 30(6): 377–384. <https://doi.org/10.3415/VCOOT-16-09-0134> PMID: 29202499
21. Fitch RB, Montgomery RD, Milton JL, Garrett PD, Kincaid SA, Wright JC, et al. The intercondylar fossa of the normal canine stifle: an anatomic and radiographic study. *Vet Surg*. 1995; 24(2): 148–155. <https://doi.org/10.1111/j.1532-950x.1995.tb01309.x> PMID: 7778254
22. Griffon DJ. A review of the pathogenesis of canine cranial cruciate ligament disease as a basis for future preventive strategies. *Vet Surg*. 2010; 39(4): 399–409. <https://doi.org/10.1111/j.1532-950X.2010.00654.x> PMID: 20345536
23. Thieman KM, Pozzi A, Ling HY, Lewis D. Comparison of contact mechanics of three meniscal repair techniques and partial meniscectomy in cadaveric dog stifles. *Vet Surg*. 2010; 39(3): 355–362. <https://doi.org/10.1111/j.1532-950X.2010.00661.x> PMID: 20345534
24. Snow LA, White R, Gustafson S, Xie L, Hosgood G, Monroe WT, et al. Ex vivo comparison of three surgical techniques to stabilize canine cranial cruciate ligament deficient stifles. *Vet Surg*. 2010; 39(2): 195–207. <https://doi.org/10.1111/j.1532-950X.2009.00635.x> PMID: 20210967
25. Ho-Eckart LK, Seki M, Luizza LM, Kearney MT, Lopez MJ. Joint stability after canine cranial cruciate ligament graft reconstruction varies among femoral fixation sites. *Vet Surg*. 2017; 46(2): 213–225. <https://doi.org/10.1111/vsu.12609> PMID: 28075493
26. Muir P, Schwartz Z, Malek S, Kreines A, Cabrera SY, Buote NJ, et al. Contralateral Cruciate Survival in Dogs with Unilateral Non-Contact Cranial Cruciate Ligament Rupture. *PLoS One*. 2011; 6(19): e25331. <https://doi.org/10.1371/journal.pone.0025331> PMID: 21998650
27. Sample SJ, Racette MA, Hans EC, Volstad NJ, Holzman G, Bleedorn JA, et al. Radiographic and magnetic resonance imaging predicts severity of cruciate ligament fiber damage and synovitis in dogs with cranial cruciate ligament rupture. *PLoS One*. 2017; 12(6): e0178086. <https://doi.org/10.1371/journal.pone.0178086> PMID: 28575001
28. Biskup JJ, Balogh DG, Scott RM, Conzemius MG. Long-term outcome of an intra-articular allograft technique for treatment of spontaneous cranial cruciate ligament rupture in the dog. *Vet Surg*. 2017; 46(5): 691–699. <https://doi.org/10.1111/vsu.12653> PMID: 28370152
29. Johnson K, Lanz O, Elder S, McLaughlin R, Were S, Harper T. The effect of stifle angle on cranial tibial translation following tibial plateau leveling osteotomy: An in vitro experimental analysis. *Can Vet J* 2011; 52(9): 961–966. PMID: 22379194
30. Beer P, Bockstahler B, Schnabl-Feichter E. Tibial plateau leveling osteotomy and tibial tuberosity advancement—a systematic review. *Tierarztl Prax Ausg K Kleintier Heimtier*. 2018; 46(4): 223–235. <https://doi.org/10.15654/TPK-170486> PMID: 30149404
31. Cook JL, Luther JK, Beetem J, Karnes J, Cook CR. Clinical comparison of a novel extracapsular stabilization procedure and tibial plateau leveling osteotomy for treatment of cranial cruciate ligament deficiency in dogs. *Vet Surg*. 2010; 39(3): 315–323. <https://doi.org/10.1111/j.1532-950X.2010.00658.x> PMID: 20345535
32. Shahar R, Milgram J. Biomechanics of tibial plateau leveling of the canine cruciate-deficient stifle joint: a theoretical model. *Vet Surg*. 2006; 35(2): 144–149. <https://doi.org/10.1111/j.1532-950X.2006.00125.x> PMID: 16472294
33. Rey J, Fischer MS, Böttcher P. Sagittal joint instability in the cranial cruciate ligament insufficient canine stifle. Caudal slippage of the femur and not cranial tibial subluxation. *Tierarztl Prax Ausg K Kleintier Heimtier*. 2014; 42(3): 151–156. <https://doi.org/10.1055/s00381623760>