



Histoplasmosis: An Emerging or Neglected Disease in Bangladesh? A Systematic Review

Muhammad Abdur Rahim^{1*}, Shahana Zaman², Mohammad Robed Amin³, Khwaja Nazim Uddin⁴ and MA Jalil Chowdhury⁵

¹Department of Nephrology, Bangladesh Institute of Research and Rehabilitation in Diabetes, Endocrine and Metabolic Disorders General Hospital, Dhaka, Bangladesh

²Department of Cardiology, National Institute of Cardiovascular Diseases, Dhaka, Bangladesh

³Department of Medicine, Dhaka Medical College and Hospital, Dhaka, Bangladesh

⁴Department of Internal Medicine, Bangladesh Institute of Research and Rehabilitation in Diabetes, Endocrine and Metabolic Disorders General Hospital, Dhaka, Bangladesh

⁵Department of Medicine, Bangabandhu Sheikh Mujib Medical University, Dhaka, Bangladesh

ARTICLE INFO

Article history:

Received: 16 June 2018

Accepted: 22 September 2018

Online:

DOI 10.5001/omj.2020.09

Keywords:

Bangladesh; Histoplasmosis; *Histoplasma capsulatum*.

ABSTRACT

Histoplasmosis is uncommon in many parts of the world, including Bangladesh, where, in recent years, cases are increasingly reported. We sought to describe the sociodemographic characteristics, clinical presentation, investigations, treatment, and outcome of histoplasmosis in Bangladesh. We conducted a retrospective data review of published literature from 1962 to 2017, containing information on histoplasmosis in and/or from Bangladesh. Unpublished, well-documented histoplasmosis cases were also included. A total of 26 male patients aged 8–75 years, with a diagnosis of histoplasmosis were included; nine were farmers, seven had diabetes, one was a renal transplant recipient, and four had HIV/AIDS. Fever (n = 20), weight loss (n = 17), anemia (n = 15), lymphadenopathy (n = 9), and hepatosplenomegaly (n = 7) were common. Eleven patients had bilateral adrenal enlargement. Diagnosis was confirmed by histo/cytopathology from skin (n = 1), oropharyngeal ulcers (n = 8), lymph nodes (n = 3), adrenal glands (n = 11), paravertebral soft tissue (n = 2), and bone marrow (n = 4). Cultures of representative samples and antibodies were detected in three and two cases, respectively. Twenty-two patients had disseminated histoplasmosis and four patients had localized oropharyngeal disease. Nine patients were prescribed anti-tuberculosis drugs empirically before establishing the diagnosis of histoplasmosis. Treatment consisted of amphotericin B and itraconazole. Six patients died in hospital, 14 patients recovered with relapse in two cases, and the outcome of the other patients could not be ascertained. Histoplasmosis is thought to be endemic in Bangladesh, but few cases are reported to date, which may be due to many asymptomatic, undiagnosed, misdiagnosed, or under-reported cases. Histoplasmosis should be considered as a differential in appropriate clinical scenarios.

Histoplasmosis is a systemic fungal infection caused by dimorphic fungus *Histoplasma capsulatum*, which is widely distributed throughout the world, but the greatest endemicity is reported in the Americas, especially along the Mississippi and Ohio river valleys.^{1,2} Its mycelial form is found in soil rich in bird and bat droppings.³ Airborne conidia enter into the human lungs by inhalation, where they germinate into yeast form.^{4,5} The host response to infection depends upon the size of the infective inoculum, the underlying health of the patient, and host immune status.¹ Most infections

remain asymptomatic or mild respiratory symptoms may occur in immunocompetent individuals, but in immunodeficient patients, dissemination may occur to involve various organs including the oropharynx, lymph nodes, liver, spleen, skin, and adrenal glands.^{2,4–11} Reactivation of latent infections may complicate recipients of solid organ transplants and patients receiving immunosuppressive therapy for other reasons.^{12,13} Symptoms depend upon organ involvement; fever and weight loss are common features,^{4–11} and the clinical presentation often mimics tuberculosis.⁶ Diagnosis depends on identification of the organism in culture or

histopathological examination findings of tissue biopsy samples or serological tests.²

In Bangladesh, one-fifth of the population exhibited positive skin sensitivity reaction to histoplasmin^{14,15}, with the first case of histoplasmosis reported in 1982.¹⁶ Cases were infrequent but in recent years, a good number of cases, mostly disseminated forms, have been reported in immunodeficient and immunocompetent patients.¹⁷⁻³¹ In this systematic review, we describe the sociodemographic characteristics, clinical features, diagnostic proofs, treatment, and outcome of histoplasmosis in Bangladesh.

METHODS

We systematically searched to identify all previously published English literature containing information regarding histoplasmosis in/ or from Bangladesh. Searches were conducted via “PubMed” using the keywords “Bangladesh”, “*Histoplasma capsulatum*”, and “histoplasmosis”. We also systematically searched through Bangladesh Journals Online (BanglaJOL) for articles published in local journals. The search engine “Google” was also used to identify articles. All literature searches were conducted up to 31 December 2017. Searches were conducted by the first two authors individually and then cross-checked by all the authors. Unpublished but well-documented cases (seven cases) were added. Cases mentioned elsewhere with inadequate information^{7,32,33} and possible repetitions^{21,34} were excluded [Figure 1].

Histoplasmosis cases were analyzed for selected sociodemographic characteristics including age and sex, immune status, endemicity, travel history, site(s) of disease, proof of diagnosis, treatment given, and the outcome recorded. Immunodeficiency status included patients with HIV or AIDS, those receiving immunosuppressive drugs, organ transplant recipients, patients with diabetes mellitus, and those with congenital immunodeficiency. Patients were categorized as having localized or systemic histoplasmosis. Systemic disease was characterized as single organ disease or disseminated forms. Disseminated disease was defined when a typical organism was grown in cultures or typical histopathological findings were identified from samples of extrapulmonary sites along with systemic symptoms.^{7,9} Endemicity was labeled where the patient had never traveled outside Bangladesh.

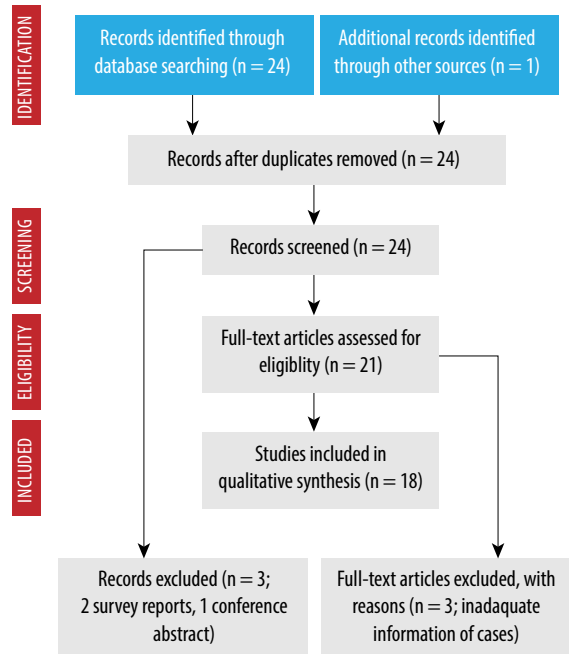


Figure 1: Flow diagram for histoplasmosis cases in Bangladesh.

RESULTS

Twenty-four articles were identified from published literature including 18 case reports, three research articles, two survey reports, and one conference abstract; and one article was identified from another source (Figure 1, Table 1, case no 22). From them, two cases were excluded because of repetition, three research articles were excluded because of inadequate information for cases (references 7 and 33) and presumptive diagnosis (reference 32), two skin survey reports (references 14 and 15), and one conference abstract was excluded. Finally, a total of 19 cases were eligible for analysis from published literature (total 18 articles) [Figure 1], to which seven unpublished but well-documented cases were added to make the total number of cases 26 [Table 1].

All 26 patients were male with a mean age of 50.9 years (range 8–75) [Table 1 and Table 2]. Nine patients were farmers, and five patients had a history of smoking. Five patients had a history of traveling outside Bangladesh [Table 2].

Among the patients, one was a known case of AIDS, and disseminated histoplasmosis was the presenting feature of AIDS in another three cases [Table 2]. The CD4 counts in one patient with AIDS was 19/ μ L and 4/ μ L in another patient [Table 1]. Seven patients had diabetes, one was a

Table 1: Cases of histoplasmosis in/or from Bangladesh (N = 26).

Patient number/ Journal, Year/ Reference	Age/ Sex/ Occupation	Immune status	Clinical presentation	Physical signs	Important laboratory and imaging findings	Diagnostic test and form of histoplasmosis	Treatment and outcome
1/ BMRC Bull, 1982 ¹⁶	69 years/ Male/ Not known	Not known	Nodular lesion in oral mucosa	Submandibular lymphadenopathy Hepatosplenomegaly	-	Histopathology from oral nodule. Disseminated histoplasmosis.	Amphotericin B. Anti-TB prescription. Cured with relapse at 16 th month.
2/ JBCPS, 2005 ³⁵	41 years/ Male/ Businessman	Positive anti- HIV	Fever Weight loss Anorexia Sore throat Loose motion	Anemia Oral moniliasis Dehydration Cervical lymphadenopathy Hepatosplenomegaly	Hb = 7.7 gm/dL WBC = 3800/cmm Platelets = 150000/cmm	Bone marrow study. Disseminated histoplasmosis.	Itraconazole. Expired in hospital due to septic shock.
3/ Transpl Infect Dis, 2010 ⁷	60 years/ Male/ Builder	T2DM Renal transplant recipient	Fever Sore throat	Skin nodules	Hb = 11.1 gm/dL WBC = 3100/cmm LDH = 256 IU/L Abnormal chest imaging (nodules)	Biopsy and culture from skin nodule, broncho-alveolar lavage, and transbronchial biopsy. Epiglottic biopsy. Disseminated histoplasmosis.	Lipid amphotericin B. Itraconazole for an indefinite period. History of INH prophylaxis. Cured, no recurrence up to 2 years.
4/ BSMMUJ, 2010 ¹⁸	45 years/ Male/ Fishing farm worker	HIV-negative	Fever Weight loss Abdominal pain	Anemia Generalized lymphadenopathy Growth in the oral cavity Ascites	Hb = 9.1 gm/dL ESR = 40 mm in first hour	Biopsy and histopathology from tongue growth and lymph node. Disseminated histoplasmosis.	Amphotericin B. Itraconazole (planned for one year). Improved up to six weeks.
5/ JHPN, 2010 ¹⁹	32 years/ Male/ Storekeeper	Diagnosed AIDS	Fever Weight loss Anorexia	Cervical lymphadenopathy Splenomegaly Maculopapular rash	Hb = 9.6 gm/dL Esophageal candidiasis CD4 = 19/uL	Histopathology from lymph node. Disseminated histoplasmosis.	Amphotericin B (0.7 mg/kg/d for 21 days). Itraconazole (200 mg 12-h). Anti-TB Not known
6/ J Med, 2010 ²⁰	56 years/ Male/ Not known	HIV-negative	Fever Cough Shortness of breath Disorientation	Anemia	Hb = 9 gm/dL ESR = 60 mm in first hour Serum creatinine = 2.3 mg/ dL Abnormal chest X-ray (infiltrates)	Bone marrow study. Disseminated histoplasmosis.	Amphotericin B. Anti-TB (presumptive). Expired due to aspiration pneumonia.
7/ J Med, 2010 ²¹	57 years/ Male/ Farmer	Not known	Fever Back pain	Anemia Generalized lymphadenopathy Hepatomegaly Spastic paraparesis	Hb = 8.9 mg/dL ESR = 90 mm in first hour	Open biopsy from paravertebral tissue. Disseminated histoplasmosis.	Not known Not known

Table 1: Cases of histoplasmosis in/or from Bangladesh (N = 26).

continued

Patient number/ Journal, Year/ Reference	Age/ Sex/ Occupation	Immune status	Clinical presentation	Physical signs	Important laboratory and imaging findings	Diagnostic test and form of histoplasmosis	Treatment and outcome
8/ Unpublished, 2010*	8 years/ Male/ Unknown	Not known	Fever Anorexia Weight loss Diarrhea	Anemia Generalized lymphadenopathy Hepatosplenomegaly	Hb = 8.3 gm/dL WBC = 5300/cmm Platelets = 132 000/cmm ESR = 89 mm in first hour	Lymph node culture. Disseminated histoplasmosis.	Anti-TB Expired
9/ J Med, 2011 ²²	65 years/ Male/ School teacher	HIV-negative	Fever Anorexia Weight loss Abdominal pain Cough Hemoptysis Vomiting Oral ulcer	Hepatomegaly Lung crepitation	ALT = 81.9 IU/L AST = 83.2 IU/L Abnormal chest X-ray (reticulonodular shadow). Bilateral adrenal masses.	FNAC from adrenal gland. Partial adrenal insufficiency. Disseminated histoplasmosis.	Anti-TB for eight months. Not known
10/ JBCPS, 2011 ²³	75 years/ Male/ Farmer	HIV-negative	Fever Anorexia Weight loss	Anemia Postural hypotension	ERS = 41 mm in first hour. Bilateral adrenal masses.	FNAC and culture from adrenal gland. Partial adrenal insufficiency. Disseminated histoplasmosis.	Amphotericin B (five doses) Itraconazole (one year). Cured, no recurrence up to 27 weeks of follow-up.
11/ J Med, 2012 ²⁴	60 years/ Male/ Not known	HIV-negative	Hoarseness of voice	Ulcerative growth in vocal cord	Abnormal chest X-ray (diffuse patchy opacity).	Histopathology from vocal cord specimen. Primary vocal cord histoplasmosis.	Amphotericin B (0.5 mg/kg EAD for 14 doses). Itraconazole (200 mg 12-h for 12 weeks). Anti-TB (two times) Improved and advised for follow-up.
12/ JAFMC, 2012 ²⁵	30 years/ Male/ Brick field worker	HIV positive	Fever Cough Bleeding from multiple sites Respiratory distress Loose stool Dis-orientation	Anemia Mucosal ulcers rash/ plaques Abnormal chest auscultation	Pancytopenia ALT = 103 IU/L Alkaline phosphatase = 527 IU/L LDH = 1003 U/L Abnormal chest imaging (consolidation).	PBF and bone marrow study. Disseminated histoplasmosis.	Anti-TB for nine months (presumptive). Expired in hospital due to aspiration pneumonia.
13/ JBCPS, 2012 ²⁶	42 years/ Male/ Painter	HIV-negative	Oral ulcer Dysphagia Poor general health Diarrhea	Anemia Bilateral submandibular lymphadenopathy	-	Histopathology from oral ulcer. Localized to the oral cavity.	Itraconazole (200 mg 12-h for three weeks then maintenance dose). Cured, no recurrence up to 2 months of follow-up.

Table 1: Cases of histoplasmosis in/or from Bangladesh (N = 26).

-continued

Patient number/ Journal, Year/ Reference	Age/ Sex/ Occupation	Immune status	Clinical presentation	Physical signs	Important laboratory and imaging findings	Diagnostic test and form of histoplasmosis	Treatment and outcome
14/ JBCPS, 2012 ²⁶	65 years/ Male/ Farmer	HIV-negative	Oral ulcer Poor general health	Anemia Bilateral submandibular lymphadenopathy	-	Histopathology from oral ulcer. Localized to oral cavity.	Itraconazole (200 mg BID for 4 weeks then maintenance dose). Cured, no recurrence up to 2 months of follow-up.
15/ J Gen Pract, 2013 ²⁷	32 years/ Male/ Farmer	HIV-negative	Fever Weight loss Anorexia	Hepatosplenomegaly	ESR = 40 mm in first hour Bilateral adrenal masses	FNAC from adrenal gland. Disseminated histoplasmosis.	Anti-TB Not known
16/ Bang J Med. 2013 ²⁸	45 years/ Male/ Not known	T2DM HIV positive	Fever Cough Weight loss Orogenital ulcers	Anemia Rash Crepitation in lung Hepatomegaly	Hb = 8.2 gm/dL WBC = 3600/cmm Platelets = 103 000/cmm ESR = 115 mm in first hour ALT = 146 IU/L AST = 537 IU/L Alkaline phosphatase = 407 IU/L LDH = 826U/L CD4 = 4/uL	Bone marrow study. Disseminated histoplasmosis.	Amphotericin B Expired
17/ J Med, 2013 ²⁹	62 years/ Male/ Farmer	HIV-negative	Fever Back pain Paraplegia Bowel-bladder in-continence	Anemia Generalized lymphadenopathy Hepatosplenomegaly Spastic paraplegia	-	Lymph node biopsy CT-guided FNAC from paraspinal soft tissue. Disseminated histoplasmosis.	Amphotericin B Itraconazole Neurosurgical exploration. Improved (up to one month of follow-up).
18/ Mymensingh Med J, 2014 ³⁰	60 years/ Male/ Farmer	T2DM HIV-negative	Fever Cough Weight loss Sore throat Voice change	-	FBG = 12 mmol/L Patchy opacity in chest X-ray	Histopathology from vocal cord punch biopsy specimen (ulcer). Vocal cord histoplasmosis.	Amphotericin B (0.5 mg/kg/d for six weeks). Itraconazole (200 mg for 12 weeks). Anti-TB Improved up to three months of follow-up.
19/ Unpublished, 2014*	60 years/ Male/ Farmer	Not known	Weight loss Anorexia Weakness	Increased pigmentation	Hb = 10.9 gm/dl WBC = 10 800/cmm Platelets = 189 000/cmm ESR = 47 mm in first hour ALT = 41 IU/L ACTH stimulation test: partial adrenal insufficiency Bilateral adrenal enlargement	CT-guided FNAC from adrenal gland. Gum biopsy Anti-histoplasma antibody. Disseminated histoplasmosis.	Itraconazole Hydrocortisone Improved up to five months of follow-up.

Table 1: Cases of histoplasmosis in/or from Bangladesh (N = 26).

-continued

Patient number/ Journal, Year/ Reference	Age/ Sex/ Occupation	Immune status	Clinical presentation	Physical signs	Important laboratory and imaging findings	Diagnostic test and form of histoplasmosis	Treatment and outcome
20/ Unpublished, 2014*	42 years/ Male/ Farmer	Not known	Weight loss Anorexia Weakness	Increased pigmentation	Hb = 10.6 gm/dL WBC = 9700/cmm Platelets = 230 000/cmm ESR = 53 mm in first hour ALT = 65 IU/L ACTH stimulation test: partial adrenal insufficiency Bilateral adrenal enlargement	CT-guided FNAC from the adrenal gland. Anti-histoplasma antibody. Disseminated histoplasmosis.	Itraconazole Hydrocortisone Improved up to three months of follow-up.
21/ Unpublished, 2014*	59 years/ Male/ School teacher	T2DM HIV-negative	Fever Weight loss Anorexia	Anemia Jaundice Hepatoplenomegaly	Hb = 9.1 gm/dL WBC = 3900/cmm Platelets = 89 000/cmm ESR = 85 mm in first hour Bilateral adrenal enlargement	FNAC from the adrenal gland. Disseminated histoplasmosis.	Discharged against medical advice. Not known
22/ BSM Bull, 2015	40 years/ Male/ Not known	HIV-negative	Fever Weight loss Cough Anorexia Weakness	Anemia Pigmentation Hepatomegaly	Hb = 8.9 gm/dl Bilateral adrenal mass	USG guided FNAC from adrenal gland. Disseminated histoplasmosis.	Lipid formulation of amphotericin B (0.5 mg/kg/d for two weeks). Itraconazole (200 mg 12-h for 12 months). Anti-TB Not known
23/ Unpublished, 2015*	72 years/ Male/ Retired government employee	T2DM HIV-negative	Fever Weight loss Anorexia	Anemia	Hb = 9.6 gm/dl WBC = 6700/cmm Platelets = 165 000/cmm ESR = 67 mm in first hour HbA1c = 8.3% Bilateral adrenal enlargement	FNAC from the adrenal gland. Disseminated histoplasmosis.	Amphotericin B Itraconazole Improving
24/ Unpublished, 2015*	62 years/ Male/ Retired government employee	T2DM	Fever Anorexia Weight loss Cough Convulsion	Anemia	Hb = 8.7 gm/dl WBC = 4100/cmm Platelets = 153 000/cmm ESR = 45 mm in first hour HbA1c = 7.9% Bilateral adrenal enlargement	FNAC from the adrenal gland MRI of brain. Disseminated histoplasmosis.	Amphotericin B Itraconazole. Recurrence with CNS histoplasmosis (later expired).
25/ Unpublished, 2016*	42 years/ Male/ Service holder	HIV-negative	Fever Anorexia Weight loss	Hepatosplenomegaly	Hb = 12 gm/dl WBC = 5600/cmm Platelets = 222 000/cmm ESR = 78 mm in first hour Bilateral adrenal enlargement	FNAC from the adrenal gland. Disseminated histoplasmosis.	Itraconazole Anti-TB Not known

Table 1: Cases of histoplasmosis in/ or from Bangladesh (N = 26)

-continued

Patient number/ Journal, Year/ Reference	Age/ Sex/ Occupation	Immune status	Clinical presentation	Physical signs	Important laboratory and imaging findings	Diagnostic test and form of histoplasmosis	Treatment and outcome
26/ BIRDEM Med J, 2018 ³¹	42 years/ Male/ Not known	T2DM HIV-negative	Fever Anorexia Weight loss Pigmentation	-	Hb = 12.4 gm/dL WBC = 8300/cmm Platelets = 426 000/cmm ESR = 40 mm in first hour ALT = 91 IU/L AST = 82 IU/L HbA1c = 6.6% Bilateral adrenal enlargement	FNAC from the adrenal gland. ACTH stimulation test: no adrenal insufficiency. Disseminated histoplasmosis.	Amphotericin B (14 days). Itraconazole (planned for 18 months). Improved up to last (six month) visit.

Anti-TB: anti-tuberculosis; HIV: human immune deficiency virus; Hb: hemoglobin; WBC: white blood cells; T2DM: type 2 diabetes mellitus; LDH: lactate dehydrogenase; INH: isoniazid; ESR: erythrocyte sedimentation rate; AIDS: acquired immunodeficiency syndrome; CD: cluster of differentiation; ALT: alanine aminotransferase; AST: aspartate aminotransferase; FNAC: fine-needle aspiration cytology; EAD: every alternate day; PBF: peripheral blood film; FBC: fasting blood glucose; CT: computed tomography; ACTH: adrenocorticotropic hormone; USG: ultrasonography; HbA1c: glycated hemoglobin; MRI: magnetic resonance imaging; CNS: central nervous system; BID: twice a day.
*Note: Unpublished cases were recruited from three teaching hospitals, BIRDEM General Hospital (cases 8, 21, 23 and 25), Bangabandhu Sheikh Mujib Medical University (cases 19 and 20) and Dhaka Medical College (Case 24), Dhaka, Bangladesh. Missing data: physical signs (cases 18 and 26) and value/important laboratory and imaging findings (cases 1, 13, 14 and 17).

renal transplant recipient, and another had AIDS. HIV was negative in 15 cases and the HIV status was not known in the rest of the cases [Table 2]. No other history suggestive of immunosuppression was found among the patients.

Fever (n = 20) and weight loss (n = 17) were the two most common clinical presentations. Other features were oral ulcer, anorexia, skin rash and nodules, cough, abdominal pain, diarrhea, and bleeding [Table 1]. Common physical findings included anemia, lymphadenopathy, hepatosplenomegaly, oral candidiasis, and abnormal lung findings [Table 2].

Fifteen patients had anemia, including pancytopenia in two patients. Three (reports available for six patients) patients had abnormal liver biochemistry, and two (reports available for three patients) patients had raised lactate dehydrogenase (LDH). Abnormal chest radiograph and bilateral adrenal enlargement were present in six and 11 cases, respectively [Table 2]. Esophageal moniliasis was found in three patients. Diagnosis was confirmed by histopathological examination of tissue from oropharyngeal ulcers (n = 8) and bone marrow (n = 4), and fine-needle aspiration cytology from adrenal glands (n = 11), lymph nodes (n = 3), and skin (n = 1) [Table 1]. Culture from lymph nodes and adrenal glands aspirates and skin nodule revealed growth of *Histoplasma* in one case each. Disseminated histoplasmosis was diagnosed in 22 cases and localized oropharyngeal disease in four cases. In six cases, diagnosis was confirmed from more than one site.

Treatment consisted of amphotericin B and itraconazole with wide variations in doses and durations [Table 1 and Table 2]. Nine patients were prescribed anti-tuberculosis (anti-TB) drugs during disease course empirically or without definitive proof, and three patients had a history of tuberculosis/anti-TB prophylaxis [Table 1]. Six patients with disseminated histoplasmosis died in hospital, 14 patients recovered with relapse in two cases (one patient later died in hospital), and the outcome of the other six cases could not be ascertained [Table 1].

DISCUSSION

The first histoplasmosis survey was done in Bangladesh in 1961 (then East Pakistan), which

Table 2: Selected sociodemographic, clinical, and laboratory characteristics of Bangladeshi patients with histoplasmosis (N = 26).

Characteristics	Frequency	Percentage	Mean	Range
Age, years	-	-	50.9	8-75
Sex, male	26	100	-	-
Occupation, farmer	9	34.6	-	-
Habit, smoker	5	19.2	-	-
History of traveling outside Bangladesh				
No	21	80.8	-	-
Yes	5	19.2	-	-
Underlying condition				
Diabetes mellitus	7	26.9	-	-
Kidney transplant recipient	1	3.8	-	-
HIV/AIDS status				
Positive	4	15.4	-	-
Negative	15	57.7	-	-
Not known	7	26.9	-	-
Clinical presentation				
Fever	20	76.9	-	-
Weight loss	17	65.4	-	-
Anorexia	14	53.8	-	-
Cough	7	26.9	-	-
Oral ulcer	8	30.8	-	-
Hyperpigmentation	3	11.5	-	-
Anemia	15	57.7	-	-
Cervical lymphadenopathy	5	19.2	-	-
Generalized lymphadenopathy	4	15.4	-	-
Skin rash/nodule	4	15.4	-	-
Hepatomegaly	3	11.5	-	-
Hepatosplenomegaly	7	26.9	-	-
Splenomegaly	1	3.8	-	-
Major organ involvement				
Lung	6	23.1	-	-
Liver/spleen	9	34.6	-	-
Adrenal glands	11	42.3	-	-
Skin	7	26.9	-	-
Gastrointestinal tract	8	30.8	-	-
Bone marrow	4	15.4	-	-
Lymph nodes	9	34.6	-	-
Form of histoplasmosis				
Disseminated histoplasmosis	22	84.6	-	-
Localized oropharyngeal disease	4	15.4	-	-
Treatment				
Amphotericin B (initial)	14	53.8	-	-
Itraconazole (continuation/only)	17	65.5	-	-
Anti-TB treatment, empiric	9	34.6	-	-
Follow-up and outcome				
Cured/improving up to the last follow-up	14 (recurred in 2)	53.8	-	-
Death	6	23.1	-	-
Recurred	2 (1 later expired)	7.7	-	-
Not known	6	23.1	-	-

HIV: human immunodeficiency virus; AIDS: acquired immunodeficiency syndrome; TB: tuberculosis.

revealed that 12–23% of people had a positive skin reaction to histoplasmin.¹⁴ A second survey among patients attending different clinics revealed almost similar results in 1968–1969.¹⁵ We also found similar results reported among people living along the banks of the river Jamuna near Delhi, India, in a survey in 1960.³⁶ In endemic areas, more than half of the population exhibit positive skin reaction to histoplasmin.¹ The first histoplasmosis case in Bangladesh was reported in 1982¹⁶ and the second case in 2005.³⁵ Cases are increasingly reported nowadays.^{17–31} All were males, reflecting that males are possibly more at risk of exposure to soil due to occupational or recreational activities. A male predominance of histoplasmosis cases was also reported from India^{6,7} and Brazil.³⁷

Common presenting features were fever, weight loss, oropharyngeal ulcer, lymphadenopathy, and hepatosplenomegaly. Bilateral adrenal enlargement was also common. Similar findings were reported among patients from Panama,⁹ Brazil,³⁷ Australia,¹⁰ Europe,¹¹ Africa,⁸ South-East Asia⁵, and India^{6,7} irrespective of patients' immune status. Disseminated forms were more common than the localized disease in the current study, even in immunocompetent patients. In immunocompetent patients, adrenal enlargements were more common as was seen in an Australian series¹⁰, but less than two Indian series.^{6,7} Increased steroid concentration within the adrenal glands promotes the growth of *H. capsulatum*.³⁸

Cytopenias, elevated hepatic enzymes, and LDH are established features of disseminated histoplasmosis in HIV infected patients.^{9,28} Among the three patients in whom LDH reports were available, two had raised LDH, and both had HIV/AIDS. Among the 26 cases reported here, only in the first case authors reported the possibility of histoplasmosis during diagnostic work-up. Among the seven unpublished cases (cases 8, 19–21, 23–25) reported here, in six (except case 8) adrenal histoplasmosis was a deferential diagnosis during diagnostic work-up (primary data; by personal communication); but few other cases reported here were diagnosed incidentally (cases 6, 7, 9, 11, 16, 17 and 26 by personal communication with the corresponding authors) when tissue samples were sent for histopathological examination or culture. A similar observation was reported in a South-East Asian series.⁵

Treatment of reported histoplasmosis cases consisted mostly of amphotericin B followed by oral

itraconazole. In localized oral cases, itraconazole can be curative. Regarding the outcome of histoplasmosis cases, six patients with disseminated disease died, and 14 patients improved with relapse in two cases. Treatment monitoring is important. Urine antigen can be used for treatment monitoring and possible disease recurrence.^{39,40} In Bangladesh, currently there is no facility for such a test.

As histoplasmosis is an uncommon diagnosis in Bangladesh, diagnostic work-up and management strategies varied widely among the cases reported. We do not have any definite working diagnostic algorithms for many diseases, including histoplasmosis, and diagnostic work-ups are performed on a case-by-case basis and also depend upon the availability of diagnostic facilities. The 2007 Update by the Infectious Diseases Society of America recommends initial amphotericin B treatment followed by itraconazole in moderately severe to severe progressive disseminated histoplasmosis cases and in less severe cases oral itraconazole.⁴¹ Patients with HIV may require life-long therapy depending upon CD4 counts and the status of anti-retroviral therapy.⁴¹ Physicians should adhere to standard protocols⁴¹ for managing histoplasmosis cases and as the cases are increasing in Bangladesh, especially in the last two decades [Table 1], it should be evaluated for possible “emerging disease” and also whether it should be considered a “notifiable” one.

Our literature search was confined to “PubMed,” “BanglaJOL,” and “Google” and we did not search through other databases. Treatment detail and outcome data were not available for all the cases reported.

CONCLUSION

Despite high skin sensitivity test results, only a small number of cases (mostly from 2010 and onwards) were reported over a three-decade period in Bangladesh. It may indicate that a good number of cases remain asymptomatic or minimally symptomatic. There may be cross-reactivity to some other fungus with histoplasmin. Under-reporting of cases and improper diagnosis, especially tuberculosis, is not impossible. Clinicians should be aware of the condition and histoplasmosis should be suspected in an appropriate clinical setting. A further survey may be done in farm areas and among persons working on poultry farms.

Disclosure

The authors declared no conflicts of interest. No funding was received for this study.

REFERENCES

1. Wheat LJ. Histoplasmosis: a review for clinicians from non-endemic areas. *Mycoses* 2006 Jul;49(4):274-282.
2. Kauffman CA. Histoplasmosis: a clinical and laboratory update. *Clin Microbiol Rev* 2007 Jan;20(1):115-132.
3. Wheat LJ, Kauffman CA. Histoplasmosis. *Infect Dis Clin North Am* 2003 Mar;17(1):1-19.
4. Oladele RO, Ayanlowo OO, Richardson MD, Denning DW. Histoplasmosis in Africa: an emerging or a neglected disease? *PLoS Negl Trop Dis* 2018 Jan;12(1):e0006046.
5. Wang TL, Cheah JS, Holmberg K. Case report and review of disseminated histoplasmosis in South-East Asia: clinical and epidemiological implications. *Trop Med Int Health* 1996 Feb;1(1):35-42.
6. Gopalakrishnan R, Nambi PS, Ramasubramanian V, Abdul Ghafur K, Parameswaran A. Histoplasmosis in India: truly uncommon or uncommonly recognised? *J Assoc Physicians India* 2012 Oct;60:25-28.
7. Subramanian S, Abraham OC, Rupali P, Zachariah A, Mathews MS, Mathai D. Disseminated histoplasmosis. *J Assoc Physicians India* 2005 Mar;53:185-189.
8. Loulergue P, Bastides F, Baudouin V, Chandenier J, Mariani-Kurkdjian P, Dupont B, et al. Literature review and case histories of *Histoplasma capsulatum* var. *duboisii* infections in HIV-infected patients. *Emerg Infect Dis* 2007 Nov;13(11):1647-1652.
9. Gutierrez ME, Canton A, Sosa N, Puga E, Talavera L. Disseminated histoplasmosis in patients with AIDS in Panama: a review of 104 cases. *Clin Infect Dis* 2005 Apr;40(8):1199-1202.
10. McLeod DS, Mortimer RH, Perry-Keene DA, Allworth A, Woods ML, Perry-Keene J, et al. Histoplasmosis in Australia: report of 16 cases and literature review. *Medicine (Baltimore)* 2011 Jan;90(1):61-68.
11. Antinori S, Magni C, Nebuloni M, Parravicini C, Corbellino M, Sollima S, et al. Histoplasmosis among human immunodeficiency virus-infected people in Europe: report of 4 cases and review of the literature. *Medicine (Baltimore)* 2006 Jan;85(1):22-36.
12. Gajurel K, Dhakal R, Deresinski S. Histoplasmosis in transplant recipients. *Clin Transplant* 2017 Oct;31(10).
13. Blanchard E, Truchetet ME, Machelart I, Séneschal J, Raherison-Semjen C. Respiratory infections associated with anti-TNF α agents. *Med Mal Infect* 2017 Oct;47(6):375-381.
14. Islam N, Islam M, Muazzam MG. A histoplasmosis survey in East Pakistan. *Trans R Soc Trop Med Hyg* 1962;56(3):246-249.
15. Islam N, Sobhan MA. Sensitivity to histoplasmin, coccidioidin, blastomycin, and tuberculin in East Pakistan. *Am J Trop Med Hyg* 1971 Jul;20(4):621-624.
16. Islam N, Chowdhury NA. Histoplasmosis from Bangladesh: a case report. *Bangladesh Med Res Counc Bull* 1982 Jun;8(1):21-24.
17. Rappo U, Beitler JR, Faulhaber JR, Firoz B, Henning JS, Thomas KM, et al. Expanding the horizons of histoplasmosis: disseminated histoplasmosis in a renal transplant patient after a trip to Bangladesh. *Transpl Infect Dis* 2010 Apr;12(2):155-160.
18. Ahmed S, Shazzad MN, Rahman MF, Kader MA, Azad MA, Haq SA. Disseminated histoplasmosis without pulmonary involvement in an immunocompetent host – a case report. *BSMMU J* 2010;3(1):44-46.
19. Pervez MM, Cobb B, Matin N, Shahrin L, Ford ER, Pietroni M. Disseminated histoplasmosis in a patient with advanced HIV disease—lessons learnt from Bangladesh. *J Health Popul Nutr* 2010 Jun;28(3):305-307.
20. Mahbub MS, Ahsan MN, Miah MT, Alam MB, Gupta RD, Arif KM, et al. Disseminated histoplasmosis. *J Med* 2010;11:70-73.
21. Parvin R, Amin R, Mahbub MS, Hasnain M, Arif KM, Miah MT, et al. Deep fungal infection- an emerging problem in Bangladesh. *J Med* 2010;11:170-175.
22. Amin MR, Shumi F, Khan H, Abdullah SA, Alam S, Hussain AR, et al. Disseminated histoplasmosis in an elderly man presented with fever, weight loss, abdominal pain and haemoptysis – a case report with literature review. *J Med* 2011;12(1):81-85.
23. Alam AS, Hasan Z, Khan MA, Zulkifl MA, Samdani AT, Islam MT, et al. Chronic disseminated histoplasmosis in an immunocompetent man presented as bilateral adrenal masses with partial adrenocortical insufficiency- a rare condition. *J Bangladesh Coll Phys Surg* 2011;29(4):235-240.
24. Habib SK, Patwary SA, Khan MA, Miah MT, Gupta RD, Ahasan HA. Primary histoplasmosis of vocal cord in an immunocompetent elderly man- a case report with literature review. *J Med* 2012;13(1):77-81.
25. Bhuiyan MN, Giti S, Islam MS, Uddin MN. Disseminated histoplasmosis in a patient with AIDS- a case report and review of literature. *JAFMC* 2012;8(2):81-86.
26. Sadat SM, Rita SN, Kahhar MA. Oral histoplasmosis: report of two cases. *J Bangladesh Coll Phys Surg* 2012;30(4):229-233.
27. Parvin R, Uddin AK. Bilateral adrenal histoplasmosis in an immunocompetent man. *J Gen Pract (Los Angel)* 2013;1:103.
28. Yasmin R, Rahim MA, Haque HF, Dewan P, Ahmed JU, Ahmed AS, et al. Disseminated histoplasmosis as presenting feature of acquired immunodeficiency syndrome: a case report. *Bangladesh J Medicine* 2013;24(2):78-81.
29. Singha CK, Biswas E, Jahan F, Biswas PK. Histoplasmosis – an unusual cause of spastic paraplegia in an immunocompetent host in Bangladesh. *J Med* 2013;14(2):201-203.
30. Masud MK, Ahmad SM, Ferdouse F, Bhuiyan MR, Paul SK, Litu MA, et al. Laryngeal histoplasmosis. *Mymensingh Med J* 2014 Jul;23(3):566-571.
31. Afsana F, Hossain KN, Tareque A, Amin MF, Pathan MF. A Case of adrenal histoplasmosis. *BIRDEM Med J* 2018;8(1):77-80.
32. Shahrin L, Leung DT, Matin N, Pervez MM, Azim T, Bardhan PK, et al. Characteristics and predictors of death among hospitalized HIV-infected patients in a low HIV prevalence country: Bangladesh. *PLoS One* 2014 Dec;9(12):e113095.
33. Gu gnani HC, Denning DW, Rahim R, Sadat A, Belal M, Mahbub MS. Burden of serious fungal infections in Bangladesh. *Eur J Clin Microbiol Infect Dis* 2017 Jun;36(6):993-997.
34. Sadat SM, Robin MA, Rita SN, Akhter F, Uddin AF. Oral histoplasmosis with previously treated pulmonary tuberculosis: a case report. *Med Today* 2013;25(2):99-102.
35. Rahman MM, Hossain SM, Dewanjee AK, Sultan MT, Faiz MA, Rahman J. Disseminated histoplasmosis in acquired immunodeficiency syndrome – a case report. *J Bangladesh Coll Phys Surg* 2005;23:43-45.
36. Viswanathan R, Chakravarty SC, Randhawa HS, Demonte AJ. Pilot histoplasmosis survey in Delhi area. *Br Med J* 1960 Feb;1(5170):399-400.
37. Faiolla RC, Coelho MC, Santana RdeC, Martinez R. Histoplasmosis in immunocompetent individuals living in an endemic area in the Brazilian Southeast. *Rev Soc Bras Med Trop* 2013 Jul-Aug;46(4):461-465.
38. Angeli A, Masera RG, Gatti G. Mycoses and adrenocortical function. New pathogenetic aspects of adrenal hypofunction. *Recenti Prog Med* 1991 Dec;82(12):652-660.
39. Wheat LJ. Histoplasmosis in Indianapolis. *Clin Infect Dis* 1992 Mar;14(Suppl 1):S91-S99.

40. Wheat LJ, Connolly-Stringfield P, Blair R, Connolly K, Garringer T, Katz BP, et al. Effect of successful treatment with amphotericin B on *Histoplasma capsulatum* variety *capsulatum* polysaccharide antigen levels in patients with AIDS and histoplasmosis. *Am J Med* 1992 Feb;92(2):153-160.
41. Wheat LJ, Freifeld AG, Kleiman MB, Baddley JW, McKinsey DS, Loyd JE, et al; Infectious Diseases Society of America. Clinical practice guidelines for the management of patients with histoplasmosis: 2007 update by the Infectious Diseases Society of America. *Clin Infect Dis* 2007 Oct;45(7):807-825.