




OPEN ACCESS

Optical coherence tomography angiography in preclinical Alzheimer's disease

Jacoba Alida van de Kreeke ,¹ Hoang-Ton Nguyen,¹ Elles Konijnenberg,² Jori Tomassen,² Anouk den Braber,^{2,3} Mara ten Kate,² Maqsood Yaqub,⁴ Bart van Berckel,⁴ Adriaan A Lammertsma,⁴ Dorret I Boomsma,³ Stevie H Tan,¹ Frank Verbraak,¹ Pieter Jelle Visser²

► Additional material is published online only. To view please visit the journal online (<http://dx.doi.org/10.1136/bjophthalmol-2019-314127>)

¹Department of Ophthalmology, Amsterdam UMC, location VUmc, Amsterdam, The Netherlands

²Alzheimer Center, Amsterdam UMC, location VUmc, Amsterdam, The Netherlands

³Department of Biological Psychology, Vrije Universiteit Amsterdam, Amsterdam, The Netherlands

⁴Department of Radiology & Nuclear Medicine, Amsterdam UMC, location VUmc, Amsterdam, The Netherlands

Correspondence to

Jacoba Alida van de Kreeke, Ophthalmology, Vrije Universiteit Academic Hospital, Amsterdam 1081HV, The Netherlands; ja.vandekreeke@vumc.nl

Received 21 February 2019

Revised 19 March 2019

Accepted 2 April 2019

Published Online First

22 May 2019

ABSTRACT

Background/aims As a protrusion from the brain, the retina might reflect the status of the brain. Previous studies showed a decrease in vessel density and foveal avascular zone (FAZ) enlargement on optical coherence tomography angiography (OCTA) in individuals suffering from Alzheimer's disease (AD). This study aims to assess whether such changes are already present in preclinical stages of AD, in a population of monozygotic (MZ) twins.

Methods 124 cognitively healthy individuals (MZ twins, ages 60–93 years) underwent [¹⁸F]flutemetamol amyloid positron emission tomography (PET) scanning and OCTA. PET scans were visually rated for cortical amyloid-beta (Aβ) positivity. Parametric global cortical non-displaceable binding potential (BP_{ND}) was used as a continuous measure for Aβ aggregation. FAZ size and vessel densities for the inner and outer ring of the macular ETDRS grid and in a 3–6 mm ring around the optic nerve head (ONH) were measured.

OCTA measures were associated with visual Aβ score, BP_{ND} and amyloid load estimated by twin concordance on visual Aβ score. Twin correlations were estimated as a measure of maximum heritability of OCTA measures.

Results 13 of 124 participants were Aβ+. Aβ+ individuals had significantly higher vessel density than Aβ– individuals in all regions but did not differ in FAZ size. Twin analyses showed a positive association between and vessel densities in all regions. BP_{ND} tended to be associated with higher vessel density in the inner ring. Twin correlations were moderate/high for all OCTA parameters except vessel density around the ONH, which correlated weakly.

Conclusion Retinal vessel density was higher in individuals with preclinical AD.

INTRODUCTION

Dementia, and in particular Alzheimer's disease (AD), is the most common neurological disorder worldwide, and it is estimated that 1 in 3 of those born in developed countries today will develop dementia during their life.¹ AD is a disease characterised by the accumulation of amyloid-beta (Aβ) and tau in the brain.² At present, there is no curative treatment for AD, despite many trials targeting, for example, Aβ deposits in the brain.^{3,4} The most common explanation for the poor results is one of timing: once severe neurodegeneration has occurred, there is no way back. As most of the trials so far have focused on patients already suffering

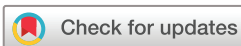from AD, it is postulated that more success may be achieved by targeting those who still are cognitively intact.^{3,4}

This, however, poses a new problem. How can we recognise those at risk for the development of AD when there are no clinical symptoms yet? PET scanning has provided a breakthrough in diagnosing these cases of 'preclinical' AD. The process of Aβ accumulation in the brain is a gradual one, which often has been ongoing for decades prior to onset of clinical symptoms.⁵ By using tracers sensitive to Aβ, PET enables visualisation of Aβ presence in vivo in cognitively healthy individuals.⁶ Presence of Aβ in the brain of healthy individuals constitutes a high risk of eventual developing AD, which is why these people are often labelled as suffering from preclinical AD.^{6,7}

However, as reliable as this technique may be, it is currently not suitable for large-scale screening. It is a costly diagnostic procedure that is only available in larger hospitals.⁸ Additionally, PET scanning makes use of intravenously delivered radioactive tracers, which is unpleasant to the patient and subjects them to radioactivity.⁹

This illustrates the urgent need for an easy, non-invasive and reliable biomarker for preclinical AD. The eye, and especially the retina, may provide an answer to this need. The retina is closely related to the brain, as is reflected by the shared embryological origin and similarities such as a blood–retina barrier and glial cell connections.¹⁰ Many studies have already illustrated changes in the retina of individuals suffering from AD, such as retinal thinning and vascular changes.^{11–13}

Conveniently, the retina is easily accessible through the optically clear media of the eye by using optical techniques. Optical coherence tomography (OCT) is such a technique, allowing imaging of the retina with a micrometre resolution.¹⁴ The recently developed functional extension of OCT termed OCT angiography (OCTA) enables a detailed angiographic view of the retinal vascular network. As AD is a disease that is also characterised by vascular changes, OCTA may reflect such vascular changes in the retina, making it of interest as a potential new and possibly early biomarker for AD.¹⁵ Some groups have already illustrated that vessel density is diminished and that the foveal avascular zone (FAZ) is enlarged in individuals with AD type dementia.^{16–18} Very few groups, however, have looked whether similar findings are present



© Author(s) (or their employer(s)) 2020. Re-use permitted under CC BY-NC. No commercial re-use. See rights and permissions. Published by BMJ.

To cite: van de Kreeke JA, Nguyen H-T, Konijnenberg E, et al. *Br J Ophthalmol* 2020;**104**:157–161.

in preclinical stages. If this is the case, OCTA may prove to be the invaluable biomarker that is sorely needed. The purpose of this study was to elucidate the diagnostic capabilities of OCTA in recognising individuals with preclinical AD, as confirmed by the presence of cerebral A β on PET scanning. Furthermore, by including monozygotic (MZ) twins, secondary aims were to: (1) elucidate the contribution of genes to vessel density and FAZ size on OCTA and (2) gain more insight in the aetiology of possible relationships between cerebral A β and retinal vascular changes on OCTA.

METHODS

Participants

This study is part of the Amsterdam substudy of the European Medical Information Framework for Alzheimer's Disease (EMIF-AD) PreclinAD cohort. From this cohort with 194 participants from the Netherlands Twin Registry,^{19 20} 150 participants received a complete ophthalmological examination including OCTA. Written informed consent was obtained from all participants, and the study followed the Tenets of the Declaration of Helsinki.

Inclusion criteria for the EMIF-AD study were: age ≥ 60 years, monozygosity, cognitively healthy as defined by: Telephone Interview for Cognitive Status modified score >22 , Geriatric Depression Scale score <11 , Consortium to Establish a Registry for Alzheimer's Disease 10-item word list immediate and delayed recall >-1.5 SD of age adjusted normative data and Clinical Dementia Rating (CDR) scale of 0 with a score on the memory sub domain of 0.

Exclusion criteria for the EMIF-AD study were: uncontrolled diabetes mellitus, alcohol consumption >35 units (1 unit=10 mL or 8 g of pure alcohol) per week, stroke with physical impairment, neurodegenerative disorders and/or cancer with a terminal life expectancy.²⁰

Ophthalmological examination

The following ophthalmological data were obtained: best-corrected visual acuity, intraocular pressure, refraction data, slit lamp examination, indirect funduscopy, fundus photography and conventional OCT of the macula and optic disc. Pupil dilation was achieved using tropicamide 0.5%. OCT images and photographs were assessed by an experienced ophthalmologist (H-TN) for unexpected pathology. Participants suffering from ophthalmological conditions interfering with the retina or image quality were excluded prior to analyses (cataract, macular degeneration, glaucoma, diabetic retinopathy, vascular occlusions and refractive error <-8 dioptres or $>+5$ dioptres).

Optical coherence tomography angiography

Standard 6×6 mm angiographic scans consisting of 350 B-scans of the macular region and around the optic nerve head (ONH) were obtained using the Cirrus 5000 Angioplex (Zeiss Meditec, Inc, Germany). Vessel densities were measured in all scans, as well as the area of the FAZ in the macular scans. For macular scans, vessel densities in the ETDRS grid were averaged to obtain one value for the inner ring (1–3 mm around the fovea) and the outer ring (3–6 mm around the fovea), while for the ONH scans, vessel density was measured in a 3–6 mm ring around the ONH. Values were averaged over left and right eyes. If only one eye could be scanned reliably, only the values of that eye were used.

OCTA scans were acquired on average 22 months after the amyloid PET scans. This is due to OCTA being available in our hospital only recently, at the time of the 2-year follow-up.

Amyloid PET scanning

All PET scans were acquired using a TF PET-MRI scanner (Philips Medical Systems, Best, the Netherlands). After intravenous injection of 185 MBq ($\pm 10\%$) [^{18}F]flutemetamol, all participants were scanned dynamically from 0 min to 30 min and then again from 90 min to 110 min.²¹ A T1-weighted gradient echo pulse MRI scan was obtained immediately prior to each part of the PET scan, which was used for attenuation correction. The first dynamic emission scan was reconstructed into 18 frames with progressive increase in frame length (6×5 , 3×10 , 4×60 , 2×150 , 2×300 and 1×600 s), the second part of the scan consisted of 4×5 min frames. Vinci viewing software 2.56 (Max Planck Institute for neurological research, Cologne, Germany) and in-house build tools were used to coregister and combine the two PET scans into a single multiframe image. Each individual's T1 was coregistered to the dynamic PET image using the generic multimodality setting of Vinci with a linear rigid body scheme and normalised mutual information as the similarity measure. The entire image set was used to generate parametric binding potential relative to the non-displaceable compartment (non-displaceable binding potential or BP_{ND}) images using the receptor parametric mapping^{22 23} implementation in PPET.²⁴ Standard uptake value ratio (SUVr) images were constructed based on the 90–110 min acquired data. Cerebellar grey matter, defined by the Hammers atlas, was used as reference region for these analyses.²⁵ Global values were computed based on the average of frontal (volume-weighted average of superior, middle and inferior frontal gyri), parietal (volume weighted average of posterior cingulate, superior parietal gyrus, post-central gyrus and inferolateral remainder of parietal lobe) and temporal (volume-weighted average of parahippocampal gyrus, hippocampus, medial temporal lobe, superior, middle and inferior temporal gyrus) regions.²⁶

All SUVr images were visually read by an experienced nuclear physician (BvB), and a positive or negative rating was awarded according to criteria defined by the manufacturer (GE Healthcare).²⁷

Statistical analysis

The values for BP_{ND} were log-transformed to normalise their distribution. Therefore, analyses with these as dependent variables are reported in ratios instead of regression coefficients. A ratio can take any value from 0 onward, where 1 means there is no relationship, <1 means there is a negative relationship and >1 means there is a positive relationship. Associations between amyloid positivity/ BP_{ND} and vessel density/FAZ were analysed using generalised estimating equations (GEE) to correct for clustering in the data from twin pairs as well as confounders such as age, gender, scan quality and a diagnosis of diabetes. As multiple yet related variables (vessel density in several regions and FAZ) were analysed, data were corrected for multiple testing using the Holm-Bonferroni method.²⁸ Receiver operating characteristic (ROC) curves were used to test overall predictive accuracy. To estimate the maximal genetic contribution to OCTA variables, the resemblance of MZ twins was quantified using Pearson correlations. For OCTA measures that were associated with amyloid status, post hoc analyses were performed, which used the status of the twin pair as a measure of 'A β load'. We defined four groups, depending on concordance or discordance for A β status within pairs.²⁹ Twins were grouped with increasing A β load starting with twins from pairs who were both A β - (group 1=concordant negative, ie, the 'healthy group'), followed by twins from discordant pairs who were A β - (group 2=discordant

Table 1 Demographics of the study population

Number of participants (N)	124
Age (years)	68.6 (±6.3)
Sex, female N (%)	66 (53.2)
BCVA (logarithm of the minimum angle of resolution)	0.01 (±0.09)
IOP (mm Hg)	14.2 (±2.6)
Spherical equivalent	0.40 (±1.82)
MMSE (median, IQR)	29.0 (29.0–30.0)
Brain amyloid status, positive N (%)	13 (10.5)
Global BP_{ND} of A β (median, IQR)	0.122 (0.095–0.177)
Retinal vessel density	
Inner ring macula	17.3 (±1.3)
Outer ring macula	17.6 (±1.2)
Around optic nerve head	18.1 (±1.3)
Foveal avascular zone (mm ²)	0.22 (±0.09)

Data are means unless otherwise specified.

A β , amyloid-beta; BCVA, best-corrected visual acuity (both eyes averaged); BP_{ND} , non-displaceable binding potential; IOP, intraocular pressure (both eyes averaged); MMSE, Mini-Mental State Exam.

negative) or A β + (group 3=discordant positive) and ending with twins from pairs who were both A β + (group 4=concordant positive, ie, the group with the highest load). This classification assumed that discordant A β - participants were in a very early stage of amyloid accumulation. The resulting variable with four different loads for A β pathology was analysed with GEE to look for associations with OCTA markers. All statistical analyses were performed in SPSS (V.22).

RESULTS

Of the 150 participants scanned, 26 were excluded due to ophthalmological disease (N=12, mostly glaucoma and age-related macular degeneration) or low-quality scans of both eyes (N=14). **table 1** shows demographic information of the 124 participants included in the analyses.

Vessel density in all regions was significantly higher for A β + individuals versus A β - individuals. There was no significant difference in FAZ size between A β + and A β - individuals. **table 2** shows all vessel density and FAZ differences for both groups.

The Area Under the Curve (AUC) values corresponding to the ROC curves for vessel densities in inner and outer ring of the macula and around the ONH were 0.651, 0.640 and 0.764, respectively (online supplementary figure 1). Sensitivity and specificity were both around 0.8 at a cut-off of 18.9 for the vessel density around the ONH.

Table 2 Difference in vessel densities and foveal avascular zone area between amyloid-positive and amyloid-negative participants

	A β + versus A β -			Adjusted p value
	Difference	Raw p value	95% CI	
Retinal vessel density				
Inner ring macula	0.81	<0.001	0.36 to 1.26	0.002
Outer ring macula	0.50	0.012	0.11 to 0.90	0.024
Around optic nerve head	0.83	0.005	0.25 to 1.42	0.015
Foveal avascular zone (mm ²)	-0.02	0.387	-0.05 to 0.02	0.387

Adjusted p values were calculated using the Holm-Bonferroni method.

GEE, corrected for age, gender, scan quality and diagnosis of diabetes.

A β , amyloid-beta; GEE, generalised estimating equation.

Table 3 Twin post hoc A β load analyses for retinal vessel densities in three regions

Retinal vessel density	Twin A β load score			Adjusted Pp value
	Beta	Raw P value	95% CI	
Inner ring macula	0.27	0.009	0.07 to 0.47	0.018
Outer ring macula	0.18	0.037	0.01 to 0.35	0.037
Around optic nerve head	0.30	0.002	0.11 to 0.49	0.006

Obtained using GEE, corrected for age, gender, scan quality and diagnosis of diabetes.

A β , amyloid-beta; GEE, generalised estimating equations.

Table 3 shows the linear twin post hoc analyses using the A β load score for vessel densities in the three regions; they were significant for vessel densities all regions. Online supplementary table 1 shows these analyses when comparing group means, and online supplementary figure 2 shows the boxplots.

The continuous measure of BP_{ND} of [¹⁸F]flutemetamol to A β was significantly associated with vessel density in the inner ring, but this association did not retain statistical significance after correction for multiple testing (**table 4**).

All OCTA measures correlated moderately to highly within twin pairs, except for vessel density around the ONH (**table 5**). Correction for APOE genotype (APOE4 carrier vs non-carrier) did not change these correlations.

DISCUSSION

The main finding of this study was that A β + participants had a significantly higher vessel density on OCTA than A β - participants in both the inner and outer ring of the macula and around the ONH. No significant differences in FAZ size were found.

Earlier studies demonstrated a lower retinal vessel density and larger FAZ in patients suffering from AD in the dementia stage.^{16–18} Based on these findings, we anticipated similar differences in the preclinical phase of AD. Yet, we found the opposite: a higher vessel density in all retinal areas (inner and outer ring of the macula, around the ONH), remaining statistically significant after correction for multiple testing. An explanation for this unexpected finding may lie in an inflammatory state of the retina in the early stages of amyloid accumulation, as many studies have found that the cerebral events occurring during the development of AD and accumulation of A β are often of an inflammatory nature.³⁰ Supposing such events occur in synchrony within the

Table 4 Associations between global cortical non-displaceable binding potential of A β and vessel densities/foveal avascular zone, given in ratios due to a log transformation applied to the dependent variable

Retinal vessel density	Global cortical non-displaceable binding potential of A β			Adjusted p value
	Ratio	Raw p value	95% CI	
Inner ring macula*	2.28	0.016	1.21 to 6.41	0.064
Outer ring macula*	3.74	0.052	0.99 to 14.1	0.156
Around optic nerve head*	0.86	0.654	0.43 to 1.69	0.654
Foveal avascular zone (mm ²)	0.59	0.356	0.19 to 1.80	0.712

GEE, corrected for age, gender, scan quality and diagnosis of diabetes.

*Reported in steps of 10. Adjusted p values were calculated using the Holm-Bonferroni method.

A β , amyloid-beta; GEE, generalised estimating equations.

Table 5 Intratwin pair correlation coefficients

	Correlation coefficient	P value
Retinal vessel density		
Inner ring macula	0.50	<0.001
Outer ring macula	0.62	<0.001
Around optic nerve head	0.34	0.014
Foveal avascular zone	0.85	<0.001

retina, it may be that in the preclinical stages this inflammatory reaction with hypoxia leads to increased retinal blood flow. Microvessels normally not detected on OCTA due to a blood flow, which is below the detection level, will become visible. This increase in the number of microvessels detected on OCTA will result in a higher vessel density.³¹ After this initial phase, continued inflammation and A β build-up may cause further damage resulting in a loss of (micro)vasculature in turn causing a decrease in vessel density, explaining why individuals suffering from full-blown AD may have lower vessel density.^{16 17 32}

In our cohort, no differences were found in FAZ size between A β + and A β - individuals. This is in contrast with the findings of a previous study, where a FAZ enlargement was found in A β + participants.³³ Two other studies looking at AD also found FAZ enlargement.^{16 17} It is possible that our participants were at an earlier stage in the disease process, where FAZ size is still unchanged but that does not explain why the other group already found this difference in preclinical AD cases. The FAZ size being unchanged does support our theory that in an early inflammatory process, blood flow in microvasculature may be increased, as one would not expect an enlargement of FAZ if this were the case. Further studies need to be performed to elucidate possible changes in FAZ size in preclinical AD.

Considering the rather pronounced differences in vessel density between A β + and A β - individuals, ROC curves for these measures were generated (online supplementary figure 1). Due to the low N in the A β + group, caution is warranted in their interpretation. Vessel density around the ONH showed the best ROC curve (AUC=0.764, online supplementary figure 1), and with a sensitivity and specificity of around 0.8 suggests diagnostic potential, although findings need to be replicated.

When staging concordant and discordant twins in a presumed model of increasing amyloid accumulation (twin post hoc A β load analysis²⁹) vessel density increased further along the A β load groups in a more or less linear fashion (online supplementary table 1, online supplementary figure 2). A statistically significant positive association between this A β load score and vessel density was found for all regions (table 3), supporting our theory that with more A β pathology, retinal vessel density increases.

We found an association between BP_{ND} and vessel density in the inner ring of the macula, and a trend with vessel density in the outer ring of the macula, but both lost statistical significance after correction for multiple testing. Considering the differences between the two groups (A β + vs A β -) in vessel density, we had expected a stronger association between retinal vessel density and BP_{ND} (as a continuous measure for cortical A β). The explanation for the lack of this (strong) association may be found in the distribution of BP_{ND} ; many people have little to no cortical A β , whereas just a few individuals have high cortical A β . This results in little variation in BP_{ND} , which might explain why no associations were found.

Intratwin pair correlations were moderate to high for all OCTA measures except vessel density around the ONH (table 5). In earlier studies, we found higher intratwin pair correlations

for other retinal markers such as retinal vascular parameters on fundus photography.³⁴ The reason for these lower correlations of OCTA markers may lie in lower reproducibility of vessel density measures, as we noticed that vessel density is very much affected by scan quality (lower quality=lower vessel density) as well as clouding of the media (floaters and cataract), making this a less reliable measure. This also explains the high number of participants who were excluded due to insufficient quality scans of both eyes (N=14). Although the intratwin pair correlations were lower for OCTA measures, they still suggest a moderate to high contribution of either genes or shared environment to these traits. As no dizygotic twin pairs were included in this study, no heritability estimates could be made. However, the estimated contribution of shared environmental effects is lower in older twins, as these twins have spent most of their life apart.^{29 35} Therefore, due to the older age of this cohort, the twin correlations in OCTA measures are likely of a genetic origin. Nevertheless, a substantial amount of variability (39%–66%, table 5) is related to unique environmental factors, which remain to be identified. To the best of our knowledge, no other studies on the subject of heritability of OCTA measures have been performed.

Strengths of the study include the thorough characterisation of participants from both a neurological and ophthalmological perspective. Extensive screening for cognitive health guaranteed that only cases of preclinical AD (ie, cognitively healthy) were included. We excluded (glaucoma, vascular occlusions and age-related macular degeneration) or controlled (diabetes) for confounders known to affect vessel density.

The main limitation of this study lies in its low inclusion and resulting (statistical) power, especially for A β + individuals. This is due to the nature of the study: only around 20% of individuals around ages 70 years are positive for A β , making this a common problem in studies assessing preclinical AD.⁵ Yet, several OCTA measures showed significant differences between the groups, which remained after correction for multiple testing. However, the low number of participants warrants caution in interpreting these results, as the results found in this (small) subset of participants might not be applicable to the population as a whole. Further studies with a larger number of subjects are needed to confirm these findings. Additionally, OCTA is a relatively new technology, and the parameters that are currently included in the imaging software (vessel density and FAZ size) may end up not being the most useful metrics for biomarker assessment. Future studies should also include newly developed, and perhaps more suitable, OCTA measures to examine their feasibility as potential biomarkers for preclinical AD.

Another limitation was that OCTA scans were made 22 months after the PET scans. At that time, four individuals had a CDR score of 0.5, indicating mild cognitive impairment. Exclusion of these individuals yielded similar results. It is possible that some individuals may have become amyloid positive at follow-up, but a previous study in amyloid negative, cognitively normal individuals showed that the risk for this in 2 years is very low and therefore unlikely to have an impact on our findings.³⁶

In conclusion, we found a significantly higher retinal vessel density in all measured regions in A β + versus A β - participants, suggesting retinal vessel density to be of interest as a possible biomarker for preclinical AD. No differences were found in FAZ size between the two groups.

Contributors JAVdK: writing the manuscript, acquiring data, analyses of the results, interpretation of the data, contribution to the conception and design of the work. H-TN, EK and MtK: acquiring data, contribution to the conception and design of the work and critical revising of the manuscript. JT: acquiring data and critical

revising of the manuscript. AdB and DIB: contribution to the conception and design of the work and critical revising of the manuscript. MY, BvB and AAL: interpretation of the data and critical revising of the manuscript. SHT: critical revising of the manuscript. FV and PJV: interpretation of the data, contribution to the conception and design of the work and critical revising of the manuscript.

Funding This work has received support from the European Union/European Federation of Pharmaceutical Industries and Associations (EU/EFPIA) Innovative Medicines Initiative Joint Undertaking (EMIF grant number 115372). This work has received funding from GE Healthcare in kind (PET tracer).

Competing interests None declared.

Patient consent for publication Not required.

Ethics approval Medical Ethics Committee of the Amsterdam UMC, location VUmc, number 2014.210 (EMIF-AD).

Provenance and peer review Not commissioned; externally peer reviewed.

Data sharing statement Data are available upon request.

Open access This is an open access article distributed in accordance with the Creative Commons Attribution Non Commercial (CC BY-NC 4.0) license, which permits others to distribute, remix, adapt, build upon this work non-commercially, and license their derivative works on different terms, provided the original work is properly cited, appropriate credit is given, any changes made indicated, and the use is non-commercial. See: <http://creativecommons.org/licenses/by-nc/4.0/>.

ORCID iD

Jacoba Alida van de Kreeke <http://orcid.org/0000-0002-0165-1839>

REFERENCES

- Lewis F. *Estimation of future cases of dementia from those born in 2015. Consulting report July 2015*. Office of Health Economics, 2015.
- Eratne D, Loi SM, Farrand S, et al. Alzheimer's disease paper 1: clinical update on epidemiology, pathophysiology and diagnosis. *Australas Psychiatry* 2018;1039856218762308.
- Sun BL, WW L, Zhu C, et al. Clinical research on Alzheimer's disease: progress and perspectives. *Neurosci Bull* 2018.
- Viña J, Sanz-Ros J. Alzheimer's disease: only prevention makes sense. *Eur J Clin Invest* 2018;48:e13005.
- Jansen WJ, Ossenkoppelle R, Knol DL, et al. Prevalence of cerebral amyloid pathology in persons without dementia: a meta-analysis. *JAMA* 2015;313:1924–38.
- Jack CR, Barrio JR, Kepe V. Cerebral amyloid PET imaging in Alzheimer's disease. *Acta Neuropathol* 2013;126:643–57.
- Vlaskenko AG, Benzinger TLS, Morris JC. PET amyloid-beta imaging in preclinical Alzheimer's disease. *Biochim Biophys Acta* 2012;1822:370–9.
- Hornberger J, Bae J, Watson I, et al. Clinical and cost implications of amyloid beta detection with amyloid beta positron emission tomography imaging in early Alzheimer's disease - the case of florbetapir. *Curr Med Res Opin* 2017;33:675–85.
- Nishii R, Higashi T, Kagawa S, et al. 18F-FPYBF-2, a new F- labelled amyloid imaging PET tracer: biodistribution and radiation dosimetry assessment of first-in-man 18F-FPYBF-2 PET imaging. *Ann Nucl Med* 2018;32:256–63.
- London A, Benhar I, Schwartz M. The retina as a window to the brain-from eye research to CNS disorders. *Nat Rev Neurol* 2013;9:44–53.
- den Haan J, Verbraak FD, Visser PJ, et al. Retinal thickness in Alzheimer's disease: a systematic review and meta-analysis. *Alzheimers Dement* 2017;6:162–70.
- Frost S, Martins RN, Kanagasingam Y. Ocular biomarkers for early detection of Alzheimer's disease. *JAD* 2010;22:1–16.
- McGrory S, Cameron JR, Pellegrini E, et al. The application of retinal fundus camera imaging in dementia: a systematic review. *Alzheimers Dement* 2017;6:91–107.
- Huang D, Swanson EA, Lin CP, et al. Optical coherence tomography. *Science* 1991;254:1178–81.
- Jellinger KA. Alzheimer disease and cerebrovascular pathology: an update. *J Neural Transm* 2002;109:813–36.
- Bulut M, Kurtuluş F, Gözkaya O, et al. Evaluation of optical coherence tomography angiographic findings in Alzheimer's type dementia. *Br J Ophthalmol* 2018;102:233–7.
- Jiang H, Wei Y, Shi Y, et al. Altered macular microvasculature in mild cognitive impairment and Alzheimer disease. *J Neuroophthalmol* 2018;38:292–8.
- Grewal DS, Polascik BW, Hoffmeyer GC, et al. Assessment of differences in retinal microvasculature using OCT angiography in Alzheimer's disease: a twin discordance report. *Ophthalmic Surg Lasers Imaging Retina* 2018;49:440–4.
- Boomsma DI, de Geus EJC, Vink JM, et al. Netherlands twin register: from twins to twin families. *Twin Res Hum Genet* 2006;9:849–57.
- Konijnenberg E, Carter SF, ten Kate M, et al. The EMIF-AD PreclinAD study: study design and baseline cohort overview. *Alz Res Therapy* 2018;10.
- Heeman FY M, Heurling K, Alves L, I. P20: Optimized coffee-break protocol for quantitative [18F]flutemetamol studies. Human Amyloid Imaging Conference, Miami, Florida, 2018.
- Gunn RN, Lammertsma AA, Hume SP, et al. Parametric imaging of ligand-receptor binding in PET using a simplified reference region model. *Neuroimage* 1997;6:279–87.
- Wu Y, Carson RE. Noise reduction in the simplified reference tissue model for neuroreceptor functional imaging. *J Cereb Blood Flow Metab* 2002;22:1440–52.
- Boellaard R, Yaqub M, Lubberink M, et al. PPET: a software tool for kinetic and parametric analyses of dynamic PET studies. *Neuroimage* 2006;31.
- Hammers A, Allom R, Koepp MJ, et al. Three-dimensional maximum probability atlas of the human brain, with particular reference to the temporal lobe. *Hum Brain Mapp* 2003;19:224–47.
- Tolboom N, Yaqub M, van der Flier WM, et al. Detection of Alzheimer pathology in vivo using both 11C-PIB and 18F-FDDNP PET. *J Nucl Med* 2009;50:191–7.
- Collij L, Konijnenberg E, Reimand J, et al. Assessing Amyloid Pathology in Cognitively Normal Subjects using [(18)F]Flutemetamol PET: Comparing Visual Reads and Quantitative Methods. *J Nucl Med* 2018.
- Holm S. A simple sequentially rejective multiple test procedure. *Scandinavian Journal of Statistics* 1979;6:65–70.
- Vitaro F, Brendgen M, Arseneault L. The discordant MZ-twin method: one step closer to the Holy Grail of causality. *Int J Behav Dev* 2009;33:376–82.
- Kinney JW, Bemiller SM, Murtishaw AS, et al. Inflammation as a central mechanism in Alzheimer's disease. *Alzheimers Dement* 2018;4:575–90.
- Sousa DC, Leal I, Moreira S, et al. Hypoxia challenge test and retinal circulation changes - a study using ocular coherence tomography angiography. *Acta Ophthalmol* 2018;96:e315–9.
- Marchesi VT. Alzheimer's dementia begins as a disease of small blood vessels, damaged by oxidative-induced inflammation and dysregulated amyloid metabolism: implications for early detection and therapy. *Faseb J* 2011;25:5–13.
- O'Bryhim BE, Apte RS, Kung N, et al. Association of preclinical Alzheimer disease with optical coherence tomographic angiography findings. *JAMA Ophthalmol* 2018;136:1242–8.
- van de Kreeke JA, Nguyen HT, Konijnenberg E, et al. Retinal and cerebral microvasculopathy: relationships and their genetic contributions. *Invest Ophthalmol Vis Sci* 2018;59:5025–31.
- De Moor MHM, Boomsma DI, Stubbe JH, et al. Testing causality in the association between regular exercise and symptoms of anxiety and depression. *Arch Gen Psychiatry* 2008;65:897–905.
- Donohue MC, Sperling RA, Petersen R, et al. Association between elevated brain amyloid and subsequent cognitive decline among cognitively normal persons. *JAMA* 2017;317:2305–16.