


A tale of twists: loperamide-induced torsades de pointes and ventricular tachycardia storm

Kamal Kant Sahu ¹, Amr El Meligy,² Ajay Kumar Mishra,¹ Sanjeev Goyal²

¹Department of Internal Medicine, Saint Vincent Hospital, Worcester, Massachusetts, USA

²Division of Cardiology, Saint Vincent Hospital, Worcester, Massachusetts, USA

Correspondence to
Dr Kamal Kant Sahu;
drkksahu85@gmail.com

Accepted 20 January 2020

DESCRIPTION

A 69-year-old man with past medical history of coronary artery disease, status postcoronary artery bypass, ischaemic cardiomyopathy with ejection fraction of 15%, status postautomatic implantable cardioverter defibrillator since 2013, known case of ventricular tachycardia (VT), on sotalol, irritable bowel syndrome (IBS) on loperamide as needed, chronic kidney disease, stage III was brought to emergency room for a syncopal event. His ECG rhythm was as shown in [figure 1A,B](#). ECG showed prolonged QTc interval with a continuously varying QRS complex morphology, which was suggestive of torsade de pointes (TdP). TdP can have either an inherited or an acquired cause. In our case, patient was taking sotalol; however, the dose was reduced from 80 mg two times per day to once daily 3 weeks ago in view of worsening renal functions. However, he was also taking 100 mg of loperamide, 2 tablets every day for last 7 days for his IBS. His laboratory tests on presentation showed Na⁺ 140 mmol/L, K⁺ 4.2 mmol/L, Ca²⁺ 8.5 mg/dL, Mg²⁺ 2.2 mg/dL and PO₄³⁻ 3.5 mg/dL. With previous history of arrhythmias, a recent loperamide use and normal electrolytes, we postulated that the patient's QTc prolongation and subsequent TdP were due to loperamide toxicity.

Implantable cardioverter defibrillator (ICD) interrogation showed that he received 29 antitachycardia pacing deliveries and 25 shock deliveries in last few days, with more than three events in a 24-hour span, which fulfilled the criteria for VT storm in this case ([figure 2A–C](#)).

TdP is mostly caused by drugs and dyselectrolytemia, which can cause excessive increase of the QT interval. Loperamide is a well-known over-the-counter (OTC) antidiarrheal agent, which is increasingly being used by drug abusers to improve opioid withdrawal symptoms.¹ More importantly, if patient is also taking an opioid detoxifying medication, methadone, it can promote development of TdP/VT.^{2,3} VT storm is a lethal syndrome that is defined as three or more sustained episodes of VT, or appropriate ICD shocks during a 24-hour period. In our patient, we tried over drive pacing to shorten his QT interval to which he did not respond.

Subsequently, he was started on tablet mexiletine 200 mg three times per day and his single chamber ICD was replaced with dual chamber ICD. Since then, patient is V-paced with no more episodes of VT ([figure 2D](#)).

The current literature suggests that neither the cumulative ingested dose nor the loperamide drug level in the serum can predict the likelihood to

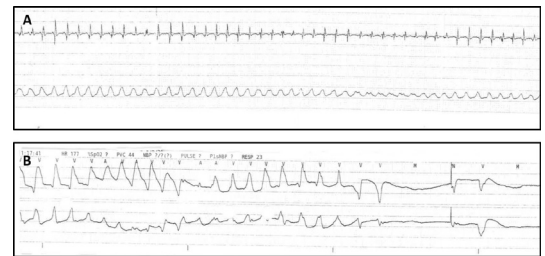


Figure 1 (A,B) ECG shows prolonged QTc interval with a continuously varying QRS complex morphology, which is suggestive of torsade de pointes.

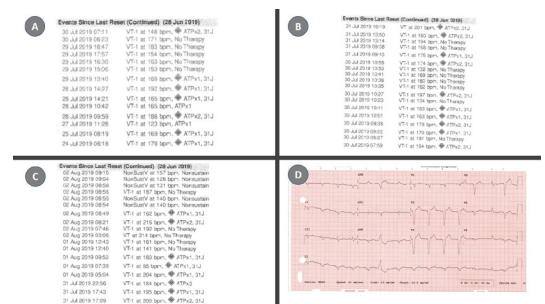
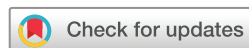

Figure 2 (A–C) Implantable cardioverter defibrillator (ICD) interrogation data confirming ventricular tachycardia storm. (D) Rhythm reverted to sinus, post-ICD shock.

develop loperamide-related cardiotoxicity. The only other reported case of loperamide-induced VT storm (with normal QT interval) was due to intentional overdose of 400 mg in 24 hours.⁴ Our case consumed 200 mg/day for 7 days and also had TdP in addition to VT storm. A recent review on the electrocardiographic changes in loperamide toxicity was done by Teigeler *et al.*⁵ The review had 36 cases with median dose of loperamide 200 mg (134–400 mg), median QTc interval 620 ms (565–701 ms) and VT was experienced by 24/36 (67%) of patients. Timely diagnosis and appropriate intervention can be helpful in preventing fatality in many electrophysiological perturbations and other cardiac conditions.^{6,7} Our case



© BMJ Publishing Group Limited 2020. No commercial re-use. See rights and permissions. Published by BMJ.

To cite: Sahu KK, El Meligy A, Mishra AK, *et al.* *BMJ Case Rep* 2020;**13**:e232823. doi:10.1136/bcr-2019-232823

Learning points

- ▶ Torsade de pointes and ventricular tachycardia (VT) storm are extremely lethal conditions and need urgent intervention.
- ▶ Definitive causes and toxicities if found can help in preventing further episodes of VT storm.

highlights importance of reviewing medication list, especially the OTC drugs like loperamide and challenges in the management of VT.

Contributors KKS: case management and draft. AEM: manuscript writing and editing. AM: ECG reading and review. SG: management and review.

Funding The authors have not declared a specific grant for this research from any funding agency in the public, commercial or not-for-profit sectors.

Competing interests None declared.

Patient consent for publication Obtained.

Provenance and peer review Not commissioned; externally peer reviewed.

ORCID iD

Kamal Kant Sahu <http://orcid.org/0000-0002-0382-6882>

REFERENCES

- 1 Katz KD, Cannon RD, Cook MD, *et al.* Loperamide-Induced torsades de pointes: a case series. *J Emerg Med* 2017;53:339–44.
- 2 Krantz MJ, Kutinsky IB, Robertson AD, *et al.* Dose-Related effects of methadone on QT prolongation in a series of patients with torsade de pointes. *Pharmacotherapy* 2003;23:802–5.
- 3 Mishra AK, Sahu KK, Lal A. Significance of prolonged PR interval in infections. *QJM* 2019;35.
- 4 Al-khatib J, Vindhya SR, Boppana VS, *et al.* Ventricular tachycardia storm induced by loperamide abuse. *Cureus* 2019;11:e3981.
- 5 Teigeler T, Stahura H, Alimohammad R, *et al.* Electrocardiographic changes in loperamide toxicity: case report and review of literature. *J Cardiovasc Electrophysiol* 2019;30:2618–26.
- 6 Sahu K, Mishra A, Lal A, *et al.* An interesting case of expressive aphasia: Enterococcus faecalis related infective endocarditis complicating as septic emboli. *QJM* 2019;pii: hcz169.
- 7 Mishra AK, Sahu KK, Lal A. Significance of prolonged PR interval in infections. *QJM* 2019;pii: hcz192.

Copyright 2020 BMJ Publishing Group. All rights reserved. For permission to reuse any of this content visit <https://www.bmj.com/company/products-services/rights-and-licensing/permissions/>
BMJ Case Report Fellows may re-use this article for personal use and teaching without any further permission.

Become a Fellow of BMJ Case Reports today and you can:

- ▶ Submit as many cases as you like
- ▶ Enjoy fast sympathetic peer review and rapid publication of accepted articles
- ▶ Access all the published articles
- ▶ Re-use any of the published material for personal use and teaching without further permission

Customer Service

If you have any further queries about your subscription, please contact our customer services team on +44 (0) 207111 1105 or via email at support@bmj.com.

Visit casereports.bmj.com for more articles like this and to become a Fellow