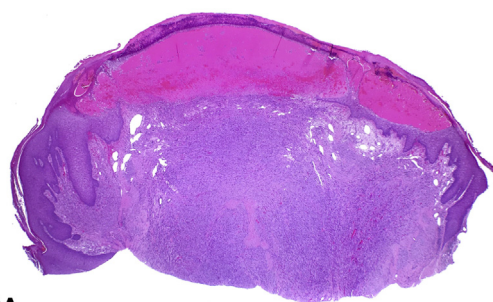
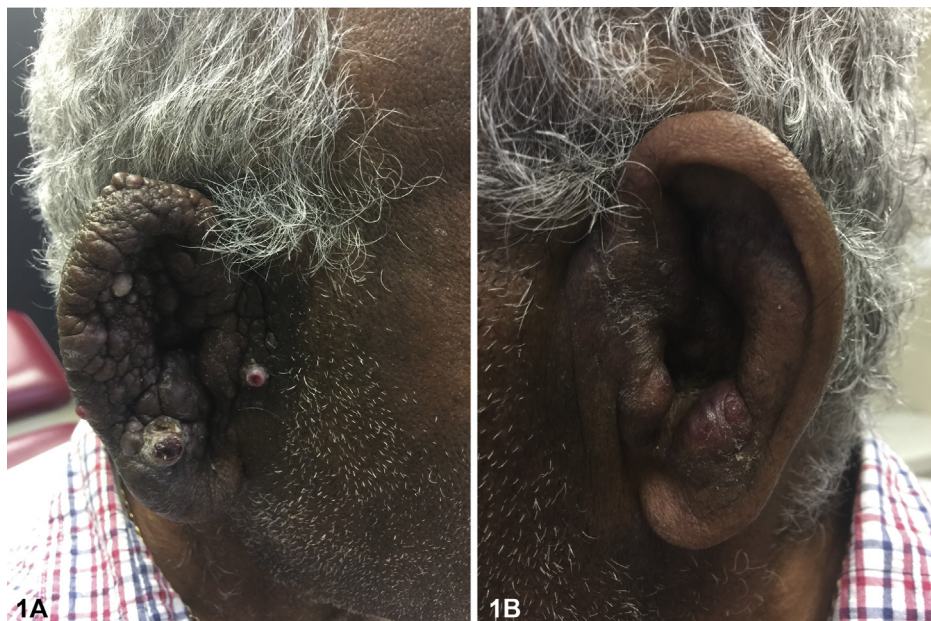

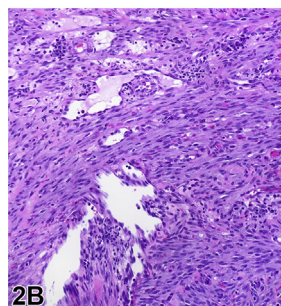
HIV patient with painless bilateral external ear nodules



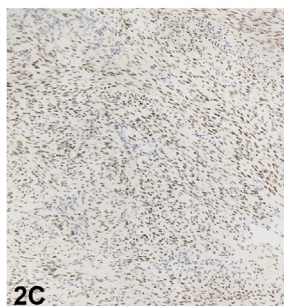
Michelle McNally, RN, BSN,^a Saisindhu Narala, MD, MAS,^b and Misha Koshelev, MD, PhD^b
Houston, Texas



2A



2B



2C

From the University of Texas McGovern Medical School at Houston^a and the Department of Dermatology, University of Texas McGovern Medical School at Houston.^b

Funding sources: None.

Conflicts of interest: None disclosed.

Correspondence to: Misha Koshelev, MD, PhD, 6655 Travis St Ste 980, Houston, TX 77030. E-mail: misha.v.koshelev@uth.tmc.edu.

JAAD Case Reports 2020;6:222-4.
2352-5126

© 2020 by the American Academy of Dermatology, Inc. Published by Elsevier, Inc. This is an open access article under the CC BY-NC-ND license (<http://creativecommons.org/licenses/by-nc-nd/4.0/>).

<https://doi.org/10.1016/j.jdc.2020.01.010>

CASE PRESENTATION

A 72-year-old man who received a diagnosis of HIV 1 week earlier presented with a 2-year history of growing pruritic but painless bilateral external ear nodules. A review of systems was positive for fatigue. On physical examination, the right pinna was enlarged and covered by verrucous, skin-colored papulonodules, resulting in auditory canal narrowing. One similar nodule was present on the left antitragus (Fig 1, A and B). Laboratory results were notable for a CD4⁺ count of 46 cells/ μ L and HIV viral load of 25,600 copies/mL. Results of further infectious evaluation were negative. HIV medications included abacavir/dolutegravir/lamivudine and trimethoprim-sulfamethoxazole prophylaxis. A shave biopsy was performed for histopathologic analysis (Fig 2, A to C).

Question 1: What is your diagnosis?

- A. Sarcoidosis
- B. Bacillary angiomatosis
- C. Kaposi sarcoma
- D. Angiolymphoid hyperplasia with eosinophilia
- E. Kaposiform hemangioendothelioma

Answers:

A. Sarcoidosis—Incorrect. Sarcoidosis is an inflammatory disease that may also rarely manifest with skin-colored nodules of the external ear but can be differentiated from Kaposi sarcoma (KS) according to histopathologic findings of noncaseating granulomas.

B. Bacillary angiomatosis—Incorrect. Bacillary angiomatosis is caused by *Bartonella henselae*, a gram-negative zoonotic bacterium that also commonly infects immunocompromised patients. It is often clinically indistinguishable from KS but can be differentiated on histopathologic examination, which reveals bacilli and a neutrophilic infiltrate.¹

C. KS—Correct. This patient has KS, a malignant proliferation of vascular endothelial cells, most commonly associated with HIV. KS of the ear is a rare occurrence that typically occurs unilaterally. There is a predilection for KS of the ear to appear in HIV-negative patients,² which makes this case with bilateral ear involvement in an HIV-positive patient a unique presentation of KS.

D. Angiolymphoid hyperplasia with eosinophilia—Incorrect. Although angiolymphoid hyperplasia with eosinophilia also commonly manifests on the head and neck, it is not associated with immunosuppression. In addition, angiolymphoid hyperplasia with eosinophilia can be differentiated from KS by the presence of eosinophils on histopathologic analysis.

E. Kaposiform hemangioendothelioma—Incorrect. Kaposiform hemangioendothelioma is an aggressive vascular tumor observed in infants; it is often associated with Kasabach-Merritt phenomenon, a consumptive coagulopathy that results in severe thrombocytopenia.¹ Although the histopathology is similar to that of KS, there is less inflammation in kaposiform hemangioendothelioma. In addition, the patient's age makes a diagnosis of kaposiform hemangioendothelioma less likely.

Question 2: What histologic description correlates with the diagnosis?

A. Proliferation of spindled and epithelioid endothelial cells that form slitlike vascular spaces in a lobular configuration, with deep extension to soft tissue and bone

B. Lobular capillary proliferation in a pale stroma with a neutrophilic or lymphocytic infiltrate and commonly with an epidermal collarette

C. Spindle cell neoplasm characterized by slitlike irregular vascular spaces, formation of new vessels surrounding preexisting vessels, a lymphoplasmacytic infiltrate, and positive human herpesvirus-8 staining result

D. Dense lobular proliferation of capillaries lined by plump endothelial cells in a stroma composed of spindle fibroblasts, mixed inflammatory infiltrate, and bacterial colonization

E. Poorly circumscribed proliferation of small, monomorphic capillaries and venules with collapsed lumina and conspicuous pericytes

Answers:

A. Incorrect. This is descriptive of kaposiform hemangioendothelioma.³ These tumors occur almost exclusively in children. They demonstrate lobular, capillary hemangioma-like areas that are absent in KS.³

B. Incorrect. This is descriptive of pyogenic granuloma, a common benign tumor of blood vessels that has a tendency to bleed.³ Pyogenic granuloma has a clinical presentation similar to that of KS and bacillary angiomatosis.

C. Correct. This is descriptive of KS (Fig 2, A and B). Human herpesvirus-8 is implicated in the pathogenesis of KS and is a sensitive immunohistochemical marker that can assist in the diagnosis and differentiation from other similar vascular formations, such as pyogenic granuloma and bacillary angiomatosis (Fig 2, C).¹

D. Incorrect. This description is observed in bacillary angiomatosis, which can be differentiated from KS by the presence of neutrophils, bacterial colonization, and the absence of human herpesvirus-8. The bacilli can be highlighted with Warthin-Starry staining.¹

E. Incorrect. This is descriptive of microvenular hemangioma, a benign vascular malformation that can be associated with POEMS (polyneuropathy, organomegaly, endocrinopathy, monoclonal protein, skin changes) syndrome. KS contains spindle cells and anastomosing but not collapsed vascular spaces.³

Question 3: Which of the following would be appropriate treatment options for a patient with localized cutaneous involvement of this disease? (Select all that apply.)

- A.** Cryotherapy
- B.** Antiretroviral therapy plus local treatment
- C.** Whole-body radiation
- D.** Systemic chemotherapy
- E.** Photodynamic therapy

Answers:

A. Cryotherapy—Correct. Liquid nitrogen cryotherapy is easily applied and may be successful as a primary therapy for localized KS or as a

supplemental therapy for lesions that respond slowly or incompletely to other treatments.⁴

B. Antiretroviral therapy plus local treatment—Correct. Local treatment with radiation, electron beam therapy, photodynamic therapy, or intralesional medication is recommended in conjunction with antiretroviral therapy to treat HIV-positive KS with localized cutaneous involvement.⁵

C. Whole-body radiation—Incorrect. Local field radiotherapy is one of the most efficient treatments of localized KS, with response rates observed in 92% of patients in a large retrospective case series.⁴ However, whole-body radiation is not indicated for the treatment of localized cutaneous disease.

D. Systemic chemotherapy—Incorrect. Localized cutaneous disease can be treated with either intralesional or topical chemotherapy, with good results reported.⁴ However, systemic chemotherapy is reserved for patients with aggressive systemic disease; liposomal doxorubicin and daunorubicin are both first-line chemotherapeutic options.⁵

E. Photodynamic therapy—Correct. Photodynamic therapy is a treatment option for localized KS, with 1 study showing a complete response in 32.5% of patients and partial response in 63.3% after treatment.⁴

Abbreviation used:

KS: Kaposi sarcoma

REFERENCES

1. Urbanowicz M, Kutzner H, Riveiro-Falkenbach E, Rodriguez-Peralto JL. Infectious angiogenesis—different pathways, the same goal. *Am J Dermatopathol*. 2016;38(11):793-801.
2. Rupp NJ, Bode B, Broglie MA, Morand GB. Kaposi sarcoma of the ear in HIV-negative patients. *Head Neck Pathol*. 2019;13:255-256.
3. Sepulveda A, Buchanan EP. Vascular tumors. *Semin Plast Surg*. 2014;28(2):49-57.
4. Aldenhoven M, Barlo NP, Sanders CJ. Therapeutic strategies for epidemic Kaposi's sarcoma. *Int J STD AIDS*. 2006;17(9):571-578.
5. Wilkins K, Dolev JC, Turner R, LeBoit PE, Berger TG, Maurer TA. Approach to the treatment of cutaneous malignancy in HIV-infected patients. *Dermatol Ther*. 2005;18(1):77-86.