

# A Technique for the Reconstruction of the Limbs of Osteomuscular Tissue Donors\*

## *Técnica para reconstrução de membros de doadores de tecidos osteomusculares*

Luiz Roberto Gomes Vialle<sup>1</sup> Emiliano Neves Vialle<sup>1</sup> Felipe de Negreiros Nanni<sup>1</sup> 

<sup>1</sup> Orthopedics and Traumatology Service, Hospital Universitário Cajuru, Pontifícia Universidade Católica do Paraná, Curitiba, PR, Brazil

Address for correspondence Felipe de Negreiros Nanni, MD, Rua Coronel Dulcídio, 1205, apto 11, Curitiba, PR, Brasil. CEP 80250-100 (e-mail: felipe\_nanni@hotmail.com).

Rev Bras Ortop 2020;55(1):112–114.

### Abstract

#### Keywords

- ▶ tissue and organ procurement
- ▶ bone transplantation
- ▶ reconstruction
- ▶ bone banks

#### Resumo

#### Palavras-chave

- ▶ obtenção de tecidos e órgãos
- ▶ transplante ósseo
- ▶ reconstrução
- ▶ bancos de ossos

The donation of bone and tendon tissues is an important source of biological material used in several surgical techniques. The removal of such tissues generates an important aesthetic sequel in the donor that requires limb reconstruction before returning the corpse to the relatives. The technique used by the Banco de Ossos do Paraná (Bone Bank from Paraná), Brazil, employs metal rebar, silicone tubes and nylon clamps to rebuild the limbs, it is easy to perform and has satisfactory aesthetic results.

A doação de tecidos ósseos e tendíneos é uma importante fonte de material biológico empregado em diversas técnicas cirúrgicas. A remoção destes tecidos gera uma importante seqüela estética no doador, sendo necessária a reconstrução dos membros antes da devolução do corpo aos familiares. A técnica utilizada pelo Banco de Ossos do Paraná faz uso de vergalhões metálicos, tubos de silicone e abraçadeiras de nylon para reconstruir os membros, uma técnica de fácil execução e com resultado estético satisfatório.

### Introduction

The donation of bone and tendon tissues represents an important source of biological material for several tissue transplantation techniques, either as structured grafts or osteoinduction components.

Donation of musculoskeletal tissues requires an extensive collection procedure, with the removal of several bone, muscle and tendinous structures from the lower and upper limbs.

The removal of such structures creates an aesthetic sequel, requiring corpse reconstruction both in respect to the donor's relatives and in compliance with the law.

Federal law number 10.211 from March 23, 2001 disposes that the donor's corpse must be properly reconditioned to be handed over to relatives or legal guardians for burial.

The lack of understanding of the cadaver reconstruction procedure after bone collection is one of the main factors responsible for family members refusal in donating musculoskeletal tissues. One study showed that 96.2% of family members who refused donation had no knowledge of how the reconstruction would be done and how the body would be presented after the procedure.<sup>1</sup>

\* Work performed in the Group of Column Surgery, Service of Orthopedics and Traumatology, Hospital Universitário Cajuru, Pontifícia Universidade Católica do Paraná, Curitiba, PR, Brazil.

received  
January 8, 2018  
accepted  
August 14, 2018

DOI <https://doi.org/10.1055/s-0039-1692696>  
ISSN 0102-3616.

Copyright © 2020 by Sociedade Brasileira de Ortopedia e Traumatologia. Published by Thieme Revinter Publicações Ltda, Rio de Janeiro, Brazil

License terms



## Other Methods

There are several methods used for limb reconstruction after bone collection; the most common uses PVC or wood tubes systems<sup>2</sup> to simulate the donor's previous bone structure.

These systems, however, have some drawbacks. They have bulky parts, requiring large boxes for accommodation and transportation. The collection teams often travel in small airplanes with reduced cargo space, and there are few people to transport these materials; as such, bulky, heavy systems are impractical.

Another disadvantage of these systems is that the pieces usually have thick finishes, making it difficult to fit them into the donor's bone structures. There are prefabricated systems that eliminate this problem, but their cost is so high that their use is unfeasible.

## Method used by the Bone Bank from Paraná

The team from the Bone Bank from Paraná developed a system of donor sites reconstruction that aims to eliminate the problems of components transportation and adaptation difficulty. The technique uses precut, molded 15 mm-diameter metal rebar, silicone tubes, and nylon clamps (► Fig. 1).

## Upper Limb Reconstruction

In the upper limbs, the humerus, radius and ulna are usually collected.

Upper-limbs reconstruction employs a 30-cm metal rebar with its proximal third premolded at a 135° angle for structural replacement of the humerus, a 30-cm metal rebar for forearm reconstruction, and a silicone tube for elbow joint recreation (► Fig. 2).

Since the upper limb is usually seen in funerary ceremonies, the preservation of joint movement at rebuilding allows the better preparation of the donor's corpse for burial.

A hole is created with a chisel and hammer at the glenoid fossa, and, then, the humeral component is hammered to fit



Fig. 1 Metal rebar, silicone tube, nylon clamp, suture and S-needle.




Fig. 2 Components for upper-limb reconstruction.

tightly. Next, a surgical pad is inserted into the humeral head space to increase assembly stability.

The forearm component is embedded between the carpal bones, and both are attached, in the elbow region, to a silicone tube using nylon clamps (► Fig. 3).

The individual components allow an assembly that fits the donor limb size, allowing great freedom of reconstruction with only a single standard size.

Due to the volumetric difference between the removed bone structures and the metal rebars used in the reconstruction, surgical compresses are placed around the stems to increase their volume; as such, when the skin is closed with cotton suture, the compression exerted by the skin helps shaping the limb, giving it an aesthetically pleasing appearance.

The members are then bandaged with crepe.

## Lower-Limb Reconstruction

In the lower limbs, the femur, tibia, fibula, talus, quadricipital and patellar tendons (along with the patella), and calcaneal tendon are collected.

Lower-limbs reconstruction employs a 50-cm metal rebar with its proximal third premolded at a 135° angle for

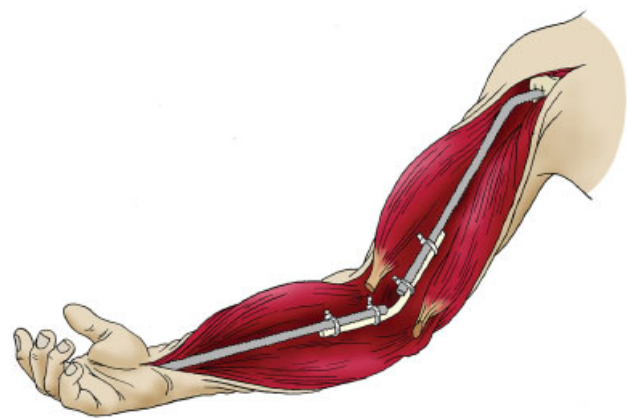


Fig. 3 Internal structure of the assembled upper limb.



**Fig. 4** Components for lower-limb reconstruction.

structural femur replacement and a 55-cm metal rebar for leg reconstruction (►**Fig. 4**).

A hole is created with a chisel and hammer at the glenoid fossa, and, then, the femoral component is hammered into a tight fit. A surgical pad is firmly fitted into the acetabulum to provide greater stability to the assembly.

A second hole is created with a hammer and chisel on the anterior calcaneal joint of the calcaneus, where the component responsible for the leg reconstruction is adapted with a hammer.

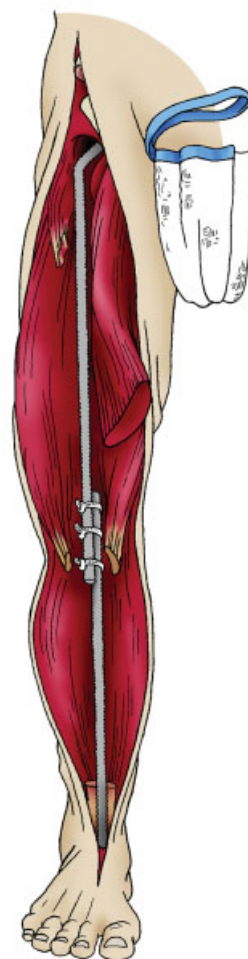
The individual components allow an assembly that adapts to the donor limb size, and it is important to pay attention to the lower limb length symmetry before securing the components with nylon clamps (►**Fig. 5**).

The volumetric difference after the removal of bony and tendinous structures is even more evident in the lower limbs, requiring the use of a greater number of surgical compresses, mainly in the knee region, to obtain an aesthetically acceptable result.

After closing the skin with cotton suture, the limbs are individually bandaged with crepe material and then bandaged together to keep them in neutral rotation.

## Conclusion

The reconstruction method of musculoskeletal tissues donor limbs developed by the Bone Bank from Paraná is a low-cost, versatile for transportation option with good aesthetic result.



**Fig. 5** Internal structure of the assembled lower limb.

## Conflict of Interests

The authors have no conflict of interests to declare.

## References

- 1 Pompeu MH, Silva SS, Roza BA, Bueno SM. Factors involved in the refusal to donate bone tissue. *Acta Paul Enferm* 2014;27(04): 380–384
- 2 de Alencar PG, Vieira IF. Banco de ossos. *Rev Bras Ortop* 2015;45 (06):524–528