


REVIEW ARTICLE

The anatomical basis for transcutaneous auricular vagus nerve stimulation

Mohsin F. Butt¹,  Ahmed Albusoda,¹ Adam D. Farmer^{2,3} and Qasim Aziz¹¹*The Wingate Institute of Neurogastroenterology, The Blizzard Institute, Barts and The London School of Medicine and Dentistry, Queen Mary University of London, Whitechapel, London, UK*²*Institute of Applied Clinical Sciences, University of Keele, Keele, UK*³*Department of Gastroenterology, University Hospitals of North Midlands NHS Trust, Stoke on Trent, UK*

Abstract

The array of end organ innervations of the vagus nerve, coupled with increased basic science evidence, has led to vagus nerve stimulation (VNS) being explored as a management option in a number of clinical disorders, such as heart failure, migraine and inflammatory bowel disease. Both invasive (surgically implanted) and non-invasive (transcutaneous) techniques of VNS exist. Transcutaneous VNS (tVNS) delivery systems rely on the cutaneous distribution of vagal afferents, either at the external ear (auricular branch of the vagus nerve) or at the neck (cervical branch of the vagus nerve), thus obviating the need for surgical implantation of a VNS delivery device and facilitating further investigations across a wide range of uses. The concept of electrically stimulating the auricular branch of the vagus nerve (ABVN), which provides somatosensory innervation to several aspects of the external ear, is relatively more recent compared with cervical VNS; thus, there is a relative paucity of literature surrounding its operation and functionality. Despite the increasing body of research exploring the therapeutic uses of auricular transcutaneous VNS (tVNS), a comprehensive review of the cutaneous, intracranial and central distribution of ABVN fibres has not been conducted to date. A review of the literature exploring the neuroanatomical basis of this neuromodulatory therapy is therefore timely. Our review article explores the neuroanatomy of the ABVN with reference to (1) clinical surveys examining Arnold's reflex, (2) cadaveric studies, (3) fMRI studies, (4) electrophysiological studies, (5) acupuncture studies, (6) retrograde tracing studies and (7) studies measuring changes in autonomic (cardiovascular) parameters in response to auricular tVNS. We also provide an overview of the fibre composition of the ABVN and the effects of auricular tVNS on the central nervous system. Cadaveric studies, of which a limited number exist in the literature, would be the 'gold-standard' approach to studying the cutaneous map of the ABVN; thus, there is a need for more such studies to be conducted. Functional magnetic resonance imaging (fMRI) represents a useful surrogate modality for discerning the auricular sites most likely innervated by the ABVN and the most promising locations for auricular tVNS. However, given the heterogeneity in the results of such investigations and the various limitations of using fMRI, the current literature lacks a clear consensus on the auricular sites that are most densely innervated by the ABVN and whether the brain regions secondarily activated by electrical auricular tVNS depend on specific parameters. At present, it is reasonable to surmise that the concha and inner tragus are suitable locations for vagal

modulation. Given the therapeutic potential of auricular tVNS, there remains a need for the cutaneous map of the ABVN to be further refined and the effects of various stimulation parameters and stimulation sites to be determined.

Key words: Acupuncture therapy; Autonomic nervous system; Cadaver; Cardiovascular system; Cranial nerves; Electrical stimulation; Magnetic resonance imaging; Neuroanatomy; Pain; Vagus nerve; Vagus nerve stimulation.

Correspondence

Mohsin F. Butt, *The Wingate Institute of Neurogastroenterology, Centre for Neuroscience Surgery and Trauma, The Blizzard Institute, Barts and The London School of Medicine and Dentistry, Queen Mary University of London, 26 Ashfield Street, Whitechapel, London E1 2AJ, UK. E: m.f.butt@smd14.qmul.ac.uk*

Dr. Adam D. Farmer, FRCP PhD and Prof. Qasim Aziz, FRCP PhD are joint senior authors.

Received 7 May 2019; Revised 25 October 2019; Accepted for publication 25 October 2019

Article published online 19 November 2019

Background

The autonomic nervous system (ANS) via its sympathetic and parasympathetic divisions influences the function of numerous organs, glands and involuntary muscles throughout the body. A major component of the parasympathetic nervous system is the vagus nerve, the 10th and longest of the cranial nerves, which serves an important bidirectional conduit between the body and brain, largely serving to maintain homeostasis. Derived from the Latin word meaning 'wandering', the vagus nerve courses from the brainstem to the proximal two-thirds of the colon, innervating multiple thoracic and abdominal viscera *en route*. It is a mixed nerve composed of 20% efferent fibres and 80% afferent fibres (Bonaz et al. 2018).

Imbalances in the activity of the constituent parts of the ANS have been linked with several clinical disorders (Farmer et al. 2016): heart failure (De Ferrari et al. 2011), inflammatory bowel disease (Ghia et al. 2006) and chronic pain syndromes (Farmer et al. 2014). In general, the reported imbalance involves relatively higher sympathetic activity associated with a paucity of parasympathetic activity (Farmer et al. 2016). In conjunction with deep slow-paced breathing, tVNS has been proposed as novel non-pharmacological analgesic intervention for pain management (Botha et al. 2014; Farmer & Aziz, 2015). In healthy subjects, we have previously demonstrated that central sensitisation can be prevented by physiological stimulation of the vagus nerve, using deep slow-paced breathing, in a validated model of oesophageal pain hypersensitivity (Botha et al. 2015). Therefore, efforts to therapeutically rebalance this equilibrium with techniques such as vagus nerve stimulation (VNS), which putatively increases the activity of the vagus nerve, are of interest across a range of clinical disciplines.

Both invasive (surgically implanted) and non-invasive (transcutaneous) techniques of VNS exist. Invasive VNS (iVNS) involves the surgical implantation of a programmable pulse generator device in the chest wall and the placement of electrodes around the left (typically) cervical vagus nerve. As it currently stands, iVNS has several potential risks. There are reports of bradycardia and asystole occurring during intraoperative lead testing, as a result of unintentional direct stimulation of the cardiac branches of the vagus nerve, occurring in approximately 1 in 1000 implantations (Asconape et al. 1999). In the direct postoperative period, implantation can result in a peri-incisional haematoma, dyspnoea and localised infection around the wound site (Fahy, 2010). Up to two-thirds of patients suffer from transient dysphonia and some patients can experience paraesthesia and pain (Watkins et al. 1995; Malow et al. 2000; Santos, 2003). Further information on iVNS, which is outside the scope of this article, is available elsewhere (Farmer et al. 2016).

Novel non-invasive (or transcutaneous) VNS delivery systems rely on the cutaneous distribution of vagal fibres,

either at the external ear (auricular branch of the vagus nerve) or at the neck (cervical branch of the vagus nerve), thus obviating the need for surgical implantation and facilitating further investigations across a wide range of uses (Ben-Menachem et al. 2015). Functional magnetic resonance imaging (fMRI) of the brain has demonstrated that tVNS can stimulate brain areas consistent with the contemporaneously accepted understanding of central vagal projections (Frangos et al. 2015). Several devices can deliver tVNS. For example, the NEMOS® (CerboMed, Erlangen, Germany) stimulates the concha of the outer ear and is CE-marked (European Conformity) for the European market for the management of epilepsy. The electrode is connected to a stimulating box, and the stimulation intensity can be adjusted by the patient, caregiver or treating physician (increased at steps of 0.1 mA until the perception threshold of the electrical stimulation is reached; the stimulation frequency is predefined at 25 Hz, the pulse width of 250 µs). The hand-held stimulator gammaCore (Electrocore LLC, Basking Ridge, NJ, USA) is used in transcutaneous stimulation of the cervical branch of the vagus nerve and is approved by the Food and Drug Administration for the management of episodic cluster headache (Mwamburi et al. 2017). The device produces a pulsatile waveform (1-ms pulses comprising 5-Hz sine waves repeated at 25 Hz). The recommended duration of stimulation is 2 min and can be administered several times (up to 12 times) a day (Holle-Lee & Gaul, 2016). Recognised side-effects of tVNS can include local skin irritation from electrode placement, headache and nasopharyngitis (Redgrave et al. 2018). A common side-effect of cervical tVNS is painless, mild facial twitching (Holle-Lee & Gaul, 2016).

Although Eastern medicine has utilised the analgesic effects of auricular acupuncture for thousands of years (Asher et al. 2010; He et al. 2012; Usichenko et al. 2017), the concept of electrically stimulating the auricle is a more recent one (Ventureyra, 2000). The feasibility of auricular tVNS was first demonstrated using recordings of vagus somato-sensory evoked potentials from the scalp (Fallgatter et al. 2003) and since then has been proposed as an effective therapeutic strategy in the management of several clinical disorders including epilepsy (Rong et al. 2014), depression (Kong et al. 2018), migraine (Straube et al. 2015) and tinnitus (Hyvarinen et al. 2015). The basis of auricular tVNS is the cutaneous representation of the auricular branch of the vagus nerve (ABVN), also termed Arnold's nerve, which provides somatosensory innervation to the external ear. The latter name of the nerve is an eponym for the German anatomist Friedrich Arnold (1803–1890), who was the first to document that irritation of the posterior wall of the external acoustic meatus could induce a cough reflex in humans (Lekakis, 2003). The ABVN is sometimes referred to as Alderman's nerve; a reference to the centuries-old Aldermen of the City of London and their practice of using rosewater bowls at ceremonial banquets,

where attendees were encouraged to place a napkin moistened with rosewater behind their ears in the belief that this would aid digestion (Murray et al. 2016). Studies have shown that the ear–cough reflex occurs in between 1.7–4.2% of individuals (Bloustine et al. 1976; Gupta et al. 1986; Tekdemir et al. 1998). The ABVN is additionally credited as the afferent pathway to other somewhat unusual somato-visceral reflexes, including (1) the gastro-auricular phenomenon, (2) the pulmono-auricular phenomenon, (3) the auriculo-genital reflex and (4) the auriculo-uterine reflex (Engel, 1979; Gupta et al. 1986).

The ABVN continues to be an area of pathophysiological interest across a number of clinical disciplines. As research into the use of auricular tVNS is rapidly growing, a review exploring the anatomical basis of this neuromodulatory technique is timely. To date, there has been no review of the literature investigating the anatomical basis of the ABVN, with reference to its cutaneous, intracranial and central distribution. Our overall aim was to address the aforementioned gap in the literature.

Anatomy of the external ear

The construction of devices for auricular tVNS relies on a precise knowledge of the anatomy and cutaneous innervation of the external ear. Fig. 1 outlines a schematic diagram of the external ear and the current consensus on the cutaneous map of the nerve fibres innervating the lateral auricle, although this dermatome map should be interpreted with caution. Indeed, a precise cutaneous map of the external ear is not practical for several reasons: (1) the cutaneous distribution of a particular nerve root can vary

considerably, (2) some nerve fibres cross-communicate with other nerve fibres along their intracranial course and (3) the boundaries between particular dermatomes are not necessarily distinct and often overlap. The challenges of producing a precise cutaneous map of the auricle and the inter-study variability in the distribution of ABVN fibres are explored herein.

Most of the commercially available devices used for auricular tVNS target the concha of the external ear (Bermejo et al. 2017; Redgrave et al. 2018), whose innervation is complicated by multiple neural communications of partly somatogenic and branchiogenic origin: the ABVN, the auriculotemporal nerve – a sensory branch of the posterior division of the mandibular division of the trigeminal nerve (Schmalfuss et al. 2002), the facial nerve, the greater auricular nerve and the lesser occipital nerve. The latter two nerves are superficial branches of the cervical plexus, contributed by fibres from the C2 and C3 spinal nerves (Ginsberg & Eicher, 2000).

Evolutionary and embryological development of the ABVN

The auricle (visible part of the ear that resides outside of the head) is formed by contributions from the first two pharyngeal (or branchial) arches – the mandibular and hyoid – whereas the external auditory meatus (which extends from the deepest part of the concha to the tympanic membrane) is formed from the first pharyngeal groove. The pharyngeal arches arise in the 4th week of embryonic development and act as precursors for head and neck structures. The depressions between the pharyngeal arches are known as

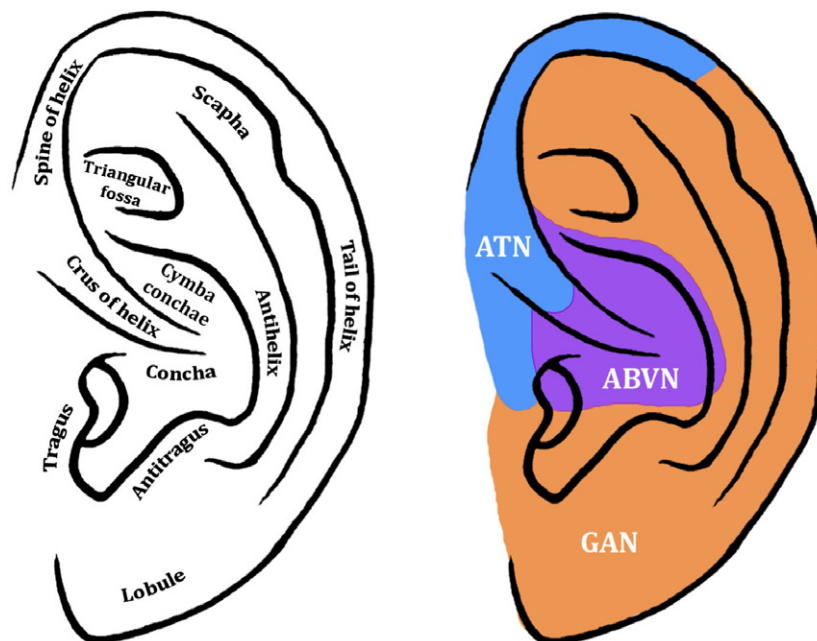


Fig. 1 Diagram of the external ear and its hypothesised cutaneous innervation. Permissions: No permissions required

pharyngeal grooves and are composed of ectoderm, itself a precursor to skin. The surface depressions between the pharyngeal arches on the endodermal surface will form the pharyngeal pouches. The ABVN is the remnant of a more extensive embryonic nerve which once supplied the first pharyngeal arch (Gupta et al. 1986) and is thought to be derived from nerves supplying the lateral line organs (a system of sense organs used to detect movement, vibration and pressure gradient in surrounding water) in aquatic vertebrates, such as fish (Hoagland, 1933; Engel, 1979). A comprehensive review exploring the embryologic development of the external ear is provided elsewhere (Wright, 1997).

Classical studies exploring the cutaneous distribution of the ABVN

It was Friedrich Arnold who, after discovering the ear–cough reflex, conducted a dissection which confirmed that the ABVN served as the afferent pathway of this unusual reflex (Arnold, 1831). However, it was not until Sherrington (1857–1952) applied his technique of ‘remaining aesthesia’ that a more refined sensory map of the ABVN and other cranial and cervico-brachial nerve roots supplying the outer ear materialised (Sherrington, 1898). After severing the trigemini and the highest three cervical nerves in the vertebral canal of two macaques, Sherrington noted sensitive skin in ‘practically the whole of the concha, the antitragus, part of the tragus and part of the antihelix; also part of the fossa of the antihelix’. He concluded with ‘little doubt’ that the sensitive skin was supplied by the un-severed vagus nerve, which was otherwise impossible to section, as this rendered the animal lame. Findings ‘extremely like those of Sherrington on the macaque’ were later reported in a human study conducted by Temple Fay (1895–1963) following a subtotal avulsion of the posterior root of the trigemini (section of the outer and lower two-thirds of the posterior root) and intracranial section of the posterior root of the vagus in a patient with intractable pain in the ear and throat due to a metastatic tongue carcinoma (Fay, 1927). Fay reported that sectioning of the trigeminal nerve caused analgesia ‘that was complete over the tragus, anterior wall of the internal auditory canal [and] over the cheek in the third divisional area’. Sectioning of the trigeminal nerve followed by the vagus root caused the cutaneous area of anaesthesia to enlarge ‘from the base of the tragus and anterior wall of the internal auditory canal to include the posterior wall, the concha and, to a slight degree for pain only, the antihelix and antitragus’.

Contemporary studies exploring the cutaneous distribution of the ABVN

Clinical surveys

Several clinical surveys have suggested the external acoustic meatus (EAM) as a region innervated by the ABVN and

therefore a potential site for auricular tVNS to be effectively delivered. In one such study (Gupta et al. 1986), 21 of 500 (4.2%) randomly selected outpatients had a clinically positive Arnold’s ear–cough reflex when the posterior and inferior quadrants of the EAM were palpated, and the reflex could also be elicited by palpating the anterior quadrant of the EAM in 10 (2%) patients. Similarly, Tekdemir et al. (1998) demonstrated Arnold’s ear–cough reflex in 11 of 514 (2.1%) patients after palpating the postero-inferior aspect of the EAM and one (0.2%) patient after palpating the antero-inferior aspect of the EAM. Although the frequencies are different, these crude clinical surveys suggest that it is anatomically possible for the ABVN to be distributed to the anterior and posterior walls of the EAM, with the posterior wall likely to have a denser innervation of ABVN fibres compared with the anterior wall.

Cadaveric studies

A list of cadaveric studies that have examined the cutaneous and intracranial course of the ABVN is outlined in Table 1. In an attempt to discern the cutaneous and intracranial course of the ABVN, Tekdemir et al. (1998) demonstrated that ABVN fibres innervated the EAM; however, those authors were unable to determine the precise sensory map of these fibres, as the terminal branches of the ABVN were ‘extremely fine’ and may have been destroyed during dissection. In a Japanese study (Kiyokawa et al. 2014), the nerve distribution around the EAM and the auricle, as well as the intracranial relationships between the ABVN, facial and glossopharyngeal nerves, were determined. That study revealed the antero-superior aspect of the EAM to be innervated by the auriculotemporal nerve, and the inferior wall by the greater auricular nerve. In comparison, the postero-superior wall of the acoustic meatus was innervated by two types of nerve branches, both of which originated from the superior ganglion of the vagus nerve. The outcomes of such cadaveric studies provide further evidence supporting the suggestion that the EAM, and particularly its posterior aspect, may be a suitable location to deliver auricular tVNS.

In addition to the EAM, there is cadaveric evidence that the inner tragus and skin surrounding the cymba concha may be innervated by the ABVN. One dissection study – arguably the most cited piece of work in the field of auricular tVNS – performed on 7 German cadavers (14 ears) systematically reported the sensory map of the lateral auricle (Peucker & Filler, 2002). Nevertheless, there are several apparent inconsistencies in this study which limit the interpretability of its findings (Burger & Verkuil, 2018). Importantly, there are contradictions between the outcomes described in the main text and those listed in the manuscript’s table regarding the innervation of the antihelix, the tragus and the cavity of the concha. According to the original table in the manuscript, Peucker & Filler (2002) report the tragus to be

Table 1 A summary of cadaveric studies that have assessed the intracranial and/or cutaneous map of the auricular branch of the vagus nerve (ABVN).

Reference	Number of cadavers (sex if available)	Mean age of cadavers (range if available)	Number of ears	Summary of salient findings in relation to the ABVN
(Ueno et al. 1993)	2m, 1f	71m (70–72)65f (65)	5 (3m, 2f)	<ul style="list-style-type: none"> • A branch of the vagus nerve, together with a branch of the facial nerve, supply the posterior parts of the external acoustic meatus in humans
(Tekdemir et al. 1998)	18m	57 (49–71)	16	<ul style="list-style-type: none"> • The ABVN was observed in the external acoustic meatus in all specimens, although it was not possible to discern its precise cutaneous map • In its course to the mastoid canaliculus (which conveys the ABVN from the jugular foramen to the facial canal), the ABVN ran in a partial bony canal in 18% of specimens
(Peuker & Filler, 2002)	7 (m and f)	N/A (68–84)	14	<ul style="list-style-type: none"> • There are conflicting results in the table and the main text, which are explored in this review article
(Kiyokawa et al. 2014)	7m, 4f	79.6 (N/A)	18	<ul style="list-style-type: none"> • The postero-superior wall of the external acoustic meatus was innervated by nerve branches that emerged from the tympano-mastoid fissure in 17/18 specimens • Nerve branches that emerged from the tympano-mastoid fissure always crossed the facial canal and had more than one communicating branch with the facial nerve inside the canal (17/17) or in the petrous bone (1/17). These branches originated from the superior ganglion of the vagus nerve • In the origin from the vagus nerve, some of these branches communicated with the glossopharyngeal nerve (3/17)
(Watanabe et al. 2016)	3	N/A	6	<ul style="list-style-type: none"> • In 6/6 specimens, the ABVN and facial nerve were exposed in the mastoid bone • The two main branches of the ABVN were dissected over the chorda tympani nerve and facial nerve, and the small branch arising from the ABVN distal segment and connecting with the chorda tympani was found

Permissions: No permissions are required.

ABVN, Auricular branch of the vagus nerve; f, female; M, male.

innervated by the ABVN in 45% of the exposed auricles. However, in the main text, the authors state that the tragus is innervated either by the greater auricular nerve (45% of all exposed auricles) or by the auriculotemporal nerve (9%), or by both of these nerves (46%). The main text does not mention that the tragus is innervated by the ABVN, and this is inconsistent with their table (Burger & Verkuil, 2018).

Contemporary cadaveric studies have detailed the intracranial course of the ABVN and its inter-neural connections with the glossopharyngeal, trigeminal and facial

nerves (Tekdemir et al. 1998; Kiyokawa et al. 2014; Watanabe et al. 2016). After arising from the superior jugular ganglion, the ABVN is soon accompanied by fibres from the inferior ganglion of the glossopharyngeal nerve. The ABVN then passes outwards behind the bulb of the internal jugular vein, and ascends through the mastoid canaliculus on the lateral surface of the jugular fossa (Proctor, 1989) or runs in a groove on the inferior aspect of the temporal bone (Guild, 1953). In the mastoid, it courses over the fallopian canal approximately 4–5 mm above the stylomastoid

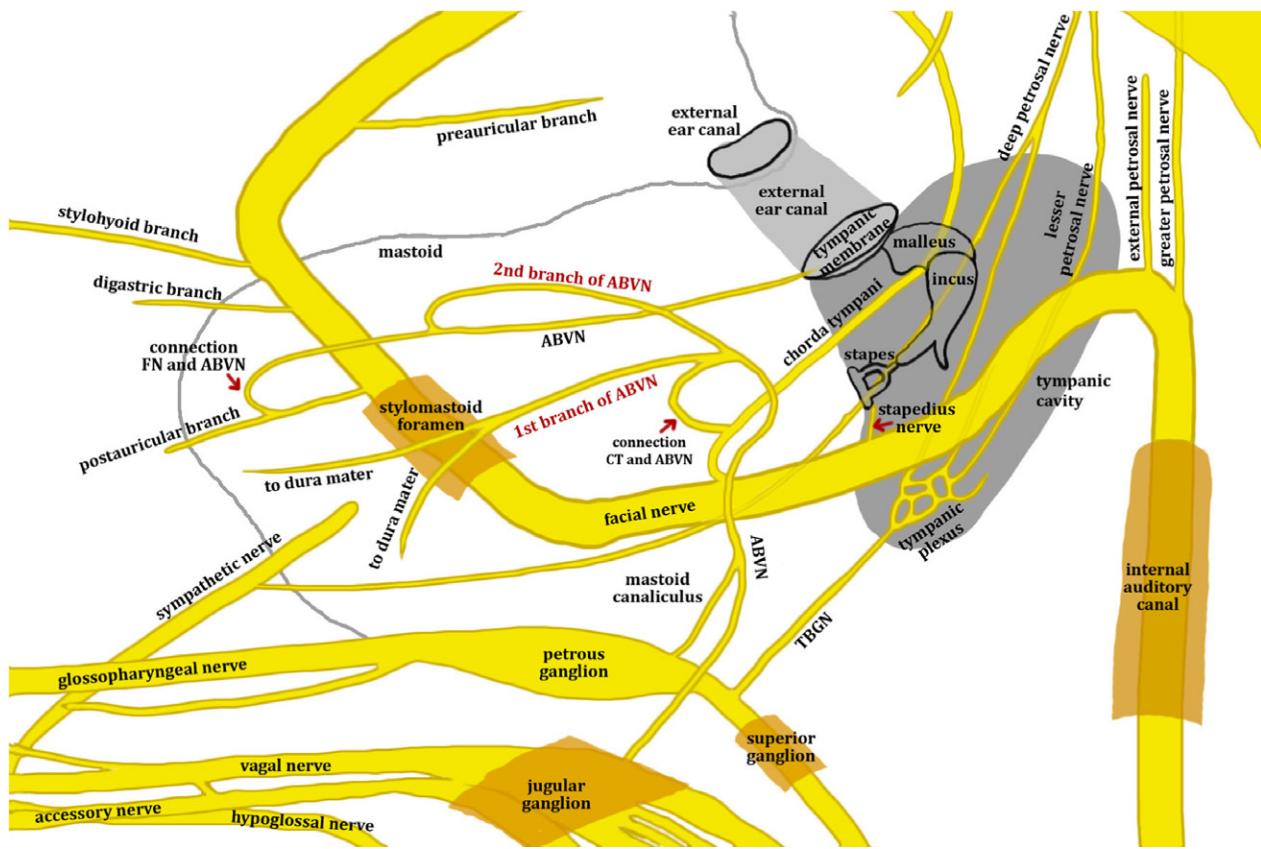


Fig. 2 A schematic diagram of the approximate relationships between the facial, glossopharyngeal and vagus nerves. The ABVN originates from the petrous ganglion of the glossopharyngeal nerve and jugular ganglion of the vagus nerve and ascends through the mastoid canaliculus. In the mastoid, it crosses the fallopian canal 3–4 mm above the stylomastoid foramen and divides into two branches. The first branch of the ABVN has a connection with the chorda tympani and supplies the sensory part of the posterior cranial fossa dura mater, while the second branch supplies the posterior skin of the external auditory meatus and adjacent tympanic membrane. The second branch also has an inferior division connecting to the posterior auricular branch of the facial nerve after exiting the stylomastoid foramen. ABVN, auricular branch of the vagus nerve; CT, chorda tympani nerve; FN, facial nerve; TBGN, tympanic branch of the glossopharyngeal nerve. *Permissions:* No permissions required.

foramen (Tekdemir et al. 1998). There it divides into two main branches. The first branch provides sensory innervation to the dura mater of the posterior cranial fossa and has a connection with the chorda tympani, a branch of the facial nerve (Watanabe et al. 2016). The second branch divides into two smaller nerves, one connecting to the posterior auricular nerve – a branch of the facial nerve – and the second innervating the postero-inferior skin of the external auditory canal and the adjacent tympanic membrane (Watanabe et al. 2016). The second branch also has an inferior division connecting to the posterior auricular branch of the facial nerve after exiting the stylomastoid foramen (Watanabe et al. 2016). A schematic diagram of the relationships between the various cranial nerves is given in Fig. 2. For a detailed description of the relationship between the facial nerve and ABVN we direct the reader to the review by Diamond et al. (2010).

To summarise, there is considerable heterogeneity in the outcomes of cadaveric studies investigating the cutaneous distribution of the ABVN. Outcomes from cadaveric studies

make it tempting to speculate that the EAM, and in particular the posterior aspect, is supplied by the ABVN; this would be reasonable as Arnold's cough reflex has been consistently evoked in clinical studies by touching the inferoposterior wall of the ear canal (Gupta et al. 1986; Tekdemir et al. 1998). Nevertheless, fMRI evidence (see below) does not suggest that the posterior wall of the ear canal is a suitable site for ABVN stimulation, and these studies generally accept the inner tragus (Dietrich et al. 2008; Kraus et al. 2013; Yakunina et al. 2017; Badran et al. 2018b) and cymba concha (Frangos et al. 2015; Yakunina et al. 2017; Wang et al. 2018) as active sites for vagal modulation, as supported by the cadaveric study conducted by Peuker & Filler (2002).

Functional magnetic resonance imaging (fMRI)

Utilising fMRI, it may be possible to compare the brain structures activated by auricular tvNS with ivNS, making it a useful surrogate modality for discerning the cutaneous

Table 2 A summary of functional magnetic resonance imaging (fMRI) studies that have investigated the brain regions secondarily activated by auricular transcutaneous vagal nerve stimulation.

Reference	<i>n</i>	Subjects	Location of auricular stimulation	Location of sham stimulation	Parameters	Key findings	Effect on the autonomic nervous system (cardiovascular parameters)	One-line summary
(Kraus et al. 2007)	22	Healthy controls	Left external acoustic meatus on the inner side of the tragus	Earlobe	20 μ s 8 Hz 30 s On 120 s Off	Tragus vs. Control: <ul style="list-style-type: none"> BOLD-signal \downarrow in limbic and temporal brain areas, including bilateral amygdala, parahippocampal gyrus, precuneus region, middle temporal gyrus, posterior cingulate cortex, paracentral lobe, superior frontal gyrus and the left hippocampus BOLD-signal \uparrow in the insula and precentral gyrus on both sides and in the right thalamus (ventral lateral nucleus) and right anterior cingulate cortex 	<ul style="list-style-type: none"> There were no significant differences in heart rate and blood pressure (before vs. after auricular tVNS) in the experimental vs. control group (unpublished data) 	<ul style="list-style-type: none"> Auricular tVNS at the left external acoustic meatus on the inner side of the tragus shares brain activation patterns observed during invasive vagal nerve stimulation
(Dietrich et al. 2008)	4	Healthy controls	Inner wall of the left tragus	No (compared with baseline)	250 μ s 25 Hz 50 s On 100 s Off	Tragus vs. baseline: <ul style="list-style-type: none"> BOLD-signal \uparrow in left locus coeruleus, thalamus (left \gg right), left prefrontal cortex, right and left postcentral gyrus, left posterior cingulate gyrus and left insula BOLD-signal \downarrow in right nucleus accumbens and right cerebellar hemisphere 	<ul style="list-style-type: none"> Not reported 	<ul style="list-style-type: none"> Auricular tVNS at the inner wall of the left tragus is appropriate for accessing cerebral vagus nerve structures
(Kraus et al. 2013)	16	Healthy controls	Inner wall of the left tragus vs. posterior side of the left ear canal	Earlobe	20 μ s 8 Hz 30 s On 60 s Off	Tragus vs. Control <ul style="list-style-type: none"> BOLD-signal \uparrow in the left insula and in the left medial frontal gyrus Significantly less activation during anterior stimulation as compared with sham stimulation in the left parahippocampal gyrus. Furthermore, there was a tendency toward the same effect in the left posterior and the right thalamus pulvinar, which both failed to be significant Posterior side of the left ear canal vs. sham <ul style="list-style-type: none"> Significantly less activation during posterior stimulation vs. sham stimulation in the left and right superior frontal gyrus, the right medial frontal gyrus, and the left subgenual cingulate Tendency toward the same effect in the left anterior cingulate and the left uncus which both failed to be significant Anterior side of the left ear canal vs. posterior side <ul style="list-style-type: none"> In most cortical areas, BOLD-signal changes were in the opposite direction when comparing anterior vs. posterior stimulation of the 	<ul style="list-style-type: none"> Not reported 	<ul style="list-style-type: none"> Vagal afferents can be stimulated at the outer canal of the ear, especially if done at the anterior side of the external acoustic meatus

(continued)

Table 2 (continued)

Reference	<i>n</i>	Subjects	Location of auricular stimulation	Location of sham stimulation	Parameters	Key findings	Effect on the autonomic nervous system (cardiovascular parameters)	One-line summary
(Frangos et al. 2015)	12	Healthy controls	L cymba concha	Earlobe	250 μ s 25 Hz 7 min On 11 min Off	<p>left auditory canal. The only exception was in the insular cortex, where both stimulation types evoked positive BOLD-signal changes</p> <p>Anterior versus posterior stimulation</p> <ul style="list-style-type: none"> In most brain regions, stimulation of the anterior wall leads to higher BOLD-signal changes vs. posterior wall In the left parahippocampal gyrus, the left posterior cingulate and the right thalamus pulvinar, the effect was the other way round, i.e. posterior stimulation evoked higher BOLD-signal changes vs. anterior stimulation <p>Brain stem regions</p> <ul style="list-style-type: none"> In the brain stem areas (locus coeruleus, solitary tract), effects were only found when comparing stimulations of the anterior wall with sham stimulation, with a stronger BOLD signal decrease during anterior stimulation <p>Cymba concha vs. control</p> <ul style="list-style-type: none"> BOLD-signal \uparrow ipsilateral nucleus of the solitary tract, bilateral spinal trigeminal nucleus, dorsal raphe, locus coeruleus, and contralateral parabrachial area, amygdala, and nucleus accumbens BOLD-signal \uparrow paracentral lobule bilaterally BOLD-signal \downarrow hippocampus and hypothalamus 	<ul style="list-style-type: none"> No significant effect on heart rate (unpublished data) 	<ul style="list-style-type: none"> The cymba concha is a biologically active site for auricular tVNS
(Yakunina et al. 2017)	37	Healthy controls	The left inner tragus, left inferoposterior wall of the ear canal, left cymba concha	Earlobe	500 μ s 25 Hz 6 min On 90 s Off	<ul style="list-style-type: none"> Stimulation of the inferoposterior wall of the ear canal produced the weakest activation of the nucleus of solitary tract and locus coeruleus Stimulation of the inner tragus and cymba concha activated nucleus of solitary tract and locus coeruleus as compared to sham Only stimulation of the cymba concha produced a significantly stronger activation in the nucleus of solitary tract and locus coeruleus vs. sham stimulation <p>Tragus vs. control</p> <ul style="list-style-type: none"> BOLD-signal \uparrow right caudate, bilateral anterior cingulate, cerebellum, left prefrontal 	<ul style="list-style-type: none"> No subjects experienced bradycardia (heart rate < 60 bpm) or abnormal cardiac behavior during the auricular tVNS course 	<ul style="list-style-type: none"> Both the cymba concha and inner tragus are active vagal sites, however, the cymba concha is the more biologically active site
(Badran et al. 2018b)	17	Healthy controls	Left tragus	Earlobe	500 μ s 25 Hz 60 s On 60 s Off	<p>Tragus vs. control</p> <ul style="list-style-type: none"> BOLD-signal \uparrow right caudate, bilateral anterior cingulate, cerebellum, left prefrontal 	<ul style="list-style-type: none"> Results published in a separate article (Badran et al. 2017) 	<ul style="list-style-type: none"> The inner tragus is an active vagal stimulation site

(continued)

Table 2 (continued)

Reference	<i>n</i>	Subjects	Location of auricular stimulation	Location of sham stimulation	Parameters	Key findings	Effect on the autonomic nervous system (cardiovascular parameters)	One-line summary
						cortex, and mid-cingulate gyrus	with a different group of healthy participants (<i>n</i> = 15) • Auricular tVNS resulted in a 1.1 beats per minute mean reduction in heart rate (<i>P</i> < 0.05)	

The number of subjects, location of stimulation, site of sham stimulation, parameters of stimulation and pertinent findings are listed for each study.

Permissions: No permissions are required.

map of the ABVN. A summary of fMRI studies that have been conducted to date and the auricular sites reported to engage the classical vagal centres is given in Table 2. fMRI studies of iVNS (Bohning et al. 2001; Lomarev et al. 2002; Narayanan et al. 2002; Liu et al. 2003; Nahas et al. 2007) and auricular tVNS (see Table 2) have reported activity within the same afferent vagal projection sites. The cell bodies of (human) afferent vagal nerve fibres are housed in the inferior vagal ganglion, thence projecting centrally to the brainstem where their processes terminate primarily in the nucleus of the solitary tract (Berthoud & Neuhuber, 2000; Knowles & Aziz, 2009).

The nucleus of the solitary tract receives approximately 95% of projections from the vagus nerve (Magdaleno-Madrigo et al. 2002; Lulic et al. 2009) and in turn projects to several other forebrain, limbic and brainstem sites, including the spinal trigeminal nucleus, parabrachial area, dorsal raphe, periaqueductal gray, thalamus, amygdala, insula, nucleus accumbens, bed nucleus of the stria terminalis, and hypothalamus (Sawchenko, 1983; Ruggiero et al. 2000; Knowles & Aziz, 2009). Importantly, the nucleus of the solitary tract projects to the locus coeruleus, the major noradrenergic brain structure in the brain that is thought to mediate several of the therapeutic effects underlying VNS (Fornai et al. 2011; Yakunina et al. 2017). Both the nucleus of the solitary tract and locus coeruleus are the assumed key targets of auricular tVNS (Keute et al. 2018b) and activation of these brainstem structures can be considered (indirect) proof of vagal activity.

The outcomes of fMRI studies presented in Table 2 demonstrate considerable heterogeneity in the brain regions secondarily activated by auricular tVNS, which may be a result of differences in sex distribution, frequencies of stimulation and locations of outer-ear stimulation: the inner wall of the tragus (Kraus et al. 2007; Dietrich et al. 2008; Kraus et al. 2013; Yakunina et al. 2017; Badran et al. 2018b), the posterior aspect of the ear canal (Kraus et al. 2013) and

the cymba concha (Frangos et al. 2015; Yakunina et al. 2017; Wang et al. 2018). Indeed, there is evidence that different sites on the external ear can activate vagal centres to different degrees (Yakunina et al. 2017). In one study (Yakunina et al. 2017), stimulation at the posterior aspect of the ear canal failed sufficiently to activate the locus coeruleus and nucleus of the solitary tract, which indicates that the vagal pathway was not sufficiently activated at this location. On the other hand, the same study showed that stimulation at the inner wall of the tragus and cymba concha successfully activated the vagal afferent pathway, with the greatest activation seen at the cymba concha, suggesting that this is the most promising site for auricular tVNS (Yakunina et al. 2017). In another study (Kraus et al. 2013), a head-to-head assessment of BOLD-signal changes secondary to tVNS at the anterior vs. posterior wall of the auditory canal, revealed BOLD-signal decreases in the locus coeruleus and nucleus of the solitary tract following stimulation at the anterior wall of the auditory canal, whereas stimulation at the posterior wall resulted in non-specific changes of the BOLD-signal within the solitary tract. The fMRI findings that the posterior wall of the ear canal is an unlikely site of ABVN innervation is interesting, as Arnold's cough reflex has consistently been evoked in clinical surveys following physical stimulation at the inferoposterior wall of the ear canal (Gupta et al. 1986; Tekdemir et al. 1998). It is therefore likely that the cutaneous distribution of the ABVN exhibits significant heterogeneity, which is supported by the findings from dissection studies (see section on Cadaveric studies).

The nucleus of the solitary tract is indirectly and directly connected to a network of brain regions, including the amygdala and nucleus accumbens, which are postulated to influence the pathogenesis of depression (Mayberg, 1997; Mayberg et al. 1999; Dagey et al. 2011). Thus, there may be a basis for the use of tVNS in managing depressive symptoms (Liu et al. 2016). fMRI can be used to investigate the

relationship between changes in resting-state functional connectivity (rsFC) secondary to tVNS. rsFC measures the temporal dependency of neuronal activation patterns between anatomically separated brain regions during rest (Biswal et al. 1995), which allows a study of the functional correlation of one brain region with other brain regions in terms of networks (Fang et al. 2016). Studies on patients with depression have demonstrated aberrant rsFC between the amygdala – the brain region implicated in emotional processing, fear and motivation – and regions in the frontal cortex, and that this is related to overall depression severity (Tang et al. 2013; Cullen et al. 2014; Pannekoek et al. 2014). In one study ($n = 49$, patients with mild/moderate depression), tVNS applied at the auricular concha area of both ears simultaneously (30 min, carried out twice a day, at least 5 days per week, for a 4-week duration) compared with sham stimulation (superior scapha) resulted in increased rsFC between the right amygdala and left dorsolateral prefrontal cortex (Liu et al. 2016).

The 'gold-standard' sham stimulation site in fMRI studies

A sham stimulation site – the ear lobe in the majority of published reports – ensures that the pattern of brain changes observed by fMRI are not caused by the conscious perception of touch, pressure, vibration or pain that may accompany auricular tVNS. A gold-standard sham location should meet the following two (non-exhaustive) criteria: (1) the site should not be innervated by ABVN fibres and (2) both the tVNS and sham operations should be clinically indistinguishable to the patient.

The earlobe has been widely used as a sham as it is thought to be relatively free of vagal afferents (Peuker & Filler, 2002; Yakunina et al. 2017) and innervated by the greater auricular nerve – a branch of the superficial cervical plexus. However, stimulation of the earlobe is not physiologically inert and has been shown to produce similar fMRI patterns to ABVN stimulation. In one tVNS study, several regions of the limbic system were deactivated by both sham stimulation (applied at the earlobe) and tVNS (applied at the inner surface of the tragus, inferoposterior wall of the external acoustic meatus and cymba concha): namely, the hippocampus, the posterior cingulate gyrus, parahippocampal gyrus and amygdala (Yakunina et al. 2017). Low-intensity stimulation of the earlobe can be used as part of cranial electrotherapy stimulation, an FDA-approved therapeutic strategy for the management of insomnia, depression and anxiety (Feusner et al. 2012). fMRI analyses of the neurophysiological changes induced by cranial electrotherapy stimulation have revealed negative BOLD changes in several brain regions, including the precuneus, posterior cingulate gyrus, precentral and postcentral gyri, and occipital cortex (Feusner et al. 2012). Several of these brain regions have

also been affected in the published tVNS fMRI studies (see Table 2).

Limitations and future potential of fMRI

fMRI is a useful surrogate modality for determining the sites most likely innervated by the ABVN, granted that its use has several limitations. First, it is impossible to demonstrate conclusively that the observed fMRI patterns are a direct cause of stimulation of the ABVN, as definitive proof would require direct nerve recordings and systematic cadaveric studies. Secondly, researchers should appreciate that stimulation of the earlobe is not physiologically inert and can produce very similar fMRI patterns to ABVN stimulation, although there is no substantial published evidence to date that the locus coeruleus and nucleus of the solitary tract (central vagal relay centres) are activated by electrical stimulation of the earlobe (Frangos et al. 2015; Yakunina et al. 2017). Therefore, there remains a need to research the 'gold-standard' sham site to ensure that accurate conclusions can be drawn from the effects found. Thirdly, the challenges of employing fMRI are compounded by swallowing artefacts, subject motion, heart rate and breathing, which can make it challenging to image small brainstem structures, such as the locus coeruleus, measuring (approximately) 1 mm at the widest in the axial plane (Keren et al. 2009). Therefore, researchers using fMRI in auricular tVNS studies should remember to use advanced fMRI techniques that can permit a closer study of these small brainstem regions. Lastly, fMRI studies have employed a range of stimulation techniques with heterogeneous parameters (e.g. frequency, on-off cycle and current intensity), stimulation durations and control sites. Therefore, a clear consensus on the precise auricular sites that allow access to the vagus nerve and whether the brain regions that are secondarily activated depend on specific parameters has yet to be determined.

There is a paucity of high-quality head-to-head fMRI trials of tVNS applied at the three most likely sites of ABVN innervation: tragus vs. posterior aspect of the ear canal vs. cymba concha. Such investigations would help to discern the region most densely innervated by the ABVN and the most promising sites for tVNS. It would be worthwhile if future head-to-head fMRI studies also studied peripheral biomarkers, such as autonomic variables (e.g. heart rate and blood pressure) and behavioural changes, as these are some of the variables through which tVNS can exert its therapeutic benefits in clinical practice. Hitherto, functional connectivity studies conducted on patients with mild/moderate depression have identified the cymba concha as a suitable location to modulate brain connectivity, although there is still insufficient evidence that this is due to vagal activity, and future studies may want to consider electrical stimulation at other auricular sites.

Interestingly, no fMRI study to date has described an ear–cough reflex following electrical auricular tVNS, which highlights the rarity of this phenomenon. There is some evidence that the ear–cough reflex is associated with hypersensitivity of vagal nerve afferents (sensory neuropathy of the vagus nerve), which may be responsible for idiopathic or refractory cough (Ryan et al. 2014). Therefore, since fMRI studies have used healthy participants, it is unlikely that the ear–cough phenomenon would be observed at a rate similar to the estimated population prevalence of 1.7–4.2% (Bloustine et al. 1976; Gupta et al. 1986; Tekdemir et al. 1998).

Retrograde tracing studies

fMRI studies have demonstrated activation of the nucleus of the solitary tract and locus coeruleus (the central vagal relay centres that are assumed to be the key targets of auricular tVNS), following electrical auricular tVNS at specific auricular points. However, this pattern of fMRI changes may not necessarily be truly unique to vagus activation, and it is possible that these effects are mediated by the two other nerves supplying the external ear, namely, the greater auricular and auriculotemporal nerves. Retrograde tracing studies (necessarily conducted in animal models) can help

to clarify the central terminations of the ABVN, greater auricular and auriculotemporal temporal nerve afferent fibres.

Central projections of the greater auricular nerve in animals have been examined only in rabbit ($n = 18$) by means of transganglionic transport of horseradish peroxidase (HRP) (Liu & Hu, 1988). HRP applied to the cut central end of the greater auricular nerve was detected ipsilaterally in the dorsal root ganglion cells (C2–C3) and the superior cervical ganglion cells. The transganglionically labelled fibres were also noted in the dorsal column of the upper four segments of the spinal cord and were strongly stained in laminae I–V at the C2 level. The afferent greater auricular nerve projections also had intense staining in the cranial nerve nuclei in the medulla, accounting for caudal subnuclei of the spinal trigeminal nerve, the solitary nucleus, and also medial and lateral cuneate nuclei (Liu & Hu, 1988).

Studies on central termination of the auriculotemporal have been conducted in rodent models (Jacquin et al. 1982; Takemura et al. 1987). HRP-labelled primary afferent fibres of the auriculotemporal nerve were confined to the ipsilateral brainstem. The nerve terminals projected to the caudal medulla; specifically staining the dorsolateral border of the mandibular division of the trigeminal principal nucleus, cuneate nucleus and also paratrigeminal nucleus (Pa5).

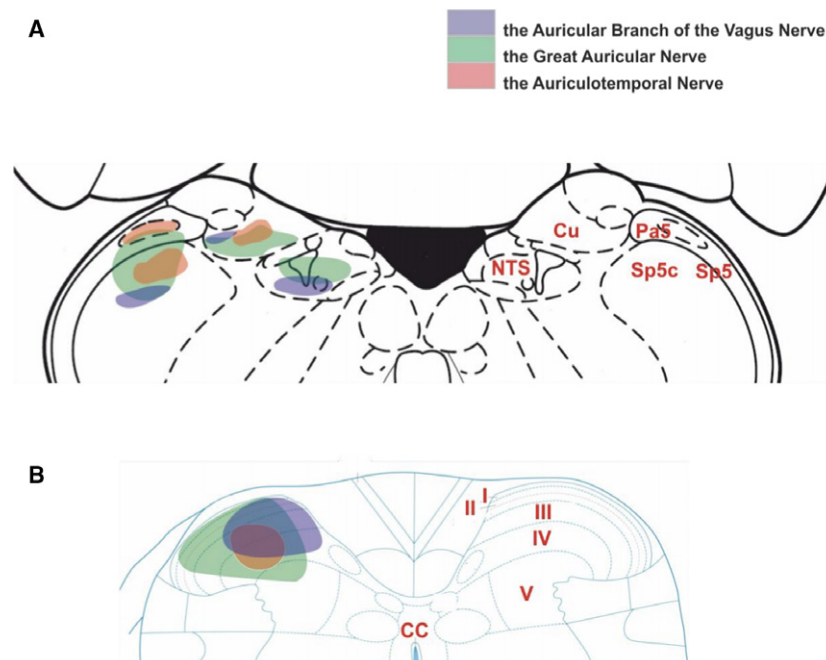


Fig. 3 A schematic diagram of external auricle afferent projections to the brainstem and upper cervical spinal cord. (A) In the brainstem, the greater auricular nerve (green) projects into the trigeminal tract, cuneate nucleus and a little in the nucleus of the solitary tract. The auriculotemporal nerve (red) terminates in the trigeminal tract, caudal trigeminal nucleus and cuneate nucleus. The ABVN (blue) is projected into the nucleus of the solitary tract, cuneate nucleus, and caudal trigeminal nucleus. (B) Projection of the greater auricular nerve into upper cervical cord has wide coverage from laminae I to laminae V, and smaller coverage by the auriculotemporal nerve concentrated in the laminae III–IV. The ABVN afferents terminate in the laminae I–IV. The level central nervous axis was omitted for clarity. *Permissions:* We wish to thank Prof. Jim Deuchars (University of Leeds) and Dr Mohd Kaisan Bin Mahadi for providing this figure. No formal permissions required.

Table 3 A comparison between neuronal tracing studies of the nerves supplying the lateral auricle (the ABVN, the greater auricular nerve and the auriculotemporal nerve) and the cervical vagal trunk.

Study	Reference	Location of injection	Tracer	Species	NTS			Vagal			Trigeminal			Cervical				
					L	D	Comm	M	D	I	V	DVN	Pa5	SP5n	SP5	C1	C2	C3
Non-isolated ABVN	(Chien et al. 1996)	Middle and caudal auricle	Horseradish peroxidase	Dogs	+							+	+	+	+	+	+	+
	(He et al. 2013)	Auricular concha	Cholera toxin B	Rats	+							+				+	+	+
Isolated ABVN	(Nomura & Mizuno, 1984)	ABVN	Horseradish peroxidase	Cats	+	+			+		+	+	+	+	+	+	+	+
Vagal nerve	(Kalia & Sullivan, 1982)	Cervical vagal trunk	Horseradish peroxidase	Rats	+	+	+		+	+	+	+	+			+	+	+
	(Nomura & Mizuno, 1983)	Cervical vagal trunk	Horseradish peroxidase	Cats	+	+	+		+	+	+	+	+			+	+	+
Isolated greater auricular nerve	(Liu & Hu, 1988)	Greater auricular nerve root	Horseradish peroxidase	Rabbit								+	+	+	+	+	+	+
Isolated auriculotemporal nerve	(Takemura et al. 1987)	Auriculotemporal nerve branch	Horseradish peroxidase	Rats								+	+	+	+	+	+	+

Permissions: We wish to thank Professor Jim Deuchars (University of Leeds) and Dr Mohd Kaisan Bin Mahadi for providing this table. No formal permissions required.

L, Lateral; DL, dorsolateral; Comm, commissural; M, medial; D, dorsal; I, intermediate; V, ventral; DVN, dorsal vagal nucleus; Pa5, paratrigeminal nucleus; SP5n, spinal trigeminal nucleus; SP5, spinal trigeminal tract; AP, area postrema; Cu, cuneate nucleus.

Travelling further caudally until the 3rd cervical level, a termination of the auriculotemporal nerve was also found in the dorsolateral spinal dorsal horn complex at laminae I–V, but most intensely in III–IV (Takemura et al. 1987).

Retrograde tracing studies conducted on afferent projections from the external ear demonstrate some degree of overlap in the central nervous system (Fig. 3). All of the auricular nerve tracing studies (greater auricular nerve, auriculotemporal nerve and ABVN) ipsilaterally labelled laminae III and IV of the dorsal horn (Nomura & Mizuno, 1983; Takemura et al. 1987; Liu & Hu, 1988). Interestingly, this was not the case when vagal tracing was performed directly from the vagal trunk. A summary of the auricular vagal nerve studies and the cervical vagal studies is presented in Table 3.

Vagus somato-sensory evoked potentials (VSEPs)

The feasibility of auricular tVNS was first demonstrated using recordings of scalp potentials induced from stimulation of the inner tragus which were thought to originate from vagal nuclei, hence the term 'vagus somato-sensory evoked potentials' (VSEPs) (Fallgatter et al. 2003). Provided the reported signals arise from vagal nuclei, they may be used to compare the scalp-recorded VSEPs of auricular tVNS with iVNS, providing (in theory) a surrogate method for determining the cutaneous map of the ABVN. Table 4 outlines the result of electrophysiological studies that have

investigated scalp potentials following auricular tVNS. Researchers have consistently demonstrated three reproducible peaks (P1, N1 and P2) from C4–F4 recordings after stimulation of various regions around the tragus. This pattern of peaks has also been shown with left cervical iVNS (Usami et al. 2013).

Usami et al. (2013) recorded short-latency component VSEPs during left cervical iVNS of 25 patients with drug-resistant epilepsy and found the response to consist of four peaks (P1, N1, P2 and N2) at the scalp level. The early complexes P1–N1 of responses to direct stimulation of the vagus nerve did not disappear after the administration of a neuromuscular blocking agent (which would preclude myogenic scalp potentials). However, the later complex P2–N2 disappeared after the administration of a neuromuscular blocking agent, and thus this is a muscular component.

Leutzow et al. (2013) conducted a study investigating the artefact-free (using neuromuscular blocking agents) VSEPs elicited by auricular tVNS to the inner side of the tragus of the auricle. The scalp responses to the auricular stimulation were recorded before and after induction of general anaesthesia in 14 patients, during non-depolarising muscle relaxing agent, *cis*-atracurium (C-AR) and after recovery from C-AR under anaesthesia. Typical response curves with P1, N1 and P2 peaks were reported in all patients before and after general anaesthesia induction, which disappeared during the neuromuscular block. The authors postulated that the scalp responses reported in previous VSEP studies were a

Table 4 A summary of electrophysiological studies that have investigated vagus somatosensory evoked potentials (VSEPs) – a measure of the activity of vagus brain stem nuclei – secondary to auricular tVNS.

Reference	n	Subjects	Location of auricular stimulation	Location of sham stimulation	Parameters	Findings
(Fallgatter et al. 2003)	5	Healthy subjects	Inner side of the tragus at the outer ventral edge of the external acoustic meatus	In a single subject only: lobulus auriculae, the scapha, the crus antihelicis superior and the top of the helix	8 mA	<ul style="list-style-type: none"> • Three reproducible peaks (P1, N1, and P2) from C4-F4 • These evoked potentials were not identified at the lobulus auriculae, the scapha, the crus antihelices superior and the top of the helix
(Fallgatter et al. 2005)	65	22 young healthy participants vs. 43 healthy elderly participants	Inner side of the tragus at the outer ventral edge of the internal auditory meatus	None	Stimulus intensity was 8 mA. Stimuli were electrical square impulses of 0.1-ms duration. The interstimulus interval was 2 s	<ul style="list-style-type: none"> • In 20/22 young participants, three identifiable peaks (P1, N1, and P2) from C4–F4 were observed with identical location, shape, latencies and amplitudes as previously described (Fallgatter et al. 2003) • Latencies of all evoked potential components (N1, P1 and N2) were significantly longer in the elderly as compared to the younger participants, while the amplitudes showed less clear-cut differences between groups
(Polak et al. 2007)	10	Patients diagnosed with Alzheimer's disease (7/10) and mild cognitive impairment (3/10)	Inner side of the tragus at the outer ventral edge of the external acoustic meatus	None	Stimulus intensity was 8 mA, the sequence of stimuli was randomised. Stimuli were electrical square impulses of 0.1 msec duration. The interstimulus interval was 2 s	<ul style="list-style-type: none"> • In 10/10 patients, VSEP with identifiable peaks P1, N1, and P2 were observed • Differences in VSEP amplitudes between Alzheimer's disease patients vs. patients with mild cognitive impairment did not reach statistical significance
(Polak et al. 2009)	20	Young healthy participants	Inner side of the tragus at the outer ventral edge of the internal auditory meatus	None	Stimuli were electrical square impulses of 0.1-ms duration with interstimulus interval of 2 s and stimulus intensity of 5, 8, and 10 mA in randomized sequence	<ul style="list-style-type: none"> • VSEP with unambiguously identifiable peaks P1, N1, and P2. Amplitudes and latencies were well in range with previous studies (Fallgatter et al. 2003, 2005; Polak et al. 2007) <ul style="list-style-type: none"> i VSEP amplitudes as well as stimulus perception increased with increasing stimulation intensity ii No difference in the VSEP amplitudes was observed between genders
(Leutzow et al. 2013)	14	Patient scheduled for elective extracranial surgery under total intravenous anaesthesia. Patients required administration of a muscle-relaxing agent	Inner side of the right tragus and to the concha of the auricle	None	Electrical square impulses with 0.1 ms with a frequency of 0.5 Hz and an intensity of 8 mA	<ul style="list-style-type: none"> • Typical response curves with P1, N1 and P2 peaks could be reproduced in all patients before and after induction of anaesthesia. • The response curves disappeared during the administration of the neuromuscular blocking agent (<i>cis</i>-atracurium) and re-appeared after recovery from <i>cis</i>-atracurium under total intravenous anaesthesia. • The disappearance of the scalp responses to electrical tragus stimulation under the neuromuscular block suggests a muscular origin of these potentials

(continued)

Table 4 (continued)

Reference	n	Subjects	Location of auricular stimulation	Location of sham stimulation	Parameters	Findings
(Nonis et al. 2017)	12	Healthy volunteers	Medial region of the tragus close to the entry of the acoustic meatus	None	Mean stimulation intensity 8 mA. 50 stimulations delivered at a frequency of 2 Hz and a pulse duration of 500 ms	Stimulation evoked two reproducible peaks (P1, N1) in nine of 12 subjects

The number of subjects, location of stimulation, site of sham stimulation, parameters of stimulation and pertinent findings are listed for each study.

Permissions: No permissions are required.

result of the activation of trigeminal or facial nerves, given the partially overlapping innervation of the auricle. The authors suggested a possible role for the occipitofrontal muscle (innervated by branches of the facial nerve) and the parietotemporal muscle (innervated by the trigeminal nerve) for the myogenic scalp potentials.

Despite the weighty evidence against the study of scalp potentials originating from vagal nuclei (VSEPs), there is little denying that VSEP studies have made important contributions to the tVNS field. A review ignoring such studies would be both incomplete, given it was a study of VSEPs that initially provided researchers with the impetus to explore this landscape (Fallgatter et al. 2003). Nevertheless, all available evidence seems to suggest that any recorded evoked potentials after auricular tVNS may be a result of facial or trigeminal nerve stimulation, and not stimulation of the vagus. Therefore, at present, there is no reason to refer to these signals as VSEPs, as the vagus likely has little to do with them. The VSEP field ought to remain an active research frontier. Indeed, postmortem studies have demonstrated that vagal nuclei are selectively vulnerable to the early pathophysiological processes of Alzheimer's (Parvizi et al. 2001) and Parkinson's diseases (Braak et al. 2003; Rietdijk et al. 2017), thus a method to assess the function of vagal nuclei, potentially by employing tVNS, may be used to detect these neurodegenerative processes in their primitive stages and permit earlier therapeutic interventions (Hagen et al. 2015).

Acupuncture studies

Eastern medicine has utilised the analgesic effects of auricular acupuncture for thousands of years (Asher et al. 2010; He et al. 2012; Usichenko et al. 2017) and numerous human studies have shown that vagal tone can be elicited by auricular acupuncture (He et al. 2012). Usichenko et al. (2017) extracted data concerning the auricular acupuncture points, used for the treatment of patients with acute and chronic pain in randomised controlled trials, from a previously

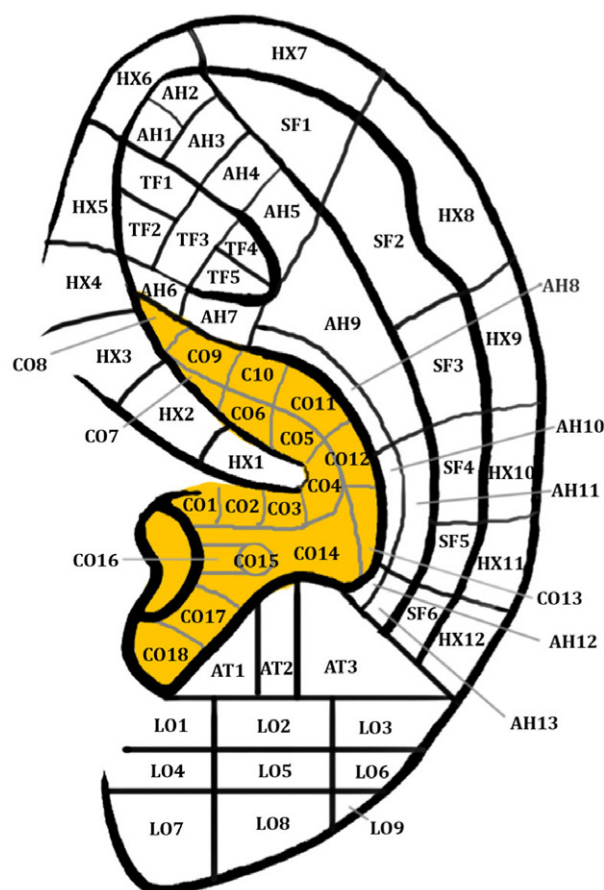


Fig. 4 Auricular acupoints. *Permissions:* No permissions required.

published meta-analysis (Asher et al. 2010). The three most frequently used auricular acupuncture points were: 'Shen-men' (TF4) (12/17 studies), located at the apex of the triangular fossa of the auricle, 'Lung' (CO14) (7/17 studies), located at the cavum concha, and thalamus (5/17 studies), located close to the antitragus (see Fig. 4). All 17 RCTs investigating the therapeutic effect of auricular acupuncture targeted the ABVN either exclusively or in a region of shared

innervation by the ABVN and greater auricular nerve, as previously reported by Peuker & Filler (2002), and that group therefore concluded that the analgesic effects of auricular acupuncture were mediated by stimulation of the ABVN.

Moreover, studies have examined the association between auricular acupoint 'Heart' (CO15), located in the cavum concha, and cardiovascular regulation (He et al. 2012). In 14 healthy volunteers, a significant decrease in heart rate and increase in heart rate variability has been observed after manual ear acupressure at auricular acupoint CO15, which is located in the cavum concha (Gao et al. 2012). Moreover, a study by Huang & Liang (1992) of auricular acupuncture at auricular acupoint CO15 in a group of 30 vascular hypertensive patients revealed a marked immediate short-term and long-term depressor effect and marked effects on angiotensin II in grade III hypertension. Interestingly, the same study reported that acupuncture at auricular acupoint 'Stomach' (located at the crus helix) produced no depressor effect on vascular hypertension, which fits with the cutaneous map of the ABVN described by Peuker & Filler (2002), in which the crus helix was innervated in 20% of cases by the ABVN (according to the table) and 0% (according to the manuscript). An acupuncture study ($n = 12$) reported that a single needle insertion in the left inferior hemi-concha of the ear resulted in a statistically significant increase in the high frequency component (an indirect measure of parasympathetic outflow) of heart rate variability both during and post-stimulation compared with pre-stimulation (Haker et al. 2000) without affecting the heart rate. A more complete analysis of heart rate variability is described later in this review article.

Autonomic nervous system – the cardiovascular system

Sympathoexcitation is a key feature of many cardiovascular diseases, such as heart failure, hypertension and obstructive sleep apnoea (Charkoudian & Rabbitts, 2009; Malpas, 2010). Device-based autonomic modulation by simultaneously decreasing sympathetic and increasing parasympathetic nervous system activity has been hypothesised to improve outcomes and quality for patients with a broad range of cardiovascular diseases (Schwartz et al. 2015). Table 5 outlines the human and animal studies that have investigated the effects of auricular tVNS applied at different locations of the auricle on various cardiovascular parameters.

Some studies noted in Table 5 refer to the autonomic variables heart rate variability (HRV), high frequency (HF) and low frequency (LF) components. HRV refers to the beat-to-beat alterations in heart rate (determined from the R-R intervals of an ECG), and several lines of evidence suggest that HRV is a marker, albeit non-specific, of autonomic tone (De Couck et al. 2017). Power spectral analysis of the R-R intervals produces two components which are

hypothesised to reflect sympathetic activity (HF component) and parasympathetic/vagus nerve activity (LF component) (Malfatto et al. 2001; Chappleau & Sabharwal, 2011).

Several studies have reported that electrical stimulation of the inner tragus, most probably due to ABVN stimulation, which is hypothesised to activate parasympathetic afferents, can modulate heart rate and HRV (Clancy et al. 2014; Badran et al. 2018c). Badran et al. (2018c) showed that (only) two parameters (500 μ s 10 Hz and 500 μ s 25 Hz) significantly decreased heart rate during active stimulation of the inner wall of the tragus compared with sham stimulation at the earlobe. Clancy et al. (2014) investigated the effects of auricular tVNS (applied to the inner and outer aspects of the tragus) on cardiovascular autonomic function in 48 healthy participants. The group found that auricular tVNS (200- μ s pulses at 30 Hz, 10–50 mA, slightly below the level at which subjects could feel the electrical stimulus) significantly decreased the LF : HF ratio of HRV, indicative of a (potential) increase in parasympathetic activity. Micrographic recordings revealed a significant decrease in frequency and incidence of muscle sympathetic nerve activity, hence stimulation of the tragus significantly reduced the incidence of firing of single sympathetic fibres. Interestingly, although the group showed a decrease in the LF : HF ratio during auricular tVNS, they did not report a statistically significant increase in the HF component (an indirect measure of parasympathetic outflow) or a statistically significant decrease in the LF component (an indirect measure of sympathetic outflow) of HRV. A study investigating the short (10 min) and prolonged (1 h) effects of auricular tVNS (right vs. left tragus) on HRV in healthy subjects ($n = 60$) showed no consistent changes in HRV, greater effects on HRV using left auricular tVNS or more consistent changes in women compared with men (De Couck et al. 2017).

Studies investigating the therapeutic potential of tVNS in sympathetic nervous system-driven disorders, such as pain and angina, have failed to demonstrate any effect of electrical auricular tVNS on cardiovascular parameters. In one study, auricular tVNS (supplied at the exhalation phase of respiration) in female patients ($n = 15$) with chronic pelvic pain reported no statistically significant change in heart rate or any HRV indices (HF, LF and LF : HF ratios) (Napadow et al. 2012). Busch et al. (2013) reported that auricular tVNS applied at the left inner tragus reduced the sensitivity of mechanically evoked pain and had an inhibitory effect on the temporal summation of noxious tonic heat in healthy volunteers. However, with regard to autonomic variables, the researchers did not show any a statistically significant change in heart rate (other HRV indices were not measured). Another study investigating the effects of electrical auricular tVNS (located on the internal surfaces of the auricle) in male patients ($n = 48$) with angina demonstrated that auricular tVNS did not cause any statistically significant changes in the LF : HF ratio (Popov et al. 2013). However, the patients had a significantly reduced number of

Table 5 The effect of auricular tVNS on various cardiovascular parameters.

Reference	Subjects	n	Sampling group	Location of auricular stimulation	Control group	Parameters	Findings
Animal studies							
Yu et al. (2013)	Dogs	16	AF	Right tragus	N/A	20 Hz, 1-ms square wavesLLTS was defined as a voltage of stimulation setting at 80% below the threshold that slowed the sinus rate or AV conduction (threshold mean: 9.8 ± 2.6 V)	<ul style="list-style-type: none"> RAP caused a significant decrease in the effective refractory period, increase in the window of vulnerability (a measure of AF inducibility), and increase in neural activity (measured in the anterior right ganglionated plexus located in the atrium) vs. baseline RAP + LLTS caused a linear return of the effective refractory period, window of vulnerability and neural activity toward baseline levels Bivagal transection prevented the reversal of the effective refractory period and window of vulnerability
Wang et al. (2014)	Dogs	30	MI	Bilateral tragus stimulation	Sham surgery without tragus stimulation	20 Hz, 1 ms square wavesLLTS was defined as a voltage of stimulation setting at 80% below the threshold that slowed the sinus rate. Actual electrical stimulation value 16–24 V (range)	<ul style="list-style-type: none"> LLTS significantly reduced left atrium and left ventricle dilatation, improved left ventricle contractile and diastolic function and reduced infarct size vs. MI group without LLTS LLTS significantly alleviated cardiac fibrosis and reduced protein expression level of collagen I, III, transforming growth factor β1, and matrix metalloproteinase 9 in LV tissues vs. MI group without LLTS LLTS significantly reduced the plasma level of high-specific C-reactive protein, norepinephrine and N-terminal pro-B-type-natriuretic peptide vs. MI group without LLTS
Chen et al. (2015a)	Dogs	15	AF	Right tragus	Sham surgery for RAP and no tragus stimulation	20 Hz, 1-ms square wavesLLTS was defined as a voltage of stimulation setting at 80% below the threshold that slowed the sinus rate (mean threshold value/ actual electrical stimulation range unreported)	<ul style="list-style-type: none"> LLTS significantly shortened AF duration and prolonged AF cycle length vs. RAP group without LLTS RAP reduced the level of atrial Cx40 and Cx43 expression, which was prevented by low level tragal stimulation. Cx40 and Cx43 are two connexons which form gap junctions (which permit the intercellular exchange of ions) between myocardial cells
Chen et al. (2015b)	Dogs	32	AF	Left tragus	Sham surgery for RAP and no tragus stimulation	20 Hz, 1 ms square wavesLLTS was defined as a voltage of stimulation setting at 80% below the threshold that slowed the sinus rate (mean threshold value/ actual electrical stimulation range unreported)	<ul style="list-style-type: none"> LLTS significantly shortened AF duration and prolonged AF cycle length RAP reduced the level of atrial Cx40 and Cx43 expression, which was prevented by low level tragal stimulation
Zhou et al. (2016)	Dogs	16	Tachycardia	Right tragus	Sham surgery without stimulation	20 Hz, 2-millisecond pulse widthLLTS was defined as a voltage of stimulation setting at 80% below the threshold that slowed the sinus rate (mean threshold value/ actual electrical stimulation range unreported)	<ul style="list-style-type: none"> LLTS significantly attenuated the sympathetically induced sinus node acceleration in response to right stellate ganglion stimulation vs. baseline LLTS did not result in significant changes in blood pressure, heart rate, QT interval, QT_c interval or HF component vs. baseline LLTS resulted in a significant reduction in the LF component and LF/HF ratio vs. baseline LLTS decreased the expression of c-fos, nerve growth factor and increased the expression of the potassium ion channel SK2 at both the mRNA and protein level in the right stellate ganglion vs. control group

(continued)

Table 5 (continued)

Reference	Subjects	n	Sampling group	Location of auricular stimulation	Control group	Parameters	Findings
Human studies Zamotrinsky et al. (1997)	Humans	20	Preoperative coronary artery disease patients	Bilateral cymba concha	Patients with a similar degree of coronary artery disease not treated with auricular tVNS	0.2–1.5 mA, 1.5 ms, 3 Hz	<ul style="list-style-type: none"> Patients treated with auricular tVNS did not develop angina at rest or after moderate physical load, and their dependence on vasodilators decreased considerably vs. baseline Atrial tissue from patients treated with auricular tVNS had reduced HSP 70i and reduced ATP vs. control group
Zamotrinsky et al. (2001)	Humans	38	Preoperative coronary artery disease patients	Bilateral cymba concha	Untreated patients with coronary artery disease	0.2–1.5 mA, 1.5 ms, 3 Hz	<p>Relative to baseline, patients treated with auricular tVNS had:</p> <ul style="list-style-type: none"> A significantly decreased heart rate, systolic blood pressure, QRS- and QT-interval periods A significantly increased left ventricular ejection fraction and improved diastolic filling A significantly reduced dependency on glycerol trinitrate tablets Patients treated with tVNS had a significantly reduced number of noradrenergic nerves in the atrial tissues vs. control group
Popov et al. (2013)	Humans	48	Coronary artery disease patients	Bilateral cymba concha	Untreated patients with coronary artery disease	0.05–0.15 mA	<p>Relative to baseline, patients treated with auricular tVNS had:</p> <ul style="list-style-type: none"> Alleviation of angina symptoms Significantly reduced LF/HF index and frequency of ventricular extrasystoles
Clancy et al. (2014)	Humans	48	Healthy	Right tragus	Healthy patients who did not undergo auricular tVNS	200 ms, 30 Hz	<p>Relative to baseline, patients treated with auricular tVNS had:</p> <ul style="list-style-type: none"> No significant change in the LF and HF components of HRV A significant reduction in the LF/HF ratio A significant increase in HRV Microneurographic recordings revealed a significant decrease in frequency and incidence of muscle sympathetic nerve activity during tVNS
Stavarakis et al. (2015)	Humans	40	Paroxysmal atrial fibrillation	Right tragus	Patients with atrial fibrillation who did not undergo auricular tVNS	1 ms, 20 Hz	<p>Relative to baseline, experimental group participants:</p> <ul style="list-style-type: none"> Had a significantly decreased duration of pacing-induced atrial fibrillation Had a significantly increased atrial fibrillation cycle length Significantly reduced levels of systemic (femoral vein) but not coronary sinus TNF-α and CRP levels
De Couck et al. (2017)	Humans	60	Healthy	Right or left concha	Patients not treated with auricular tVNS	0.7 mA, 250 μ s, 25 Hz	<ul style="list-style-type: none"> Relative to baseline, experimental group participants had no consistent changes in HRV as a result of acute (10 min) or prolonged (1 h) auricular tVNS. Compared with left auricular tVNS, right auricular tVNS had more effects on HRV and these changes could be found more consistently in women than in men

Permissions: No permissions are required.

AF, Atrial fibrillation; AV, atrioventricular; HF, high frequency component of heart rate variability; LF, low frequency; LLTS, low level electrical transcutaneous tragal stimulation; RAP, rapid atrial pacing.

ventricular extrasystoles (at both time points) compared with baseline.

Several observations could explain the inconsistent effects of auricular tVNS on HRV parameters. Different groups have used different stimulation sites, e.g. the concha (De Couck et al. 2014) and tragus (Clancy et al. 2014), and studies have also employed different stimulation parameters, which could activate vagal afferents to different degrees. Moreover, auricular tVNS operates via a complex indirect system of brain regions and nuclei (see section on fMRI studies), hence the effects of auricular tVNS on HRV may be minimal (De Couck et al. 2017). The complex nature of LF power, its poor relationship to sympathetic nerve activation, and the non-linear interactions between sympathetic and parasympathetic activity that are confounded by the mechanical effects of respiration and heart rate mean that the LF: HF sympatho-vagal balance hypothesis is inaccurate (Billman, 2013; Shaffer & Ginsberg, 2017). Therefore, it is challenging to determine the cutaneous map of the ABVN using the current evidence base investigating the autonomic effects of auricular tVNS.

Hitherto, it has been unclear whether the autonomic effects of auricular tVNS are the result of the activation of

the hypothesised afferent central targets of the vagus system (ear → brain → vagus nerve → organ) or whether there is direct activation of the efferent vagal projections from the ear to body organs (ear → vagus → heart) (Murray et al. 2016; Fig. 5). Afferent ABVN fibres are thought to modulate neuronal activity in the nucleus of the solitary tract, dorsal vagal nucleus, nucleus ambiguus, caudal ventrolateral medulla and rostroventral medulla (Fig. 6). An investigation of the role of afferent and efferent vagal fibres in mediating the therapeutic effect of tVNS would benefit from *in vivo* microelectrode recording of nerve dissections in animal models, or in animal models where the ABVN is lesioned.

ABVN fibre composition

Thick afferent A β axons have been consistently shown to mediate the therapeutic effects of cervical iVNS (Evans et al. 2004). Group C nerve fibres (C-fibres) are not thought to be involved in mediating the physiological effects of VNS. In a study investigating the therapeutic effect of iVNS in stimulation-induced seizures in rats, capsaicin-induced destruction of peripheral C-fibre populations did not alter the

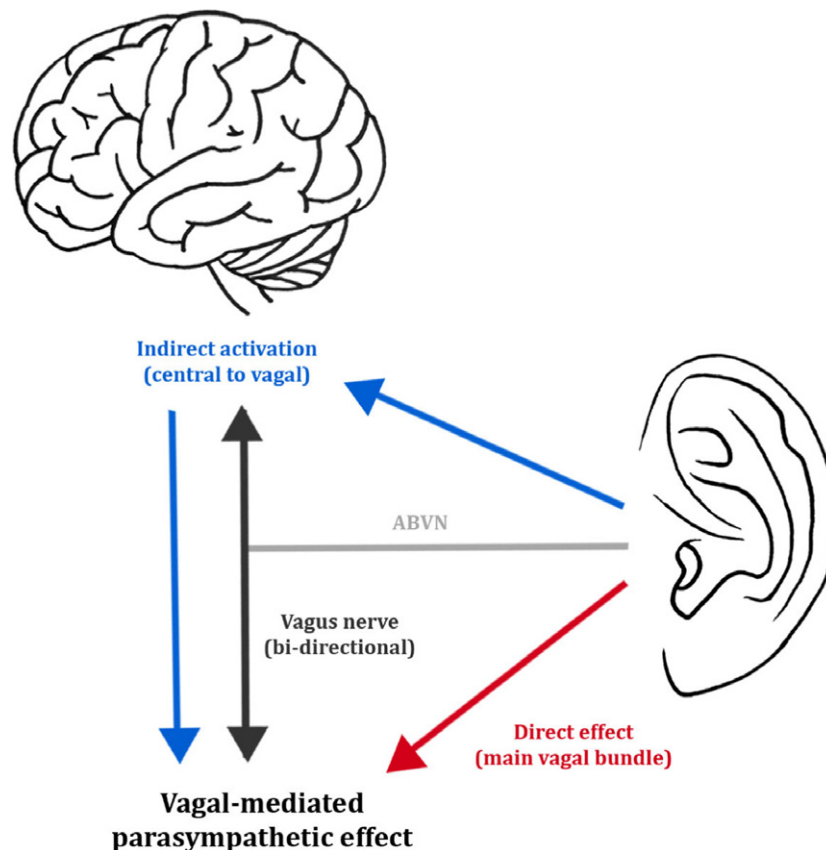


Fig. 5 Two possible mechanisms for parasympathetic activation via the auricular branch of the vagus nerve (ABVN). The blue arrows represent the activation of vagal afferents and stimulation of the main vagal bundle via the central nervous system. The red arrow represents the direct activation of vagal efferents and stimulation of the main vagal bundle. *Permissions:* No permissions required.

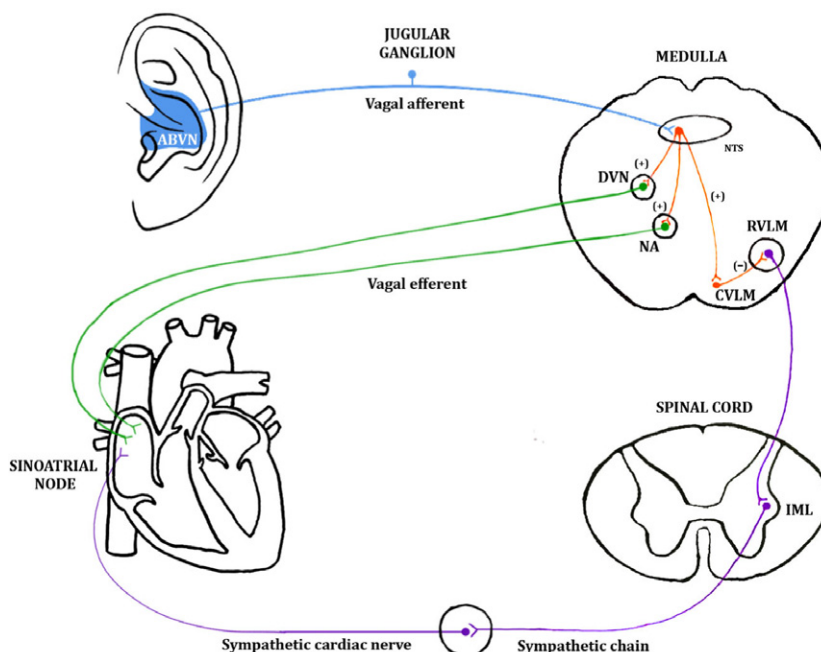


Fig. 6 A schematic diagram of one of the hypothesised pathways through which stimulation of the auricular branch of the vagus nerve (ABVN) can influence the cardiovascular system. Stimulation of the ABVN increases input to the nucleus of the solitary tract (NTS) in the medulla and influences the activity of NTS neurones projecting to the cardioinhibitory vagal efferent neurones of the dorsal vagal nucleus (DVN) and nucleus ambiguus (NA). These vagal efferent neurones propagate the vagal tone to the sinoatrial node (SA). Stimulation of the ABVN may also excite NTS neurones, sending excitatory projections to the caudal ventrolateral medulla (CVLM). The CVLM inhibits the rostromedullary nucleus (RVLM), which is the primary source of excitatory drive to sympathetic preganglionic neurones in the intermediolateral cell column (IML) of the spinal cord. This inhibition would decrease sympathetic activity. *Permissions:* No permissions required.

therapeutic mechanism of iVNS for seizure suppression in rats (Krahl et al. 2001). To our knowledge, only one study to date has determined the number of myelinated axons in the human ABVN (Safi et al. 2016). In that study, researchers investigated the numbers and caliber of myelinated axons in 18 segments of the ABVN (9 left, 9 right) in 16 German cadavers. The human ABVN was shown to contain thick myelinated axons ≥ 7 μ m belonging to the A β class, which were reportedly five to six times less numerous than those found in the cervical vagus nerve. The study (Safi et al. 2016) revealed that the number of A β myelinated axons represent, on average, about one-fifth of the total myelinated axon count and can vary widely between individuals, which may help to explain why auricular tVNS may not be effective in some patients, or indeed why the ear-cough reflex is elicited in so few people (Gupta et al. 1986; Tekdemir et al. 1998) and has not been reported in any of the fMRI studies published to date. These seminal findings may represent the anatomical basis for the clinical effectiveness of auricular tVNS.

Effects of auricular tVNS on the central nervous system (CNS)

The therapeutic mechanism of auricular tVNS and iVNS is thought to be mediated by concentration shifts of the

neurotransmitters noradrenaline, γ -aminobutyric acid (GABA) and acetylcholine (ACh) in the CNS (Van Leusden et al. 2015), which induce neuroplastic changes in the cerebral cortex. The majority of studies investigating the therapeutic mechanisms underlying VNS have studied the locus coeruleus: the major noradrenergic brain structure (Krahl et al. 1998; Van Bockstaele et al. 1999; Groves et al. 2005; Fornai et al. 2011). The first study (Capone et al. 2015) to assess the GABA-mediated mechanism of tVNS employed transcranial magnetic stimulation and demonstrated significantly reduced cortical excitability in 10 healthy participants following 1 h of tVNS at the inner side of the left tragus (relative to sham stimulation at the left ear lobe) as measured by increased short-interval intra-cortical inhibition (SICI). SICI is a transcranial magnetic stimulation protocol which is a surrogate marker of GABA_A activity within the motor cortex, and an increase in SICI suggests increased GABA neurotransmitter concentration (Stagg et al. 2011). Recently, Keute et al. (2018a) demonstrated, using 16 healthy young human volunteers, that auricular tVNS applied to the cymba concha of the left ear induced a GABAergic neuromodulation during automatic inhibition, as measured by the behavioural marker negative compatibility effect (NCE), which is robustly negatively correlated to GABA concentration (Boy et al. 2010). Interestingly, the group reported that auricular tVNS produced an increased NCE, in contradiction to the

decrease in NCE that they had hypothesised. The group postulated that GABA activity may not have increased globally by auricular tVNS but was rather differentially modified in different brain regions, as has been previously reported (Greenhouse et al. 2016).

Conclusion

Our review article has explored the neuroanatomy of the ABVN with reference to (1) clinical surveys examining Arnold's reflex, (2) cadaveric studies, (3) fMRI studies, (4) electrophysiological studies, (5) acupuncture studies, (6) retrograde tracing studies and (7) studies measuring changes in autonomic (cardiovascular) parameters in response to auricular tVNS. We have also provided an overview of the composition of the ABVN and the effects of auricular tVNS on the central nervous system. Cadaveric studies, of which a limited number exist in the literature, would be the 'gold-standard' approach to studying the cutaneous map of the ABVN and thus there is a need for more such studies to be conducted by individuals with advanced training in microdissection of the head and neck, as the ABVN diameter is only of 1 µm resolution. Teams should also consider age, ethnicity, trauma and prior health history in their selection of cadavers (Badran et al. 2018a). fMRI may (in theory) offer a useful surrogate modality for determining the auricular locations that best activate central vagal centres (when compared with the fMRI patterns observed with invasive vagal nerve stimulation), accepting that its use has several limitations. Importantly, fMRI studies cannot discern whether the observed fMRI patterns are a direct result of activation of the ABVN as opposed to the greater auricular and auriculotemporal nerves. Importantly, stimulation of the earlobe – an auricular site innervated by the greater auricular nerve and a popular auricular location for sham electrical stimulation in fMRI studies – is not physiologically inert and there is therefore a need to explore alternative sham stimulation sites. A clear consensus on the auricular sites that are most densely innervated by the ABVN and whether the brain regions secondarily activated by electrical auricular tVNS depend on specific parameters has yet to be achieved. At present, the outcomes of fMRI studies published to date make it reasonable to surmise that the concha and inner tragus are suitable locations for vagal modulation. Given the therapeutic potential of auricular tVNS (Rong et al. 2014; Hyvarinen et al. 2015; Straube et al. 2015; Kong et al. 2018), there remains a need for the cutaneous map of the ABVN to be further refined and the effects of various stimulation parameters and stimulation sites to be determined.

Acknowledgements

We are indebted to Dr Mohd Kaisan Bin Mahadi and Prof. Jim Deuchars (University of Leeds, School of Biomedical Sciences) for providing us with Fig. 3 and Table 3. We also thank Ms Reya Srivastava

(Barts and The London School of Medicine and Dentistry) for expertly drawing the figures contained in this article.

Conflict of interest

There are no known conflicts of interest associated with the publication of this work. No author received financial support.

References

- Arnold F (1831) *Der Kopftheil des vegetativen Nervensystems beim Menschen*. Heidelberg: Karl Groos.
- Asconape JJ, Moore DD, Zipes DP, et al. (1999) Bradycardia and asystole with the use of vagus nerve stimulation for the treatment of epilepsy: a rare complication of intraoperative device testing. *Epilepsia* **40**, 1452–1454.
- Asher GN, Jonas DE, Coeytaux RR, et al. (2010) Auriculotherapy for pain management: a systematic review and meta-analysis of randomized controlled trials. *J Altern Complement Med* **16**, 1097–1108.
- Badran BW, Glusman CE, Badran AW, et al. (2017) The physiological and neurobiological effects of transcutaneous auricular vagus nerve stimulation (taVNS). *Brain Stimul* **10**, 378.
- Badran BW, Brown JC, Dowdle LT, et al. (2018a) Tragus or cymba conchae? Investigating the anatomical foundation of transcutaneous auricular vagus nerve stimulation (taVNS). *Brain Stimul* **11**, 947–948.
- Badran BW, Dowdle LT, Mithoefer OJ, et al. (2018b) Neurophysiologic effects of transcutaneous auricular vagus nerve stimulation (taVNS) via electrical stimulation of the tragus: A concurrent taVNS/fMRI study and review. *Brain Stimul* **11**, 492–500.
- Badran BW, Mithoefer OJ, Summer CE, et al. (2018c) Short trains of transcutaneous auricular vagus nerve stimulation (taVNS) have parameter-specific effects on heart rate. *Brain Stimul* **11**, 699–708.
- Ben-Menachem E, Revesz D, Simon BJ, et al. (2015) Surgically implanted and non-invasive vagus nerve stimulation: a review of efficacy, safety and tolerability. *Eur J Neurol* **22**, 1260–1268.
- Bermejo P, López M, Larraya I, Chamorro J, Cobo JL, Ordóñez S, Vega JA (2017). Innervation of the human cavum conchae and auditory canal: anatomical basis for transcutaneous auricular nerve stimulation. *Biomed Res Int* **2017**, 1–10.
- Berthoud HR, Neuhuber WL (2000) Functional and chemical anatomy of the afferent vagal system. *Auton Neurosci* **85**, 1–17.
- Billman GE (2013) The LF/HF ratio does not accurately measure cardiac sympatho-vagal balance. *Front Physiol* **4**, 26.
- Biswal B, Yetkin FZ, Haughton VM, et al. (1995) Functional connectivity in the motor cortex of resting human brain using echo-planar MRI. *Magn Reson Med* **34**, 537–541.
- Bloustine S, Langston L, Miller T (1976) Ear-cough (Arnold's) reflex. *Ann Otol Rhinol Laryngol* **85**, 406–407.
- Bockstaele EJ van, Peoples J, Telegan P (1999) Efferent projections of the nucleus of the solitary tract to peri-locus coeruleus dendrites in rat brain: evidence for a monosynaptic pathway. *J Comp Neurol* **412**, 410–428.
- Leusden JWR van, Sellaro R, Colzato LS (2015) Transcutaneous vagal nerve stimulation (tVNS): a new neuromodulation tool in healthy humans? *Front Psychol* **6**, 102.

- Bohning DE, Lomarev MP, Denslow S, et al.** (2001) Feasibility of vagus nerve stimulation-synchronized blood oxygenation level-dependent functional MRI. *Invest Radiol* **36**, 470–479.
- Bonaz B, Bazin T, Pellissier S** (2018) The vagus nerve at the interface of the microbiota-gut-brain axis. *Front Neurosci* **12**, 49.
- Botha C, Farmer AD, Nilsson M, et al.** (2014) Preliminary report: modulation of parasympathetic nervous system tone influences oesophageal pain hypersensitivity. *Gut* **64**, 611–617.
- Botha C, Farmer AD, Nilsson M, et al.** (2015) Preliminary report: modulation of parasympathetic nervous system tone influences oesophageal pain hypersensitivity. *Gut* **64**, 611–617.
- Boy F, Evans CJ, Edden RAE, et al.** (2010) Individual differences in subconscious motor control predicted by GABA concentration in SMA. *Curr Biol* **20**, 1779–1785.
- Braak H, Rub U, Gai WP, et al.** (2003) Idiopathic Parkinson's disease: possible routes by which vulnerable neuronal types may be subject to neuroinvasion by an unknown pathogen. *J Neural Transm (Vienna)* **110**, 517–536.
- Burger AM, Verkuil B** (2018) Transcutaneous nerve stimulation via the tragus: are we really stimulating the vagus nerve? *Brain Stimul* **11**, 945–946.
- Busch V, Zeman F, Heckel A, et al.** (2013) The effect of transcutaneous vagus nerve stimulation on pain perception—an experimental study. *Brain Stimul* **6**, 202–209.
- Capone F, Assenza G, di Pino G, et al.** (2015) The effect of transcutaneous vagus nerve stimulation on cortical excitability. *J Neural Transm* **122**, 679–685.
- Chapleau MW, Sabharwal R** (2011) Methods of assessing vagus nerve activity and reflexes. *Heart Fail Rev* **16**, 109–127.
- Charkoudian N, Rabbitts JA** (2009) Sympathetic neural mechanisms in human cardiovascular health and disease. *Mayo Clin Proc* **84**, 822–830.
- Chen M, Yu L, Liu Q, et al.** (2015a) Low level tragus nerve stimulation is a non-invasive approach for anti-atrial fibrillation via preventing the loss of connexins. *Int J Cardiol* **179**, 144–145.
- Chen M, Zhou X, Liu Q, et al.** (2015b) Left-sided noninvasive vagus nerve stimulation suppresses atrial fibrillation by upregulating atrial gap junctions in canines. *J Cardiovasc Pharmacol* **66**, 593–599.
- Chien CH, Shieh JY, Ling EA, et al.** (1996) The composition and central projections of the internal auricular nerves of the dog. *J Anat* **189**, 349–362.
- Clancy JA, Mary DA, Witte KK, et al.** (2014) Non-invasive vagus nerve stimulation in healthy humans reduces sympathetic nerve activity. *Brain Stimul* **7**, 871–877.
- de Couck M, Nijs J, Gidron Y** (2014) You may need a nerve to treat pain: the neurobiological rationale for vagal nerve activation in pain management. *Clin J Pain* **30**, 1099–1105.
- de Couck M, Cserjesi R, Caers R, et al.** (2017) Effects of short and prolonged transcutaneous vagus nerve stimulation on heart rate variability in healthy subjects. *Auton Neurosci* **203**, 88–96.
- de Ferrari GM, Crijns HJ, Borggrefe M, et al.** (2011) Chronic vagus nerve stimulation: a new and promising therapeutic approach for chronic heart failure. *Eur Heart J* **32**, 847–855.
- Cullen KR, Westlund MK, Klimes-Dougan B, et al.** (2014) Abnormal amygdala resting-state functional connectivity in adolescent depression. *JAMA Psychiatry* **71**, 1138–1147.
- Dagyte G, den Boer JA, Trentani A** (2011) The cholinergic system and depression. *Behav Brain Res* **221**, 574–582.
- Diamond M, Wartmann CT, Tubbs RS, et al.** (2010) Peripheral facial nerve communications and their clinical implications. *Clin Anat* **24**, 10–18.
- Dietrich S, Smith J, Scherzinger C, et al.** (2008) A novel transcutaneous vagus nerve stimulation leads to brainstem and cerebral activations measured by functional MRI. *Biomed Tech (Berl)* **53**, 104–111.
- Engel D** (1979) The gastroauricular phenomenon and related vagus reflexes. *Arch Psychiatr Nervenkr* **1970**, 271–277.
- Evans MS, Verma-Ahuja S, Naritoku DK, et al.** (2004) Intraoperative human vagus nerve compound action potentials. *Acta Neurol Scand* **110**, 232–238.
- Fahy BG** (2010) Intraoperative and perioperative complications with a vagus nerve stimulation device. *J Clin Anesth* **22**, 213–222.
- Fallgatter AJ, Neuhauser B, Herrmann MJ, et al.** (2003) Far field potentials from the brain stem after transcutaneous vagus nerve stimulation. *J Neural Transm (Vienna)* **110**, 1437–43.
- Fallgatter AJ, Ehlis AC, Ringel TM, et al.** (2005) Age effect on far field potentials from the brain stem after transcutaneous vagus nerve stimulation. *Int J Psychophysiol* **56**, 37–43.
- Fang J, Rong P, Hong Y, et al.** (2016) Transcutaneous vagus nerve stimulation modulates default mode network in major depressive disorder. *Biol Psychiatry* **79**, 266–273.
- Farmer AD, Aziz Q** (2015) Vagally mediated analgesia: breathing during exhalation as a simple manipulation to reduce pain Perception-Reyes Del Paso et al. Pain medicine 2015. *Pain Med* **16**, 2417.
- Farmer AD, Coen SJ, Kano M, et al.** (2014) Psychophysiological responses to visceral and somatic pain in functional chest pain identify clinically relevant pain clusters. *Neurogastroenterol Motil* **26**, 139–148.
- Farmer AD, Albu-Soda A, Aziz Q** (2016) Vagus nerve stimulation in clinical practice. *Br J Hosp Med (Lond)* **77**, 645–651.
- Fay T** (1927) Observations and results from intracranial section of the glossopharyngeus and vagus nerves in man. *J Neurol Psychopathol* **8**, 110–123.
- Feusner JD, Madsen S, Moody TD, et al.** (2012) Effects of cranial electrotherapy stimulation on resting state brain activity. *Brain Behav* **2**, 211–220.
- Fornai F, Ruffoli R, Giorgi FS, et al.** (2011) The role of locus coeruleus in the antiepileptic activity induced by vagus nerve stimulation. *Eur J Neurosci* **33**, 2169–2178.
- Frangos E, Ellrich J, Komisaruk BR** (2015) Non-invasive access to the vagus nerve central projections via electrical stimulation of the external ear: fMRI evidence in humans. *Brain Stimul* **8**, 624–636.
- Gao XY, Wang L, Gaischek I, et al.** (2012) Brain-modulated effects of auricular acupuncture on the regulation of autonomic function in healthy volunteers. *Evid Based Complement Alternat Med* **2012**, 714391.
- Ghia JE, Blennerhassett P, Kumar-Ondiveeran H, et al.** (2006) The vagus nerve: a tonic inhibitory influence associated with inflammatory bowel disease in a murine model. *Gastroenterology* **131**, 1122–1130.
- Ginsberg LE, Eicher SA** (2000) Great auricular nerve: anatomy and imaging in a case of perineural tumor spread. *AJNR Am J Neuroradiol* **21**, 568–571.
- Greenhouse I, Noah S, Maddock RJ, et al.** (2016) Individual differences in GABA content are reliable but are not uniform across the human cortex. *NeuroImage* **139**, 1–7.

- Groves DA, Bowman EM, Brown VJ (2005) Recordings from the rat locus coeruleus during acute vagal nerve stimulation in the anaesthetised rat. *Neurosci Lett* **379**, 174–179.
- Guild SR (1953) The glomus jugulare, a nonchromaffin paraganglion, in man. *Ann Otol Rhinol Laryngol* **62**, 1045–1071.
- Gupta D, Verma S, Vishwakarma SK (1986) Anatomic basis of Arnold's ear-cough reflex. *Surg Radiol Anat* **8**, 217–220.
- Hagen K, Ehlis AC, Haeussinger FB, et al. (2015) The relation of SMI and the VSEP in a risk sample for neurodegenerative disorders. *J Neural Transm (Vienna)* **122**, 1167–1174.
- Haker E, Egekvist H, Bjerring P (2000) Effect of sensory stimulation (acupuncture) on sympathetic and parasympathetic activities in healthy subjects. *J Auton Nerv Syst* **79**, 52–59.
- He W, Wang X, Shi H, et al. (2012) Auricular acupuncture and vagal regulation. *Evid Based Complement Alternat Med* **2012**, 786839.
- He W, Jing XH, Zhu B, et al. (2013) The auriculo-vagal afferent pathway and its role in seizure suppression in rats. *BMC Neurosci* **14**, 85.
- Hoagland H (1933) Electrical responses from the lateral-line nerves of catfish. I. *J Gen Physiol* **16**, 695–714.
- Holle-Lee D, Gaul C (2016) Noninvasive vagus nerve stimulation in the management of cluster headache: clinical evidence and practical experience. *Ther Adv Neurol Disord* **9**, 230–234.
- Huang H, Liang S (1992) Acupuncture at otoacupoint heart for treatment of vascular hypertension. *J Tradit Chin Med* **12**, 133–136.
- Hyvarinen P, Yrttioho S, Lehtimäki J, et al. (2015) Transcutaneous vagus nerve stimulation modulates tinnitus-related beta- and gamma-band activity. *Ear Hear* **36**, e76–e85.
- Jacquin MF, Semba K, Rhoades RW, et al. (1982) Trigeminal primary afferents project bilaterally to dorsal horn and ipsilaterally to cerebellum, reticular formation, and cuneate, solitary, supratrigeminal and vagal nuclei. *Brain Res* **246**, 285–291.
- Kalia M, Sullivan JM (1982) Brainstem projections of sensory and motor components of the vagus nerve in the rat. *J Comp Neurol* **211**, 248–265.
- Keren NI, Lozar CT, Harris KC, et al. (2009) In-Vivo Mapping of the Human Locus Coeruleus. *NeuroImage* **47**, 1261–1267.
- Keute M, Ruhnau P, Heinze H-J, et al. (2018a) Behavioral and electrophysiological evidence for GABAergic modulation through transcutaneous vagus nerve stimulation. *Clin Neurophysiol* **129**, 1789–1795.
- Keute M, Ruhnau P, Zaehle T (2018b) Reply to 'Reconsidering sham in transcutaneous vagus nerve stimulation studies'. *Clin Neurophysiol* **129**, 2503–2504.
- Kiyokawa J, Yamaguchi K, Okada R, et al. (2014) Origin, course and distribution of the nerves to the posterosuperior wall of the external acoustic meatus. *Anat Sci Int* **89**, 238–245.
- Knowles CH, Aziz Q (2009) Basic and clinical aspects of gastrointestinal pain. *Pain* **141**, 191–209.
- Kong J, Fang J, Park J, et al. (2018) Treating depression with transcutaneous auricular vagus nerve stimulation: State of the Art and future perspectives. *Front Psychiatry* **9**: doi: 10.3389/fpsy.2018.00020.
- Krahl SE, Clark KB, Smith DC, et al. (1998) Locus coeruleus lesions suppress the seizure-attenuating effects of vagus nerve stimulation. *Epilepsia* **39**, 709–714.
- Krahl SE, Senanayake SS, Handforth A (2001) Destruction of peripheral C-fibers does not alter subsequent vagus nerve stimulation-induced seizure suppression in rats. *Epilepsia* **42**, 586–589.
- Kraus T, Hosl K, Kiess O, et al. (2007) BOLD fMRI deactivation of limbic and temporal brain structures and mood enhancing effect by transcutaneous vagus nerve stimulation. *J Neural Transm (Vienna)* **114**, 1485–1493.
- Kraus T, Kiess O, Hosl K, et al. (2013) CNS BOLD fMRI effects of sham-controlled transcutaneous electrical nerve stimulation in the left outer auditory canal – a pilot study. *Brain Stimul* **6**, 798–804.
- Lekakis GK (2003) Philipp Friedrich Arnold, Ludvig Levin Jacobson and their contribution to head and neck anatomy. *J Laryngol Otol* **117**, 28–31.
- Leutzow B, Lange J, Gibb A, et al. (2013) Vagal sensory evoked potentials disappear under the neuromuscular block – an experimental study. *Brain Stimul* **6**, 812–816.
- Liu D, Hu Y (1988) The central projections of the great auricular nerve primary afferent fibers – an HRP transganglionic tracing method. *Brain Res* **445**, 205–210.
- Liu WC, Mosier K, Kalnin AJ, et al. (2003) BOLD fMRI activation induced by vagus nerve stimulation in seizure patients. *J Neurol Neurosurg Psychiatry* **74**, 811–813.
- Liu J, Fang J, Wang Z, et al. (2016) Transcutaneous vagus nerve stimulation modulates amygdala functional connectivity in patients with depression. *J Affect Disord* **205**, 319–326.
- Lomarev M, Denslow S, Nahas Z, et al. (2002) Vagus nerve stimulation (VNS) synchronized BOLD fMRI suggests that VNS in depressed adults has frequency/dose dependent effects. *J Psychiatr Res* **36**, 219–227.
- Lulic D, Ahmadian A, Baaj AA, et al. (2009) Vagus nerve stimulation. *Neurosurg Focus* **27**, E5.
- Magdaleno-Madriral VM, Valdes-Cruz A, Martinez-Vargas D, et al. (2002) Effect of electrical stimulation of the nucleus of the solitary tract on the development of electrical amygdaloid kindling in the cat. *Epilepsia* **43**, 964–969.
- Malfatto G, Branzi G, Gritti S, et al. (2001) Different baseline sympathovagal balance and cardiac autonomic responsiveness in ischemic and non-ischemic congestive heart failure. *Eur J Heart Fail* **3**, 197–202.
- Malow BA, Edwards J, Marzec M, et al. (2000) Effects of vagus nerve stimulation on respiration during sleep: a pilot study. *Neurology* **55**, 1450–1454.
- Malpas SC (2010) Sympathetic nervous system overactivity and its role in the development of cardiovascular disease. *Physiol Rev* **90**, 513–557.
- Mayberg HS (1997) Limbic-cortical dysregulation: a proposed model of depression. *J Neuropsychiatry Clin Neurosci* **9**, 471–481.
- Mayberg HS, Liotti M, Brannan SK, et al. (1999) Reciprocal limbic-cortical function and negative mood: converging PET findings in depression and normal sadness. *Am J Psychiatry* **156**, 675–682.
- Murray AR, Atkinson L, Mahadi MK, et al. (2016) The strange case of the ear and the heart: The auricular vagus nerve and its influence on cardiac control. *Auton Neurosci* **199**, 48–53.
- Mwamburi M, Liebler EJ, Tenaglia AT (2017) Review of non-invasive vagus nerve stimulation (gammaCore): efficacy, safety, potential impact on comorbidities, and economic burden for episodic and chronic cluster headache. *Am J Manag Care* **23**, S317–S325.
- Nahas Z, Teneback C, Chae JH, et al. (2007) Serial vagus nerve stimulation functional MRI in treatment-resistant depression. *Neuropsychopharmacology* **32**, 1649–1660.
- Napadow V, Edwards RR, Cahalan CM, et al. (2012) Evoked pain analgesia in chronic pelvic pain patients using respiratory-

- gated auricular vagal afferent nerve stimulation. *Pain Med* **13**, 777–789.
- Narayanan JT, Watts R, Haddad N, et al.** (2002) Cerebral activation during vagus nerve stimulation: a functional MR study. *Epilepsia* **43**, 1509–1514.
- Nomura S, Mizuno N** (1983) Central distribution of efferent and afferent components of the cervical branches of the vagus nerve. A HRP study in the cat. *Anat Embryol (Berl)* **166**, 1–18.
- Nomura S, Mizuno N** (1984) Central distribution of primary afferent fibers in the Arnold's nerve (the auricular branch of the vagus nerve): a transganglionic HRP study in the cat. *Brain Res* **292**, 199–205.
- Nonis R, D'Ostilio K, Schoenen J, et al.** (2017) Evidence of activation of vagal afferents by non-invasive vagus nerve stimulation: An electrophysiological study in healthy volunteers. *Cephalalgia* **37**, 1285–1293.
- Pannekoek JN, van der Werff SJ, Meens PH, et al.** (2014) Aberrant resting-state functional connectivity in limbic and salience networks in treatment-naïve clinically depressed adolescents. *J Child Psychol Psychiatry* **55**, 1317–1327.
- Parvizi J, van Hoesen GW, Damasio A** (2001) The selective vulnerability of brainstem nuclei to Alzheimer's disease. *Ann Neurol* **49**, 53–66.
- Peuker ET, Filler TJ** (2002) The nerve supply of the human auricle. *Clin Anat* **15**, 35–37.
- Polak T, Ehlis AC, Langer JB, et al.** (2007) Non-invasive measurement of vagus activity in the brainstem – a methodological progress towards earlier diagnosis of dementias? *J Neural Transm (Vienna)* **114**, 613–619.
- Polak T, Markulin F, Ehlis AC, et al.** (2009) Far field potentials from brain stem after transcutaneous vagus nerve stimulation: optimization of stimulation and recording parameters. *J Neural Transm (Vienna)* **116**, 1237–1242.
- Popov SV, Afanasiev SA, Kurlov IO, Pisklova AV** 2013. Drug-free correction of the tone of the autonomic nervous system in the management of cardiac arrhythmia in coronary artery disease. *Int J BioMed*, **3**, 74–77.
- Proctor B** (1989) *Surgical anatomy of the ear and temporal bone*. New York: Thieme Medical Publishers.
- Redgrave J, Day D, Leung H, et al.** (2018) Safety and tolerability of transcutaneous vagus nerve stimulation in humans; a systematic review. *Brain Stimul* **11**, 1225–1238.
- Rietdijk CD, Perez-Pardo P, Garssen J, et al.** (2017) Exploring Braak's Hypothesis of Parkinson's disease. *Front Neurol* **8**, 37.
- Rong P, Liu A, Zhang J, et al.** (2014) An alternative therapy for drug-resistant epilepsy: transcutaneous auricular vagus nerve stimulation. *Chin Med J (Engl)* **127**, 300–304.
- Ruggiero DA, Underwood MD, Mann JJ, et al.** (2000) The human nucleus of the solitary tract: visceral pathways revealed with an 'in vitro' postmortem tracing method. *J Auton Nerv Syst* **79**, 181–190.
- Ryan NM, Gibson PG, Birring SS** (2014) Arnold's nerve cough reflex: evidence for chronic cough as a sensory vagal neuropathy. *J Thorac Dis* **6**, S748–S752.
- Safi S, Ellrich J, Neuhuber W** (2016) Myelinated axons in the auricular branch of the human vagus nerve. *Anat Rec* **299**, 1184–1191.
- Santos PM** (2003) Evaluation of laryngeal function after implantation of the vagus nerve stimulation device. *Otolaryngol Head Neck Surg* **129**, 269–273.
- Sawchenko PE** (1983) Central connections of the sensory and motor nuclei of the vagus nerve. *J Auton Nerv Syst* **9**, 13–26.
- Schmalzfuss IM, Tart RP, Mukherji S, et al.** (2002) Perineural tumor spread along the auriculotemporal nerve. *AJNR Am J Neuroradiol* **23**, 303–311.
- Schwartz PJ, la Rovere MT, de Ferrari GM, et al.** (2015) Autonomic modulation for the management of patients with chronic heart failure. *Circ Heart Fail* **8**, 619–628.
- Shaffer F, Ginsberg JP** (2017) An overview of heart rate variability metrics and norms. *Front Public Health* **5**, 258.
- Sherrington CS** (1898) Experiments in examination of the peripheral distribution of the fibres of the posterior roots of some spinal nerves. *Philos Trans R Soc Lond B Biol Sci* **190**, 45–186.
- Stagg CJ, Bestmann S, Constantinescu AO, et al.** (2011) Relationship between physiological measures of excitability and levels of glutamate and GABA in the human motor cortex. *J Physiol* **589**, 5845–5855.
- Stavarakis S, Humphrey MB, Scherlag BJ, et al.** (2015) Low-level transcutaneous electrical vagus nerve stimulation suppresses atrial fibrillation. *J Am Coll Cardiol* **65**, 867–875.
- Straube A, Ellrich J, Eren O, et al.** (2015) Treatment of chronic migraine with transcutaneous stimulation of the auricular branch of the vagal nerve (auricular t-VNS): a randomized, monocentric clinical trial. *J Headache Pain* **16**: 543.
- Takemura M, Sugimoto T, Sakai A** (1987) Topographic organization of central terminal region of different sensory branches of the rat mandibular nerve. *Exp Neurol* **96**, 540–557.
- Tang Y, Kong L, Wu F, et al.** (2013) Decreased functional connectivity between the amygdala and the left ventral prefrontal cortex in treatment-naïve patients with major depressive disorder: a resting-state functional magnetic resonance imaging study. *Psychol Med* **43**, 1921–1927.
- Tekdemir I, Aslan A, Elhan A** (1998) A clinico-anatomic study of the auricular branch of the vagus nerve and Arnold's ear-cough reflex. *Surg Radiol Anat* **20**, 253–257.
- Ueno N, Sudo H, Hattori Y, et al.** (1993) Innervation of the external ear in humans and the musk shrew. *Nihon Jibiinkoka Gakkai Kaiho* **96**, 212–218.
- Usami K, Kawai K, Sonoo M, et al.** (2013) Scalp-recorded evoked potentials as a marker for afferent nerve impulse in clinical vagus nerve stimulation. *Brain Stimul* **6**, 615–623.
- Usichenko T, Hacker H, Lotze M** (2017) Transcutaneous auricular vagus nerve stimulation (taVNS) might be a mechanism behind the analgesic effects of auricular acupuncture. *Brain Stimul* **10**, 1042–1044.
- Ventureyra EC** (2000) Transcutaneous vagus nerve stimulation for partial onset seizure therapy. A new concept. *Childs Nerv Syst* **16**, 101–102.
- Wang Z, Yu L, Wang S, et al.** (2014) Chronic intermittent low-level transcutaneous electrical stimulation of auricular branch of vagus nerve improves left ventricular remodeling in conscious dogs with healed myocardial infarction. *Circ Heart Fail* **7**, 1014–1021.
- Wang Z, Fang J, Liu J, et al.** (2018) Frequency-dependent functional connectivity of the nucleus accumbens during continuous transcutaneous vagus nerve stimulation in major depressive disorder. *J Psychiatr Res* **102**, 123–131.
- Watanabe K, Tubbs RS, Satoh S, et al.** (2016) Isolated deep ear canal pain: possible role of auricular branch of vagus nerve – case illustrations with cadaveric correlation. *World Neurosurg* **96**, 293–301.
- Watkins LR, Goehler LE, Relton JK, et al.** (1995) Blockade of interleukin-1 induced hyperthermia by subdiaphragmatic

- vagotomy: evidence for vagal mediation of immune-brain communication. *Neurosci Lett* **183**, 27–31.
- Wright CG** (1997) Development of the human external ear. *J Am Acad Audiol* **8**, 379–382.
- Yakunina N, Kim SS, Nam EC** (2017) Optimization of transcutaneous vagus nerve stimulation using functional MRI. *Neuro-modulation* **20**, 290–300.
- Yu L, Scherlag BJ, Li S, et al.** (2013) Low-level transcutaneous electrical stimulation of the auricular branch of the vagus nerve: a noninvasive approach to treat the initial phase of atrial fibrillation. *Heart Rhythm* **10**, 428–435.
- Zamotrinsky A, Afanasiev S, Karpov RS, et al.** (1997) Effects of electrostimulation of the vagus afferent endings in patients with coronary artery disease. *Coron Artery Dis* **8**, 551–557.
- Zamotrinsky AV, Kondratiev B, de Jong JW** (2001) Vagal neurostimulation in patients with coronary artery disease. *Auton Neurosci* **88**, 109–116.
- Zhou X, Zhou L, Wang S, et al.** (2016) The use of noninvasive vagal nerve stimulation to inhibit sympathetically induced sinus node acceleration: a potential therapeutic approach for inappropriate sinus tachycardia. *J Cardiovasc Electrophysiol* **27**, 217–223.