

A. Tipold · P. Moore · A. Zurbriggen · I. Burgener
G. Barben · M. Vandeveld

Early T cell response in the central nervous system in canine distemper virus infection

Received: 16 March 1998 / Revised, accepted: 6 July 1998

Abstract The initial demyelinating lesions in canine distemper virus (CDV) infection develop during a period of severe immunosuppression in the absence of inflammation. *In vitro* and *in vivo* studies suggest that early demyelination is due to directly virus-induced oligodendroglial changes. In the present spatiotemporal study in experimentally CDV-infected dogs we observed diffuse up-regulation of T cells throughout the central nervous system (CNS) and T cell invasion in early demyelinating lesions. Invasion of T cells in the CNS occurred despite severe immunosuppression and without any perivascular cuffing. However, the major fraction of invading T cells correlated with sites of viral replication and coincided with the demonstration of an early immune response against the nucleocapsid protein of CDV. Activation of microglial cells was thought to have elicited the migration of T cells to the CNS by secretion of chemokines: marked IL-8 activity was found in the CSF of dogs with acute lesions. In areas of early demyelination, large numbers of CD3⁺ cells accumulated in the tissue in the absence of any morphological sign of inflammation. Whether the T cells at lesion sites contribute to the development of acute demyelination remains uncertain at this stage. Antiviral cytotoxicity was not apparent since viral clearance in demyelinating lesions is only effective when B cells and concurring antiviral antibody production appeared in the subacute and chronic inflammatory stage of the disease. CD3⁺ cells appear to persist

for several weeks after infection since they were also found in recovered dogs that did not develop demyelination. Accumulation of immune cells, including a significant proportion of resting T cells (CD45RA⁺) in the CNS in the early stages of the disease may facilitate the later development of the intrathecal immune response and associated immunopathological complications.

Key words Canine distemper virus · T cells · Acute demyelination · Immunosuppression

Introduction

Canine distemper virus (CDV) induces multifocal demyelination in the central nervous system (CNS) [32] and is considered to be a model for human demyelinating diseases such as multiple sclerosis [2]. Initial non-inflammatory demyelination in distemper develops during a long period of severe virus-induced immunosuppression and is associated with viral spread and replication in the glial cells of the white matter [32, 34]. The mechanism which leads to demyelination in the immunosuppressive stage of distemper is not completely understood. We have recently found that restricted CDV infection of oligodendrocytes with down-regulation of myelin gene transcription occurs in acute demyelinating lesions [37], which had been previously observed *in vitro* [38]. Since viral infection of oligodendrocytes was only seen in a limited number of cells, this observation could not completely explain total loss of myelin in the lesions.

The view that the initial lesions in distemper are directly virus induced and, therefore, purely degenerative in nature has recently been challenged by our studies aimed at the immunophenotyping of cells in different canine CNS infections [29], which revealed the presence of lymphocytes in the CNS of an animal in the acute immunosuppressed state of canine distemper. That the CNS immune system could be somehow involved in acute distemper has been suggested by the work of Alldinger et al. [1] describing up-regulation of major histocompatibility

A. Tipold (✉) · A. Zurbriggen · I. Burgener · G. Barben
M. Vandeveld
Institute of Animal Neurology, University of Berne,
Länggass-Strasse 122, CH-3012 Berne, Switzerland
e-mail: tipold@ivv.unibe.ch,
Tel.: +41-31-6312664, Fax: +41-31-6312534

A. Tipold · I. Burgener
Institute of Veterinary Virology, University of Berne,
Berne, Switzerland

P. Moore
VM Pathology, Microbiology and Immunology,
School of Veterinary Medicine,
University of California, Davis, USA

complex (MHC) class II expression in the white matter. Because of this unexpected finding we designed a spatiotemporal study to investigate the presence of lymphocytes in the CNS of dogs during the course of the infection against the background of an antiviral immune response.

Materials and methods

Experiment 1:

Dogs for neuropathological studies

Dogs with distemper

Thirteen pure-bred specific pathogen-free (SPF) Beagle dogs had been experimentally inoculated with A75/17 CDV in two previous studies [32] and were killed between 14 and 46 days post infection (PI). Nine additional dogs with spontaneous canine distemper infection were obtained from the animal neurology service, University of Berne. In all animals infection was monitored by clinical examination, hematology and CSF examination. The immune status of most animals was evaluated by demonstration of neutralizing antibodies against CDV in serum and CSF, and lectin stimulation of peripheral lymphocytes [32] as well as lymphatic tissues at the time of euthanasia.

Control dogs

Brain tissues from 7 normal dogs between 3 months and 1 year of age from the same Beagle colony were used as controls. In addition, we examined brain tissue from 18 dogs with other inflammatory brain lesions, including central European tick-borne encephalitis, and rabies, bacterial and protozoal encephalitides. An additional control group consisted of 5 dogs with degenerative CNS diseases, including degenerative myelopathy, GM1-gangliosidosis, hereditary ataxia of Jack Russel Terriers and multisystem neuronal degeneration of Cocker Spaniels.

Immediately after death, the brain tissue of all dogs was fixed in 4% buffered formalin or paraformaldehyde and processed for paraffin embedding. Serial sections of representative brain (basal ganglia, thalamus, midbrain, cerebellum, medulla) and spinal cord areas were mounted on positively charged slides (Superfrost plus, Menzel-Gläser, Braunschweig, Germany) and used for hematoxylin-eosin (H&E) staining, immunohistochemistry and in situ hybridization (ISH). From three selected cases with distemper frozen sections were made and processed for immunohistochemistry using positively charged slides.

Demonstration of CDV-neutralizing antibodies in serum and CSF

Neutralizing antibodies against CDV had been examined in previous studies [32]. Briefly, serial dilutions of serum and CSF were incubated with aliquots of tissue culture-propagated CDV and inoculated into VERO cells grown in microtiter plates. Antibody titers correspond to the highest dilutions inhibiting cytopathological effect.

Lectin stimulation of mixed lymphocyte cultures

These studies had been performed on previous occasions [32]. Briefly, isolated peripheral lymphocytes, and lymphocyte cultures derived from lymphatic tissues at the time of euthanasia were treated with phytohemagglutinin A (PHA) and concanavalin A (Con A) in the presence of [³H]thymidine. Incorporated radioactivity as measured in a scintillation chamber reflected mitogen responsiveness.

Antibodies for immunocytochemistry

The following antibodies were used for immunohistochemical studies: mouse monoclonal antibody (mAb) D110, which binds to the major nucleocapsid (N) protein of CDV [7]; rat mAb anti-canine CD3 (CD3-12) used as a T cell marker; mouse mAb anti-canine α D beta2 (α D) (CA18.3C6), an integrin found on large granular lymphocytes or natural killer cells; mouse mAb anti-canine CD18 (CA16.3C10), an integrin, generally labeling leukocytes, was shown to be an excellent microglia label in preliminary studies; mouse mAb anti-canine CD45RA (CA21.4B3), a lymphocyte surface marker for naive or resting T cells [15] which are also found in normal CSF [28]. On frozen sections mouse mAb against the following antigens were used: CD3 (CA17.2A12), CD4 (CA13.1E4), CD8 α (CA9.JD3) to further characterize T cell subsets, CD21 (CA2.1D6) as a B cell marker and CD18 (CA1.4E9). These canine-specific antibodies against leukocyte surface markers were generated at the University of California in Davis and were reported at the first international canine leukocyte antigen workshop [11]. Additional primary antibodies included mouse mAb against canine IgG, IgA and IgM (K992E3; Serotec, purchased from Inotech, Dottikon, Switzerland) to show B lymphocytes on paraffin-embedded tissue and mouse mAb Ki-67 antigen MIB-1 (Immunotech, purchased from Milan, La Roche, Switzerland). Ki-67 is an antigen expressed in all phases of the cell cycle except G0 [12, 27] and, therefore, a marker for proliferating cells.

Secondary antibodies included goat anti-mouse IgG (own production), peroxidase anti-peroxidase (PAP) mouse monoclonal (Dako, Zug, Switzerland), biotinylated anti-rat IgG (Amersham Life Science, Zürich, Switzerland), Vectastain ABC-Kit Elite (Vector Laboratories, Geneva, Switzerland).

Immunohistochemistry

The PAP technique was used [33] for the demonstration of CDV antigen, surface Ig, CD45RA, α D, CD18, and Ki-67. Deparaffinized tissue sections, treated with trypsin or urea (CD45RA), were incubated with the primary antibodies (hybridoma supernatant) diluted 1:4 or 1:100 for surface IgA, IgG, IgM overnight at 4°C, followed by incubation with caprine polyclonal antiserum against mouse IgG diluted 1:40. Subsequently, the PAP complex (diluted 1:100) was added, followed by a colorimetric reaction with diaminobenzidine (DAB) and hydrogen peroxide. CD3 was developed after incubation overnight at 4°C using biotinylated anti-rat IgG antiserum (1:300), followed by an ABC complex (1:100) and the above-mentioned color reaction. Frozen sections were stained with PAP after a 2-min fixation in acetone. Duplicate sections were stained. Lymph node sections served as positive control for lymphocyte surface markers, and sections from a canine lymphoma served as a control for the Ki-67 marker. Negative controls included brain sections from normal dogs, and tissue sections incubated with a nonspecific primary control antibody (mouse IgG1, negative control, Dako).

In situ hybridization

ISH was performed as described [21]. Pretreated sections were hybridized overnight at 52°C using 10 ng/100 μ l hybridization solution of a digoxigenin-labeled probe complementary to the mRNA of the N protein of the virulent A75/17 CDV. Washed slides were incubated with an anti-digoxigenin antibody conjugated with phosphatase (Boehringer Mannheim, Germany), followed by development with nitro blue tetrazolium and X-phosphate (Boehringer Mannheim).

Evaluation of the tissue sections

All sections were stained and evaluated in duplicates. Sections were examined by light microscopy. Representative lesions were

identified and marked on H&E-stained sections and the same lesions were marked on consecutive serial sections processed for immunohistochemistry or ISH. Labeled cells were evaluated semi-quantitatively, counting the number of cells per microscopic field at a 100-fold magnification. In addition, labeled cells were also counted in unaffected tissue in four to five microscopic fields per slide and mean values were calculated.

Experiment 2:

Demonstration of antibodies against recombinant nucleocapsid protein of CDV

Serum samples

Serum samples were obtained from 12 CDV-seronegative 4- to 8-month-old SPF Beagle dogs of both sexes. These dogs had been inoculated intraperitoneally with 0.5 ml A75/17 CDV inoculum containing 5×10^5 tissue culture infection doses (TCID)₅₀/ml in an experiment to develop an antigen detection assay (Rhône-Mérieux company, Lyon, France). Serum samples were collected at days 0 (prior to CDV infection), 7, 14, 21 and 27 PI. All dogs developed clinical signs and most had acute CNS lesions.

Dot-blot assay for the detection of CDV-specific dog IgM

Recombinant nucleocapsid protein (N protein) of the virulent A75/17 CDV strain, produced in our laboratory, was used as antigen [24]. Purified recombinant CDV N protein (2.0 µg/ml) diluted 1:10, 1:20, and 1:40 in 0.9 M NaCl was applied as 1-µl dots (in duplicate) on nitrocellulose (NC) stripes. The dried antigen was blocked for 30 min (0.02 M TRIS pH 8.0, 0.5 M NaCl, 0.5% Tween 20, 1% milk powder) at room temperature (RT) on the shaker. Subsequently, the blocked antigen was incubated with a 1:500 dilution of test sera in washing buffer (0.9 M NaCl, 0.5% Tween, 0.02 M TRIS) for 2 h at 37°C on a shaker at 55 rpm. Afterwards, the NC stripes were thoroughly washed with washing buffer. The stripes were then incubated with a mouse mAb anti-canine IgM (CM7, IgG_k recognizing the Fc5u heavy chain region; Custom Monoclonals, Sacramento, Calif.) for 30 min at RT on a shaker. After another washing step, polyclonal goat anti-mouse antibody diluted 1:40 in washing buffer was added for 30 min at RT on a shaker. Again the stripes were washed, followed by application of a monoclonal mouse PAP antibody complex (1:100). After a further washing step, the reaction product was visualized using DAB as chromogen (1 ml DAB, 0.05 M TBS pH 7.6, 5 µl 30% H₂O₂).

Experiment 3:

Demonstration of IL-8-like activity in CSF

IL-8-like activity in the CSF was measured in 14 dogs with spontaneous CDV infection, which were presented at the Animal Neurology Service, University of Berne. All dogs were euthanized and examined neuropathologically. Seven animals had subacute to chronic inflammatory demyelination and seven were in the acute stage of the CNS disease. As a control, CSF samples of eight healthy dogs were used. Evidence for the presence of IL-8-like activity was obtained based on receptor-specific desensitization of canine neutrophilic granulocytes in repeated stimulation [5, 9]. The desensitizing activity could be completely or at least partially blocked after pre-incubation of the CSF samples with a polyclonal antibody against canine recombinant IL-8 (crIL-8), known to neutralize the chemotactic activity of crIL-8 [9, 25]. crIL-8 (Repligen Corporation, Needham, Mass.) was used in a chemotaxis assay using a 48-well microchemotaxis chamber (Neuroprobe, Cabin John, Md.) to prove that IL-8 elicits chemotactic activity for canine mononuclear cells (including about 85% lymphocytes and 15% monocytes).

Results

Experiment 1:

Neuropathological findings

Early viral invasion and spread

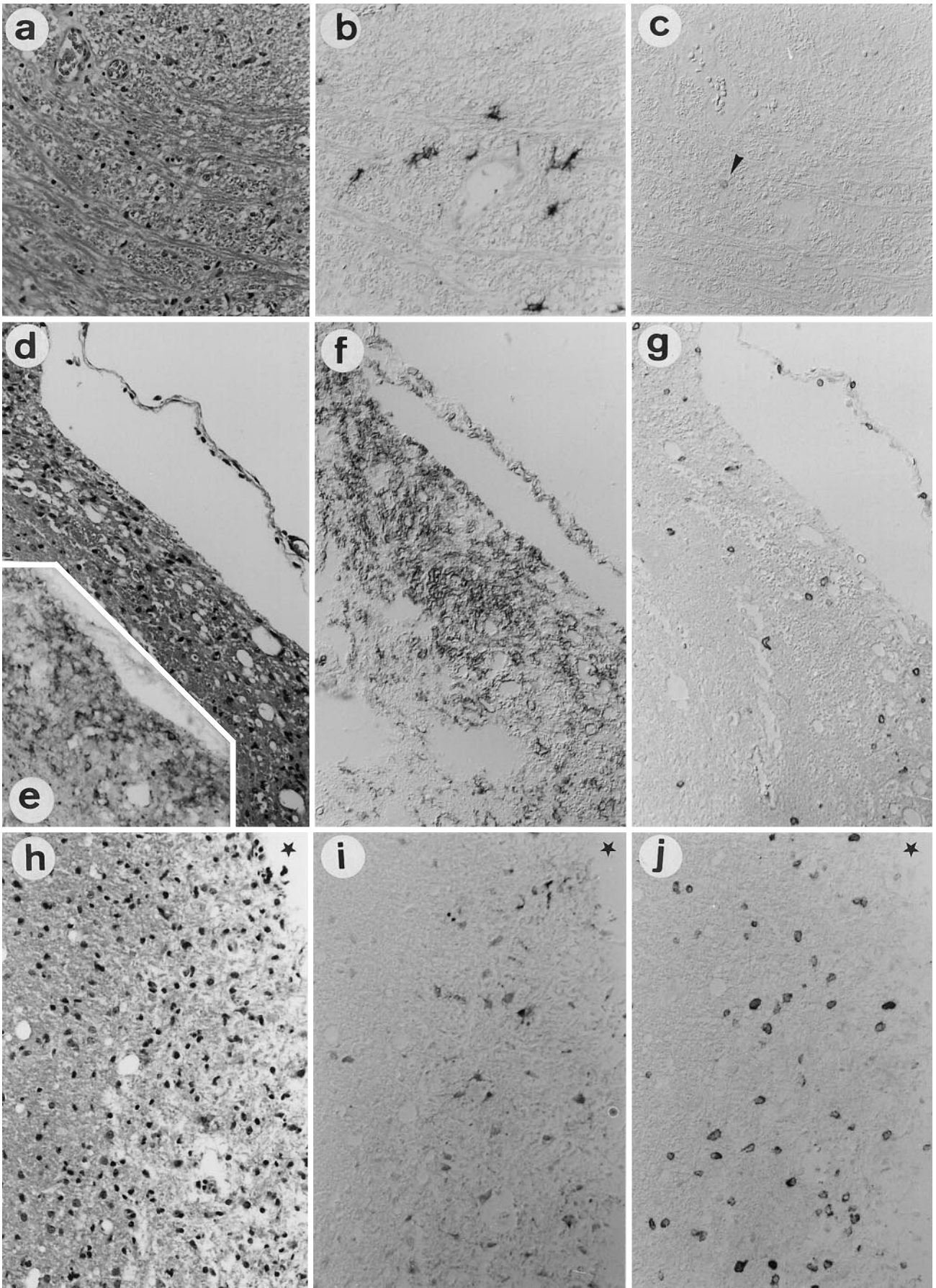
One experimentally infected dog was killed at 14 days PI. CDV mRNA and antigen-containing cells were detected in some areas of the white matter around the fourth ventricle and subpial regions (Fig. 1 b). There was no sign of any white matter change with the exception of a few prominent microglial cells (Fig. 1 a). Scattered CD3⁺ cells were found in the white matter throughout the brain (Fig. 1 c) and in the meninges. Their distribution appeared to be random but also coincided with areas of viral replication. The number of CD3⁺ cells was about four- to fivefold that found in the brain tissue of normal dogs. Neither B cells nor αD⁺ cells were found. A few CD45RA⁺ cells were detected, but no Ki-67⁺ cells were found.

Acute demyelination

This group included six experimentally infected cases which had been killed between 21 and 24 days PI and two additional spontaneous cases. It has been well documented that initial demyelinating lesions in distemper develop between 21 and 24 days PI [32].

Viral spread had progressed considerably in these animals with numerous infected glial cells in the white matter and ventricular lining, and viral mRNA in some neurons. In several areas of viral replication, demyelination occurred (Fig. 1 d, e). The earliest white matter lesions were characterized by mild vacuolation of the white matter with occasional hypertrophic astrocytes and rod cells but loss of myelin was not yet evident (Fig. 1 d). These lesions contained a few CD3⁺ cells (Fig. 1 g); their numbers were higher than in normal white matter (see Fig. 5). No B cells were found in these early lesions. A few positive CD45RA⁺ cells were observed, but staining for Ki-67 and αD was negative. Enhanced expression of CD18 was seen, probably reflecting an activation of microglia as judged by the morphological appearance of labeled cells (Fig. 1 f).

In addition to these areas of white matter vacuolation frank multifocal demyelination had occurred within CDV-infected regions with marked spongy state and pallor of the tissue and numerous macrophages that had ingested tissue debris (Fig. 1 h). A marked diffuse accumulation of T cells but not of B cells was observed in these demyelinating lesions (Figs. 1 j; 2 a, c). A significant number of CD45RA⁺ cells (about 1/3 of the number of CD3⁺ cells) was observed (Fig. 2 b); staining for Ki-67 was negative. Single αD⁺ cells were detected in the meninges near the lesions in only one case. A clearly enhanced expression of CD18 was associated with microglia cells, which were hypertrophied with thickened processes.



◀ **Fig. 1 a–j** Development of T cell invasion in acute distemper infection. **a–c** CDV-infected dog 14 days PI showing virus invasion in the CNS; **a** white matter in medulla oblongata, no microscopic changes; H&E. **b** Same area as in **a**, showing mRNA of the N protein of CDV; in situ hybridization. **c** Same area as in **a**, showing a single CD3⁺ cell (*arrowhead*); anti-CD3-ABC. **d–g** CDV-infected dog 21 days PI, consecutive sections of early acute demyelinating lesion in subpial tissue around the 4th ventricle, near velum medullare. **d** White matter vacuolation; H&E. **e** Many infected cells showing mRNA of the N protein of CDV; in situ hybridiza-

tion. **f** Prominent microglia staining; anti-CD18-PAP. **g** Several CD3⁺ cells in the lesion; anti-CD3-ABC. **h–f** CDV-infected dog 24 days PI, consecutive sections of acute demyelinating lesion in subpial tissue of cerebellum, *asterisk* marks meningeal space. **h** Severe myelin loss and hypercellularity; H&E. **i** Many infected cells showing N protein of CDV; anti-CDV NP-PAP. **j** Numerous CD3⁺ cells in the lesion; anti-CD3-ABC (*CDV* canine distemper virus, *ABC* avidin-biotin-peroxidase complex, *PAP* peroxidase-antiperoxidase, *PI* post infection). **a–j** × 100

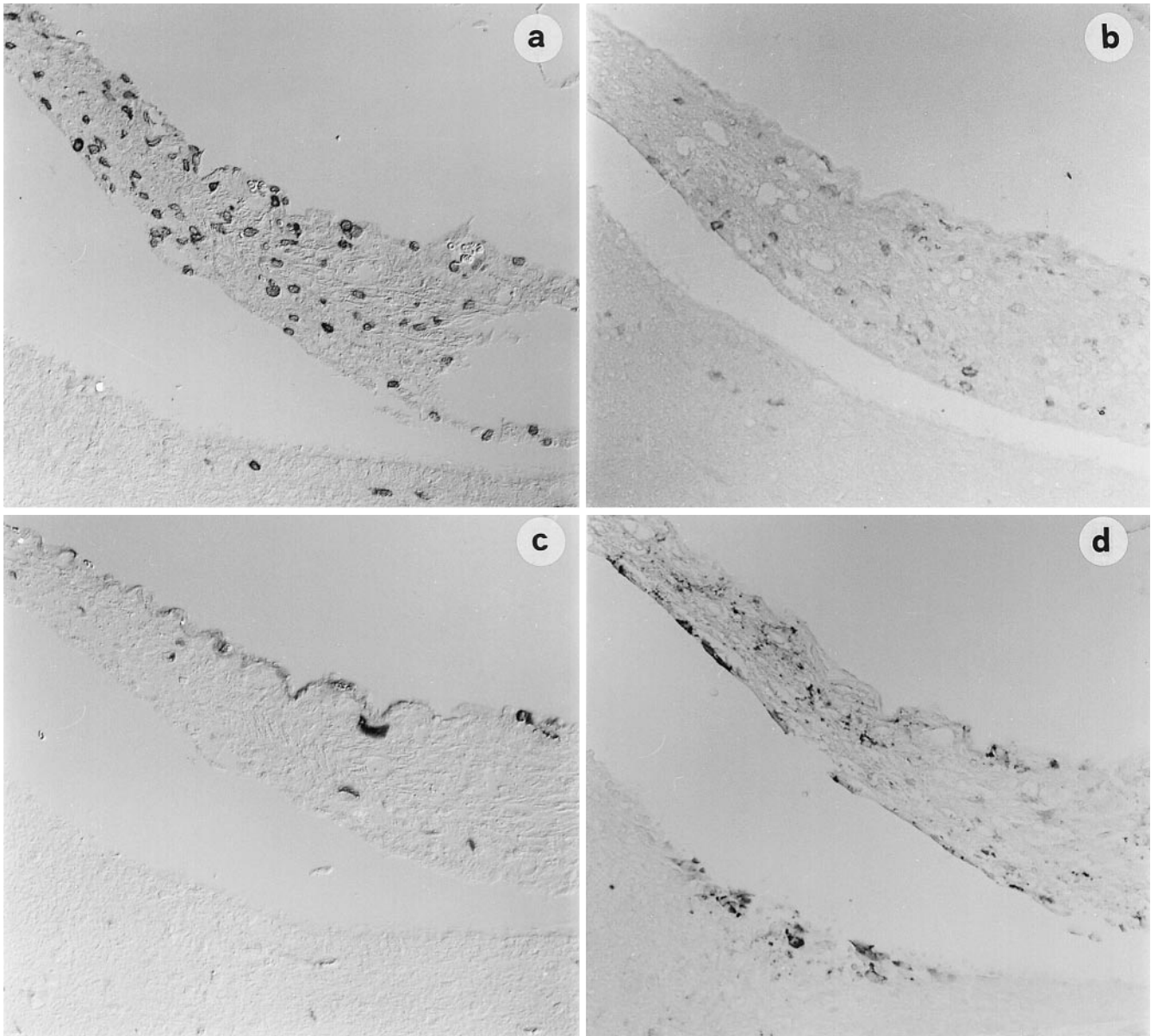
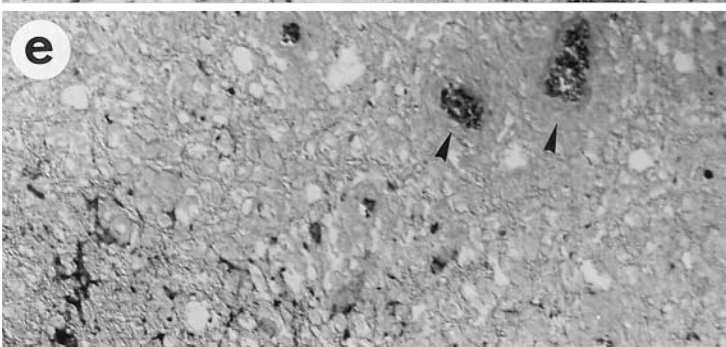
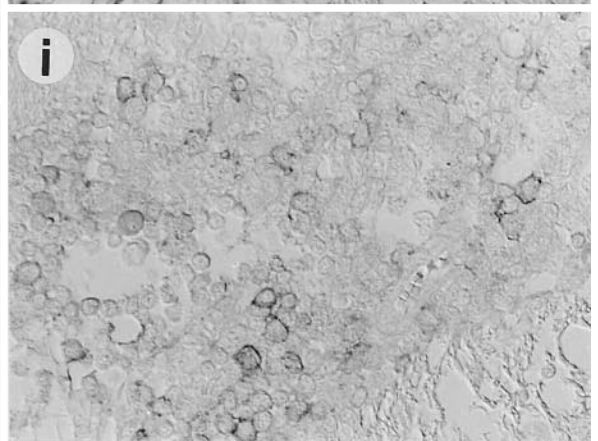
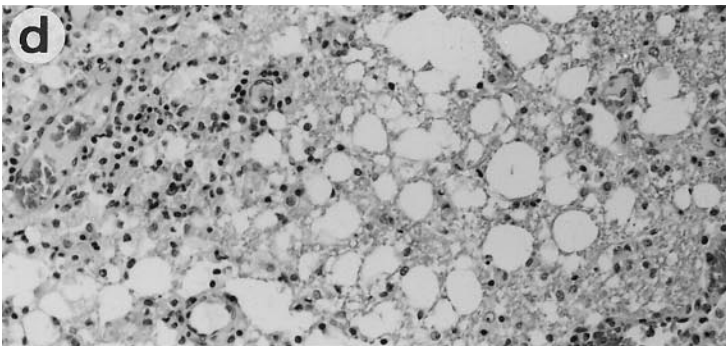
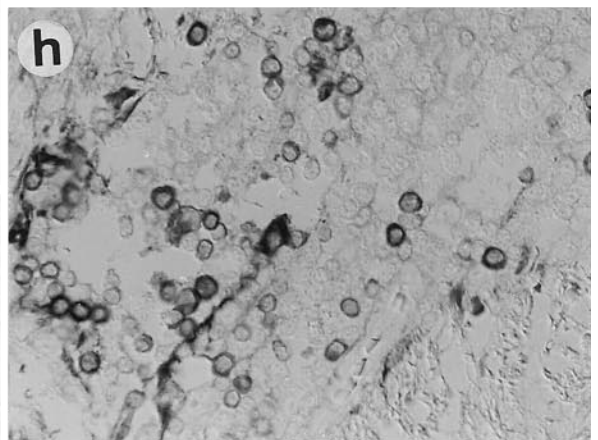
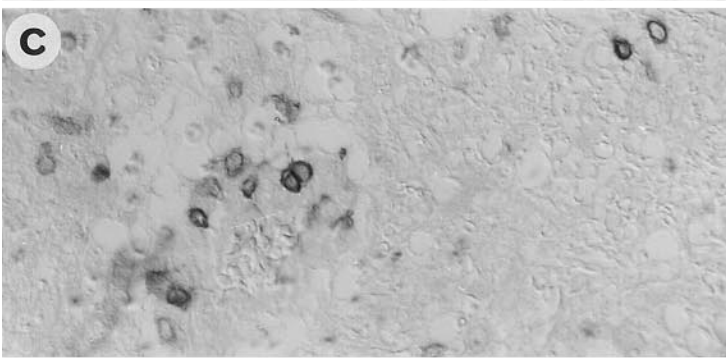
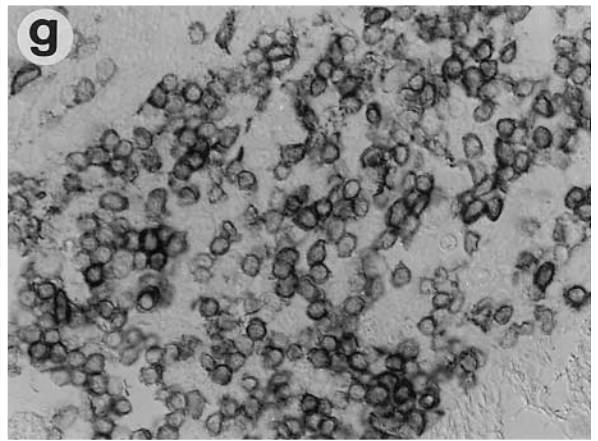

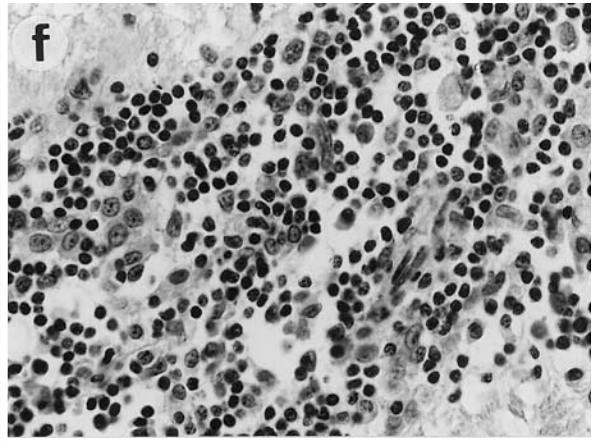
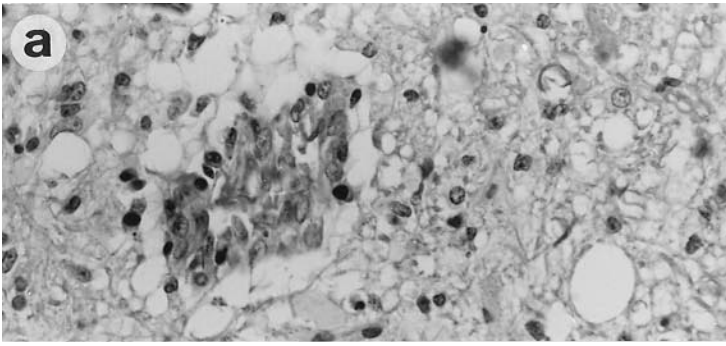


Fig. 2 a–d CDV-infected dog 24 days PI, serial sections of acute demyelinating lesion in velum medullare. **a** Numerous CD3⁺ cells in the lesion; anti-CD3-ABC. **b** Several CD45RA⁺ cells; anti-CD45RA-PAP. **c** Immunoglobulin staining is associated with plasma in a few blood vessels, no cellular staining; anti-canine Ig-PAP. **d** Numerous infected cells showing N protein of CDV; anti-CDV NP-PAP. **a–d** × 100

In all eight dogs in this group, scattered CD3⁺ cells (about nine times the number of CD3⁺ cells found in the brain tissue of normal dogs, see Fig. 5), were found in virus-infected areas but were also distributed randomly in unaffected brain tissue, mostly in the white matter (Fig. 4 a, b). These T cells had no apparent relation to blood vessels. About one third of the lymphocytes in the normal tissue were CD45RA⁺ cells. B cells were not detected. In



four of these dogs very few Ki-67⁺ cells were detected; α D⁺ cells were not found.

CD3⁺ cells were further analyzed in frozen sections from three selected cases. The poor quality of the frozen tissue prevented a detailed evaluation of the frozen sections. However, CD3⁺ cells showed a scattered distribution, as observed on paraffin-embedded tissue. CD21⁺ cells were not detected. Both CD4⁺ and CD8⁺ cells were found in the lesions and distributed in the tissue. CD8⁺ cells were by far more numerous.

Early inflammation

This lesion type was found in two dogs. One was an experimental case which was killed 31 days PI, the other one was a spontaneous case. CDV infection was extensive in large areas of the white matter. Lesions were characterized by advanced demyelination with numerous macrophages and astrogliosis. In contrast to the previous group, the lesions were accompanied by beginning mild perivascular cuffing (Fig. 3a). There was marked diffuse CD3⁺ cell infiltration in the lesions (Fig. 3c) and most cells in the perivascular cuffs were CD3⁺. Of these nearly 10% were CD45RA⁺. At this time point a few B cells appeared in the lesions and in the perivascular cuffs (Fig. 3b). A few α D⁺ cells were found in one of the two cases. CD18 staining showed marked up-regulation of microglial cells. All these lesions still contained large numbers of CDV-infected cells.

In the unaffected brain tissue randomly scattered CD3⁺ cells were again observed (about 11-fold the CD3⁺ cells found in normal dogs; Fig. 5). Some were CD45RA⁺ and very few Ki-67⁺ were seen. Neither B cells nor α D⁺ cells were detected. CD18⁺ staining of microglia cells in the unaffected white matter did not differ from normal dogs.

Inflammatory demyelination

This group included four dogs. One was an experimental case, which had been killed at 42 days PI. The three others were spontaneous cases.

◀ **Fig. 3a–j** Lymphocytes in subacute and chronic distemper encephalitis. **a–c** Severe inflammatory demyelinating lesion in cerebellar peduncle of CDV-infected dog 31 days PI. **a** Beginning perivascular cuffing in a demyelinated area; H&E. **b** Same area as in **a**, a few B cells in the perivascular cuff and in the tissue; anti-canine Ig-PAP. **c** Same area as in **b**, several CD3⁺ cells in the cuff and in the tissue; anti-CD3-ABC. **d** CDV-infected dog 41 days PI, showing severe inflammatory demyelination in cerebellar white matter; H&E. **e** Viral clearance in inflammatory lesion of CDV-infected dog 42 days PI. Viral labeling disappears in center of the lesion (perivascular cuffs indicated by arrows), mRNA of the N protein CDV; in situ hybridization. **f–j** Cellular composition in serial sections of perivascular cuff of CDV-infected dog 42 days PI. **f** H&E; **g** T cells shown with anti-CD3-ABC; **h** B cells shown with anti-canine Ig-PAP; **j** anti-CD45RA PAP. **a–c** $\times 200$, **d**, **e** $\times 100$, **f–j** $\times 400$

The white matter lesions at this stage were characterized by massive perivascular cuffing (Fig. 3f). Demyelination was compounded by complete necrosis of the white matter in many of these lesions (Fig. 3d). On average, 60% of the perivascular and diffusely invading lymphocytes were CD3⁺ (Fig. 3g) and 40% were B cells (Fig. 3h). CD45RA⁺ cells were more numerous in perivascular cuffs (20%; Fig. 3i) than in the surrounding tissue (6–13%). α D⁺ cells in the lesions numbered between 0% and 4%. Marked activation of microglia cells appeared on CD18 stains. Virus clearance was observed in the inflammatory lesions (Fig. 3e). Virus was still detected at outer limits of some lesions or in parts of the unaffected myelin as well as in the gray matter. The normal white matter of these four animals also contained randomly scattered CD3⁺ cells. These were more numerous than in the acute stage (about 12-fold of the number of CD3⁺ cells in the brain tissue of normal dogs; Fig. 5). A third of the CD3⁺ cells were estimated to be CD45RA⁺ cells. Neither B cells nor α D⁺ cells and very few Ki-67⁺ cells were detected in unaffected tissue.

Experimentally infected, recovered dogs

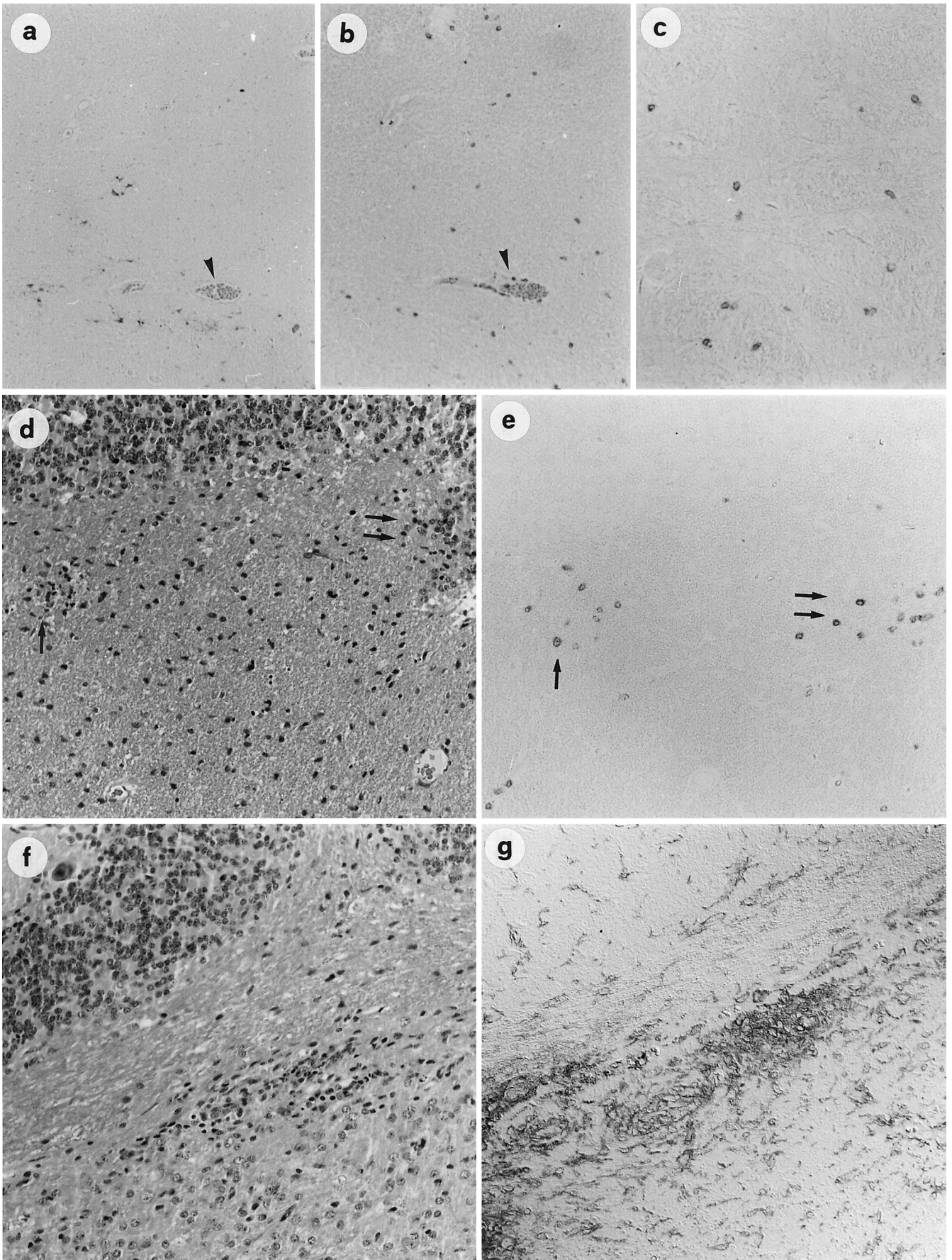
Four experimentally inoculated dogs developed mild transient systemic signs after infection with CDV. One of these dogs was killed at 21 days PI, another one at 41 days and two at 46 days PI. Histopathological examination revealed no abnormalities with the exception of few areas with prominent microglia cells and a few scattered glial nodules (Fig. 4d, f, g). No virus mRNA or protein were detected. In all these dogs scattered CD3⁺ cells were found mostly in the white matter throughout the brain, with random distribution (Fig. 4c), but also accumulated in glial nodules (Fig. 4e). They were more numerous than in the brain of healthy dogs. Most were found in the dog killed at 21 days PI, 16-fold that seen in brain tissue of healthy dogs (Fig. 5). One dog of this group, killed at 41 days PI, showed about 11-fold and the two dogs killed at 46 days PI 5-fold the number seen in brain tissue of healthy dogs.

Controls

In the 7 healthy control dogs, 0–1 CD3⁺ cell/microscopic field were found the brain tissue. None of the other types of inflammatory cells examined could be detected.

In the 18 dogs with other encephalitides, labeled lymphocytes were found in lesion sites in all cases. In one case with protozoal encephalitis and one case with rabies, scattered T cells were found in the tissue outside the lesion areas. However, in these two cases lesions were widespread and clearly unaffected tissue was not well defined.

In the 5 dogs with degenerative diseases, there was no difference in the occurrence of CD3⁺ cells in the brain tissue and that of normal dogs. However, prominent microglia was detected using the CD18 marker in lesion areas.



◀ **Fig. 4a–g** T cells in normal white matter. **a, b** Normal cerebellar white matter in CDV-infected dog 24 days PI. **a** Scattered infected cells, NP of CDV; anti-CDV NP-PAP; **b** scattered CD3⁺ cells in the matching area; anti-CD3-ABC. Blood vessel, as landmark indicated by *arrow*. **c** Experimentally CDV-inoculated, recovered dog 21 days PI, showing diffusely scattered CD3⁺ cells in unaffected tissue of the brain stem; no virus is found in the CNS; anti-CD3-ABC. **d, e** Cerebellar white matter of experimentally infected, recovered dog 21 days PI. **d** A few “glial nodules” indicated by *arrowheads*, H&E. **e** Same area as in **d**, accumulation of CD3⁺ cells in glial nodules; anti-CD3-ABC. **f, g** Experimentally infected, recovered dog 46 days PI, edge of cerebellar white matter. **f** Glial nodule; H&E. **g** Prominent microglial staining, anti-CD18-PAP. **a–g** × 100

T-cells in different stages of CDV infection

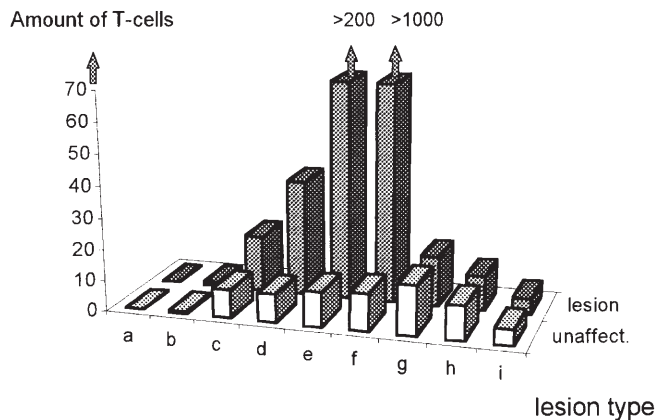


Fig. 5 Estimated numbers of T cells at different stages of CDV infection (average number of cells per microscopic field). *White columns in front row* show T cells in unaffected brain tissue; the *second row (gray columns)* the amount of T cells in demyelinating lesions during CDV infection. *a* Healthy controls; *b* 14 days PI, virus invasion in white matter/no demyelination; *c* 21–24 days PI, white matter vacuolation; *d* 21–24 days PI, advanced loss of myelin; *e* 31 days PI, subacute stage of CDV encephalitis, beginning inflammation; *f* 42 days PI, chronic stage of CDV encephalitis, massive perivascular cuffing; *g–i* = experimentally infected, recovered dogs without demyelinating lesions, euthanized at 21 (*g*), 41 (*h*) and 46 (*i*) days PI

Immunological status and neutralizing antibodies against CDV

The results are summarized in Table 1. The animal that was killed at 14 days PI was severely immunosuppressed. At this time point no CDV neutralizing antibodies were detected in the CSF and serum. The animal was lymphopenic and its lymphocytes did not respond to lectins [32]. All animals with acute demyelinating lesions that

Table 1 Neutralizing antibodies and lymphocyte proliferation test in CDV-inoculated dogs (CDV canine distemper virus)

Stage of the disease	Neutralizing antibodies in CSF	Neutralizing antibodies in serum	Lymphocyte proliferation depressed	Lymphocyte proliferation normal
Acute	0/6	1/6	4/4	0/4
Subacute – chronic	3/4	5/6	1/5	4/5
Recovered/no demyelination	3/3	4/4	1/4	3/4

were killed between 21 and 24 days PI were immunosuppressed as shown by the lack of neutralizing anti-CDV antibodies, extreme lymphopenia and inability of lymphocytes to respond to lectin stimulation. Neutralizing antibodies could not be found in one dog killed at 31 days PI with beginning perivascular cuffing because of toxic serum reaction in the neutralization assay; in the other dog killed at this stage a significant titer was found. The lymphocyte proliferation test at the time of euthanasia was normal in one dog and depressed in the other. In three dogs with fulminant inflammatory demyelination, the lymphocyte proliferation test was normal at the time of euthanasia. Significant antibody titers against CDV were found in the serum and CSF in the three dogs. All four dogs that recovered had significant titers of neutralizing antibodies against CDV in the CSF as well as in the serum at the time of euthanasia. Lymphocyte proliferation test returned to normal in three of these dogs and was depressed in one dog (21 days PI) at the time of euthanasia.

Experiment 2:

Antibodies against recombinant nucleocapsid protein of CDV

The results are summarized in Table 2. Of the 12 SPF dogs, no dog had detectable anti-CDV IgM antibodies in the serum prior to infection with CDV (day 0). Already at 1 week PI, 2 out of 11 test sera showed a positive reaction. At 14 and 21 days PI with CDV 10 of the 12 dog sera tested showed marked anti-CDV IgM binding. All 5 test sera available at 4 weeks PI were positive in our dot-blot assay.

Experiment 3:

IL-8-like activity in the CSF

The results of the IL-8 desensitization assay are listed in Fig. 6. Marked IL-8 levels were found in all but one case of the chronic, inflammatory stage of CDV infection. A similar level of IL-8-like activity was detected in five out of seven cases in the acute, non-inflammatory stage of the disease. Canine mononuclear cells were able to migrate to crIL-8. However, a concentration-dependent chemotactic activity occurred: 100 nM crIL-8 developed the strongest chemotactic activity for these cells, followed by 10 nM and 1 nM, whereas 1 μM crIL-8 was not chemotactic for canine mononuclear cells. Morphologically the migrated cells appeared to be lymphocytes.

Table 2 Detection of anti-N protein IgM in SPF dogs infected with A75/17CDV (SPF specific pathogen free, PI post infection, – no anti-N protein IgM detectable, +/++/+++ weakly positive/positive/strongly positive for anti-N protein IgM, n.d. not done)

Dogs	Days of serum collection				
	0*	7 PI	14 PI	21 PI	27 PI
1	–	n.d.	–	–	+
2	–	–	+	+	+++
3	n.d.	–	–	–	n.d.
4	–	–	++	++	n.d.
5	–	–	++	++	n.d.
6	–	+	++	++	n.d.
7	–	–	+++	++	n.d.
8	–	+	+++	++	n.d.
9	–	–	++	++	n.d.
10	–	–	++	++	++
11	–	–	++	++	+
12	–	–	++	++	++
Total pos.	0/11	2/11	10/12	10/12	5/5

* Before challenge

IL-8 like activity in the CSF of CDV infected dogs

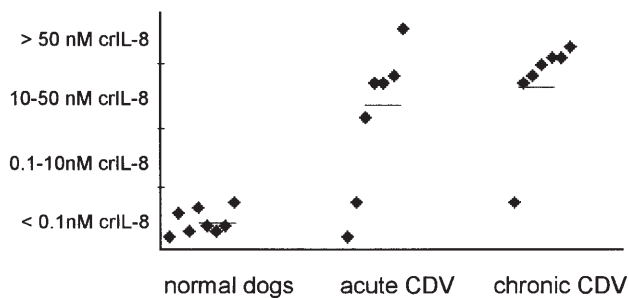


Fig. 6 IL-8 like activity as measured using a desensitization assay in CSF in healthy dogs (*first column*), in dogs in the acute, non-inflammatory stage of CDV infection (*second column*) and in dogs in the chronic, inflammatory stage of the disease (*third column*). The CSF IL-8 levels were compared to values obtained in the same assay using canine recombinant IL-8 (*crIL-8*)

Discussion

The acute stage of CDV infection is characterized by severe long-lasting immunosuppression with lymphoid depletion, lack of mitogen responsiveness and inability to mount a specific immune response [16]. Perivascular cuffing is completely lacking in the early demyelinating lesions in distemper. Moreover, *in vitro* studies showed that CDV is capable of inducing oligodendroglial dysfunction and degeneration [13]. For all these reasons, it is believed that initial demyelination in distemper is a virus-induced degenerative lesion. Inflammatory demyelination is a later complication in the chronic stage of the disease. In view of all these previous findings it was intriguing to consistently find significant numbers of lymphocytes in

the CNS of such immunosuppressed dogs in acute distemper in the present study.

Two phenomena were observed: marked T cell invasion in early demyelinating lesions and diffuse up-regulation of T cells throughout the CNS. Passive diffusion of these cells from the blood is unlikely, because there is no evidence for blood-brain barrier breakdown in acute distemper [4, 7, 30, 35]. The observed increased numbers of T cells in the brain could not be explained by local proliferation of residential T cells, which can be found in small numbers in the CNS in normal dogs as in other species [18]. Rather, locally produced chemokines could be responsible for attracting T cells from the circulation. Indeed, we found marked IL-8-like activity in CSF in a group of dogs with acute distemper in the present study. It is known that besides neutrophils also T cells are attracted by IL-8 [17]. Potential sources of IL-8 are the microglia and probably activated astrocytes. Microglia are activated in distemper as shown by our present findings and those of Alldinger et al. [1]. Production of IL-8 has been shown in our study, but it seems probable that other chemokines also attract T cells, and numerous other cytokines may be involved in the immunopathogenesis of canine distemper.

In areas of white matter pathology, T cell numbers increased proportionally to the progression of demyelination. These T cells were not associated with blood vessels, which is consistent with the previously noted complete absence of any perivascular cuffing in acute distemper lesions. This suggests a high mobility of these T cells; they probably migrate quickly into the tissue without accumulating in the Virchow-Robin space. This is similar to Borna disease [23] in which CD8⁺ cells are trafficking through the parenchyma, whereas CD4⁺ cells are more restricted to perivascular cuffs. Our limited studies in frozen sections suggested that most of the T cells were CD8⁺. This is also consistent with studies in frozen sections from Wünschmann et al. [36], who showed a predominance of CD8⁺ cells in the initial stages of the inflammatory response in distemper.

Although scattered T cells were also found outside of lesions and/or infected areas, major T cell invasion correlated with virus replication in the CNS especially in areas of myelin pathology. This correlation strongly suggests the antiviral nature of the invading T cells. This contrasts with the well-established fact that an antiviral immune response is virtually lacking in the immunosuppressed acute stage of the disease [3]. Antiviral immunity has been measured by its success to eliminate CDV by cytotoxic T lymphocytes (CTL) and neutralizing antibodies, which correlates with an immune response against surface antigens of the virus [3]. However, while such an effective response is clearly lacking in animals that develop acute demyelination, there is some evidence for a weak antiviral antibody response against internal proteins in early infection stages [20]. Using a sensitive binding assay with recombinant N protein of virulent CDV in the present study, we were able to demonstrate a significant specific IgM response against the N protein of CDV starting between 1 and 2 weeks PI in the majority of animals in a group of experimentally in-

ected dogs. We could also show in other studies that, similar to other Morbilliviruses [6], a conserved epitope of CDV N protein is capable of inducing a CTL response in mice (Witteck and Zurbriggen, unpublished data). The early immune response to CDV N protein in dogs coincides temporally with the earliest detection of T cells in the CNS at the time when CDV starts to invade the brain. Taken together, these findings strongly support the notion that the T cells in acute demyelinating lesions are indeed directed against CDV, probably against internal viral proteins.

T cell accumulation in acute distemper lesions did not at all appear to inhibit CDV spread: viral load continued to increase at least up to 31 days PI, despite continuously increasing numbers of T cells. Similar to corona virus infection in rats [14], CDV clearance, the visible effect of an effective antiviral immune response, occurs much later in the inflammatory stage of the disease [8], when the intrathecal antiviral humoral immunity develops with invasion of CD4⁺ cells, B cells [29, 36] and neutralizing antibodies. Therefore, there is no evidence that antiviral cytotoxicity contributes to demyelination in early lesions by killing infected cells, as for example could occur in Borna virus infection [23]. A humoral component [19] may also be required for autoimmune demyelination in experimental allergic encephalomyelitis (EAE), which is induced by myelin antigen-sensitized T cells [26, 31]. Such cells have been found in experimental distemper [10], but do not correlate with disease outcome.

Based on previous studies, there is little doubt that direct interaction of CDV with glial cells including oligodendrocytes is the initial event in the demyelinating process. Early T cell invasion as seen in the present study could perhaps exacerbate the process by secreting cytokines leading to tissue damage.

In addition to T cell invasion in early demyelinating lesions, diffuse up-regulation of T cells was already found in the early stages of viral invasion of the CNS. These T cells were scattered in unaffected/uninfected tissue throughout the brain, mostly in the white matter and did not correlate with disease outcome: similar numbers of T cells were also found in four experimentally CDV-infected, recovered animals that did not develop demyelination. The later course of the infection has been described before in experimental distemper in a limited number of animals that are capable of mounting an early effective antiviral immune response [3, 16, 32]. Neither CDV protein nor CDV mRNA were detected in the CNS of our recovered animals. It is possible that T cells in the CNS, whose numbers in recovered animals decreased towards the end of the observation period, reflect transient presence of CDV in the CNS. The observed small glial nodules in the CNS of the recovered dogs would support this notion. An alternative explanation would be that homing abilities of lymphocytes are deranged as a result of the primary interaction of CDV with the immune system. In lymphatic tissue CDV mRNA and antigen were abundant already 5 days PI (data not shown). Although T lymphocytes infiltrating the lesion epicenter also occur in experimental spinal cord

trauma [22], we do not believe that T cells in our study were attracted to the brain as an unspecific response to injury. Diffuse T cell invasion in other canine infectious diseases such as rabies and central European tick-borne encephalitis is not as evident as in distemper, but may be difficult to assess because of a more widespread distribution of the lesions. Moreover, in conditions with neuronal or white matter degeneration such an up-regulation of T cells was not observed.

A proportion of invading T cells in our acute cases expressed CD45RA. This suggests that these cells penetrated the blood-brain-barrier either without being activated or they regained CD45RA after entry into the CNS, in which case they are considered to be resting T cells. The presence of a pool of resting T cells in the CNS could possibly have implications for generating a certain memory potential [15], and recruitment of an intrathecal immune response during the later course of the disease.

In conclusion, we detected an early virus-induced T cell response, probably directed against CDV in the CNS, in the absence of morphological markers of inflammation and despite severe immune suppression. The invasion of these cells may be directed by chemokine production associated with microglia activation, which in turn results from virus-induced tissue changes. Whether the observed T cells contribute to the development of acute demyelination remains uncertain at this stage. Accumulation of immune cells in the CNS in the early stages of the disease may, however, facilitate the later development of the local immune response and associated immunopathological complications.

Acknowledgements This study was supported by grants from the Swiss National Science Foundation (grant nos. 32-49506.96, 32-44483.95, 32-46784.96, 32-050203.97 and 31-45609.95) and from the Swiss MS Society. The generous gifts of crIL-8 by Repligen Corporation (Needham, Mass.) and of a polyclonal antibody against crIL-8 by R. K. Straubinger (James A. Baker Institute of Animal Health, Cornell University, Ithaca, N.Y.) are gratefully acknowledged.

References

1. Alldinger S, Wunschmann A, Baumgartner W, Voss C, Krenmer E (1996) Up-regulation of major histocompatibility complex class II antigen expression in the central nervous system of dogs with spontaneous canine distemper virus encephalitis. *Acta Neuropathol* 92: 273–280
2. Appel MJ, Glickman LT, Raine CS, Tourtellotte WW (1981) Canine viruses and multiple sclerosis. *Neurology* 31: 944–949
3. Appel MJ, Shek WR, Summers BA (1982) Lymphocyte-mediated immune cytotoxicity in dogs infected with virulent canine distemper virus. *Infect Immun* 37: 592–600
4. Axthelm MK, Krakowka S (1987) Canine distemper virus: the early blood-brain barrier lesion. *Acta Neuropathol (Berl)* 75: 27–33
5. Baggiolini M, Dahinden CA (1994) CC chemokines in allergic inflammation. *Immunol Today* 15: 127–133
6. Beauverger P, Buckland R, Wild TF (1993) Measles virus antigens induce both type-specific and canine distemper cross-reactive cytotoxic T lymphocytes in mice: localization of a common Ld-restricted nucleoprotein epitope. *J Gen Virol* 74: 2357–2363

7. Bichsel P, Vandeveld M, Vandeveld E, Affolter U (1984) Immunoelectrophoretic determination of albumin and IgG in serum and cerebrospinal fluid in dogs with neurological diseases. *Res Vet Sci* 37: 101–107
8. Bollo E, Zurbriggen A, Vandeveld M, Fankhauser R (1986) Canine distemper virus clearance in chronic inflammatory demyelination. *Acta Neuropathol (Berl)* 72: 69–73
9. Burgener I, Van Ham L, Jaggy A, Vandeveld M, Tipold A (1998) Chemotactic activity and IL-8 levels in the cerebrospinal fluid in canine steroid responsive meningitis-arteritis. *J Neuroimmunol* (in press)
10. Cerruti-Sola S, Kristensen F, Vandeveld M, Bichsel P, Kihm U (1983) Lymphocyte responsiveness to lectin and myelin antigens in canine distemper infection in relation to development of demyelinating lesions. *J Neuroimmunol* 4: 77–90
11. Cobbold S, Metcalfe S (1994) Monoclonal antibodies that define canine homologs of human Cd antigens – summary of the First International Canine Leukocyte Antigen Workshop (Claw). *Tissue Antigen* 43: 137–154
12. Gerdes J, Lemke H, Baisch H, Wacker HH, Schwab U, Stein H (1984) Cell cycle analysis of a cell proliferation-associated human nuclear antigen defined by the monoclonal antibody Ki-67. *J Immunol* 133: 1710–1715
13. Graber HU, Muller CF, Vandeveld M, Zurbriggen A (1995) Restricted infection with canine-distemper virus leads to down-regulation of myelin gene-transcription in cultured oligodendrocytes. *Acta Neuropathol* 90: 312–318
14. Hein A, Schwender S, Imrich H, Sopper S, Czub M, Dorries R (1995) Phenotypic and functional characterization of CD8⁺ T lymphocytes from the central nervous system of rats with coronavirus JHM induced demyelinating encephalomyelitis. *J Neurovirology* 1: 340–348
15. Herzenberg LA, Weir DM, Herzenberg L, et al (1996) Weir's handbook of experimental immunology, vol II. Cell surface and messenger molecules of the immune system. Blackwell, Cambridge
16. Krakowka S, Higgins RJ, Koestner A (1980) Canine distemper virus: review of structural and functional modulations in lymphoid tissues. *Am J Vet Res* 41: 284–292
17. Larsen CG, Anderson AO, Appella E, Oppenheim JJ, Matsushima K (1989) The neutrophil-activating protein (NAP-1) is also chemotactic for T lymphocytes. *Science* 243: 1464–1466
18. Lassmann H, Schmied M, Vass K, Hickey WF (1993) Bone marrow derived elements and resident microglia in brain inflammation. *Glia* 7: 19–24
19. Linington C, Bradl M, Lassmann H, Brunner C, Vass K (1988) Augmentation of demyelination in rat acute allergic encephalomyelitis by circulating mouse monoclonal antibodies directed against a myelin/oligodendrocyte glycoprotein. *Am J Pathol* 130: 443–454
20. Miele JA, Krakowka S (1983) Antibody responses to virion polypeptides in gnotobiotic dogs infected with canine distemper virus. *Infect Immun* 41: 869–871
21. Müller CE, Fatzer RS, Beck K, Vandeveld M, Zurbriggen A (1995) Studies on canine distemper virus persistence in the central nervous system. *Acta Neuropathol* 89: 438–445
22. Popovich PG, Wei P, Stokes BT (1997) Cellular inflammatory response after spinal-cord injury in Sprague-Dawley and Lewis rats. *J Comp Neurol* 377: 443–464
23. Sobbe M, Bilzer T, Gommel S, Noske K, Planz O, Stütz L (1997) Induction of degenerative brain lesions after adoptive transfer of brain lymphocytes from Borna disease virus-infected rats: presence of CD8⁺ T cells and perforin mRNA. *J Virol* 71: 2400–2407
24. Stettler M, Zurbriggen A (1995) Nucleotide and deduced amino acid-sequences of the nucleocapsid protein of the virulent A75/17-CDV strain of canine distemper virus. *Vet Microbiol* 44: 211–217
25. Straubinger RK, Straubinger AF, Harter L, Jacobson RH, Chang YF, Summers BA, Erb HN, Appel MJG (1997) *Borrelia burgdorferi* migrates into joint capsules and causes an up-regulation of interleukin-8 in synovial membranes of dogs experimentally infected with ticks. *Infect Immun* 65: 1273–1285
26. Sun D, Wekerle H (1986) Ia-restricted encephalitogenic T lymphocytes mediating EAE lyse autoantigen-presenting astrocytes. *Nature* 320: 70–72
27. Teske E, Kiupel M, Goverde G (1997) Proliferation markers in canine malignant lymphoma. Abstracts of the 7th Annual Congress of the European Society of Vet. Intern. Med., Lyon 7: 46
28. Tipold A, Moore P, Jungi TW, Sager H, Vandeveld M (1998) Lymphocyte subsets and CD45RA-positive T cells in normal canine cerebrospinal fluid. *J Neuroimmunol* (in press)
29. Tipold A, Moore P, Zurbriggen A, Vandeveld M (1997) Antigen dependent immune response in canine encephalitis. Abstracts of the 11th Annual Symposium of the European Society of Veterinary Neurology, Bologna 11: 37
30. Tipold A, Pfister H, Vandeveld M (1993) Determination of the IgG index for the detection of intrathecal immunoglobulin synthesis in dogs using an ELISA. *Res Vet Sci* 54: 40–44
31. Umehara F, Quin YF, Goto M, Wekerle H, Meyermann R (1990) Experimental autoimmune encephalomyelitis in the maturing central nervous system. Transfer of myelin basic protein-specific T line lymphocytes to neonatal Lewis rats. *Lab Invest* 62: 147–155
32. Vandeveld M, Higgins RJ, Kristensen B, Kristensen F, Steck AJ, Kihm U (1982) Demyelination in experimental canine distemper virus infection: immunological, pathological, and immunohistological studies. *Acta Neuropathol (Berl)* 56: 285–293
33. Vandeveld M, Hugi E, Isler A, Suter M, Pfister H (1983) Histological immunoenzyme techniques in canine tissues: evaluation of various methods and modifications. *Res Vet Sci* 34: 193–198
34. Vandeveld M, Kristensen F, Kristensen B, Steck AJ, Kihm U (1982) Immunological and pathological findings in demyelinating encephalitis associated with canine distemper virus infection. *Acta Neuropathol (Berl)* 56: 1–8
35. Vandeveld M, Zurbriggen A, Steck A, Bichsel P (1986) Studies on the intrathecal humoral immune response in canine distemper encephalitis. *J Neuroimmunol* 11: 41–51
36. Wünschmann A, Alldinger S, Vogl C, Kremmer E, Baumgärtner W (1997) Phenotypical characterization of lymphocytes in acute, subacute and chronic demyelinating brain lesions of dogs with spontaneous canine distemper encephalitis. *Immunobiology* 197: 369
37. Zurbriggen A, Schmid I, Graber HU, Vandeveld M (1998) Oligodendroglial pathology in canine distemper. *Acta Neuropathol* 95: 71–77
38. Zurbriggen A, Yamawaki M, Vandeveld M (1993) Restricted canine distemper virus infection of oligodendrocytes. *Lab Invest* 68: 277–284