

Coinfection of avian influenza virus (H9N2 subtype) with infectious bronchitis live vaccine

M. Haghighat-Jahromi · K. Asasi · H. Nili ·
H. Dadras · A. H. Shooshtari

Received: 16 January 2007 / Accepted: 12 December 2007 / Published online: 5 February 2008
© Springer-Verlag 2008

Abstract Avian influenza virus of H9N2 subtype is pathotyped as a non-highly pathogenic virus. However, frequent incidences of avian influenza of high mortality that are caused by H9N2 viruses have been observed in broiler chicken farms in Iran and some other Asian countries. Coinfections or environmental factors may be involved in such cases. Infectious microorganisms have been implicating in taking part in the cases of coinfection. We studied the effect of experimental coinfection of H9N2 avian influenza virus with infectious bronchitis live vaccine, which is used extensively in chicken farms in Iran. Clinical signs, gross lesions, viral shedding and mortality rate of the experimentally infected birds were examined. Coinfection of infectious bronchitis live vaccine and H9N2 avian influenza virus led to an extension of the shedding period of H9N2 virus, increasing the severity of clinical signs and mortality rates, causing macroscopic lesions in the embryos.

Introduction

Avian influenza (AI) is caused by viruses that are classified as members of the family *Orthomyxoviridae*, genus *Influenzavirus A* [31]. Influenza A viruses have two major surface glycoproteins, hemagglutinin (HA) and neuraminidase (NA). At present, 16 hemagglutinin (H1–H16) and nine neuraminidase subtypes (N1–N9) of the virus have been recognized [11]. Avian influenza viruses are classified as highly pathogenic (HP) and non-highly pathogenic (non-HP) or mildly pathogenic (MP) [9]. Based on experimental inoculation of chickens and the sequence of amino acids at the cleavage site of the HA molecule, only a small percentage of H5 and H7 AI viruses have been HP. By contrast, all AI viruses of the other HA subtypes are non-HP (i.e., MP) for birds [1, 22, 32]. The HA plays a key role in the pathogenicity of avian influenza virus [6, 17]. HAs of HP AI viruses are cleaved by cellular proteases, such as ubiquitous furin and PC6. In contrast, the HAs of non-HP AI viruses are cleaved only by trypsin-like proteases, which are secreted from cells in restricted tissues, such as the respiratory and intestinal tracts [17, 31]. Cleavage of HA into HA1 and HA2 is required for the entry of the virus to the host cell plasma via fusion of the viral envelope with the endosomal membrane after receptor-mediated endocytosis [18]. Cleavage of the HA allows exposure of the amino terminal fusion peptide of the HA 2 subunit.

The worldwide situation of HP AI has attracted the attention of scientists and government officials. On the other hand, the importance of low-pathogenic avian influenza viruses such as of H9N2, circulating in wild and commercial birds, should not be ignored.

Since 1997, serious problems caused by H9N2 virus infection in the poultry industry have been reported in Iran, Saudi Arabia, Pakistan, China and other Asian countries [9,

M. Haghighat-Jahromi · K. Asasi · H. Nili (✉) · H. Dadras
Poultry Research Center, School of Veterinary Medicine,
Shiraz University, P.O. Box 1731, 71345 Shiraz, Iran
e-mail: nili@shirazu.ac.ir

A. H. Shooshtari
Razi Vaccine and Serum Research Institute,
P.O. Box: 11365-1558, Tehran, Iran

M. Haghighat-Jahromi
Group of Veterinary Medicine, Darab Branch,
Islamic Azad University (IAU), Darab, Iran

12]. Mortality rates in some broiler farms in Iran are up to 65% [25]. However, the isolate was characterized as Non-highly pathogenic in the laboratory [34]. Mixed infections of influenza virus with other respiratory pathogens have been found to be responsible for such a high mortality, resulting in great economic losses [3, 5, 10, 15]. Since infectious bronchitis is one of the most prevalent respiratory viral infections in broiler chicken farms in Iran, infectious bronchitis live vaccine (IBLV) is used extensively in chicken farms in Iran. In the present study, experimental co-infection of IBLV with H9N2 virus in chickens and chicken embryos was carried out.

Materials and methods

Viruses

Avian influenza virus (AIV) strain A/chicken/Iran/SH-110/99(H9N2) and a commercial infectious bronchitis vaccine (freeze-dried live attenuated vaccine, Mass type, H120 strain, Merial Company) were used. Each dose of vaccine contains minimum of 10^3 EID₅₀ infectious bronchitis virus.

H9N2 AIV stock was propagated in 10-day-old embryonated chicken eggs for 48 h at 37°C. Allantoic fluids were harvested, and the 50% egg infectious dose (EID₅₀) was determined as described by Reed and Muench [28]. The stock virus yielded a concentration of 10^7 EID₅₀/ml when titrated in embryonated chicken eggs. Infectious allantoic fluids were stored at -70°C for use as inocula.

Experimental study

One-hundred and twenty, 1-day-old broiler chicks (*Gallus gallus subsp. domesticus*) were randomly divided into four groups. The chicks were raised for 40 days in the Animal Research Unit of Shiraz University Veterinary School. The birds were inoculated on the 20th day of age with 10^6 EID₅₀/bird H9N2 AIV via the nasal route and/or one dose of IBLV vaccine via the spray route. In the negative control group, sterile phosphate-buffered saline (PBS) was used for inoculation. No other vaccine was used in this experiment. The chickens were monitored daily for their general condition, clinical signs, viral shedding and mortality.

Duration of viral shedding

Fecal samples of all groups were collected each day starting on day one post-infection throughout the experiment. AIV antigen test kit (Felco) was used, and samples that were

negative with the kit were inoculated into 10-day-old embryonated chicken eggs via the chorioallantoic cavity. The eggs were incubated in a stationary incubator at 37°C and 55% relative humidity for 48 h, then chorioallantoic fluids were harvested and tested for the presence of AIV by hemagglutination (HA) and hemagglutination inhibition (HI) tests with the chicken antiserum to H9N2 virus [14, 19].

Gross lesions of embryos

Forty, 10-day-old embryonated chicken eggs were randomly divided into four equal groups and inoculated with 0.2 ml of H9N2 AIV (10^6 EID₅₀/egg) and/or IBLV (one vaccine dose) via the allantoic sac. The eggs of the control group were inoculated with sterile PBS. In order to prevent bacterial and fungal contamination, penicillin (10,000 IU/ml), streptomycin (10,000 µg/ml) and amphotericin B (5 µg/ml) were added to the samples [27]. The eggs were incubated in a stationary incubator at 37°C and 55% relative humidity for 48 h. Embryos were then investigated for any gross lesions.

HA activity of avian influenza virus in embryonated chicken eggs

One hundred and forty-four, 10-day-old embryonated chicken eggs were randomly divided into three groups and inoculated with 0.2 ml of H9N2 AIV (10^6 EID₅₀/egg) or AIV + IBLV (one vaccine dose) via the allantoic sac. The embryonated chicken eggs of the control group were inoculated with sterile PBS. Antibiotics and antifungal materials were used as described above. The eggs were incubated in a stationary incubator at 37°C and 55% relative humidity for 48 h. The allantoic fluids were harvested at 0, 16, 18, 20, 22, 24, 26, 28, 30, 44, 46 and 48 h post-inoculation in each group. Serial twofold dilutions of the allantoic fluid (50 µl) in PBS (pH 7.2) were mixed with 50 µl of a 1% washed chicken red blood cell suspension, then HA titers were read 30 min later at room temperature [7].

Results

Experimental study

Clinical signs

Results of daily monitoring of all groups showed that all chicks were clinically normal and did not show any abnormality prior to inoculation with viruses. AIV + IBLV group: From day two post-challenge, birds co-infected with AIV + IBLV started to show clinical signs

such as depression, ruffled feathers, respiratory distress (coughing, sneezing and dyspnea), swelling of the periorbital tissues and sinuses, conjunctivitis, and nasal and ocular discharge which continued to day six post-inoculation (PI). In some cases, dyspnea was very severe, and clinically affected birds extended their necks with open mouth to breathe. It seems that asphyxiation is responsible for high mortality.

AIV group: 2 of the 30 chickens inoculated with AIV showed mild clinical signs such as depression, ruffled feathers, nasal and ocular discharge and conjunctivitis.

Negative control and IBLV group: no clinical signs were found in negative control birds or in birds that were inoculated with IBLV.

There was 10% (3/30) mortality in chickens co-infected with AIV and IBLV, and death started 48 h post-inoculation, while no death was observed in the negative control birds and the birds that were inoculated either with AIV or IBLV alone.

Postmortem findings

Postmortem examinations of the respiratory system in dead birds showed tracheal congestion, lung hyperemia, and exudation with tubular cast formation in the tracheal bifurcation, which extended to the lower bronchi (Fig. 1).

Duration of viral shedding

Chickens coinfecting with AIV + IBLV shed H9N2 AIV from day 2 to day 11 PI, while chickens infected with AIV shed the virus from day three to day nine PI. Chickens of other groups did not shed virus (Table 1). As indicated in the table, birds in the AIV + IBLV group shed virus for a longer period (between days 2 and 11).

Fig. 1 **a** Cast formation in the tracheal bifurcation (*arrow*) extending to the lower bronchi of a dead chicken from the AIV + IBLV-inoculated group. **b** Extended tips of cast in the formaldehyde-fixed tracheal sample. These lesions were frequently observed in field cases of H9N2 infection with high mortality

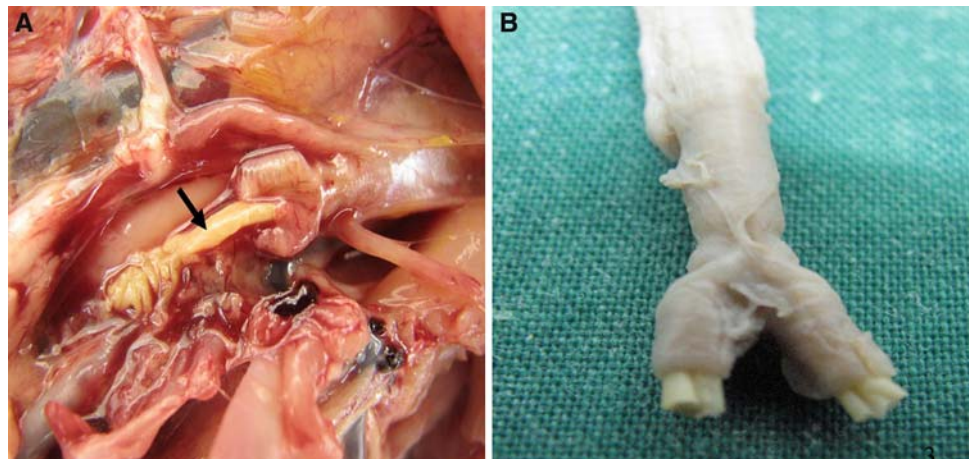


Table 1 Virus isolation from the birds of different groups after AIV inoculation

Day (PI) Group	1	2	3	4	5	6	7	8	9	10	11	12
Negative control	-	-	-	-	-	-	-	-	-	-	-	-
IBLV	-	-	-	-	-	-	-	-	-	-	-	-
AIV	-	-	+	+	+	+	+	+	+	-	-	-
AIV + IBLV	-	+	+	+	+	+	+	+	+	+	+	-

Gross lesions of embryos

Embryos inoculated with AIV + IBLV showed stunting and gross lesions such as subcutaneous hyperemia and many petechial to ecchymotic hemorrhages (Fig. 2). No gross lesions were found in the embryos of the other groups.

HA activity of avian influenza virus in embryonated chicken eggs

As shown in Fig. 3, HA activity, which is an indication of virus propagation, was observed 6 h earlier in the allantoic fluids of eggs inoculated with AIV + IBLV than in the allantoic fluids of eggs that were inoculated only with AIV. The final HA activities were the same for both groups. HA activity was not detected in those of negative control group.

Discussion

In the last decade, frequent incidences of H9N2 AIV outbreaks have caused high mortality in broiler chicken farms in Iran and some other Asian countries, resulting in great economic losses [9, 25, 26]. However, the causative virus

Fig. 2 Twelve-day-old chicken embryos, inoculated with AIV and/or IBLV, showing gross lesions. **a** Stunting in the embryos inoculated with AIV + IBLV (*b1–b4*) as compared with an AIV-inoculated embryo (*a*). **b** Hyperemia, petechial to ecchymotic hemorrhages in the subcutaneous tissues of an embryo inoculated with AIV + IBLV. It is noteworthy that the embryos inoculated with IBLV or AIV alone did not show any lesions

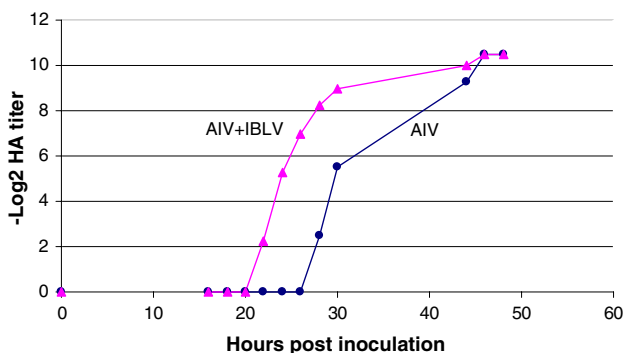
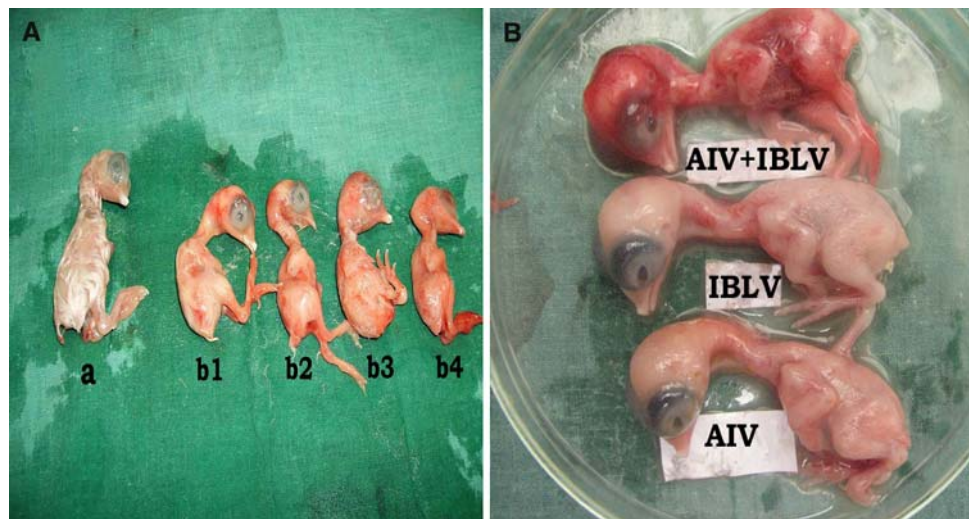


Fig. 3 Mean HA titers in embryonated chicken eggs inoculated with AIV and AIV + IBLV

has been characterized as mildly pathogenic [34]. So far, there has not been any clear explanation for such a discrepancy in mortality and severity of clinical manifestation between field and experimental induction of the disease in a controlled environment. One of the possible explanations for such a high mortality could be that it is due to mixed infection of the virus (H9N2) with other respiratory pathogens.

Since wild and vaccine strains of infectious bronchitis virus commonly circulate in poultry farms in the Middle East [13], we carried out experimental coinfection of H9N2 AIV with IBLV, both in chickens and chicken embryos.

The results of the present study showed that coinfection of IBLV with H9N2 AIV increased the severity of AI clinical signs and gross lesions; it even caused death of the infected birds. Postmortem lesions such as tracheal congestion, lung hyperemia and exudation of the trachea with tubular cast formation in the tracheal bifurcation, which have been reported previously [26], were observed in necropsy examination. Cast formation in the tracheal bifurcation abruptly reduced airflow, resulting in asphyxiation. It is well known that trypsin-like proteases are

necessary for the cleavage activation of the HA and thus play a key role in viral pathogenicity [6, 17]. IBLV coinfection may have provided the enzymes and enhanced H9N2 pathogenicity in this experiment. It has been reported that a trypsin-like serine protease domain is encoded by coronavirus IBV [20, 24]. The presence of similar enzymes in the field situation could possibly increase the pathogenicity of H9N2 AIV. There is general agreement that clinical signs and disease effects of AI may be far more devastating in the presence of bacterial pathogens, environmental conditions and other stresses [2, 4, 5, 8, 16, 21, 29]. For explanation of this phenomenon, other researchers have proposed various hypotheses. These hypotheses are: secretion of trypsin-like proteases by bacteria [33], stimulation of host cells to produce or secrete more protease, destruction of endogenous cell protease inhibitors [21] and suppression of the immune system due to stress by bacterial infection [16]. Our findings, including faster AIV propagation and gross lesions in the embryos inoculated with AIV + IBLV, may be due to an increase of protease activity. The extended viral shedding period in the group of AIV + IBLV-inoculated birds may affect clinical signs, postmortem examination and embryo studies.

It should be emphasized that the infectious bronchitis attenuated live vaccine increased the severity of clinical signs and postmortem findings of H9N2 infection. Field conditions under which wild strains of infectious bronchitis virus are circulating may lead to more severe clinical signs and postmortem findings.

In conclusion, the results of this study indicate that IBLV co-infection promoted the propagation of AIV and increased the pathogenicity and extended the period of H9N2 AIV shedding in broiler chickens and caused mortality under the present experimental conditions. Further research is needed in order to provide more information about the effect of strain variation of infectious bronchitis

virus and environmental factors affecting the pathogenicity of H9N2 AIV infection.

Acknowledgments Poultry Research Center of Shiraz University and contract number 83-VE-1509-102 with IVO supported this research project. We also acknowledge assistance provided by Dr. S. Nahid from Group of Veterinary Sciences of Islamic Azad University (IAU), Darab Branch.

References

- Alexander DJ (2000) A review of avian influenza. In different bird species. *Vet Microbiol* 74:3–13
- Alexander DJ (1982) Avian influenza: recent developments. *Vet Bull* 52:341–359
- Alexander DJ, Spackman D (1981) Characterization of influenza A viruses isolated from turkeys in England during March–May 1979. *Avian Pathol* 10:281–293
- Bahl AK, Pomeroy BS, Easterday BC (1975) Isolation of two turkey influenza A viruses in Minnesota. *Avian Dis* 19:374–378
- Bano S, Naeem K, Malik SA (2003) Evaluation of pathogenic potential of avian influenza virus serotype H9N2 in chickens. *Avian Dis* 47:817–822
- Bosch FX, Orlich M, Klenk HD, Rott R (1979) The structure of the hemagglutinin, a determinant for the pathogenicity of influenza viruses. *Virology* 95:197–207
- Burleson FG, Chambers TM, Wiedbrauk DL (1992) *Virology: a laboratory manual*. Academic Press, San Diego
- Byrum BR, Slemons RD (1995) Detection of proteolytic bacteria in the upper respiratory tract flora of poultry. *Avian Dis* 39:622–626
- Capua I, Alexander DJ (2004) Avian influenza: recent developments. *Avian pathol* 33:393–404
- Capua I, Marangon S (2000) The avian influenza epidemic in Italy, 1999–2000: a review. *Avian Pathol* 29:289–294
- Fouchier RA, Munster V, Wallensten A, Bestebroer TM, Herfst S, Smith D, Rimmelzwaan GF, Olsen B, Osterhaus AD (2005) Characterization of a novel influenza A virus hemagglutinin subtype (H16) obtained from black-headed gulls. *J Virol* 79:2814–2822
- Guo YJ, Krauss S, Senne DA, Mo IP, Lo KS, Xiong XP, Norwood M, Shortridge KF, Webster RG, Guan Y (2000) Characterization of the pathogenicity of members of the newly established H9N2 influenza virus lineages in Asia. *Virology* 267:279–288
- Haqshenas G, Asasi K, Akrami H (2005) Isolation and molecular characterization of infectious bronchitis virus, isolate Shiraz3. IBV, by RT PCR and restriction enzyme analysis. *Iran J Vet Res* 6:9–15
- Johnson FB (1990) Transport of viral specimens. *Clin Microbiol Rev* 3:120–131
- Johnson DC, Maxfield BC, Moulthrop JI (1977) Epidemiologic studies of the 1975 avian influenza outbreak in chickens in Alabama. *Avian Dis* 21:167–177
- Kishida N, Sakoda Y, Eto M, Sunaga Y, Kida H (2004) Coinfection of *Staphylococcus aureus* or *Haemophilus paragal-linarum* exacerbates H9N2 influenza A virus infection in chickens. *Arch Virol* 149:2095–2104
- Klenk HD, Garten W (1994) Host cell proteases controlling virus pathogenicity. *Trends Microbiol* 2:39–43
- Lazarowitz SG, Chopin PW (1975) Enhancement of the infectivity of influenza A and B viruses by proteolytic cleavage of the hemagglutinin polypeptide. *Virology* 68:440–454
- Lennette DA (1995) Collection and preparation of specimens for virological examination. In: Murray PR, Baron EJ, Pfaller MA, Tenover FC, Tenover RH (eds) *Manual of clinical microbiology*, 6th edn. ASM Press, Washington DC, pp 868–875
- Liu DX, Brierley I, Brown TD (1995) Identification of a trypsin-like serine proteinase domain encoded by ORF 1a of the coronavirus IBV. *Adv Exp Med Biol* 380:405–411
- Mancini DAP, Mendonca RMZ, Dias ALF, Mendonca RZ, Pinto JR (2005) Co-infection between influenza virus and flagellated bacteria. *Rev Inst Med Trop Sao Paulo* 47:275–280
- Mo IP, Brugh M, Fletcher OJ, Rowland GN, Swayne DE (1997) Comparative pathology of chickens experimentally inoculated with avian influenza viruses of low and high pathogenicity. *Avian Dis* 41:125–136
- Nagai Y (1993) Protease-dependent virus tropism and pathogenicity. *Trends Microbiol* 1:81–87
- Ng LFP, Liu DX (2000) Further characterization of the coronavirus infectious bronchitis virus 3C-like proteinase and determination of a new cleavage site. *Virology* 272:27–39
- Nili H, Asasi K (2003) Avian influenza (H9N2) outbreak in Iran. *Avian Dis* 47:828–831
- Nili H, Asasi K (2002) Natural cases and experimental study of H9N2 avian influenza in commercial broiler chickens of Iran. *Avian Pathol* 31:247–252
- Purchase HG, HArp L, Domermuth CH, Pearson JE (1989) *A laboratory manual for the isolation and identification of avian pathogens*, 3rd edn. Kendall-Hunt, Dubuque
- Reed LJ, Muench H (1938) A simple method for estimating fifty percent endpoints. *Am J Hyg* 27:493–497
- Scheiblaue H, Reinacher M, Tashiro M, Rott R (1992) Interactions between bacteria and influenza A virus in the development of influenza pneumonia. *J infect Dis* 166:783–791
- Stieneke-Grober A, Vey M, Angliker H, Shaw E, Thomas G, Roberts C, Klenk HD, Garten W (1992) Influenza virus hemagglutinin with multibasic cleavage site is activated by furin, a subtilisin-like endoprotease. *EMBO J* 11:2407–2414
- Swayne DE, Suarez DL (2000) Highly pathogenic avian influenza. *Rev Sci Tech Off Inter Epiz* 19:463–482
- Swayne DE (1997) Pathobiology of H5N2 Mexican avian influenza virus infection of chickens. *Vet Pathol* 34:557–567
- Tashiro M, Ciborowski P, Klenk HD, Pulverer G, Rott R (1987) Role of *Staphylococcus* protease in the development of influenza pneumonia. *Nature* 325:536–537
- Vasfi Marandi M, Bozorgmehrifard MH (1999) An outbreak of non-highly pathogenic avian influenza in chicken in Iran. Proceedings of the 61st meeting of the World Veterinary Association (CD-ROM), France 1999