

**Biological and pathological consequences
of feline infectious peritonitis virus infection in the cheetah**

Brief Review

J. F. Evermann¹, J. L. Heeney², M. E. Roelke³, A. J. McKeirnan¹, and S. J. O'Brien²

¹ Department of Veterinary Clinical Medicine and Surgery, College of Veterinary Medicine, Washington State University, Pullman, Washington

² Section of Genetics, National Cancer Institute, Frederick, Maryland

³ Wildlife Research Laboratory, Gainesville, Florida, U.S.A.

Accepted July 29, 1988

Summary. An epizootic of feline infectious peritonitis in a captive cheetah population during 1982–1983 served to focus attention on the susceptibility of the cheetah (*Acinonyx jubatus*) to infectious disease. Subsequent observations based upon seroepidemiological surveys and electron microscopy of fecal material verified that cheetahs were indeed capable of being infected by coronaviruses, which were antigenically related to coronaviruses affecting domestic cats, i.e. feline infectious peritonitis virus/feline enteric coronavirus. Coincident with the apparent increased susceptibility of the cheetah to infectious diseases, were observations that the cheetah was genetically unusual insofar as large amounts of enzyme-encoding loci were monomorphic, and that unrelated cheetahs were capable of accepting allogenic skin grafts. These data provided the basis for a hypothesis that the cheetah, through intensive inbreeding, had become more susceptible to viral infections as a result of genetic homogeneity.

Introduction

Research aimed toward understanding the pathogenesis of viral infections of endangered species constitutes a major component of the species survival management plan for the cheetah [38, 56]. One of the primary reasons for this emphasis was the recent occurrence of a devastating epizootic of feline coronavirus infection (feline infectious peritonitis [FIP]) in captive cheetahs in 1982–1983 [26, 29, 72]. Since that time, there have been other reports on the apparent susceptibility of the cheetah to infectious diseases with emphasis on FIP [4, 10, 38, 62, 63, 93]. Since there are currently no vaccines available for control of FIP in either domestic or exotic cat populations it is essential that biologists,

diagnosticians, and veterinarians be aware of the impact that this infection has upon the cheetah, so that appropriate management steps can be taken to minimize the chance for infection and thereby lessen the risk of fatal disease. The purpose of this review is to present descriptions of the various forms of coronaviral infections in the cheetah relying upon studies of both natural infections, as well as experimental infections in other species with coronaviruses, such as mouse hepatitis virus (MHV), canine coronavirus (CCV), transmissible gastroenteritis virus (TGEV) of swine, and bovine coronavirus (BCV) of neonatal calves [28, 36, 39, 49, 57, 60, 61, 75, 79, 92].

Biological features of the feline coronaviruses

Historical perspective

The biology of the feline coronaviruses has a short history since isolates were not available for laboratory studies until 1976 [see 66 for review]. Prior to that time, the disease was referred to as feline systemic proliferative and exudative vasculitis [30, 40], and later feline infectious peritonitis (FIP) [91]. Recognition of the first coronavirus associated with FIP in cats was determined by electron microscopy in 1970 [86]. Inasmuch as cell culture-adapted isolates of the FIP virus (FIPV) were not yet available, the disease condition was experimentally transmitted by the inoculation of liver homogenates from diseased cats into the peritoneal cavity of susceptible cats. During the period of experimental transmission of FIP by tissue homogenates, serologic assays were developed which utilized indirect immunofluorescence on cryostat sections of liver obtained from cats with clinical FIP [66]. Subsequent serologic studies relied upon cell culture-grown homologous virus, FIPV, or heterologous cross-reacting coronavirus strains, such as CCV and TGEV [25, 33, 42–44, 59, 66].

Seroprevalence studies conducted during the 1970s indicated that certain populations of cats had a high percentage of antibody, suggesting that either FIPV was not 100% fatal as was generally believed, or that cats were also being

Table 1. Spectrum of virulence for the feline coronaviruses^a

Virulence			
Non-FIP inducing	Low ^b	Moderate ^c	High ^d
FECV UCD ^e	FIPV UCD-2	FIPV UCD-1	FIPV WSU 79-1146
FECV WSU 79-1683	FIPV UCD-3		FIPV TN 406
	FIPV UCD-4		FIPV NOR-15

^a Modified from [27]

^b Persistent (chronic carrier), FIP occurs when cat is immunosuppressed; i.e., concurrent FeLV infection

^c Dose-related disease via oronasal route

^d Low dose results in 100% fatality by oronasal route

^e Infectious for cats only; i.e., no in vitro model

infected by a coronavirus that cross-reacted with FIPV [66]. In 1981, this dilemma was partially resolved with the isolation of a strain of coronavirus from cats that mimicked FIPV *in vitro*, but did not cause FIP when inoculated into cats by various routes [59, 69]. The virus was subsequently referred to as feline enteric coronavirus (FECV) [4, 66, 68, 69]. Since those initial reports on the divergent nature of feline coronaviruses and the designation of FIPV and FECV strains, there have been additional reports on the detection and/or isolation of feline coronaviruses [4, 66]. The spectrum of disease resulting from these various isolates is presented in Table 1. Although there are marked phenotypic differences in terms of *in vivo* virulence, efforts to distinguish FECV strains from FIPV strains *in vitro* have not been successful [8, 31, 32, 85]. It is conceivable that molecular technology will reveal differences at the genomic level, which reflect variation in strain virulence or pathology [18, 19, 46, 7]. Diagnostic molecular procedures would be useful in the detection of cats that were shedding FIPV into the environment. However, if FIPV is the progeny of a random mutation from FECV, or a recombinant of two enteric coronaviruses, then the application would vary according to the frequency of these mutational events [51, 54, 66, 70, 78, 80, 90].

Cheetah coronavirus

Although the majority of research on the feline coronaviruses has been conducted in domestic cats, access to serologic tests has allowed investigators to test serum from other Felidae, as well as from closely related members of the cat family, such as the cheetah [43, 66]. The serologic results, as well as reports of sporadic cases of FIP in cheetahs, indicated that they were susceptible to infection and in some cases succumbed to disease [10, 26, 29, 43, 62]. The susceptibility of the cheetah to FIP was of particular interest during an outbreak of the disease in a wildlife park in 1982–1983 [26, 29]. In this incident, an infected cheetah was imported to the facility, which was a leading center for breeding cheetahs in North America. A retrospective serologic survey of the resident cheetah ($n=35$) population showed that all were seronegative to the feline coronaviruses by IFA prior to June, 1982. Within a year, every cheetah at the facility had developed IFA antibodies to the feline coronaviruses and a high percentage developed clinical symptoms (diarrhea, anorexia, peritonitis). Within 3 years, 19 of the 35 (54%) cheetahs succumbed to FIP-related disease. The epizootic was considered to be the largest die-off of captive cheetahs from FIP in recorded history [26]. Although the factors which allowed the epizootic to occur are still being investigated, there are several points that emerged which lend support to the observation that at least two factors were vitally important. These included: (1) an unusually uniform susceptibility of the resident population of cheetahs; and (2) the introduction of a particular strain of pathogenic coronavirus [27, 56, 62]. The susceptibility of the cheetah to FIPV will be addressed in later sections pertaining to the immunological features and genetic

predisposition. The coronavirus infecting cheetahs appears distinct from other strains previously isolated from domestic cats, although serologic studies by indirect immunofluorescence, virus neutralization and Western blotting have indicated that cheetahs are being infected by an antigenically related virus [10, 26, 38, 43]. Indeed, it cannot be excluded that the cheetah has at least two populations of coronavirus, one being a cheetah enteric coronavirus, and the other being a cheetah infectious peritonitis virus.

Biological properties of the cheetah virus in vitro

Infectious agents were isolated in Crandell feline kidney (CrFK) cells from tissues submitted from 3 cheetahs that died during the FIP epizootic of 1982–1983 [26, 29]. A common feature of the isolates was their reduced cytopathic effect (CPE) in CrFK cells and cytoplasmic immunofluorescence when stained with antisera to a strain of moderate virulence, FIPV UCD-1 (Fig. 1a, b, c) [27]. Another differentiating feature was the lack of cell fusion (syncytia) for the cheetah virus when compared with other feline coronavirus strains, FECV 79-1683 and FIPV 79-1146 [27].

The cheetah virus has been maintained in cell culture as a persistent non-cytolytic infection [27, 29]. However, infected cells do express periods of cytopathogenicity referred to as “crisis periods”, but following each crisis, cells emerge and the infection is maintained. Assays for cell-free virus have been hampered due to the low release of extracellular virus. Ultrastructural studies conducted on the cells persistently infected by the cheetah coronavirus have revealed the presence of virus particles in cytoplasmic vacuoles, but minimal virus at the cell surface [27]. This is in contrast to the high number of virus particles observed, both within virus-infected cells, as well as at the surface of cells with the cytopathogenic coronaviruses, FECV 79-1683 and FIPV 79-1146 [27].

The phenotypic parameters of the cheetah coronavirus in vitro indicate that the virus is a biological variant of a virulent coronavirus or is in a partially nonpermissive host cell [27]. This is further suggested by its cell-associated nature and the lack of cell fusion capability, which would indicate incomplete expression of the essential E2 protein (fusion protein) [21, 37, 39, 82]. This observation may be due to a partially defective virus [55] or to a virus which fails to mature properly due to the absence of a host-cell protease [39, 89]. The cheetah agent represents the least virulent in cell culture as compared with other feline coronaviruses (Table 1) except for FECV UCD, which has not yet been cultured in vitro, but must be maintained by passage through cats [66, 68].

Enzymatic enhancement of coronavirus replication and expression of CPE in vitro have been reported for a number of different coronaviruses including BCV and TGEV [2, 13, 14, 58, 84]. The addition of low amounts of trypsin (5 µg/ml) to serum-free culture media enhances the CPE of the feline corona-

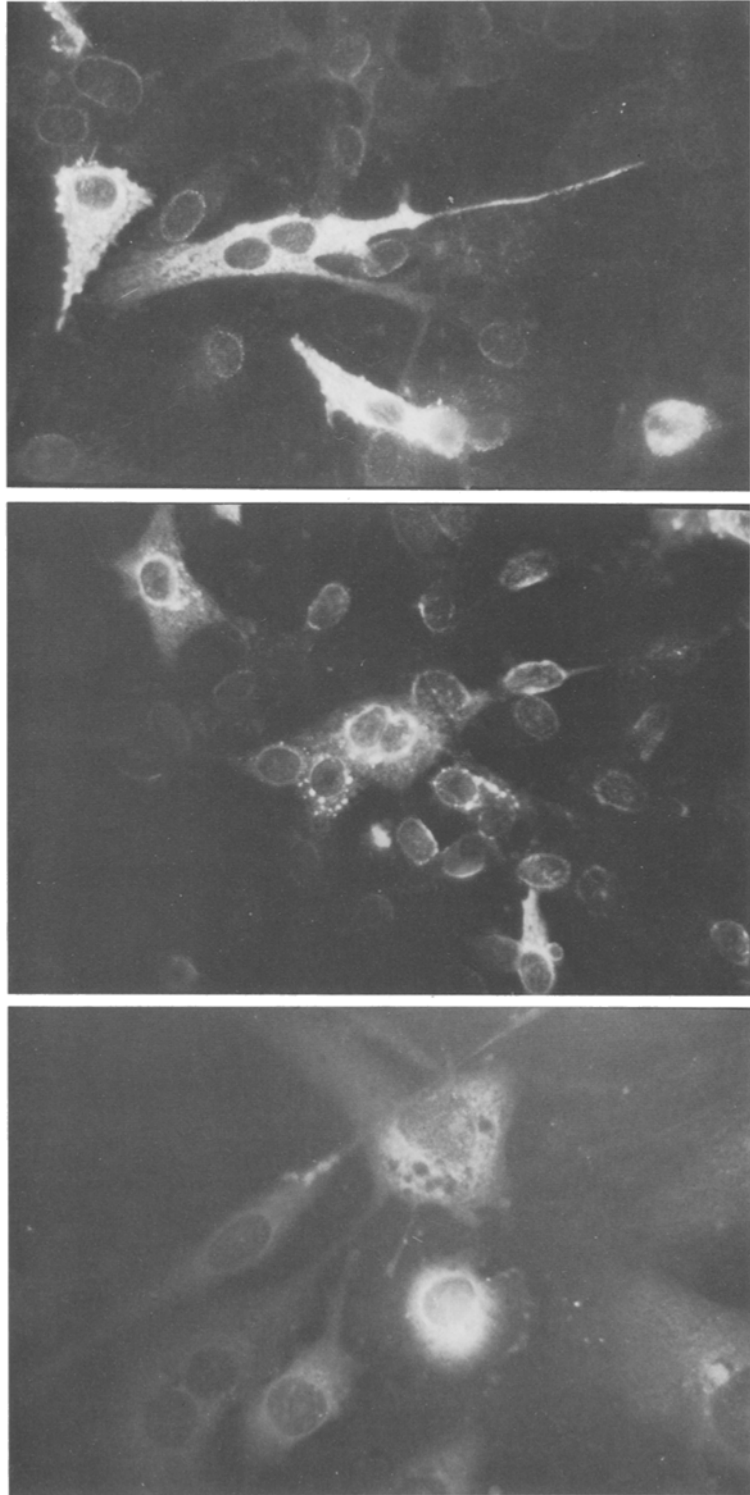


Fig. 1. Immunofluorescence staining of feline coronaviruses and cheetah coronavirus in Crandell feline kidney cells. **a** FECV 79-1683 antigen stained by cat antisera to FECV 79-1683; **b** FECV 79-1683 antigen substrate stained by cheetah serum (IFA titer 1:3,200). Note perinuclear fluorescence; and **c** cheetah coronavirus 83-4497 antigen stained by cat antisera to FIPV UCD-1 \times 160

viruses FIPV UCD-1 and FIPV UCD-4, and also appears to augment the expression of the cheetah coronavirus [27]. Studies on the effects of trypsin on various coronavirus strains, including FECV and FIPV, have suggested that trypsin-sensitive and trypsin-resistant phenotypes occur in nature [13, 58]. Those strains that are highly resistant have been hypothesized to survive longer in the gastrointestinal tract and therefore be infectious longer, both for the infected host, as well as for other susceptible animals in the population which come in contact with the shedding host [15, 16].

Transmission of the coronaviruses

Initially, definitive information on the natural spread of the feline coronaviruses was hampered due to the lack of cell-free virus; however, subsequent studies with cell-free virus strains have indicated that the oronasal route of infection is the most likely natural route of virus entry [25, 66–70]. These observations are consistent with the pathogenesis of other coronaviruses, such as MHV, CCV, TGEV, and BCV in which the fecal-oral and aerosol routes of virus spread have been well documented [5, 6, 15, 36, 50]. Other possible sources of coronavirus entry could be by direct inoculation (needles, cat bites), or by the licking of open wounds [29, 57].

The incubation periods for feline coronavirus infections are variable depending upon the dose and strain of virus and the age of and route of entry into the host. Pedersen has conducted the most definitive studies to date on the pathogenicity of the viruses [66, 70]. His results indicated an incubation period of 4–12 days for FECV-induced enteric infection, and 8 days to 3 months for the FIPV strains. In some cases the outcome of FIPV infection is dependent upon concurrent immunosuppression such as may occur with feline leukemia virus infection [70].

Clinical features and differential diagnosis

The clinical features of the feline coronaviruses in domestic cats and cheetahs appear to be very similar [4, 7, 29, 66, 72, 74]. Symptoms in domestic cats following FECV infection may range from subclinical to a mild diarrhea in uncomplicated cases [66]. Although not well documented in cats, multiple enteric infections with other viruses or bacteria should be considered in making a differential diagnosis. This has been reported to be the case in dogs with concurrent CCV and canine parvovirus infections [28].

The clinical manifestations of FIP include anorexia, icterus, and elevated serum proteins in fluids within the thoracic/abdominal cavities (wet form). Although experimental studies of FIP in cheetahs has not been conducted, information obtained from naturally occurring cases has indicated that the majority show early signs of liver dysfunction followed by periods of anorexia, dehydration and death [26, 29]. It is important to recognize that although

cheetahs appear to be very susceptible to FIP-related disease, there are other factors which may contribute to a generalized liver dysfunction, such as dietary deficiencies [34, 76].

Pathological features

Pathologic studies of cheetahs diagnosed as having FIP have many features in common with the lesions reported in domestic cats [1, 25, 26, 29, 66]. A predominant feature in the FIP lesions in cheetahs is multi-focal necrosis throughout many organs including the liver, kidneys, pancreas, spleen, lymph nodes, and thymus. The necrotic areas are characterized by karyorrhexis, karyolysis, cytolysis, and infiltration by lymphocytes and macrophages. Fibronectin plaques are present on many organs in both the pleural and peritoneal cavities. Necrotic foci containing lymphocytic infiltrates, macrophages, and neutrophils are also present in mesenteric fat and within the muscular layers of the small and large bowel. Lymphoid aggregates in the spleen and lymph nodes were depleted. The fundamental histopathological lesions are a generalized vasculitis and perivasculitis [1, 44, 66, 72, 88, 91].

Although the course of the disease and distribution of lesions bear a close resemblance to FIP in domestic cats, it is important that a complete necropsy and detailed histological examination be conducted in order to confirm the occurrence of FIP in the cheetah [93].

Several other lesions have been noted in cheetahs in addition to changes attributed to FIPV [26, 29]. The gastric mucosa of four cheetahs contained superficial erosions of mucosal epithelium. In most cases, the changes were relatively mild with hyperemia of superficial mucosal vessels, mild focal hemorrhages and mild fibrosis of the interstitium. Gastric ulcers have been observed in one cheetah. Epithelium within the gastric pits was generally intact, although fibroblastic response bridged gastric pits in some areas. A moderate interstitial infiltrate of lymphocytes, plasma cells and macrophages was associated with areas of erosion.

Immunological features

The immune response of the cat to the feline coronaviruses presents a critical factor in the pathogenesis of FIPV infection. Many of the lesions observed in cases of FIP can be directly attributed to the immune response; i.e., an immune-mediated vasculitis [1, 4, 41, 47, 66]. These findings are supported by the reports of enhancement of FIP by prior infusion of passively acquired antibody and the failure of conventional vaccine preparations to protect cats against subsequent challenge [see 66, for review].

Currently, at least three distinct cellular lineages of the cat's immune system appear to be critical in determining the outcome of FIPV infection [4, 41, 47, 48, 66, 83]. These include the macrophage, the B-cell and the T-cell populations. The macrophage appears to be one of the primary sites for FIPV replication

in vivo and was demonstrated to be a source of virus in vitro prior to the isolation of viruses in conventional cell cultures [66]. Although definitive studies have not been reported yet with FIPV, it may be predicted that cells of the monocyte-macrophage lineage are very important in conferring resistance to infection, and in subsequent immune reactions of the processed FIPV antigens with the B- and T-cell populations. Coronaviral infection of the macrophage has been reported to be one of the major criteria for distinguishing resistance and susceptibility in mice with the murine coronavirus, MHV [3, 5, 6, 9, 11, 20, 22, 52, 53]. FIP-inducing strains apparently infect and replicate in feline macrophages while non-FIP strains, e.g., the FECV strains, are primarily restricted to mucosal infections without replication in macrophages [see 66, for review].

In the majority of cases of FIP, serum antibody has been measured by the indirect immunofluorescence assay (IFA), a group-specific test that does not distinguish between antibody to FIPV and FECV [4, 26, 33, 38, 69]. Serum from cats with high IFA antibody titers has been demonstrated to enhance the pathogenesis of FIPV when passively administered to cats six hours prior to virus inoculation [66]. The role of antibody in the pathogenesis of FIP has been controversial, but is not without precedent since there are several viral infections which have been documented to have an immune-mediated disease sequelae. These include dengue fever of humans [17, 65, 87], and yellow fever virus [35]. The mechanism(s) of antibody-mediated enhancement may take the form of non-neutralizing antibodies, enhancing antibodies, or blocking antibodies (bind to/or block T-cell receptors) [see 73 for review]. A likely explanation is that certain strains of feline coronavirus, i.e., FIPV variants or mutants [51, 78, 80, 90], infect and replicate in macrophage cells, perhaps altering normal B- and T-cell interactions. The B-cell response is polyclonal and antibodies that are formed appear to detect all the major viral proteins as determined by Western blot techniques [38]. Certain types of these antibodies may serve as enhancing antibodies in terms of increased viral uptake and replication within macrophages, which are subsequently spread throughout the body.

The effectiveness of the T-cell response appears to play a critical role in controlling FIPV infection, but may also play a part in the subsequent immune-mediated pathogenesis. Impairment of the T-cell response, such as may occur during concurrent viral infection with either feline panleukopenia virus or feline leukemia virus, appears to predispose cats to FIP [66, 70, Evermann, unpublished observation]. Without T-cell surveillance of virus-infected macrophages, cell-associated viremia occurs and dispersal of virus occurs throughout the body [88]. The actual mechanism(s) of FIPV-induced tissue damage is being investigated, but may be a combination of inflammatory response with neutrophils imparting tissue damage alone or in combination with cytotoxic T cells attempting to rid tissues of virus-infected macrophages [23]. The basic lesions in FIP are a result of the cat's immune response producing large quantities of antibodies and the formation of immune complexes which are subsequently

deposited within the vessels of the serosa [41, 44, 66, 87, 88]. Persistence of viral antigens in the serosal blood vessels provokes a hypersensitivity reaction with the migration and infiltration of mononuclear cells into vessel adventitia and media, resulting in severe vascular damage [87, 88]. The outcome from the vessel damage usually includes a serous effusion and accumulation of fluid in the major body cavities. This type of immune response is characteristic of a type III hypersensitivity reaction [44, 66, 87, 88].

Immunogenetics

The genetic regulation of the immune response has been of interest in studying viral infections of animals, since it has been shown that resistance to certain viruses appears to be under genetic control [3, 6, 9, 24]. More recently, the cheetah has been shown to be genetically unusual insofar as large amounts of enzyme-encoding loci are monomorphic in natural populations [63, 64, 94]. This observation, coupled with the extraordinary finding that unrelated cheetahs would immunologically accept allogenic skin grafts, was interpreted in the context of a hypothesis that the cheetah had undergone intensive inbreeding in its recent natural history [63]. Such a situation would have significant effect upon the immune defenses against microbial pathogens. By analogy to other species, natural populations have multiple loci which are polymorphic for functions which influence the outcome of viral-induced disease outbreaks [62]. Notable amongst such genes are those forming the major histocompatibility complex, whose gene products function directly in monitoring immune response to viral infections [3, 5, 6, 94]. The genetic homogeneity of the cheetah may be an important contributing factor in the increased susceptibility of the species to viral infections, such as FIPV and feline herpesvirus [26, 71, 72].

Epidemiological features

Seroprevalence of coronavirus infection in captive and wild-caught cheetahs

Since the fatal outcome of the FIP epizootic of 1982–1983, it has been apparent that cheetahs are highly vulnerable to infection and disease from the feline coronaviruses [26, 29, 62, 63]. In an effort to determine the prevalence of feline coronavirus infection in cheetahs, a serologic survey and an electron microscopic analysis were conducted on captive and wild-caught cheetahs [38]. The serological results from captive cheetahs in 14 zoologic parks in North America (Table 2) indicated that 25 of 89 (28%) captive cheetahs were seropositive to feline coronavirus by IFA (group-specific serology test). These results were higher than those of captive cheetahs located in southern Africa and Europe, but similar to captive cheetahs in eastern Africa as well as to wild-caught cheetahs (Table 3). The serologic results indicated that the cheetahs were being infected by a virus which was antigenically related to the feline coronavirus group, and that there was a comparable risk of acquiring infection whether

Table 2. Summary of serologic studies of captive cheetahs in North America for detection of feline coronavirus infection

Zoologic facility	No. seropositive/ total no. tested	(%)	Antibody titer ^a range
A	0/8	(0)	<25
B	4/9	(44)	<25–400
C	3/5	(60)	<25–1,600
D	3/7	(43)	<25–1,600
E	9/22	(41)	<25–1,600
F	0/9	(0)	<25
G	1/1	(100)	1,600
H	2/6	(33)	<25–100
I	0/10	(0)	<25
J	1/2	(50)	25
K	0/2	(0)	<25
L	0/4	(0)	<25
M	0/1	(0)	<25
N	2/3	(66)	<25–1,600
Totals	25/89	(28)	

^a Indirect immunofluorescence assay

Table 3. Serologic studies of captive and wild-caught cheetahs in Africa and Europe

Habitat	No. seropositive/ total no. tested	(%)	Antibody titer ^a range
Captive, So. Africa	4/53	(7.5)	<25–25
Captive, E. Africa	4/12	(33)	<25–100
Captive, Europe	1/12	(8)	<25–25
Wild-caught E. Africa	4/16	(25)	<25–25
Totals	13/93	(14)	

^a Indirect immunofluorescence assay

cheetahs were in captivity in eastern Africa or in North America. The other finding was that even in the wild-caught cheetahs in eastern Africa there was a serologic response to coronavirus in 4 of 16 cheetahs (25%). These results are consistent with those of Horzinek and Osterhaus [43], who reported a high percentage of wild cheetahs with coronavirus antibodies. While these results may suggest an on-going exposure to a unique coronavirus infection in wild cheetahs, it may also reflect exposure to cross-reacting but less virulent coronaviruses that the cheetah encounters in nature, such as coronaviruses of other felids, canids, wild pigs, and wild ungulates [4, 7, 42, 43].

Management schemes

Efforts to control FIP in captive cheetahs are structured around periodic serologic testing and the segregation of cheetahs that are seropositive to feline coronaviruses by IFA. The limitations of these recommendations are the possible lack of specificity of IFA for identifying exposure to pathological variants, and the lack of complete understanding of the coronaviruses affecting cheetahs [4, 27, 38, 66]. However, until further information is reported regarding coronaviral diseases of exotic cats, especially the cheetah, then the management should follow basic guidelines for control of an infectious disease (Table 4).

Table 4. Management recommendations for handling cheetahs with feline coronavirus infection

Serologic status of cheetahs to feline coronavirus ^a	Recommendation(s)
<i>Incoming</i> --- > <i>Resident</i> Seronegative ^b --- > Seronegative	Placement without risk of feline coronavirus infection. Monitor annually. Monitor replacements prior to introduction and 60 days later
Seronegative --- > Seropositive ^b	Placement of seronegative cheetah would result in risk of infection and disease
Seropositive --- > Seropositive	Placement of seropositive cheetah would not result in any greater risk of infection; however the risk of disease would be higher based on occurrence of FIP in domestic cats in catteries
Seropositive --- > Seronegative	Placement of seropositive cheetah would result in the potential of an epizootic occurring in a susceptible population

^a Serum antibody titers of 1:25 or greater as determined by indirect immunofluorescence assay

^b Assume two types of resident collections, those cheetahs that are seronegative and those cheetahs that are seropositive. Also assume two types of incoming cheetah, i.e., seronegative and seropositive to feline coronaviruses

Conclusions

The cheetah has assumed a prominent position in the zoologic and wildlife communities due to its endangered status and its apparent increased susceptibility to microbial infections [56, 62]. These factors have emphasized the need for further research into the genetics and the diseases that may affect the cheetah in captivity, as well as in the wild [63]. Although coronaviral infections of the domestic cat have been recognized for over 2 decades, the emergence of pathogenic variants in the cheetah populations has only recently been acknowledged as having a potentially severe impact on its survival [56, 62, 66].

Primary amongst the coronaviruses affecting domestic cats is FIPV, which is regarded as being 100% fatal once clinical signs are manifested [4, 66]. The occurrence of coronaviral infections of the cheetah have now been documented based on serology, electron microscopy of fecal contents, and the occurrence of fatal forms of infectious peritonitis compatible with the clinicopathologic signs observed in domestic cats with FIP [7, 10, 26, 29, 38, 43, 56, 72].

These observations may indicate that the cheetah has acquired a unique group of coronaviruses which have antigenic similarity to the domestic cat coronaviruses or that the cheetah is susceptible to cross-species transmission of domestic cat coronaviruses [27, 38, 45, 81]. Serological studies support the contention that both situations may be important in the epizootiology of FIPV in cheetahs [26, 38, 43]. Although cheetahs in the wild have a comparable seroprevalence to the feline coronavirus group, their antibody titers are invariably lower than those titers detected in captive cheetahs during a disease outbreak [38, 43]. The seroprevalence of feline coronavirus infection in cheetahs in captivity, both in North America and Africa, indicates that the virus is transmitted with equal frequency. While evidence in support of cross-species transmission of feline coronaviruses to the cheetah is lacking, it is known that the cheetah cells are susceptible to some of the domestic cat coronaviruses in vitro [27].

It is apparent that further analysis of cheetahs in captivity needs to be conducted in order to determine more about their microbial flora and their immune response [12]. This information is essential in order to determine the risk of infection and disease from viruses such as FIPV and feline herpesvirus [71, 72]. Until more is known regarding the pathogenesis of coronaviral infections of the cheetah, it would be prudent to establish surveillance programs which utilize a combination of serologic monitoring and quarantine procedures in order to insure the survival of the cheetah in captivity [38].

Acknowledgements

The authors wish to express their appreciation to Drs. Niels Pedersen and Richard Ott for their advice and support of research on coronavirus infections of cats. Gratitude is extended to the veterinarians and zoologic park curators who assisted in the collection of samples, in particular Drs. M. Bush and D. Wildt, National Zoological Park, Washington, DC; Dr. D. G. Meltzer, Roodeplaat Research Laboratories, Sinoville 0129, Pretoria, South Africa; Dr. L. Colly, Zoological Gardens, Johannesburg 2193, South Africa; and Dr. V. J. Manton, Zoological Society of London, Dunstable Beds LV 62 LF, London, England. The authors would also like to thank J. Martenson, R. Brown, V. Harrington, and P. Dilbeck for their technical assistance.

The cheetah projects have been supported in part by the White Oak Plantation, John Lucas, Director, Yulee, Florida, 32097, and by NIH Sabbatical Assignment, Intergovernmental Personnel Program, 1987–1988 (Evermann).

References

1. August JR (1984) Feline infectious peritonitis. An immune-mediated coronaviral vasculitis. *Vet Clin North Am Small Anim Pract* 14(5): 971–984

2. Aynaud JM, Nguyen TD, Bottreau E, Brun A, Vannier P (1985) Transmissible gastroenteritis (TGE) of swine: survivor selection of TGE virus mutants in stomach juice of adult pigs. *J Gen Virol* 66: 1911–1917
3. Bang FB (1978) Genetics of resistance of animals to viruses. I. Introduction and studies in mice. *Adv Virus Res* 23: 269–348
4. Barlough JE, Stoddart CA (1988) Feline coronaviral infections. In: Greene CE (ed) *Infectious diseases of the dog and cat*, 2nd edn. Saunders, Philadelphia (in press)
5. Barthold SW (1987) Host age and genotypic effects on enterotropic mouse hepatitis virus infection. *Lab Anim Sci* 37: 36–40
6. Barthold SW, Smith AL (1987) Response of genetically susceptible and resistant mice to intranasal inoculation with mouse hepatitis virus JHM. *Virus Res* 7: 225–239
7. Bland van den Berg P, Botha WS (1977) Feline infectious peritonitis in South Africa. *J S Afr Vet Assoc* 48: 109–116
8. Boyle JF, Pedersen NC, Evermann JF, McKeirnan AJ, Ott RL, Black JW (1984) Plaque assay, polypeptide composition and immunochemistry of feline infectious peritonitis virus and feline enteric coronavirus isolates. In: Rottier PJM, van der Zeijst BAM, Spaan WJM, Horzinek MC (eds) *Molecular biology and pathogenesis of coronaviruses*. Plenum Press, New York, pp 133–147
9. Boyle JF, Weismiller DG, Holmes KV (1987) Genetic resistance to mouse hepatitis virus correlates with absence of virus-binding activity on target tissues. *J Virol* 61: 185–189
10. Briggs MB, Evermann JF, McKeirnan AJ (1986) Feline infectious peritonitis. An update of a captive cheetah population. *Fel Pract* 16: 13–16
11. Carman PS, Ernst PB, Rosenthal KL, Clark DA, Befus AD, Bienenstock J (1986) Intraepithelial leukocytes contain a unique subpopulation of NK-like cytotoxic cells active in the defense of gut epithelium to enteric murine coronavirus. *J Immunol* 136: 1548–1553
12. Caro TM, Hold ME, Fitzgibbon CD, Bush M, Hawkey CM, Kock RA (1987) Health of adult free-living cheetahs. *J Zool (London)* 212: 573–584
13. Chen K-S (1985) Enzymatic and acidic sensitivity profiles of selected virulent and attenuated transmissible gastroenteritis viruses of swine. *Am J Vet Res* 46: 632–636
14. Chen K-S, Kahn DE (1985) A double-protease-resistant variant of transmissible gastroenteritis virus and its ability to induce lactogenic immunity. *Am J Vet Res* 46: 1632–1636
15. Collins JK, Riegel CA, Olson JD, Fountain A (1987) Shedding of enteric coronavirus in adult cattle. *Am J Vet Res* 48: 361–365
16. Crouch CF, Bielfeldt Ohmann H, Watts TC, Babiuk LA (1985) Chronic shedding of bovine enteric coronavirus antigen-antibody complexes by clinically normal cows. *J Gen Virol* 66: 1489–1500
17. Daughaday CC, Brandt WE, McCown JM, Russell PK (1981) Evidence for two mechanisms of dengue virus infection of adherent human monocytes: trypsin-sensitive virus receptors and trypsin-resistant immune complex receptors. *Infect Immun* 32: 469–473
18. De Groot FJ, Maduro J, Lenstra JA, Horzinek MC, van der Zeijst BAM, Spaan WJ (1987) cDNA cloning and sequence analysis of the gene encoding the peplomer protein of feline infectious peritonitis virus. *J Gen Virol* 68: 2639–2646
19. De Groot RJ, Ter Haar RJ, Horzinek MC, van der Zeijst BAM (1987) Intracellular RNAs of the feline infectious peritonitis coronavirus strain 79–1146. *J Gen Virol* 68: 995–1002
20. Dindzans JV, Skamene E, Levy GA (1986) Susceptibility/resistance to mouse hepatitis virus strain 3 and macrophage procoagulant activity are genetically linked and controlled by two non-H-2-linked genes. *J Immunol* 137: 2355–2360

21. Dubois-Dalcq M, Holmes KV, Rentier B (1984) Assembly of *Coronaviridae*. In: Dubois-Dalcq M, Holmes KV, Rentier B, Kingsbury DW (eds) Assembly of enveloped RNA viruses. Springer, Wien New York, pp 100–119
22. Dupuy JM, Levy-Leblond E, Le Prévost C (1975) Immunopathology of mouse hepatitis virus type 3 infection. II. Effect of immunosuppression in resistance mice. *J Immunol* 114: 226–230
23. Emancipator SN, Lamm ME (1986) Pathways of tissue injury initiated by humoral immune mechanisms. *Lab Invest* 54: 475–478
24. Esa AH, Reissig M (1985) Influences of nutrition on immunity and susceptibility to mouse hepatitis virus type 2. *Immunology* 55: 539–545
25. Evermann JF, Baumgartner L, Ott RL, Davis EV, McKeirnan AJ (1981) Characterization of a feline infectious peritonitis virus isolate. *Vet Pathol* 18: 256–265
26. Evermann JF, Burns G, Roelke ME, McKeirnan AJ, Greenlee A, Ward AC, Pfeifer M (1984) Diagnostic features of an epizootic of feline infectious peritonitis in captive cheetahs. *Am Assoc Vet Lab Diag Proc* 26: 365–382
27. Evermann JF, Heeney JL, McKeirnan AJ, O'Brien SJ (1988) Comparative features of a coronavirus isolated from a cheetah with feline infectious peritonitis. *Virus Res*, submitted for publication
28. Evermann JF, McKeirnan AJ, Eugster AK, Solozano RF, Collins JK, Black JW, Kim JS (1988) Update on canine coronavirus infections and interactions with other enteric pathogens of the dog. *Comp Anim Pract* 2: 15–23
29. Evermann JF, Roelke ME, Briggs MB (1986) Clinical and diagnostic features of feline coronavirus infections of cheetahs. *Fel Pract* 26: 21–30
30. Feldmann BM, Jortner BS (1964) Clinicopathologic conference [Feline systemic proliferative and exudative vasculitis]. *J Am Vet Med Assoc* 144: 1409–1420
31. Fiscus SA, Rivoire BL, Teramoto YA (1987) Epitope-specific antibody responses to virulent and avirulent feline infectious peritonitis virus isolates. *J Clin Microbiol* 25: 1529–1534
32. Fiscus SA, Teramoto YA (1987) Functional differences in the peplomer glycoproteins of feline coronavirus isolates. *J Virol* 61: 2655–2657
33. Fiscus SA, Teramoto YA, Mildbrand MM, Knisley CV, Winston SE, Pedersen NC (1985) Competitive enzyme immunoassay for the rapid detection of antibodies to feline infectious peritonitis virus polypeptides. *J Clin Microbiol* 22: 395–401
34. Gosselin SJ, Loudy DL, Tarr MJ, Balistreri WF, Setchell KDR, Johnston JO, Kramer LW, Dresser BL (1988) Venous-occlusive disease of the liver in captive cheetah. *Vet Pathol* 25: 48–57
35. Gould EA, Buckley A, Groeger BK, Cane PA, Doenhoff M (1987) Immune enhancement of yellow fever virus neurovirulence for mice: studies of mechanisms involved. *J Gen Virol* 68: 3105–3112
36. Haelterman EO (1972) On the pathogenesis of transmissible gastroenteritis of swine. *J Am Vet Med Assoc* 160: 534–540
37. Haywood AM (1986) Patterns of persistent viral infections. *N Engl J Med* 315: 939–948
38. Heeney JL, Evermann JF, McKeirnan AJ, O'Brien SJ (1988) Prevalence and implications of coronavirus infections in captive and free-ranging cheetah populations. *J Virol*, submitted for publication
39. Holmes KV, Boyle JF, Williams RK, Stephensen CB, Robbins SG, Bauer EC, Duchala CS, Frana MF, Weismiller D, Compton S, McGowan J, Sturman LS (1987) Processing of coronavirus proteins and assembly of virions. In: Briton, MA, Rueckert RR (eds) Positive strand RNA viruses. Alan Liss, New York, pp 339–349
40. Holzworth JK (1963) Some important disorders of cats. *Cornell Vet* 53: 157–160

41. Horzinek MC, Ederveen J, Egberink H, Jacobse-Geels HEL, Niewold T, Prins J (1986) Virion polypeptide specificity of immune complexes and antibodies in cats inoculated with feline infectious peritonitis virus. *Am J Vet Res* 47: 754–761
42. Horzinek M, Lulz H, Pedersen NC (1982) Antigenic relationships among homologous structural polypeptides of porcine, feline and canine coronaviruses. *Infect Immun* 37: 1148–1155
43. Horzinek MC, Osterhaus ADME (1979) Feline infectious peritonitis: a worldwide serosurvey. *Am J Vet Res* 40: 1487–1492
44. Horzinek MC, Osterhaus ADME (1979) The virology and pathogenesis of feline infectious peritonitis. *Arch Virol* 59: 1–15
45. Hoshino Y, Scott FW (1980) Coronavirus-like particles on the feces of normal cats. *Arch Virol* 63: 147–152
46. Jacobs L, de Groot R, van der Zeijst BAM, Horzinek MC, Spaan W (1987) The nucleotide sequence of the peplomer gene of porcine transmissible gastroenteritis virus (TGEV): comparison with the sequence of the peplomer protein of feline infectious peritonitis virus (FIPV). *Virus Res* 8: 363–371
47. Jacobse-Geels HEL, Daha MR, Horzinek MC (1982) Antibody, immune complexes and complement activity fluctuations in kittens with experimentally induced feline infectious peritonitis. *Am J Vet Res* 43: 666–670
48. Jacobse-Geels H, Horzinek MC (1983) Expression of feline infectious peritonitis coronavirus antigens on the surface of feline macrophage-like cells. *J Gen Virol* 64: 1885–1866
49. Jimenez G, Correa I, Melgosa MP, Bullida MJ, Enjvanes L (1986) Critical epitopes in transmissible gastroenteritis virus neutralization. *J Virol* 60: 131–139
50. Keenan KP, Jervis HR, Marchwicki RH, Binn LN (1976) Intestinal infection of neonatal dogs with canine coronavirus 1–71: studies by virologic, histologic, histochemical, and immunofluorescent techniques. *Am J Vet Res* 37: 247–256
51. Lai MMC, Baric RC, Makino S, Keck JG, Egbert J, Leibowitz JL, Stohlman SA (1985) Recombination between nonsegmented RNA genomes of murine coronaviruses. *J Virol* 56: 449–456
52. LePrévost C, Levy-Lebland E, Virelizier JL, Dupuy JM (1975) Immunopathology of mouse hepatitis virus type 3 infection. I. Role of humoral and cell-mediated immunity in resistance mechanisms. *J Immunol* 114: 221–225
53. LePrévost C, Virelizier JL, Dupuy JM (1975) Immunopathology of mouse hepatitis virus type 3 infection. III. Clinical and virologic observation of a persistent viral infection. *J Immunol* 115: 640–643
54. Makino S, Keck JG, Stohlman SA, Lai MMC (1986) High-frequency RNA recombination of murine coronaviruses. *J Virol* 57: 729–737
55. Makino S, Shieh C-K, Keck JG, Lai MMC (1988) Defective-interfering particles of murine coronavirus: mechanism of synthesis of defective viral RNAs. *Virology* 163: 104–111
56. Marker L, O'Brien SJ (1988) Captive breeding of the cheetah (*Acinonyx jubatus*) in North American zoos (1871–1986). *Zoo Biol*, in press
57. Martin ML (1985) Canine coronavirus enteritis and a recent outbreak following modified live virus vaccination. *Compend Cont Educ Pract Vet* 7: 1012–1017
58. McKeirnan AJ, Evermann JF, Davis EV, Ott RL (1987) Comparative properties of feline coronaviruses in vitro. *Canad J Vet Res* 51: 212–216
59. McKeirnan AJ, Evermann JF, Hargis A, Miller LM, Ott RL (1981) Isolation of feline coronaviruses from two cats with diverse disease manifestations. *Fel Pract* 11: 16–20
60. McNulty MS, Bryson DG, Allan GM, Logan EF (1984) Coronavirus infection of the bovine respiratory tract. *Vet Microbiol* 9: 425–434

61. Nguyen TD, Bottreau E, Bernard S, Lantier I, Aynaud JM (1986) Neutralizing secretory IgA and IgG do not inhibit attachment of transmissible gastroenteritis virus. *J Gen Virol* 67: 939–943
62. O'Brien SJ, Evermann JF (1988) Interactive influence of infectious disease and genetic diversity in natural populations. *Trends Ecol Evol*, in press
63. O'Brien SJ, Roelke ME, Marker L, Newman A, Winkler CA, Meltzer D, Colly L, Evermann JF, Bush M, Wildt DE (1985) Genetic basis for species vulnerability in the cheetah. *Science* 227: 1428–1434
64. O'Brien SJ, Wildt DE, Goldman D, Merrill CR, Bush M (1983) The cheetah is depauperate in genetic variation. *Science* 221: 459–462
65. Pang T (1983) Delayed-type hypersensitivity: probable role in the pathogenesis of dengue hemorrhagic fever/dengue shock syndrome. *Rev Infect Dis* 5: 346–352
66. Pedersen NC (1987) Coronavirus disease (coronavirus enteritis, feline infectious peritonitis). In: Holzworth J (ed) *Diseases of the cat*. WB Saunders, Philadelphia, pp 193–214
67. Pedersen NC, Boyle JF, Floyd K (1981) Infection studies in kittens using feline infectious peritonitis virus propagated in cell culture. *Am J Vet Res* 42: 363–367
68. Pedersen NC, Boyle JF, Floyd K, Fudge A, Barker J (1981) An enteric coronavirus infection of cats and relationship to feline infectious peritonitis. *Am J Vet Res* 42: 368–377
69. Pedersen NC, Evermann JF, McKeirnan AJ, Ott RL (1984) Pathogenicity studies of feline coronavirus isolates 79-1146 and 79-1683. *Am J Vet Res* 45: 2580–2585
70. Pedersen NC, Floyd K (1985) Experimental studies with three new strains of feline infectious peritonitis virus: FIPV-UCD 2, FIPV-UCD 3 and FIPV-UCD 4. *Compend Cont Educ Pract Vet* 7: 1001–1011
71. Pernikoff DS, Sundberg JP, Miller RE, Boever WJ, Scherba G (1986) Eosinophilic ulcers in association with herpetic dermatitis in sibling cheetahs. *Proc Am Zool Assoc* 1985, 145 (Abstr)
72. Pfeifer ML, Evermann JF, Roelke ME, Gallina AM, Ott RL, McKeirnan AJ (1983) Feline infectious peritonitis in a captive cheetah. *J Am Vet Med Assoc* 183: 1317–1319
73. Porterfield JS (1986) Antibody-dependent enhancement of viral infectivity. *Adv Virus Res* 31: 335–356
74. Quesenberry KE (1984) Infectious disease of nondomestic cats. *Vet Clin North Am Small Anim Pract* 14: 1089–1106
75. Saif LJ, Redman DR, Moorhead PD, Theil KW (1986) Experimentally induced coronavirus infections in calves: viral replication in the respiratory and intestinal tracts. *Am J Vet Res* 47: 1426–1432
76. Setchell KDR, Gosselin SJ, Welsh MB, Johnston JO, Balistreri WF, Kramer LW, Dresser BL, Tarr MJ (1987) Dietary estrogen—a probable cause of infertility and liver disease in captive cheetahs. *Gastroenterology* 93: 225–233
77. Shockley LJ, Kapke PA, Lapps W, Brian DA, Potgieter LND, Woods R (1987) Diagnosis of porcine and bovine enteric coronavirus infections using cloned cDNA probes. *J Clin Microbiol* 25: 1591–1596
78. Smith DB, Inglis SC (1987) The mutation rate and variability of eukaryotic viruses: an analytical review. *J Gen Virol* 68: 2729–2740
79. Sprino PJ, Ristic M (1982) Intestinal, pulmonary, and serum antibody responses of feeder pigs exposed to transmissible gastroenteritis virus by the oral and the oral-intranasal routes of inoculation. *Am J Vet Res* 43: 255–261
80. Steinhauer DA, Holland JJ (1987) Rapid evolution of RNA viruses. *Ann Rev Microbiol* 41: 409–433
81. Stoddart CA, Barlough JE, Scott FW (1984) Experimental studies of a coronavirus and coronavirus-like agent in a barrier-maintained feline breeding colony. *Arch Virol* 79: 85–94

82. Sturman LS, Ricard CS, Holmes KV (1985) Proteolytic cleavage of the E 2 glycoprotein of murine coronavirus: activation of cell-fusing activity of virions by trypsin and separation of two different 90 K cleavage fragments. *J Virol* 56: 904–911
83. Takenouchi T, Ami Y, Hayashi T, Fujiwara K (1985) Role of T cells in feline infectious peritonitis virus infection of suckling mice. *Jpn J Vet Sci* 47: 465–468
84. Toth TE (1982) Trypsin-enhanced replication of neonatal calf diarrhea coronavirus in bovine embryonic lung cells. *Am J Vet Res* 43: 967–972
85. Tupper GT, Evermann JF, Russell RG, Thouless ME (1987) Antigenic and biological diversity of feline coronaviruses: feline infectious peritonitis and feline enteritis virus. *Arch Virol* 96: 29–38
86. Ward JM (1970) Morphogenesis of a virus in cats with experimental feline infectious peritonitis. *Virology* 41: 191–194
87. Weiss RC, Scott FW (1981) Antibody-mediated enhancement of disease in feline infectious peritonitis: comparisons with dengue hemorrhagic fever. *Comp Immunol Microbiol Infect Dis* 4: 175–189
88. Weiss RC, Scott FW (1981) Pathogenesis of feline infectious peritonitis: nature and development of viremia. *Am J Vet Res* 42: 382–390
89. Wellink J, van Kammen A (1988) Proteases involved in the processing of viral polyproteins. *Arch Virol* 98: 1–26
90. Whitaker-Dowling P, Youngner JS (1987) Viral interference-dominance of mutant viruses over wild-type viruses in mixed infections. *Microbiol Rev* 51: 179–191
91. Wolfe LG, Griesemer RA (1971) Feline infectious peritonitis: review of gross and histopathologic lesions. *J Am Vet Med Assoc* 158: 987–993
92. Woods RD, Cheville NF, Gallagher JE (1981) Lesions in the small intestine of newborn pigs inoculated with porcine, feline and canine coronaviruses. *Am J Vet Res* 42: 1163–1169
93. Worley M (1987) Feline coronavirus. In: Appel MJ (ed) *Virus infections of carnivores*. Elsevier, New York, pp 431–436
94. Yuhki N, O'Brien SJ (1988) Genetic variation of major histocompatibility complex class I genes in various species: the lack of polymorphism in the African cheetah. *Immunogenetics*, in preparation

Authors' address: Dr. James F. Evermann, Department of Veterinary Clinical Medicine and Surgery, College of Veterinary Medicine, Washington State University, Pullman, WA 99164-7010, U.S.A.

Received July 23, 1988