

# Neonatal Necrotizing Enterocolitis Inflammatory Bowel Disease of the Newborn

DAVID P. CHEROMCHA, MD, and PAUL E. HYMAN, MD

---

*Neonatal necrotizing enterocolitis is the most common serious gastrointestinal disorder encountered in neonatal intensive care units. It is a major cause of morbidity and mortality in the newborn, particularly in premature infants. Consistent risk factors are birth weight and prematurity. Polycythemia and hyperviscosity altering blood flow and infectious agents are also implicated. Clinical findings include abdominal distention and diarrhea, and systemic symptoms such as apnea, acidosis, and lethargy. Pneumatosis intestinalis can be demonstrated radiographically. Mucosal ulcerations, hemorrhage, and thrombosis occur early, followed by inflammatory changes. Later still necrosis develops. Ischemia, infection, and enteral feedings are suspected to be involved in the pathophysiology. Eicosanoids, especially thromboxane, platelet-activating factor, and leukotrienes are likely mediators.*

---

**KEY WORDS:** necrotizing enterocolitis; premature infants; neonate; thromboxane.

Neonatal necrotizing enterocolitis (NEC) is the most common and most serious gastrointestinal disorder encountered in neonatal intensive care units. NEC is a major cause of morbidity and mortality in the newborn, particularly premature infants. A collaborative study conducted by the Centers for Disease Control estimated the overall incidence of NEC to be 2.4% (range 1–5% in 12 neonatal centers) of all neonatal ICU admissions (1). A more recent report from the National Collaborative Study on Patent Ductus Arteriosus in Premature Infants (1979–1981) gives an overall incidence of 5.7%, with rates ranging from 13.5% for infants with birth weights between 500 and 749 g to 2.9% for infants with birth weights between 1500 and 1749 g (2). Mortality rates are also variable, depending on birth weight, maturity, and the presence of coexisting medical problems. Overall mortality

rates range from 30 to 40% and have not changed significantly over the past 10 years. The unchanging mortality rate is probably a reflection of an increasing population of very-low-birth-weight infants—a subpopulation of infants with an increased case-fatality ratio (3)—who survive the perinatal period only to develop NEC later in their hospital course.

Necrotizing enterocolitis is predominantly a disease of premature infants, and the incidence is inversely proportional to birth weight and degree of maturity (4). Despite the strong association between NEC and prematurity, 10% of affected patients are full-term infants and, on occasion, NEC has been reported in infants outside of the neonatal period, usually after a protracted course of diarrhea (5). When studied in a systematic and prospective fashion, the only consistent risk factors appear to be birth weight and prematurity (6). The association between NEC and prematurity suggests that the structural integrity of the immature gastrointestinal tract may play an important role in the pathogenesis of the disease. This hypothesis is supported by the observation of Bauer et al (7)

---

From the Department of Pediatrics, Harbor-UCLA Medical Center.

Address for reprint requests: Dr. Paul E. Hyman, Harbor-UCLA Medical Center, 1000 West Carson Street, Torrance, California 90509.

(in the Collaborative Study on Antenatal Steroid Therapy) of a decreased incidence of NEC in premature infants receiving antenatal maternal steroids. Costicosteroids are known to accelerate the maturation of fetal tissues and stabilize epithelial and endothelial barriers (8), and they may augment the structural integrity of the gut.

A consistent risk factor among full-term infants with NEC is polycythemia (9); this implicates hyperviscosity and altered mucosal blood flow in the pathogenesis of the disease. The role of infectious agents in the etiology of NEC is supported by the epidemiological observation of periodic epidemics, with the emergence of a predominant microorganism in a particular neonatal intensive care unit. The demographics of infants affected during epidemics appear to differ from endemic cases (10), with larger infants and delayed onset of disease being more common in epidemic settings. A significant percentage (10–15%) of infants developing NEC have no identifiable risk factors (11).

It is likely that multiple factors are capable of initiating the pathologic sequence of events that results in NEC, and a combination of factors may be responsible in a given case of NEC.

### CLINICAL FACTORS

The clinical manifestations of NEC are protean, and can range from mild gastrointestinal disturbance with abdominal distensions to frank peritonitis and intestinal perforation. Symptomatology is usually divided into two categories: (1) Gastrointestinal symptoms are felt to be directly attributable to the primary disease process, including abdominal distension, retention of gastric contents, bilious emesis, and bloody stools. (2) Systemic nonspecific symptoms, such as apnea, acidosis, temperature instability, and lethargy, are present in a variety of disease states in the neonate.

Necrotizing enterocolitis is suspected when a cluster of predominantly gastrointestinal symptoms appear in an hospitalized infant. In 1978, Bell et al proposed a method of clinical staging for infants with necrotizing enterocolitis, based on severity of presenting symptomatology and radiographic signs (12). Clinical staging has allows comparison of the outcome of infants with disease of similar and different severities and has been useful in standardizing therapeutic approaches.

### RADIOGRAPHIC FACTORS

Although NEC can be suspected on clinical grounds, confirmation usually requires the demonstration of characteristic findings on abdominal roentgenograms. Definitive radiographic features include pneumatosis intestinalis (intramural air), which is present in 85–90% of cases (13), or intrahepatic venous gas (14). Additional nonspecific radiographic findings include small bowel dilatation, ileus, and ascites. As the disease progresses, gangrenous bowel is often manifested by a persistently dilated loop on serial abdominal radiographs (15), and intestinal perforation is heralded by the appearance of pneumoperitoneum.

### PATHOLOGIC FACTORS

In the absence of characteristic radiographic findings, confirmation of diagnosis is achieved only at surgery or by the histologic examination of tissue specimens obtained at the time of surgical resection or autopsy. The most commonly affected regions are the terminal ileum and ascending colon. However, any part of the gastrointestinal tract may be involved. On gross inspection, the affected bowel segments appear distended, hemorrhagic, and poorly perfused. Involvement can be focal or diffuse. The histologic appearance of the lesions is dependent on the stage and severity of disease at the time of examination. Early lesions are characterized by superficial mucosal ulcerations and hemorrhage, with microthrombi in submucosal vessels (16). An inflammatory cell response is not a prominent feature of early lesions. With more advanced disease, mucosal ulcerations deepen and become covered with pseudomembranes consisting of fibrin, necrotic epithelium, and inflammatory cells. Scattered areas of transmural necrosis can be appreciated and pneumatosis is commonly noted in the submucosal area. Thrombus formation may be found in the mesenteric arterioles which supply blood to the bowel.

### THEORIES OF PATHOGENESIS

Despite an abundance of epidemiological studies and the identification of potential risk factors, a complete understanding of the pathogenesis of NEC is lacking. The theory of primary mucosal damage followed by secondary bacterial invasion is generally regarded as an oversimplification of a complex sequence of events that results in the

clinical and pathological manifestations of NEC. Mucosal injury appears to be a prerequisite for the development of NEC, but the mechanisms by which the injury can be sustained are numerous and poorly understood. Intraluminal factors, such as formula feedings, structural immaturity of the bowel wall, and direct colonization and invasion by enteropathogenic bacteria, as well as extraluminal (vascular) factors, such as ischemia, thrombosis, and hyperviscosity have been implicated in the genesis of mucosal injury. No single factor or proposed mechanism provides an adequate explanation for the occurrence of NEC in all neonates. It is likely that NEC represents a final common response of the neonatal gastrointestinal system to a variety of pathologic events.

**Ischemia.** Intestinal ischemia, secondary to reduced mesenteric blood flow, has long been implicated as a primary cause of mucosal injury in stressed neonates, and much attention has been focused on the role of ischemia in the pathogenesis of NEC. In 1972, Touloukian et al developed an animal model for ischemic gastroenteritis in asphyxiated neonatal piglets (17). During periods of asphyxia, redistribution of cardiac output occurred, with diminished perfusion to the intestinal mucosa, particularly in the distal ileum and proximal colon. Although a rebound in perfusion occurred with resuscitation, blood flow remained diminished in the ileocecal area—the area most frequently affected in NEC. Histologic findings in the affected intestine included mucosal edema and hemorrhage, consistent with histologic changes in the early stages of human NEC.

The redistribution of cardiac output during asphyxia was likened to the “diving reflex” present in aquatic mammals—a compensatory mechanism to preserve blood flow to vital organs during periods of systemic hypoxia. It has been hypothesized, but remains unproven, that such a reflex is operative in asphyxiated human neonates. Lloyd (18) has suggested that the selective redistribution of cardiac output and diminished intestinal mucosal perfusion plays a major role in the pathogenesis of gastrointestinal perforations in neonates. The hypoxia-ischemia model for NEC is strengthened by the frequent clinical observation of asphyxial episodes during the perinatal period in the majority of infants developing NEC (19).

However, the clinical corroboration is largely retrospective, and carefully designed prospective studies (20) failed to document antecedent asphyxia

as a consistent risk factor for the development of NEC. Asphyxia and the proposed circulatory responses can result from a variety of low-output states in sick neonates, including sepsis, patent ductus arteriosus (PDA), respiratory distress syndrome, shock, and prolonged apnea. Although these conditions may predispose neonates to asphyxial episodes, prospective clinical studies failed to demonstrate a higher incidence in neonates developing NEC when compared to gestationally matched control infants (21).

Reduction of mesenteric blood flow and subsequent intestinal ischemia may result from thromboembolism. Thromboembolic phenomena have been associated with indwelling umbilical arterial catheters (22) and have been proposed as a cause of NEC. Although microemboli are found commonly in mucosal blood vessels supplying affected bowel, pathologic examinations have failed to demonstrate thrombus formation in major mesenteric arterioles. In one study, umbilical artery catheterization was associated with an increased risk for the development of NEC (23), secondary to direct interference of mesenteric blood flow by the catheter. However, a recent prospective study comparing the incidence of NEC in neonates with umbilical arterial catheters above and below the level of the mesenteric arteries revealed no difference (24), thus challenging previous conceptions.

Neonatal polycythemia and the associated hyperviscosity are well-documented risk factors for the development of NEC (25), particularly in infants with birth weights greater than 2 kg (9). Non-occlusive ischemic changes have been demonstrated in the intestinal mucosa of newborn dogs (26) with hyperviscous blood, thus suggesting intravascular stasis and poor microcirculation in the mesenteric vascular bed as the inciting ischemic event in polycythemic infants.

**Infection.** In addition to circulatory factors, infectious agents are implicated in the pathogenesis of NEC (27). Support for this hypothesis is found in the occurrence of periodic epidemics of NEC and the emergence of a predominant microorganism during epidemic periods. In addition, epidemics have been abated by the institution of standard infectious disease control measures (28), such as patient isolation and strict hand washing. A wide variety of bacterial and viral pathogens have been associated with epidemics and include *E. coli* (29), *Klebsiella* (30), enterobacter (31) and coronavirus (32). However, in the majority of

epidemics, no single enteric pathogen has been isolated consistently (33).

The bacteria involved, including *E. coli* and *Clostridia*, are normal inhabitants of the neonatal gastrointestinal tract. The circumstances under which normal bowel flora become enteropathic are incompletely understood. It has been suggested by Lawrence et al (34) that selective bacterial overgrowth and altered bowel colonization may occur in hospitalized neonates receiving broad-spectrum antibiotics. This common scenario may promote a favorable environment for the overgrowth of opportunistic microorganisms associated with NEC. Additional factors that may augment bacterial pathogenicity include structural immaturity of the bowel wall, absence of local protective immunologic factors, and the presence of incompletely absorbed products of digestion after formula feedings.

*Clostridia* species, agents frequently implicated in the pathogenesis of NEC (35) and other gastrointestinal infections, are obligate anaerobes with a propensity to infect ischemic tissue. Clostridial virulence is enhanced by a decreased oxidation-reduction potential of poorly perfused bowel. In animal studies by Yale and Balish (36), differential virulence was demonstrated when germ-free animals were inoculated with single bacterial strains. In the presence of experimentally induced ischemic bowel, *Clostridium perfringens* proved lethal in 99% of animals, *E. coli* was lethal in 77%, and other bacteria demonstrated intermediate virulence. In addition, the presence of clostridia or other anaerobes appears to be necessary for the development of pneumatosis intestinalis in germ-free animals with experimental intestinal ischemia (37). Based on experimental and epidemiological observations, it appears likely that infectious agents play an important, although incompletely defined, role in the pathogenesis of NEC.

**Feeding.** The importance of enteral feedings in the pathogenesis of NEC has been suggested by the clinical observation that 90% of infants with NEC have been fed formula or breast milk prior to the appearance of symptoms. The composition of enteral feedings affects the acquisition and composition of intestinal flora, and in animal studies (38) enteral feedings and bacteria acted in a synergistic fashion in the pathogenesis of NEC. Factors such as formula composition (human milk vs cow-milk formula) (39), formula osmolality (40), rate and method of feeding (41), and time of initiation of

enteral feeds (42) have been examined to determine their relative influence on the occurrence of NEC.

A protective influence of breast milk was demonstrated in an animal model of ischemia-induced NEC (38) and was attributed to the presence of nonspecific immunoprotective factors in breast milk. However, evidence for a protective value of human breast milk is lacking, and NEC occurred in preterm infants fed exclusively breast milk (39).

Hypertonic enteral feedings were associated with intestinal mucosal injury in preterm animals (43). Moreover, hyperosmolar feedings and medications were associated with an increased incidence of NEC in low-birth-weight human infants (44).

Retrospective studies suggested that early, large volume feedings contribute to the development of NEC and that conservative feeding regimens may help to decrease the incidence of NEC (45). The mechanism whereby excessive feeding may initiate events leading to NEC remains speculative. Excessive intake has been associated with intestinal distension and altered peristalsis (46), which may result bacterial overgrowth favoring the development of NEC. Feeding results in increased blood flow and tissue O<sub>2</sub> extraction in healthy neonatal piglets (47). It is possible that in sick infants unable to increase blood flow to the gut because of no cardiac reserve, feeding results in a relative ischemia in which increased tissue demands for oxygen are not met. In addition, the absorptive capacity of the preterm intestine may be surpassed in the presence of excessive substrate, allowing for the passage of undigested nutrients to colonic bacteria for fermentation. Fermentation of undigested carbohydrates by colonic bacteria results in the production of hydrogen gas, a major component of pneumatosis intestinalis (48), a diagnostic hallmark of NEC. Despite these findings, prospective studies (49) have failed to document a causative effect of enteral feedings. It has been common practice in the majority of neonatal intensive care units to delay initiation of enteral feedings in preterm asphyxiated infants. The rationale for delayed feeding is to allow sufficient time for healing of intestinal mucosa subjected to hypoxic-ischemic stress. However, a recent prospective study by LaGamma et al (50) failed to demonstrate a protective effect of delayed feedings. Instead, there was an increased incidence of NEC in infants in whom enteral feeding was withheld for two weeks. There is evidence that enteral feedings may participate in the stimulation of postnatal gastrointestinal maturation through the re-

lease of trophic hormones (51) and that prolonged periods without enteral feeding may cause mucosal atrophy. Therefore, delayed feedings may place the preterm infant at increased risk for NEC.

### ROLE OF EICOSANOIDS IN NEC

**Human Studies.** In a recent study of human neonates, urinary immunoreactive thromboxane B<sub>2</sub> concentrations (TxB<sub>2</sub>) were measured in preterm infants with and without NEC (52). Mean TxB<sub>2</sub> was established for healthy term and preterm infants, stressed neonates without NEC, and infants with NEC. TxB<sub>2</sub> was significantly elevated in neonates with NEC when compared to all other groups studied. Stressed neonates without NEC had TxB<sub>2</sub> intermediate between healthy neonates and infants with NEC. Serial urine samples were obtained for measurement of TxB<sub>2</sub> from a group of preterm infants considered at high risk for the development of NEC. In the four infants who subsequently developed NEC, TxB<sub>2</sub> became elevated after the onset of gastrointestinal symptoms, and values paralleled the course of illness, recovery, and recurrence. Although TxB<sub>2</sub> did not allow for earlier identification of infants who develop NEC, the results suggested that elevated TxB<sub>2</sub> correlated with the severity of gastrointestinal inflammation in neonates. Beta-thromboglobulin, another product of platelet activation, was increased in the urine of infants with NEC. In addition, there was an inverse correlation between TxB<sub>2</sub> and platelet counts. These findings were consistent with the concept that platelet consumption was the source of enhanced thromboxane excretion. These preliminary results lend support to the possibility that platelet thrombosis and release of vasoconstrictor thromboxanes play an important role in the potentiation of the ischemic injury in neonates who subsequently develop NEC (Figure 1).

**Laboratory Studies.** The role of eicosanoids in the pathogenesis of experimental NEC has been examined in two animal models. Ischemic necrosis of the bowel was induced in adult rats by infusing synthetic platelet activating factor (PAF) with or without endotoxin directly into the abdominal aorta (53–55). The histology of the injury was similar to that in adults with ischemic bowel disease, but thromboemboli were not found. An inhibitor of leukotriene synthesis, a leukotriene receptor antagonist, and verapamil, a calcium-channel blocker, all inhibited the ischemic injury induced by PAF (54). The venous effluent

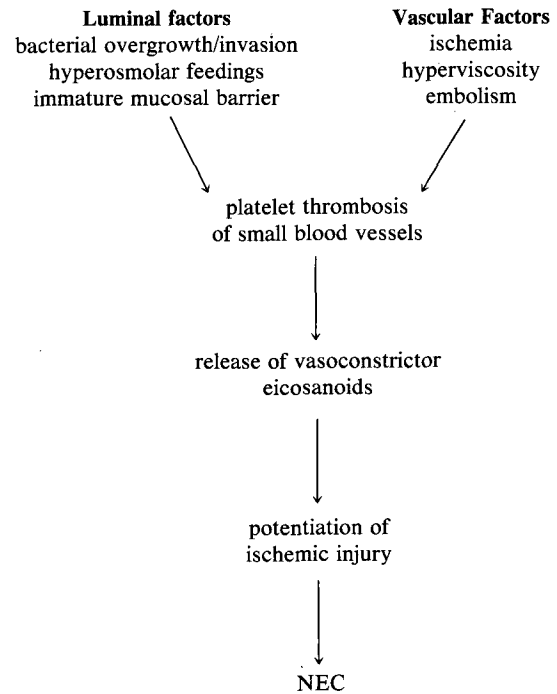


Fig 1. Possible role of eicosanoids in the pathogenesis of NEC.

collected from the experimental animals was tested in a bioassay cascade (55). Following PAF, leukotriene C<sub>4</sub> was released in large amounts. Direct infusion of leukotriene C<sub>4</sub> into rat aorta resulted in bowel necrosis, suggesting an important role for the vasoconstrictor leukotriene C<sub>4</sub> in bowel ischemia following treatment with PAF.

Prostaglandins, predominantly PGE<sub>1</sub>, were also detected in the venous effluent of PAF-stimulated perfused intestines. PGE<sub>1</sub> is a vasodilator whose potential role in the pathogenesis of ischemic bowel necrosis remains undefined. Continuous systemic infusion of PGE<sub>1</sub> resulted in improved intestinal perfusion and prevented bowel necrosis in PAF-treated rat intestines. Pretreatment of the same animals with indomethacin, a cyclooxygenase inhibitor, resulted in increased vascular resistance in mesenteric vessels and acceleration of the development of ischemic changes. It is likely that pretreatment with indomethacin resulted in a decreased production of vasodilating PGE<sub>1</sub> and in an increase in the relative concentration of leukotrienes via preferential metabolism of arachidonic acid through the lipooxygenase pathway.

Thromboxane A<sub>2</sub>, another metabolite of arachidonic acid with potent vasoconstricting actions, was not detected in venous effluents of PAF-treated

intestines, and the administration of thromboxane inhibitors did not prevent the development of ischemic bowel necrosis. It was therefore concluded that thromboxanes were not involved in the pathogenesis of ischemic bowel necrosis in this experimental model (54, 55). It appears that the pathogenesis of bowel necrosis in this vascular model is mediated by the relative concentrations and interactions of locally produced prostaglandins and leukotrienes.

In the luminal-based experimental model for NEC developed by Clark et al (56), the role of eicosanoid release and leukocyte infiltration in the pathogenesis of bowel inflammation was explored. Their model involved the establishment of mucosal necrosis in the intestines of weanling rabbits by the intraluminal injection of calcium gluconate and casein. Their findings included extensive mucosal damage and diminished blood flow to the treated loops (57). Leukocyte accumulation was limited to non-damaged areas immediately adjacent to necrotic bowel, and leukotriene release was greatest in the area of leukocyte infiltration (58). These data support the hypothesis that leukotrienes are released by invading leukocytes and suggest that leukotrienes may be involved in the extension of established mucosal damage.

These few preliminary studies in neonates and animals suggest that arachadonic acid metabolites may be involved in the pathogenesis of NEC. A great deal of further investigation will be required before the roles of the eicosanoids in NEC can be clarified. The long-term goals of such research will be to discover specific interventions that might prove useful for the prevention or treatment of NEC in human infants.

REFERENCES

1. Ryder RW, Shelton JD, Guinan ME: Necrotizing enterocolitis: A prospective multicenter investigation. *Am J Epidemiol* 112:113-123, 1980
2. Kanto WP, Wilson R, Breart GL, Zierlers S, Purohit OM, Peckham GJ, Ellison RC: Perinatal events and necrotizing enterocolitis in premature infants. *Am J Dis Child* 141:167-169, 1987
3. Stoll BJ, Kano WP, Glass RI, Nahmias AJ, Brannon AW: Epidemiology of necrotizing enterocolitis: A case-control study. *J Pediatr* 96:447-451, 1980
4. Kleigman RM, Fanaroff AA: Neonatal necrotizing enterocolitis: A nine-year experience. *Am J Dis Child* 135:603-607, 1981
5. Polin RA, Pollack PF, Barlow B, Wigger JH, Slovis TL, Santulli TU, Heiro WC: Necrotizing enterocolitis in term infants. *J Pediatr* 89:460-462, 1976
6. Kleigman RM, Hack M, Jones P, Fanaroff AA: Epidemiological study of necrotizing enterocolitis among low-birth-weight infants. *J Pediatr* 100:440-444, 1982
7. Bauer CR, Morrison JC, Poole WR, Korones SB, Boehm JJ, Rigatto H, Zachman RD: A decreased incidence of necrotizing enterocolitis after prenatal glucocorticoid therapy. *Pediatrics* 73:682-687, 1984
8. Collaborative Group on Antenatal Steroid Therapy: Effect of antenatal dexamethasone administration on the prevention of respiratory distress syndrome. *Am J Obstet Gynecol* 141:276-287, 1984
9. Wilson R, delPortillo M, Schmidt E, Feldman RA, Kanto WP Jr: Risk factors for necrotizing enterocolitis in infants weighing more than 2000 grams at birth: A case-control study. *Pediatrics* 71:19-21, 1983
10. Moomjian A, Peckham G, Fox W, Pereira GR, Schaberg DA: Necrotizing enterocolitis endemic vs epidemic form. *Pediatr Res* 12:5530, 1978
11. Gregory JR, Campbell JR, Harrison MW, Campbell TJ: Neonatal necrotizing enterocolitis: A 10-year experience. *Am J Surg* 141:562-567, 1987
12. Bell MJ, Ternberg JL, Feigin RD, Keating JP, Marshall R, Barton L, Brotherton T: Neonatal necrotizing enterocolitis: Therapeutic decisions based upon clinical staging. *Ann Surg* 187:1-6, 1978
13. Benirschke K: NEC in the newborn infant: Report of 68th Ross Conference on Pediatric Research. Columbus, Ohio; Ross Laboratories, 1974, p 27
14. Arnon RG, Fishbein JF: Portal venous gas in the pediatric age group. *J Pediatr* 79:255-259, 1971
15. Leonard T, Johnson A, Pettet PG: Critical evaluation of the persistent loop sign in necrotizing enterocolitis. *Radiology* 142:385-386, 1982
16. Santelli TV, Schullinger JN, Haird WC, Gongaware RD, Wigger J, Barlow B, Blanc W, Berdon WE: Acute necrotizing enterocolitis in infancy: A review of 64 cases. *Pediatrics* 55:376-387, 1975
17. Touloukian RJ, Posch JN, Spencer R: The pathogenesis of ischemic gastroenteritis of the neonate: Selective gut mucosal ischemia in asphyxiated neonatal piglets. *J Pediatr Surg* 7:194-207, 1972
18. Lloyd JR: The etiology of gastrointestinal perforation in the newborn. *J Pediatr Surg* 4:77-84, 1969
19. Brady P, Garik T, German J: Fetal heart rate patterns in infants in whom necrotizing enterocolitis develops. *Arch Surg* 115:1050, 1980
20. Yu VY, Tudehope DI: Neonatal necrotizing enterocolitis II. Perinatal risk factors. *Med J Aust* 1:688, 1977
21. Virnig NZ, Reynolds JW: Epidemiological aspects of neonatal necrotizing enterocolitis. *Am J Dis Child* 128:186-190, 1974
22. Tyson JE, deSa DJ, Moore S: Thromboartheromatous complications of umbilical arterial catheterization in the newborn period. *Arch Dis Child* 51:744-754, 1976
23. Bunton GL, Durbin GM, McIntosh N, Shaw, DG, Taghizadeh, A, Reynolds EOR, Rivers RPA, Urman G: Necrotizing enterocolitis: Controlled study of 3 years' experience in a neonatal intensive care unit. *Arch Dis Child* 52:772-777, 1977
24. Kliegman R, Stork E, Fanaroff A: Lack of relationship between umbilical arterial catheter complications and necrotizing enterocolitis. *Pediatr Res* 19:349A, 1985

25. Leake RD, Thanopoulos B, Nieberg R: Hyperviscosity syndrome associated with necrotizing enterocolitis. *Am J Dis Child* 129:1192-1194, 1975
26. Le Blanc MH, D'Cruz C, Pate K: Necrotizing enterocolitis can be caused by polycythemic hyperviscosity in the newborn dog. *J Pediatr* 105:804-808, 1984
27. Kliegman RM: Neonatal necrotizing enterocolitis: Implications for an infectious disease. *Pediatr Clin North Am* 26:327-344, 1979
28. Book LS, Overall JUC, Herbst JJ, Britt MR, Epstein B, Jung AL: Clustering of necrotizing enterocolitis: Interruption by infection-control measures. *N Engl J Med* 297:984-986, 1977
29. Cushion AH: Necrotizing enterocolitis of *Escherichia coli*: Heat-labile enterotoxin. *Pediatrics* 71:626-630, 1983
30. Hill HR, Hunt CE, Matsen JM: Nocosomial colonization with klebsiella type 26, in a neonatal intensive care unit associated with an outbreak of sepsis, meningitis and necrotizing enterocolitis. *J Pediatr* 85:415-449, 1974
31. Powell J, Bureau M, Pare C, Galiory ML, Cabana D, Patriquin H: Necrotizing enterocolitis: epidemic following an outbreak of enterobacter cloaca. *Am J Dis Child* 134:1152-1154, 1980
32. Chany C, Mostovici O, Lebon P, Rousset S: Association of coronavirus with neonatal necrotizing enterocolitis. *Pediatrics* 69:209-218, 1982
33. Anderson C, Collin M, OKeefe J: A widespread epidemic of mild necrotizing enterocolitis of unknown cause. *Am J Dis Child* 138:979, 1984
34. Lawrence G, Bates J, Gal A: Pathogenesis of necrotizing enterocolitis. *Lancet* 1:137-139, 1982
35. Cashore WJ, Peter G, Lauer mann M, Stonestreet BS, Oh W: Clostridial colonization and clostridial toxin in neonatal necrotizing enterocolitis. *J Pediatr* 98:308-311, 1981
36. Yale CE, Balish E: The importance of six common bacteria in intestinal strangulation. *Arch Surg* 107:438-442, 1972
37. Yale CE, Balish E, WU JP: The bacterial etiology of pneumatosis cystoides intestinalis. *Arch Surg* 109:89, 1974
38. Barlow B, Santulli TV, Heird WA, Pitt J, Blanc WA, Schullinger JN: An experimental study of acute neonatal enterocolitis—the importance of breast milk. *J Pediatr Surg* 9:587-594, 1974
39. Kliegman RM, Pittard WE, Fanakroff AA: Necrotizing enterocolitis in neonates fed human milk. *J Pediatr* 95:450-453, 1979
40. Book LS, Herbst JJ, Atherton SO, Jung AL: Necrotizing enterocolitis in low-birth-weight infants fed an elemental formula. *J Pediatr* 87:602-605, 1975
41. Goldman HI: Feeding and necrotizing enterocolitis. *AM J Dis Child* 134:553-555, 1980
42. Osterrag SG, LaGamma EF, Reisen CE, Ferrentino FL: Early enteral feeding does not affect the incidence of necrotizing enterocolitis. *Pediatrics* 77:275-280, 1987
43. deLemos RA, Rogers JH, McLaughlin GW: Experimental production of necrotizing enterocolitis in newborn goats. *Pediatr Res* 8:380, 1974(abstract)
44. Willis DM, Chabot J, Raddle IC, Chance GW: Unsuspected hyperosmolarity of oral solutions contributing to necrotizing enterocolitis in very-low-birth-weight infants. *Pediatrics* 60:535-538, 1977
45. Brown EG, Sweet AY: Preventing necrotizing enterocolitis in neonates. *JAMA* 240:2452-2454, 1978
46. Murrell TJC, Roth L: Necrotizing jejunitis: A newly discovered disease in the highlands of New Guinea. *Med J Aust* 1:68, 1963
47. Nowicki PT, Stonestreet BS, Hansen NB, Yao AC, Oh W: Gastrointestinal blood flow and oxygen consumption in awake newborn piglets: Effects of feeding. *Am J Physiol* 245:G697-G702, 1983
48. Engel R: Necrotizing enterocolitis in the newborn: Report of 68th Ross Conference on Pediatric Research, Columbus, Ohio. Ross Laboratories, 1974, pp 66-71
49. Book LS, Herbst JJ, Jung AL: Comparison of fast- and slow-feeding rate schedules to the development of necrotizing enterocolitis. *J Pediatr* 89:463-466, 1976
50. LaGamma EF, Ostertag SG, Birenbaum H: Delayed feeding fails to prevent necrotizing enterocolitis. *Am J Dis Child* 139:385-389, 1985
51. Anysley-Green A: Hormones and postnatal adaptation to enteral nutrition. *J Pediatr Gastroenterol Nutr* 2:418, 1983
52. Hyman PE, Abrams CE, Zipser RD: Enhanced urinary immunoreactive thromboxane in neonatal necrotizing enterocolitis: A diagnostic indicator of thrombotic activity. *Am J Dis Child* 141:686-689, 1987
53. Gonzalez-Guzzi F, Hsueh W: Experimental model of ischemic bowel necrosis. The role of platelet activating factor and endotoxin. *Am J Pathol* 112:127-135, 1983
54. Hsueh W, Gonzalez-Crussi F, Arroyave JL: Platelet-activating factor-induced ischemic bowel necrosis. *Am J Pathol* 122:231-239, 1986
55. Hsueh W, Gonzales-Crussi F, Arroyave JL: Release of leukotriene C<sub>4</sub> by isolated perfused rat small intestine in response to platelet-activating factor. *J Clin Invest* 78:108-114, 1986
56. Clark DA, Pelley RP, Schneider AJ: Interaction between bovine casein and *V. cholera* enterotoxin in the rabbit ileal loop. *Pediatr Res* 17:1008-1012, 1983
57. Clark DA, Thompson JE, Weiner LB, Micmillian JA, Schneider AJ, Rokahr JE: Necrotizing enterocolitis: Intraluminal biochemistry in human neonates and a rabbit model. *Pediatr Res* 19:919-921, 1985
58. Clark DA, Mullane K, Caravella S, McNeill H, Dweck HS, Miller MJS: Eicosanoid and leukocyte participation in experimental necrotizing enterocolitis. *Pediatr Res* 21:407, 1987 (abstract)