

RESEARCH LETTER

Open Access



# Familial cluster of COVID-19 infection from an asymptomatic

Jinjun Zhang<sup>1,2\*</sup>, Sijia Tian<sup>2</sup>, Jing Lou<sup>2</sup> and Yuguo Chen<sup>3,4\*</sup>

Since December 2019, the first case of a novel coronavirus (COVID-19) infection pneumonia was detected in Wuhan, and the outbreak has been spreading rapidly in the world. As of February 18, 2020, a total of 73,332 cases of confirmed COVID-19 infection have been detected in the world as reported by the WHO [1, 2]. Given that the asymptomatic persons are potential sources of COVID-19 infection [3], we report a familial cluster case of five patients infected with COVID-19 from an asymptomatic confirmed case in Beijing. We obtained the data of patients, which included demographic, epidemiological, and clinical features; chest radiography; laboratory test; and outcomes. Laboratory confirmation of COVID-19 was detected in the first hospital admission and verified by the Beijing Center for Disease Control and Prevention (CDC). An asymptomatic case was defined as a laboratory-confirmed COVID-19 infection case who was afebrile and well. We enrolled the family that had five patients in total with COVID-19 infection who were transferred by the Beijing Emergency Medical Service (EMS) from January 24 to 27, 2020, to the designated hospitals for special treatment. Clinical outcomes were followed up to February 29, 2020.

The familial cluster of five patients (index patient to patient 4) was infected with COVID-19, and just the index patient had been to Wuhan, who had no symptoms before his family members started to get sick one after another. On January 19, the index patient, a 48-year-old male, came back to Beijing from Wuhan. He invited his nephew (patient 3) for dinner. On January 22, patient 3, a 32-year-old man, became ill with continuous high fever and fatigue; the highest body temperature was 40.2 °C; he first visited a

hospital on January 24. Two nasopharyngeal swabs sample were obtained and were found to be positive for COVID-19 on the real-time reverse transcription-polymerase chain reaction (RT-PCR) assay. Before he went to the hospital, his uncle (index patient) was informed that his relative in Wuhan had been infected with COVID-19. On January 23, the index patient's wife, patient 1, a 45-year-old female, had a fever of 37.8 °C too. For the reason that his relative in Wuhan and nephew had been detected to be infected with COVID-19, his family visited a hospital together and tested the RT-PCR for COVID-19, the results of which were all positive (Fig. 1). The chest radiograph of patient 2 was normal, and it is noteworthy that she was an asymptomatic too. The index patient's and his wife's (patient 1) chest radiograph demonstrated ground glass opacities (Fig. 2). Then, the family were transferred by EMS to the designated hospitals for special treatment and isolated on January 27. On the same day, the nephew's mother (patient 4) got a fever of 38.4 with joint pain; after being confirmed with COVID-19 infection, she was transferred to the designated hospital too. On February 18, 2020, index patient to patient 2 were discharged, the index patient had no fever along with dry cough, and patient 2 had no clinical symptoms during hospitalization, while patients 3 and 4 were still in hospital.

Finally, the familial cluster infected with COVID-19 has been reported in homes or hospital, especially without obvious symptoms [4]. According to our recent study, 5% of COVID-19 infection were asymptomatic cases [5]. If the asymptomatic cases cannot be found or isolated appropriately for medical observation, they will spread the virus to other close contacts quickly. Therefore, to identify and control the asymptomatic cases, as well as early quarantine for their close contacts, especially in families are important measures to prevent transmission of the COVID-19 infection.

\* Correspondence: [zhang92560@163.com](mailto:zhang92560@163.com); [chen919085@126.com](mailto:chen919085@126.com)

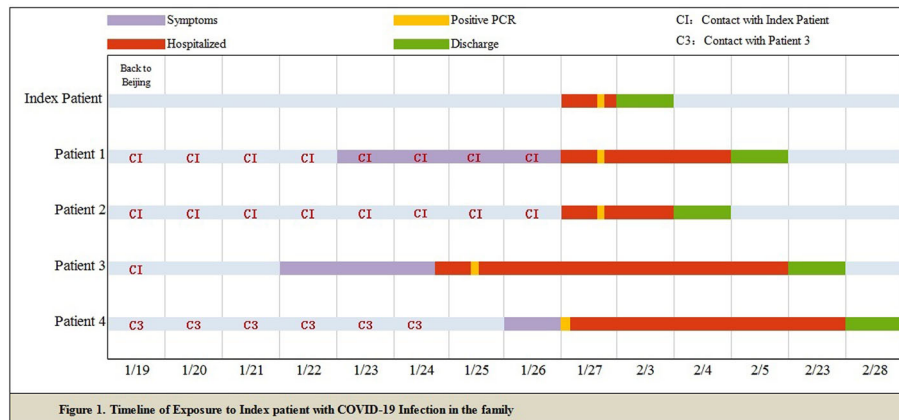
<sup>1</sup>School of Medicine, Shandong University, Jinan 250012, Shandong, China

<sup>3</sup>Emergency Department, Qilu Hospital, Shandong University, Jinan 250012, Shandong, China

Full list of author information is available at the end of the article

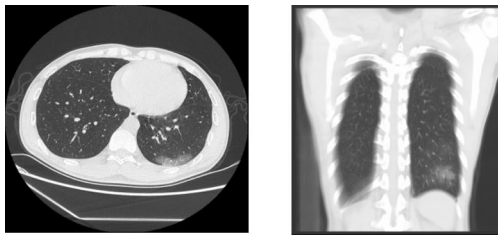


© The Author(s). 2020 **Open Access** This article is licensed under a Creative Commons Attribution 4.0 International License, which permits use, sharing, adaptation, distribution and reproduction in any medium or format, as long as you give appropriate credit to the original author(s) and the source, provide a link to the Creative Commons licence, and indicate if changes were made. The images or other third party material in this article are included in the article's Creative Commons licence, unless indicated otherwise in a credit line to the material. If material is not included in the article's Creative Commons licence and your intended use is not permitted by statutory regulation or exceeds the permitted use, you will need to obtain permission directly from the copyright holder. To view a copy of this licence, visit <http://creativecommons.org/licenses/by/4.0/>. The Creative Commons Public Domain Dedication waiver (<http://creativecommons.org/publicdomain/zero/1.0/>) applies to the data made available in this article, unless otherwise stated in a credit line to the data.

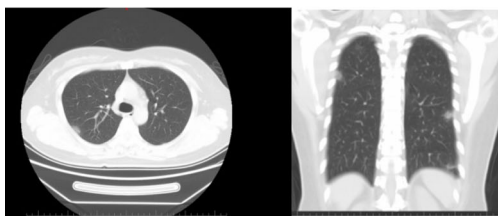


**Fig. 1** Timeline of exposure to index patient with COVID-19 infection in the familial cluster case

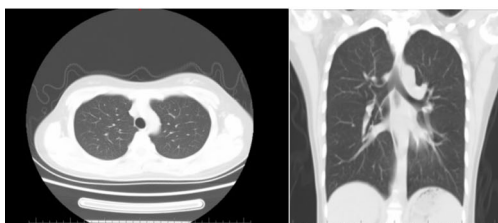
**Figure 2: Chest Imaging of Patients Infected With COVID-19**



A. Chest CT and radiograph of Index patient



B. Chest CT and radiograph of patient 1



C. Chest CT and radiograph of patient 2.

**Fig. 2** Chest imaging of patients infected with COVID-19

**Acknowledgements**

We thank all the Beijing EMS staff for their efforts in transferring the confirmed patients and all patients involved in the study.

**Authors' contributions**

All authors were the major contributors in writing the manuscript and approved the final manuscript.

**Funding**

This study was supported by a funding from the Beijing Municipal Science and Technology Project (Z191100004419003).

**Availability of data and materials**

Not applicable.

**Ethics approval and consent to participate**

The study was approved by the Ethics Committee of Beijing Emergency Medical Center (no.2020-01), and the written informed consent was waived because the study is retrospective in nature and belongs to the emergency medical service.

**Consent for publication**

Not applicable.

**Competing interests**

The authors declare that they have no competing interests.

**Author details**

<sup>1</sup>School of Medicine, Shandong University, Jinan 250012, Shandong, China. <sup>2</sup>Beijing Emergency Medical Center, Beijing 100031, China. <sup>3</sup>Emergency Department, Qilu Hospital, Shandong University, Jinan 250012, Shandong, China. <sup>4</sup>Shandong Provincial Clinical Research Center for Emergency and Critical Care Medicine, Jinan 250012, Shandong, China.

Received: 25 February 2020 Accepted: 6 March 2020

Published online: 27 March 2020

**References**

1. WHO. Coronavirus disease 2019 (COVID-19) Situation Report–29 [https://www.who.int/docs/default-source/coronaviruse/situation-reports/20200218-sitrep-29-covid-19.pdf?sfvrsn=6262de9e\\_2](https://www.who.int/docs/default-source/coronaviruse/situation-reports/20200218-sitrep-29-covid-19.pdf?sfvrsn=6262de9e_2). Accessed 20 Feb 2020.
2. Wang C, Horby PW, Hayden FG, Gao GF. A novel coronavirus outbreak of global health concern. *Lancet*. 2020;395(10223):470–3. [https://doi.org/10.1016/S0140-6736\(20\)30185-9](https://doi.org/10.1016/S0140-6736(20)30185-9).
3. Rothe C, Schunk M, Sothmann P, et al. Transmission of 2019-nCoV infection from an asymptomatic contact in Germany. *N Engl J Med*. doi:<https://doi.org/10.1056/NEJMc2001468>. [published online Jan 30, 2020].
4. Chan JF, Yuan S, Kok KH, et al. A familial cluster of pneumonia associated with the 2019 novel coronavirus indicating person-to-person transmission: a

study of a family cluster. *Lancet*. 2020;395(10223):514–23. [https://doi.org/10.1016/S0140-6736\(20\)30154-9](https://doi.org/10.1016/S0140-6736(20)30154-9).

5. Tian SJ, Hu N, Lou J, et al. Characteristics of COVID-19 infection in Beijing. *J Infect*. 2020. <https://doi.org/10.1016/j.jinf.2020.02.018>. [Epub ahead of print].

### **Publisher's Note**

Springer Nature remains neutral with regard to jurisdictional claims in published maps and institutional affiliations.

**Ready to submit your research? Choose BMC and benefit from:**

- fast, convenient online submission
- thorough peer review by experienced researchers in your field
- rapid publication on acceptance
- support for research data, including large and complex data types
- gold Open Access which fosters wider collaboration and increased citations
- maximum visibility for your research: over 100M website views per year

**At BMC, research is always in progress.**

Learn more [biomedcentral.com/submissions](https://biomedcentral.com/submissions)

