

CASE REPORT

Konnie M. Hebeda · Marius A. MacKenzie
J.Han.J.M. van Krieken

A case of anaplastic lymphoma kinase-positive anaplastic large cell lymphoma presenting with spontaneous splenic rupture: an extremely unusual presentation

Received: 24 February 2000 / Accepted: 27 April 2000

Abstract In a 22-year-old male with a 10-day history of fever, painful swelling in the left groin, and abdominal complaints, emergency surgery was performed because of spontaneous splenic rupture. At histology, a cellular infiltrate of intermediate-sized atypical lymphocytes was seen in the splenic white pulp, staining for T-cell markers. In addition, CD30 and anaplastic lymphoma kinase 1 (ALK) were diffusely positive, thus, representing a case of anaplastic large cell lymphoma (ALCL), T-cell, ALK-positive, small cell monomorphic variant. ALK-positive ALCL patients generally bear a much better prognosis than patients with T-cell lymphomas, unspecified, or ALK-negative ALCL. Therefore, besides the very unusual clinical presentation, this case highlights the importance of immunostaining for CD30 and ALK in all T-cell lymphomas. This report is the first extensive description of ALK-positive ALCL involvement of the spleen.

Keywords Non-Hodgkin's lymphoma · Immunohistochemistry · ALK1 · T-cell lymphoma · Splenic rupture

Introduction

Spontaneous rupture of the spleen is an uncommon complication of hematological malignancies and rarely the first symptom of disease [9]. In anaplastic large cell lymphoma (ALCL), splenic involvement is very unusual and only rare reports of the anaplastic lymphoma kinase (ALK)-positive variant involving the spleen are available

to date [11]. Therefore, splenic rupture as one of the presenting symptoms in ALK-positive ALCL (small cell variant) is exceptional.

Recently, a subgroup of ALCL was defined using ALK1 staining. The ALK1 monoclonal antibody recognizes an epitope of a fusion protein that is highly expressed in cases with chromosomal translocation t(2;5) [3]. Using this antibody resulted in a better definition of the entity and the recognition of morphological variants. Besides the immunohistomorphological specificity of ALK-positive ALCL, the characteristics of the patient population and the generally more favorable clinical outcome than with overall ALCL warrant this variant to be recognized as a separate entity: ALK lymphoma [11, 17].

Clinical history

A 22-year-old male with no relevant previous medical history was admitted to the hospital because of fever, fatigue, nausea, intermittent vomiting, and abdominal pain that had been present for 2 days. Since 10 days noticed a tender, enlarging mass in the left groin. There were no night sweats or weight loss. Upon physical examination, the blood pressure was 105/60 mmHg, the pulse rate 120/min, and the core temperature 39.1°C. Other than a tender splenomegaly and several painful, enlarged lymph nodes in the left groin, no further abnormalities were found. Laboratory evaluation showed erythrocyte sedimentation rate 102 mm/h, C-reactive protein level 450 mg/l, creatinine level 118 µmol/l, a normal lactate dehydrogenase level, hemoglobin level 8.4 mmol/l, platelet count 166×10⁹/l, and total white blood cells 32.4×10⁹/l with a differential count of 78% granulocytes, 2% lymphocytes, and 13% bands without other precursor cells in the blood. Blood cultures and additional microbiological tests remained negative. Ultrasound investigation of the abdomen showed a homogeneous splenomegaly of 18.5 cm, slight hepatomegaly, and multiple enlarged lymph nodes in the pancreatic, celiac, retroperitoneal, and iliac region.

K.M. Hebeda · J.H.J.M. van Krieken (✉)
Department of Pathology, UMC St. Radboud, PO Box 9101,
6500 HB Nijmegen, The Netherlands
Tel.: +31-24-3614314
Fax: +31-24-3540520

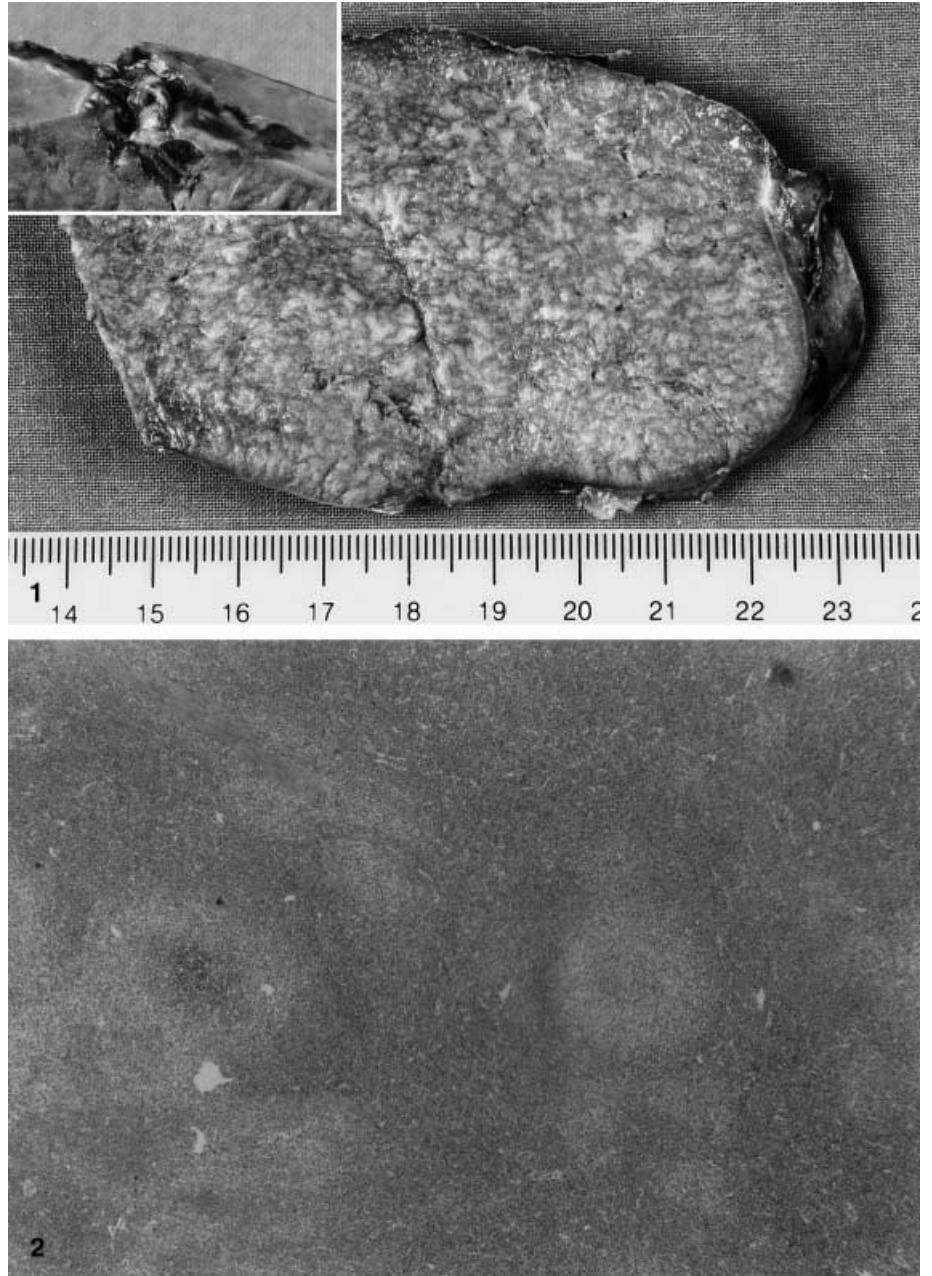
M.A. MacKenzie
Department of Hematology, UMC St. Radboud, PO Box 9101,
6500 HB Nijmegen, The Netherlands

The patient was admitted for further analysis and a presumed bacterial infection was treated with broad-spectrum antibiotics. Progressive abdominal pain and hemodynamic instability occurred the next day. Sonography showed free fluid in the abdomen. During emergency surgery, a spontaneous rupture of the enlarged spleen was found, and splenectomy was performed. Thereafter, the patient was admitted to the intensive care unit with severe sepsis leading to systemic inflammatory response syndrome and serious acute respiratory distress syndrome (ARDS), which persistently necessitated very high positive end-expiratory pressure (PEEP) upon mechanical ventilation. After histological diagnosis, the patient was treated with high doses of corticosteroids. Within some days, high fever and progressive respiratory failure during mechanical ventilation

occurred with diffuse reticulo-nodular abnormalities seen on the chest X-ray. Histology of an open lung biopsy revealed ARDS and infiltration by lymphoma cells. Because of progressive pulmonary deterioration and subsequent leukemic transformation of the lymphoma, the patient was treated with chemotherapy (cyclophosphamide and vincristine). Additional treatment with metronidazol was given because of gastrointestinal blood loss and identification of *clostridium difficile* toxin in the stool. Progressive gastrointestinal bleeding required an emergency hemicolectomy of the ascending colon with suturing of a perforation in the descending colon. Cultures of blood and bowel wall histology revealed an invasive aspergillosis, leading to progressive multi-organ failure and death 23 days after splenectomy. No autopsy was performed.

Fig. 1 Spleen with white tumor nodules and capsular ruptures (inset)

Fig. 2 Spleen with extensive tumor localization in white pulp (pale staining areas)



Materials and methods

Histology and immunohistochemical staining

The formalin-fixed paraffin-embedded sections of spleen and inguinal lymph node were stained with hematoxylin and eosin, periodic acid-Schiff, Giemsa and silver impregnation using La-guesse.

Both fresh-frozen and formalin-fixated tissues were used for immunoperoxidase studies according to standard procedures. A panel of monoclonal antibodies against CD45, CD20, CD79a, CD4, CD8, CD21, CD30, EMA, ALK1, Bcl-2, Epstein Barr virus (EBV; Dako, Denmark), CD2, CD5, CD22 (Novo Castra, UK), CD3, CD15 (Becton Dickinson, Calif.), CD7 (WT-1, investigators laboratory), perforin (NeoMarkers, Calif.), granzyme B (Monosan, The Netherlands), CD57 (Immunotech, France), and cyclin D1 (Progen, Germany) were used.

Receptor rearrangement

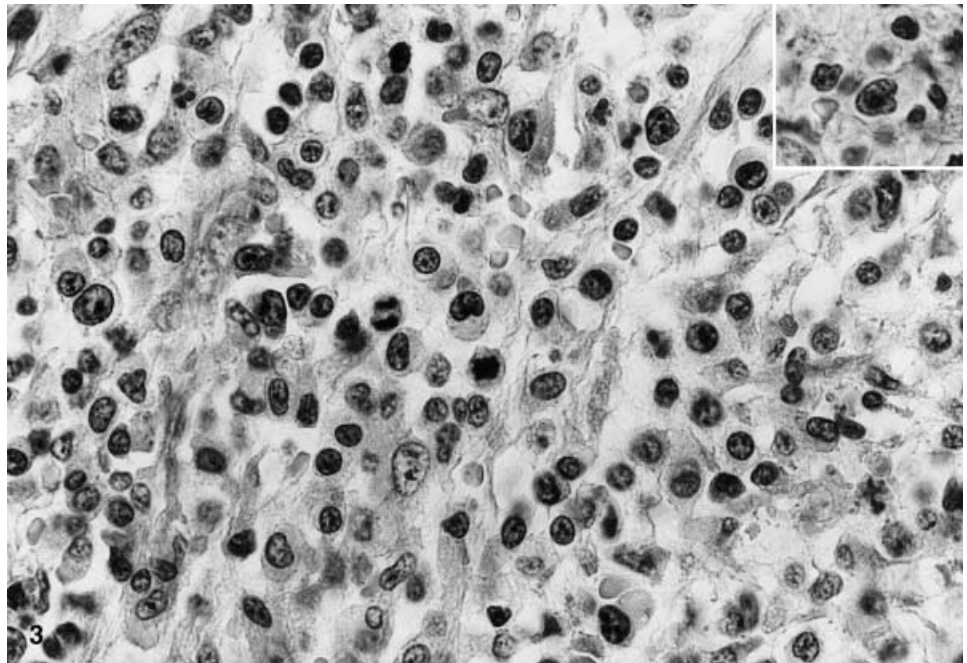
To detect rearrangement of the T-cell receptor (TCR) gene, Southern blot analysis as previously described [20] was performed on frozen tissue of spleen and lymph node using the probes J beta 2.7, C beta1, and TCR gamma.

Pathologic findings

Gross description

The fresh surgical specimen of the spleen had a maximum dimension of 19 cm and a weight of 894 g. The capsule showed small ruptures at multiple sites and was covered by blood clots. Upon sectioning, it was noted that the spleen was speckled with small white nodes, measuring up to 3 mm (Fig. 1). The lymph node was enlarged (diameter 3 cm) with a diffuse yellowish color on the cut surface.

Fig. 3 Spleen with diffuse infiltration of mainly intermediate-sized atypical lymphocytes with irregular nuclear contour. A rare "hallmark" cell in the lymph node (*inset*)



Light microscopy

The tumor cell density and distribution differed largely between spleen and lymph node. Low-power evaluation of the spleen showed a grossly intact architecture. Large light-staining areas of low cellularity surrounded and replaced T-cell areas (Fig. 2). No B-cell follicles remained.

The tumor cells were mainly intermediate size, non-anaplastic lymphoid cells with irregular nuclei and a moderate to large amount of cytoplasm (Fig. 3). Mitotic figures and nuclear debris were frequently seen. The red pulp was diffusely hypercellular with many tumor cells and eosinophils. However, the tumor cells were only recognized in retrospect with knowledge of the immunostaining.

The lymph node was enlarged by a rather diffuse infiltration of atypical lymphocytes. These cells also infiltrated the capsule and surrounding fat tissue. Clusters of larger tumor cells were mainly seen in a perivascular distribution pattern and in sinuses. Smaller atypical cells showed a more diffuse distribution and were sometimes hard to distinguish from reactive lymphocytes without the help of immunostaining. Typical "hallmark" cells as described by several authors [3, 8, 11], i.e., large cells with an eccentric kidney-shaped nucleus and an eosinophilic paranuclear region, were found only with difficulties (Fig. 3 inset). Subcortical remnants of small follicles could only scarcely be seen. Proliferation of high endothelial venules was a remarkable feature. The lymph node showed a fine, diffuse fibrosis.

Immunohistochemistry

Of the tested antibodies, those against the B-cell markers (CD20, CD79, CD21, and CD22) were negative in tu-

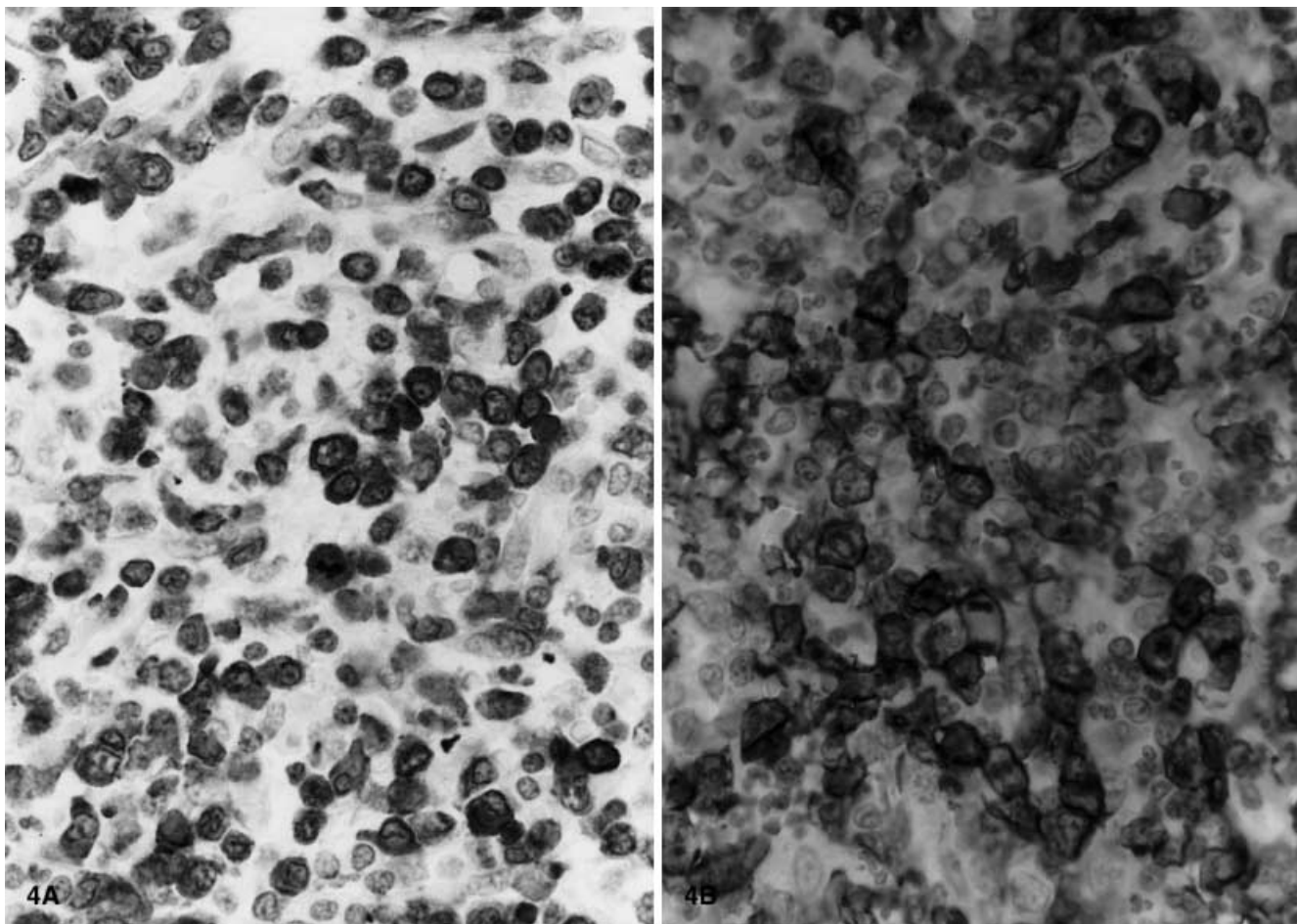


Fig. 4. Anaplastic lymphoma kinase (ALK)-protein (A) and CD30 expression (B) in the spleen

mor-involved spleen and lymph node. While tumor cells did not express CD3, CD5, or CD8, variable proportions did express CD7, CD2, and CD4. CD45 was strongly positive in smaller and somewhat less in larger tumor cells. Natural killer (NK)/T-cell markers (perforin, granzyme B, CD57) were all negative. CD15, Bcl-2, cyclin D1, and EBV were also negative.

Nuclear and cytoplasmic ALK1 expression was seen in all tumor cells in the lymph node and spleen (Fig. 4 A). CD30 showed a strong membranous staining with a paranuclear dot. In the lymph node, large, mainly perivascularly located tumor cells stained strongly, while weaker, occasional staining was seen in the smaller cell population. In the spleen, no such difference in staining of CD30 was observed (Fig. 4B). Early membrane antigen (EMA) was expressed by most of the tumor cells in both locations.

Receptor rearrangement

Southern blot analysis revealed no rearrangement for TCR beta or TCR gamma genes.

Discussion

Giagounidis et al. collected 28 cases of splenic rupture in non-Hodgkin's lymphoma (NHL) from the literature between 1861 and 1996 [9]. Thereafter, less than ten new cases were reported. To our knowledge, this case is the first description of a spontaneous splenic rupture in an ALK-positive ALCL patient. The history and the sepsis syndrome at presentation were most likely compatible with a concomitant infection at the time of the splenic rupture, contributing to the serious complications after splenectomy. Subsequently, the progressive clinical deterioration and leukemic transformation primarily reflect the aggressive course of the lymphoma in this particular patient.

ALK-positive ALCL is an only recently recognized subgroup of CD30-positive ALCL of T- and null-cell phenotype. A strong argument for distinction of this type of lymphoma is the occurrence of the t(2;5)(p23;q35) translocation which is almost exclusively found in this age and morphologically specific group of T- and null-cell ALCL. In addition, it is only rarely found in other lymphomas [4, 6, 16, 21]. Because of growing evidence of the better prognosis of this subgroup than ALK-negative ALCL patients and because of the younger patient group, several authors tend to regard ALK-positive ALCL or "ALKoma" as a clinical entity [4, 6, 7, 16, 17].

The morphology of many of these tumors is neither anaplastic nor large cell [3, 4, 6, 7, 13]. Indeed, several subgroups of ALK-positive lymphomas can be recognized other than the common-type ALCL: a monomorphic variant, a small cell variant, a lymphohistiocytic variant, a mixed cell variant, a sarcomatoid variant, a Hodgkin's-like variant, and a giant cell variant [3, 5, 6, 7, 12]. Therefore, also in pathological respect, defining ALK-positive lymphoma as an entity instead of a subgroup of ALCL seems justified.

The present case is a good example of the necessity of immunophenotyping for the classification of this type of lymphoma. Although the distribution in the splenic T-cell areas suggested a T-cell lymphoma [19], it was only after CD30 and ALK1 staining that the case was recognized as an ALCL variant. Also, the magnitude of red pulp involvement became clear only after phenotyping.

Our case represents the small cell variant of ALK-positive ALCL as described recently by several authors [3, 6, 7, 12]. Most tumor cells expressed CD30, ALK1, and EMA, while T-cell markers were only seen in a fraction of the cells. B-cell markers were absent. This marker profile fits those reported in the majority of cases described in the series of Benharroch et al. and others [3, 9, 11]. Typical "hallmark" cells, however, were difficult to recognize. Indeed, in a recent study by Kagami et al. [11], "hallmark" cells were highly characteristic of nodal cytotoxic lymphomas regardless of positivity or negativity of ALK, while our case was negative for cytotoxic markers (perforin, granzyme B, CD57).

The perivascular clustering of large tumor cells, a pattern that was recognized frequently in the small cell variant of ALK-positive ALCL, was also found in the lymph node in our case [3, 6, 11]. In the spleen, however, T-cell areas were massively infiltrated without residual follicles. This pattern seems quite distinctive because the splenic distribution of the common variant ALCL in the rare available histological descriptions is that of a metastatic tumor with massive organ involvement, red pulp infiltration, formation of tumor nodes, and lymph vessel localization [2, 10]. In a study of the pattern of splenic involvement by NHL in 139 cases, only two peripheral T-cell lymphomas were observed. They presented with infiltration of the follicles, marginal zone, and the red pulp along the capillaries [19].

Splenic involvement as such is very rare in ALCL. Sporadic reports in the literature include two cases of post-transplant ALCL [2, 10], a case of development of most likely Hodgkin's-like ALCL in a patient with chronic lymphocytic leukemia (CLL) [15], nine cases of splenic involvement at relapse after chemotherapy, however, without histologic proof [14], and finally a case of leukemic phase ALCL with t(2;5) and splenomegaly, again without histological confirmation of tumor involvement of the spleen [1]. In their series of ALK-positive ALCL patients with a cytotoxic phenotype, Kagami et al. [11] reported three cases with splenic involvement without giving any details.

The importance of recognizing CD30 positivity in non-anaplastic and non-large cell ALCL lies in the gen-

erally much better prognosis of ALCL than peripheral T-cell lymphoma [18] and in the even better prognosis of the ALK-positive ALCL subgroup than ALCL in general [9].

References

- Anderson MM, Ross CW, Singleton TP, Sheldon S, Schnitzer B (1996) Ki-1 anaplastic large cell lymphoma with a prominent leukemic phase. *Hum Pathol* 27:1093-1095
- Audouin J, Le Tourneau A, Diebold J, Reynes M, Tabbah I, Bernadou A (1989) Primary intestinal lymphoma of Ki-1 large cell anaplastic type with mesenteric lymph node and spleen involvement in a renal transplant recipient. *Hematol Oncol* 7:441-449
- Benharroch D, Meguerian-Bedoyan Z, Lamant L, Amin C, Brugieres L, Terrier-Lacombe M-J, Haralambieva E, Pulford K, Pileri S, Morris SW, Mason DY, Delsol G (1998) ALK-positive lymphoma: a single disease with a broad spectrum of morphology. *Blood* 91:2076-2084
- Bitter MA, Franklin WA, Larson RA, McKeithan TW, Rubin CM, Le Beau MM, Stephens JK, Vardiman JW (1990) Morphology in Ki-1 (CD30)-positive non-Hodgkin's lymphoma is correlated with clinical features and the presence of a unique chromosomal abnormality, t(2;5)(p23;q35). *Am J Surg Pathol* 14:305-316
- Chan JKC (1998) Anaplastic large cell lymphoma: redefining its morphologic spectrum and importance of recognition of the ALK-positive subset. *Adv Anat Pathol* 5:281-313
- Falini B, Bigerna B, Fizzotti M, Pulford K, Pileri SA, Delsol G, Carbone A, Paulli M, Magrini U, Menestrina F, Giardini R, Pilotti S, Mezzelani A, Ugolini B, Billi M, Pucciarini A, Pacini R, Pelicci PG, Flenghi L (1998) ALK expression defines a distinct group of T/null lymphomas ("ALK lymphomas") with a wide morphological spectrum. *Am J Pathol* 153:875-886
- Falini B, Pileri S, Zinzani PL, Carbone A, Zagonel V, Wolf-Peeters C, Verhoef G, Menestrina F, Todeschini G, Paulli M, Lazzarino M, Giardini R, Aiello R, Foss HD, Araujo I, Fizzotti M, Pelicci PG, Flenghi L, Martelli MF, Santucci A (1999) ALK+ lymphoma: clinico-pathological findings and outcome. *Blood* 93:2697-2706
- Gascoyne RD, Aoun P, Wu D, Chhanabhai M, Skinnider BF, Greiner TC, Morris SW, Connors JM, Vose JM, Viswanatha DS, Coldman A, Weisenburger DD (1999) Prognostic significance of anaplastic lymphoma kinase (ALK) protein expression in adults with anaplastic large cell lymphoma. *Blood* 93:3913-3921
- Giagounidis AAN, Burk M, Meckenstock G, Koch AJ, Schneider W (1996) Pathologic rupture of the spleen in hematologic malignancies: two additional cases. *Ann Hematol* 73:297-302
- Jimenez-Heffernan JA, Viguer JM, Vicandi B, Jimenez-Yuste V, Palacios J, Escuin F, Gamallo C (1997) Posttransplant CD30 (Ki-1)-positive anaplastic large cell lymphoma. Report of a case with presentation as a pleural effusion. *Acta Cytol* 41:1519-1524
- Kagami Y, Suzuki R, Taji H, Yatabe Y, Takeuchi T, Maeda S, Kondo E, Kojima M, Motoori T, Mizoguchi Y, Okamoto M, Ohnishi K, Yamabe H, Seto M, Ogura M, Koshikawa T, Takahashi T, Kurita S, Morishima Y, Suchi T, Nakamura S (1999) Nodal cytotoxic lymphoma spectrum. A clinicopathologic study of 66 patients. *Am J Surg Pathol* 23:1184-1200
- Kinney MC, Kadin ME (1999) The pathologic and clinical spectrum of anaplastic large cell lymphoma and correlation with ALK gene dysregulation. *Am J Clin Pathol* 111[suppl 1]:S56-S67
- Kinney MC, Collins RD, Greer JP, Whitlock JA, Sioutos N, Kadin ME (1993) A small-cell-predominant variant of primary Ki-1 (CD30)+ T-cell lymphoma. *Am J Surg Pathol* 17:859-868

14. Massimino M, Gasparini M, Giardini R (1995) Ki-1 (CD30) anaplastic large-cell lymphoma in children. *Ann Oncol* 6: 915–920
15. Nai GA, Cabello-Inchausti B, Suster S (1998) Anaplastic large cell lymphoma of the spleen. *Pathol Res Pract* 194:517–522
16. Nakamura S, Shiota M, Nakagawa A, Yatabe Y, Kojima M, Motoori T, Suzuki R, Kagami Y, Ogura M, Morishima Y, Mizoguchi Y, Okamoto M, Seto M, Koshikawa T, Mori S, Suchi T (1997) Anaplastic large cell lymphoma: a distinct molecular pathologic entity. A reappraisal with special reference to p80(NPM/ALK) expression. *Am J Surg Pathol* 21:1420–1432
17. The Non-Hodgkin's Lymphoma Classification Project (1997) A clinical evaluation of the International Lymphoma Study Group classification of non-Hodgkin's lymphoma. *Blood* 89: 3909–3918
18. Shiota M, Nakamura S, Ichinohasamauchi J, Mikata A, Nanba K, Takami T, Yamabe H, Takano Y, Izumo T, Nagatani T, Mohri N, Nasu K, Satoh H, Katano H, Fujimoto J, Yamamoto T, Mori S (1995) Anaplastic large cell lymphomas expressing the novel chimeric protein p80(NPM/ALK): a distinct clinicopathologic entity. *Blood* 86:1954–1960
19. Van Krieken JHJM, Feller AC, Te Velde J (1989) The distribution of non-Hodgkin's lymphoma in the lymphoid compartments of the human spleen. *Am J Surg Pathol* 13:757–765
20. Van Krieken JHJM, Elwood L, Andrade RE, Jaffe ES, Cossman J, Medeiros LJ (1991) Rearrangement of the T-cell receptor delta chain gene in T-cell lymphomas with a mature phenotype. *Am J Pathol* 139:161–168
21. Weisenburger DD, Gordon BG, Vose JM, Bast MA, Chan WC, Greiner TC, Anderson JR, Sanger WG (1996) Occurrence of the t(2;5)(p23;q35) in non-Hodgkin's lymphoma. *Blood* 87: 3860–3868