

# Oral Insulin Up-regulates Toll-like Receptor 4 Expression and Enhances Intestinal Recovery Following Lipopolysaccharide-induced Gut Injury in a Rat

Igor Sukhotnik · Naim Shehadeh · Lilah Rothem · Michael Lurie · Jorge Mogilner · Eitan Shiloni · Raanan Shamir

Received: 7 December 2006 / Accepted: 15 August 2007 / Published online: 13 October 2007  
© Springer Science+Business Media, LLC 2007

**Abstract** In the present study, we evaluated the protective effect of oral insulin (OI) on intestinal mucosa following lipopolysaccharide-induced intestinal damage in a rat. Male Sprague-Dawley rats were divided into three experimental groups: Sham rats, LPS-rats that were treated with lipopolysaccharide (LPS), and LPS-INS rats that were treated with OI given in drinking water 72 h before and following injection of LPS. Intestinal structural changes, enterocyte proliferation, enterocyte apoptosis, and mucosal expression of Toll-like receptor 4 (TLR4) were determined 24 h after the last LPS injection. LPS-INS animals showed a significantly greater bowel and mucosal weight in

jejunum and ileum, mucosal DNA and protein in jejunum and ileum, villus height in ileum, crypt depth in jejunum and ileum, cell proliferation rates in jejunum, and significantly lower apoptotic index in ileum compared to LPS-animals. LPS rats demonstrated 50% increase in TLR4 expression in jejunum compared to sham animals. Treatment with OI resulted in a three-fold increase in TLR4 expression in jejunum, compared to LPS animals. In conclusion, OI improves intestinal recovery after LPS endotoxemia in a rat.

**Keywords** Sepsis · Lipopolysaccharide · Oral insulin · Intestine · Mucosa

Igor Sukhotnik and Naim Shehadeh contributed equally to the preparation of this manuscript.

I. Sukhotnik (✉) · J. Mogilner  
Department of Pediatric Surgery B, Bnai Zion Medical Center,  
47 Golomb St, P.O. Box 4940, Haifa 31048, Israel  
e-mail: igor-dr@internet-zahav.net

N. Shehadeh  
Department of Pediatrics, Meyer Children's Hospital, Rambam  
Medical Center, The Bruce Rappaport Faculty of Medicine,  
Technion-Israel Institute of Technology, Haifa, Israel

L. Rothem · R. Shamir  
Department of Pediatric Gastroenterology and Nutrition, Meyer  
Children's Hospital, Rambam Medical Center, The Bruce  
Rappaport Faculty of Medicine, Technion-Israel Institute of  
Technology, Haifa, Israel

M. Lurie  
Department of Pathology, Bnai Zion Medical Center, Haifa,  
Israel

E. Shiloni  
Department of Surgery, Carmel Medical Center, Haifa, Israel

## Introduction

Sepsis and its consequences, adult respiratory distress syndrome (ARDS) and multiple organ failure (MOF), are major causes of mortality in severely sick and injured patients. The exact mechanisms of sepsis and MOF are still an enigma, but it has been suggested that the gut is the “motor” of such septic states [1] and the first step of a “gut-liver-lung axis” [2]. A number of factors have been shown to predispose to the passage of bacteria or bacteria products such as endotoxin from the lumen of the gut into the bloodstream (bacterial translocation). These include shock, parenteral nutrition, intestinal epithelial damage, and antibiotic therapy [3]. Translocation of bacteria and endotoxin may lead to activation of the immune inflammatory system and the production of cytokines and other immune inflammatory mediators that can promote systemic inflammatory response, multiple organ failure, and death [4].

Sepsis by itself may lead to the alteration of the gut flora, impaired host immune defenses, or direct gut

mucosal injury and may result in gut barrier failure. All of the above derangements, acting in concert, may ultimately lead to multiple organ failure and death [5]. The mechanisms by which sepsis damages intestinal mucosa are poorly understood. The innate immune recognition of bacterial and viral products is mediated by a family of transmembrane receptors known as Toll-like receptors (TLRs). Since TLRs were initially found as mammalian homologues of the *Drosophila* membrane protein toll [6], ten mammalian homologues have been identified and are designated TLR1–10, respectively [7]. Several experimental studies have shown that lipopolysaccharide (LPS), a major cell wall constituent of Gram-negative bacteria, is usually recognized by TLR4 receptor whereas TLR2 recognizes gram-positive bacterial cell wall components [8]. In enterocytes, exposure to LPS results in endothelial activation through a TLR4 receptor.

A complex of several immunologic and nonimmunologic processes maintains the barrier function of the gastrointestinal tract. Recent evidence suggests that the combination of an intact intestinal mucosa and a normally functioning immune system provides adequate barrier function. In this context, identification of factors that promote growth and regeneration of the intestinal epithelium may suggest new therapeutic strategies for maintaining gut integrity in septic patients.

Although the intestine is not a classic target tissue for insulin, extensive experimental studies have established that insulin supplementation has important physiological effects in the context of intestinal growth, cell maturation, and differentiation of the small intestine [9–11].

The purpose of this study was to evaluate the effects of oral insulin in preventing mucosal damage caused by LPS endotoxemia in a rat model, including its effect on enterocyte proliferation and death via apoptosis, and to determine whether alterations in Toll-like receptor 4-mediated signaling may occur during LPS endotoxemia and insulin administration.

## Materials and methods

### Animals

The experimental protocol was approved by the “Guide for the Care and Use of Laboratory Animals”, Rappaport Faculty of Medicine, Technion (Haifa, Israel). Male Sprague-Dawley rats weighing 250–300 g were kept in individual stainless steel cages at constant temperature (21°C) and humidity, and a 12-h light–dark cycle was maintained. The rats were acclimatized for a minimum of 1 week before experimentation. The rats had free access to water and were pair fed with standard chow.

### Experimental design

Animals were randomly assigned to one of three experimental groups of 10 rats each: (1) Sham rats (group A,  $n = 10$ ) underwent I.P. injection of sterile saline once a day; (2) lipopolysaccharide (LPS) rats (group B,  $n = 10$ ) were treated with LPS and given I.P. once a day at a dose of 10 mg/kg for 48 h (two doses); and (3) LPS-INS rats (group C,  $n = 10$ ) were pretreated with oral insulin given in drinking water (2%) 48 h before and following injection of LPS.

### Intestinal mucosal parameters

Twenty-four hours after the last LPS injection, animals were anesthetized with I.P. sodium pentobarbital (45 mg/kg) and were sacrificed by inducing open pneumothorax. The small bowel was excised quickly, washed with cold isotonic saline and divided into two segments: proximal jejunum immediately after Treitz ligament and terminal ileum proximal to ileo–cecal junction. Each segment was weighed, cut longitudinally, and the diameter was measured at three equidistant places. Mucosa was scraped using a glass slide, collected, and weighed. DNA and protein were extracted from the mucosa of jejunum and ileum using TRIzol reagent as described by Chomczynski [12]. DNA concentration was recorded spectrophotometrically and calculated per cm of bowel length/100 g body weight. Final protein concentration was measured spectrophotometrically using a commercially available kit (Bio-Rad, Protein Assay) and was calculated per cm of bowel length.

### Histologic changes

Histological sections were prepared from the proximal jejunum and distal ileum. The samples of intestinal tissues were fixed in a 10% formaldehyde solution (2–3% methanol), then were embedded in paraffin wax using standard techniques. Sections (5  $\mu\text{m}$  each) were cut and stained with hematoxylin and eosin. The mucosal damage of the small bowel or intestinal injury was graded using the Park score [13]: 0 normal mucosa, 1 subepithelial space at villus tip, 2 more extended subepithelial space, 3 epithelial lifting along villus sides, 4 denuded villi, 5 loss of villus tissue, 6 crypt layer infarction, 7 transmucosal infarction, and 8 transmural infarction.

The villus height and crypt depth for each specimen were measured using an objective mounted micrometer (100 $\times$  magnification) and an optical microscope (10 $\times$ 100 magnification). Villus height and crypt depth data were

derived from eight rats in each group, and each measurement consisted of the mean of ten villi and crypts.

#### Crypt cell proliferation and villus cell apoptosis

Standard 5-bromodeoxyuridine (5-BrdU) labeling reagent (Zymed Laboratories, Inc., San Francisco, CA) was injected intraperitoneally at a dose of 1 ml/100 g body weight 2 h before sacrifice. Crypt cell proliferation was assessed using the biotinylated monoclonal anti-BrdU antibody system provided in a kit form (Zymed Laboratories, Inc, San Francisco, CA). An index of proliferation was determined as the ratio of crypt cells staining positively for BrdU per five crypts.

Immunohistochemistry for Caspase-3 (Caspase-3 cleaved concentrated polyclonal antibody; dilution 1:100; Biocare Medical, Walnut Creek, CA) was performed for identification of apoptotic cells using a combination of the streptavidin–biotin–peroxidase method and microwave antigen retrieval on formalin-fixed, paraffin-embedded tissues according to manufacturers' protocols. Briefly, 5  $\mu$ m sections were deparaffinized, rehydrated in graded alcohol, and microwave-pretreated in EDTA buffer for 10 min. After washing in phosphate-buffered saline (PBS), the specimens were incubated in peroxidase quenching solution (3% H<sub>2</sub>O<sub>2</sub> in methanol) for 10 min, then were treated with serum blocking solution for 10 min, and thereafter were stained with primary Caspase-3 cleaved polyclonal antibodies (diluted 1:100) for 60 min in a moist chamber. After washing, the slides were incubated with human-absorbed, biotinylated, affinity-purified antibody to react with primary antibodies. Enhanced horseradish peroxidase conjugated streptavidin was then bound to the biotinylated secondary antibodies. The DAB was then used to create an intense brown deposit around the antigen–antibody–enzyme complex in the sample. For each group, the number of stained cells was counted in at least ten villi in areas without necrosis. The apoptotic index (AI) was defined as the number of apoptotic cells per ten villi.

All measurements were performed by a qualified pathologist blinded as to the source of intestinal tissue.

#### Expression of TLR4

Intestinal segments (proximal jejunum and distal ileum) were quickly isolated and frozen after sacrifice and conserved at  $-80^{\circ}\text{C}$ . For total RNA extractions, approximately 100 mg of tissue was homogenized with a glass homogenizer. Total RNA was isolated using TRIzol reagent (Gibco BRL, USA), as described by Chomczynski [12], and then was serially diluted with water pretreated with

diethylpyrocarbonate. A portion of total RNA (2  $\mu$ g in a total volume of 25  $\mu$ l) was reverse transcribed using Moloney murine leukemia virus (MMLV) First strand cDNA Synthesis Kit (Gene Choice, Inc., MD, USA). The reaction buffer contains random hexamer primers and dNTPs. Portions of cDNA ( $\sim 50$  ng) synthesized from cells were amplified using 10 pmol of each primer in 2 $\times$  Reddy Mix PCR master mic reaction buffer according to the manufacturer's instructions (ABgene, Epson, Surrey, UK). The PCR reaction was performed as follows: initial melting at  $95^{\circ}\text{C}$  for 5 min, followed by 30 cycles each of 1 min at  $95^{\circ}\text{C}$ , annealing at  $60^{\circ}\text{C}$  for rTLR4 and r $\beta$ -actin for 45 s, elongation at  $72^{\circ}\text{C}$  for 1 min, followed by a 10-min extension at  $72^{\circ}\text{C}$ .

After PCR, the amplified product (5 ml) was run on a 2% agarose gel stained with ethidium bromide and photographed. The level of gene expression was expressed as the ratio of the gray density of the objective gene over the gray density of  $\beta$ -actin at densometry. The sequences for the gene-specific TLR4 and  $\beta$ -actin primers are depicted in Table 1 (all primers were purchased from Sigma).

#### Statistical analysis

The data are expressed as the mean  $\pm$  SEM. A nonparametric Kruskal-Wallis ANOVA test was used for statistical analysis with  $P < 0.05$  considered statistically significant.

## Results

#### Mortality rate

All animals in groups A survived. Injection of LPS (group B) resulted in a 23% mortality rate (3 of 13 rats died). Pretreatment with insulin resulted in a 17% mortality (2 of 12 rats died). The remaining rats recovered from the surgery uneventfully.

#### Body weight changes

About 90% of LPS-animals (groups B and C) suffered from appetite loss, diarrhea, and weight loss. LPS endotoxemia

**Table 1** Oligonucleotids used for RT-PCR of rTLR4 and r $\beta$ -actin genes

Oligonucleotide name	Sequence (5'-3')	Annealing temperature
rTLR4 up	CAGCTCTCAACCTTGGTACT	60
rTLR4 dw	CTTGGGCTTGAATGGAGTC	60
r $\beta$ -actin up	CAGGGTGTGATGGTGGGTAT	60
r $\beta$ -actin dw	CAGAGGCATACAGGGACAAC	60

(group B) resulted in an approximately 15% ( $88.2 \pm 1.1$  vs.  $104.3 \pm 0.5$ ,  $P < 0.05$ ) decrease in final body weight compared to sham animals (group A). Exposure to oral insulin (group C) led to small but significant increases in final body weight ( $91.3 \pm 0.8$  vs.  $88.2 \pm 1.1$ ,  $P < 0.05$ ) compared to the LPS animals (group B); however, final body weight in this group was still significantly lower than in sham animals (group A).

#### Intestinal mucosal parameters

LPS endotoxemia (group B) resulted in a significant decrease in bowel weight in jejunum (29%,  $P < 0.005$ ) and ileum (15%,  $P < 0.005$ ), mucosal weight in jejunum (41%,  $P < 0.005$ ) and ileum (40%,  $P < 0.005$ ), mucosal DNA in jejunum (35%,  $P < 0.005$ ) and ileum (43%,  $P < 0.005$ ), and mucosal protein in jejunum (32%,  $P < 0.005$ ) and ileum (39%,  $P < 0.005$ ) (Table 2) compared to control animals (group A). Following oral insulin administration, LPS-rats (group C) demonstrated a significant increase in jejunal (13%,  $P < 0.005$ ) and ileal (16%,  $P < 0.05$ ) bowel weight, jejunal (26%,  $P < 0.005$ ) and ileal (37%,  $P < 0.005$ ) mucosal weight, jejunal (40%,  $P < 0.005$ ) and ileal (47%,  $P < 0.005$ ) mucosal DNA, and jejunal (20%,  $P < 0.005$ ) and ileal (23%,  $P < 0.005$ ) mucosal protein compared to LPS-animals (group B).

#### Microscopic parameters

A significant decrease in villus height in jejunum (13%,  $P < 0.05$ ) and ileum (17%,  $P < 0.05$ ) and crypt depth in ileum (11%,  $P < 0.05$ ) was seen in rats following LPS endotoxemia (group B) compared to sham animals (group A) (Table 3). Following oral insulin administration (group C), LPS animals demonstrated a significant increase in ileal (24%,  $P < 0.05$ ) villus height as well as jejunal (14%,

**Table 3** Changes in microscopic bowel appearance

Parameters	Sham ( $n = 10$ )	LPS ( $n = 10$ )	LPS-INS ( $n = 10$ )
Villus height ( $\mu\text{m}$ )			
Jejunum	$475 \pm 27$	$411 \pm 17^a$	$442 \pm 18$
Ileum	$385 \pm 40$	$320 \pm 25^a$	$396 \pm 11^b$
Crypt depth ( $\mu\text{m}$ )			
Jejunum	$161 \pm 4$	$154 \pm 6$	$176 \pm 5^b$
Ileum	$164 \pm 9$	$146 \pm 7^a$	$180 \pm 4^b$
Park score			
Jejunum	$0.3 \pm 0.1$	$1.4 \pm 0.5^a$	$0.8 \pm 0.4$
Ileum	$0.9 \pm 0.4$	$1.8 \pm 0.3^a$	$1.6 \pm 0.6$

Abbreviations: LPS lipopolysaccharide, INS insulin.

Values are mean  $\pm$  SEM.

<sup>a</sup>  $P < 0.05$  LPS versus Sham rats.

<sup>b</sup>  $P < 0.05$  LPS-INS versus LPS rats

$P < 0.05$ ) and ileal (27%,  $P < 0.05$ ) crypt depth compared to LPS- animals (group B).

Park's injury score (Table 3) increased significantly following LPS endotoxemia (group A) in jejunum (five-fold,  $P < 0.05$ ) and ileum (two-fold,  $P < 0.05$ ) compared to sham animals (group A). Pretreatment with oral insulin did not change intestinal injury score significantly compared to LPS-animals (group B).

#### Enterocyte proliferation and apoptosis

LPS rats (group B) showed a significant decrease in the proliferation index in ileum ( $123 \pm 5$  vs.  $149 \pm 12$  BrdU positive cells per 10 crypts,  $P < 0.05$ ) compared to sham animals (group A) and a trend toward a decrease in cell proliferation in jejunum ( $127 \pm 6$  vs.  $138 \pm 3$  BrdU positive cells per 10 crypts,  $P = 0.1$ ); however, this trend did

**Table 2** Changes in intestinal mucosal parameters

Parameters	Sham ( $n = 10$ )	LPS <sup>a</sup> ( $n = 10$ )	LPS-INS ( $n = 10$ )
Bowel weight (mg/cm length)			
Jejunum	$53.4 \pm 0.9$	$38.1 \pm 1.9$	$43.3 \pm 1.2^{a,b}$
Ileum	$45.4 \pm 2$	$38.5 \pm 2.2$	$44.7 \pm 1.7^b$
Mucosal weight (mg/cm length)			
Jejunum	$22.9 \pm 1.1$	$13.6 \pm 1.1$	$17.2 \pm 0.7^{a,b}$
Ileum	$20.5 \pm 1.4$	$12.3 \pm 1.1$	$16.9 \pm 1^{a,b}$
Mucosal DNA ( $\mu\text{g/cm length}$ )			
Jejunum	$31 \pm 1$	$20 \pm 3$	$28 \pm 2^b$
Ileum	$30 \pm 2$	$17 \pm 3$	$25 \pm 1^{a,b}$
Mucosal protein ( $\mu\text{g/cm length}$ )			
Jejunum	$151 \pm 13$	$103 \pm 9$	$124 \pm 5^{a,b}$
Ileum	$133 \pm 8$	$81 \pm 8$	$100 \pm 5^{a,b}$

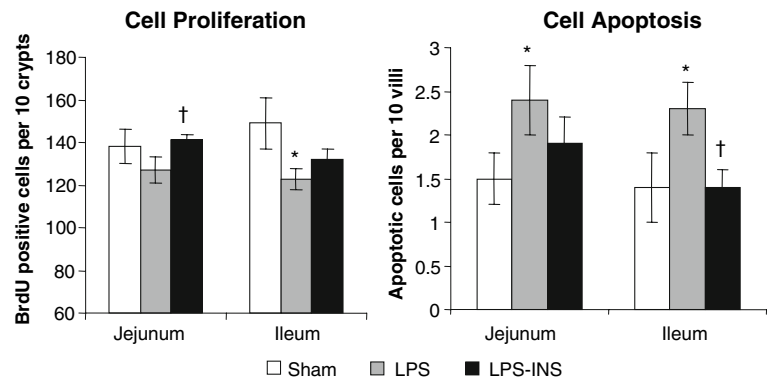
Abbreviations: LPS lipopolysaccharide, INS insulin.

Values are mean  $\pm$  SEM.

<sup>a</sup>  $P < 0.05$  LPS versus Sham rats.

<sup>b</sup>  $P < 0.05$  LPS-INS versus LPS rats

**Fig. 1** Effect of lipopolysaccharide endotoxemia and oral insulin on enterocyte proliferation and apoptosis. Values are mean  $\pm$  SEM. *LPS* lipopolysaccharide, *INS* insulin. \* $P < 0.05$  LPS versus Sham rats and † $P < 0.05$  LPS-INS versus LPS rats



not achieve statistical significance (Figs. 1 and 2). Following administration of oral insulin, LPS-rats (group C) demonstrated a significant increase in the jejunal ( $141 \pm 3$  vs.  $127 \pm 6$  BrdU positive cells per 10 crypts,  $P < 0.05$ ) proliferation rates compared to LPS-animals (group B), and a trend toward increase in the ileal proliferation index ( $132 \pm 5$  vs.  $123 \pm 5$  BrdU positive cells per 10 crypts,  $P = 0.07$ ); however, this trend was not statistically significant.

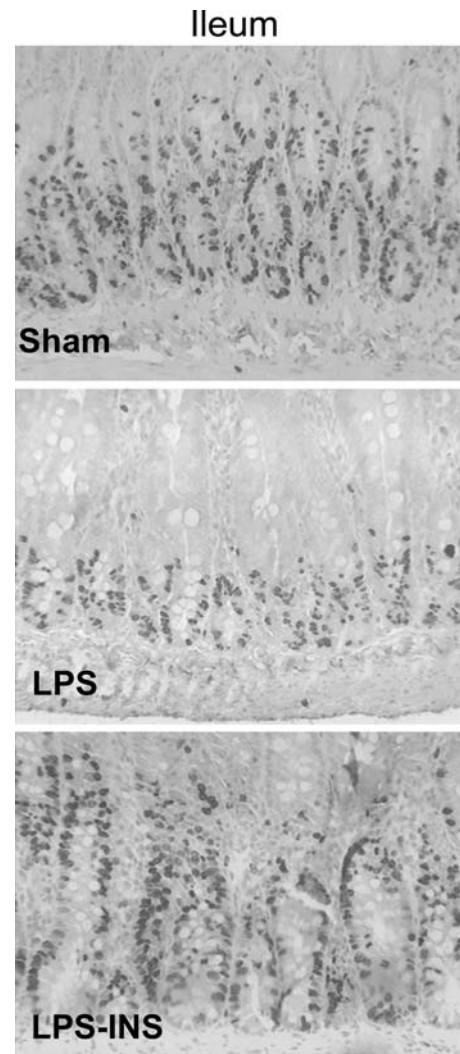
LPS-rats showed a significant increase in enterocyte apoptosis in jejunum ( $2.4 \pm 0.4$  vs.  $1.5 \pm 0.3$  apoptotic cells per 10 villi,  $P < 0.05$ ) and ileum ( $2.3 \pm 0.3$  vs.  $1.4 \pm 0.4$  apoptotic cells per 10 villi,  $P < 0.05$ ) compared to sham animals (Figs. 1 and 3). Following pretreatment with oral insulin (group C), LPS rats showed a significant decrease in apoptotic index in ileum ( $1.4 \pm 0.2$  vs.  $2.3 \pm 0.3$  apoptotic cells per 10 villi,  $P < 0.05$ ) compared to LPS-animals (group B), and tendency toward decrease in cell apoptosis in jejunum; however, this trend did not achieve statistical significance.

#### Expression of TLR4

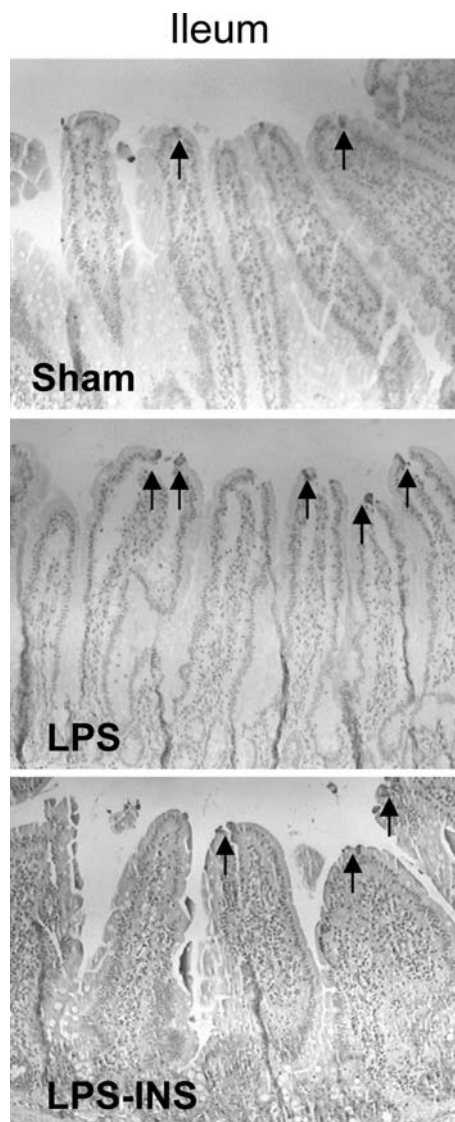
LPS rats (group B) demonstrated a 50% increase in TLR4 expression in jejunum (Fig. 4) compared to sham animals (group A). Pretreatment with oral insulin (group C) resulted in a three-fold increase in TLR4 expression in jejunum compared to LPS-animals (group B). There was no significant change in the TLR4 expression in ileum between the three experimental groups.

#### Discussion

Extensive studies in various experimental models have established that insulin plays an important role in normal intestinal physiology [10, 11, 14–16]. A fact that insulin is

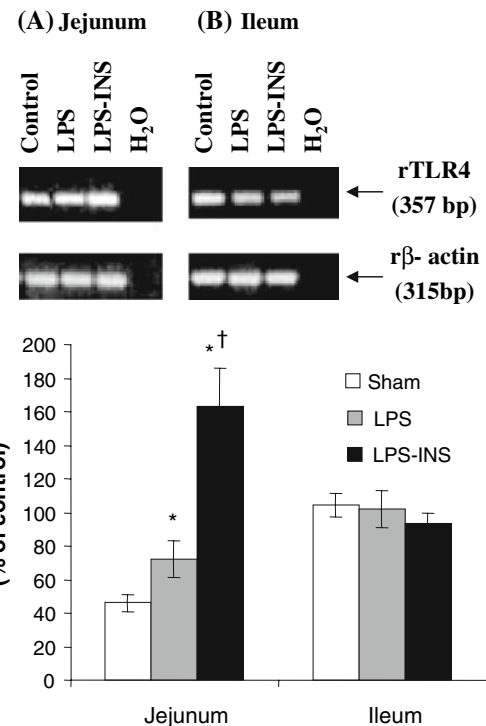


**Fig. 2** Effect of lipopolysaccharide endotoxemia and oral insulin on crypt cell proliferation. 5-BrdU incorporation into proliferating cells was detected with a goat anti-BrdU antibody. The representative sections demonstrate that cell proliferation decreased following LPS administration compared to sham animals. Following administration of oral insulin, LPS-rats demonstrated a nonmarked increase in a number of proliferating cells compared to LPS-nontreated animals



**Fig. 3** Effect of lipopolysaccharide endotoxemia and oral insulin on enterocyte apoptosis. Immunohistochemistry for caspase-3 was used to determine enterocyte apoptosis. As expected, Sham rats demonstrate a normal histologic architecture and single apoptotic cells. LPS rats show extended subepithelial space (Park score 2–3) and a significant increase in the number of the apoptotic cells. LPS-INS rats exhibited a less marked subepithelial space and a decrease in the number of apoptotic cells

present in human milk and that breast milk stimulates maturation and proliferation of intestinal mucosa, led to the hypothesis that insulin might have a trophic gut effect [9]. Shulman et al. [10] have demonstrated that administration of oral insulin causes an increase in ileal mass and disaccharidase activity in the newborn miniature pig without apparent concomitant changes in serum glucose, insulin, or cortisol levels. In another experiment, the same authors observed an increase in ileal lactase activity following oral insulin administration in the newborn miniature pig [11]. In a recent clinical trial, these authors has shown that enteral



**Fig. 4** Effect of lipopolysaccharide endotoxemia and oral insulin on expression of Toll-like receptor 4 (TLR4). LPS rats demonstrated a 55% increase in TLR4 expression in jejunum compared to sham animals. Pretreatment with oral insulin resulted in a two-fold increase in TLR4 expression in jejunum compared to LPS-animals. There was no significant change in the TLR4 expression in ileum between the three experimental groups. Values are mean  $\pm$  SEM. LPS lipopolysaccharide, INS insulin, TLR4 Toll-like receptor 4. \* $P < 0.05$  LPS versus Sham rats. † $P < 0.05$  LPS-INS versus LPS rats

administration of insulin to preterm infants (26–29 weeks of gestational age) leads to a higher lactase activity and less feeding intolerance [14]. Butts et al. [15] analyzed the distribution, ontogeny, and molecular properties of insulin receptors in immature and mature enterocytes using radioligand binding assays. They have shown that 125I-insulin binding to the insulin receptor was five times higher in crypt cells than in villus cells and two times higher in the ileum than in the jejunum. These authors concluded that increased responsiveness of rat immature enterocytes to insulin could be related to high membrane concentrations of insulin receptor and that normal rat enterocytes express a 60-kDa phosphotyrosine protein identified as a direct substrate of the insulin receptor tyrosine kinase. In another study, these researchers have demonstrated that insulin activates the brush border membrane hydrolases in rat immature intestine by binding the hormone to its intestinal receptor and indirect triggering of the transcription of hydrolases genes and possibly by changes in intracellular polyamine concentrations [16]. We have recently shown that oral insulin supplementation exerts intestinal trophic

effects, as well as systemic effects in rats when administered up to 6 weeks beyond the suckling period [17]. Since insulin has trophic gut effects, we hypothesized that insulin may have a beneficial effect on gut growth and recovery in different gastrointestinal disorders. We have recently demonstrated that oral insulin exerts a strong stimulating effect on bowel re-growth following massive small bowel resection in a rat [18]. In a different experiment, we have shown that oral insulin does not prevent ischemic damage but accelerates intestinal recovery, enhances enterocyte proliferation, and decreases cell death via apoptosis following intestinal ischemia-reperfusion in jury in rats [19].

In the present experiment, we investigated the effects of oral insulin in preventing mucosal damage caused by lipopolysaccharide endotoxemia in a rat. In a recent study, we have demonstrated that LPS endotoxemia impairs the integrity of the gastrointestinal mucosa in a rat. Decreased cell proliferation and increased apoptosis were the main mechanisms responsible for decreased cell mass in this model [20]. Our results show that LPS endotoxemia causes a direct intestinal mucosal injury (this is evident from increased Park's intestinal injury score) and leads to mucosal hypoplasia. The observed decreased bowel and mucosal weight, decreased mucosal DNA and protein, and decreased villus height and crypt depth in this model support this conclusion. The changes in body weight and small bowel morphology in the current report were similar to those observed in our previous experiment [20]. The data from the previous study [20] and the current one suggest that intestinal hypoplasia is the predominant feature of mucosal damage.

Although the Sham-insulin group was not included in the current study, we have recently shown that oral insulin exerts a trophic effect on normal intestine. In rats, oral insulin given in the postweaning period resulted in a significant increase in mucosal weight as well as intestinal DNA content and villus height. The maximal changes were observed in the first week of insulin treatment, and most significant changes were observed in the proximal intestine [17]. The present data clearly indicate that oral insulin had a strong stimulating effect on intestinal recovery from intestinal mucosal injury caused by LPS similar to that seen previously in suckling rats. Increased bowel and mucosal weight as well as mucosal DNA and protein support this conclusion. Parallel increases in mucosal DNA and protein indicate that the greater mucosal mass of animals treated with oral insulin can be attributed to cellular hyperplasia. Because the DNA content is directly proportional to mucosal cell number, these measurements exclude such factors as edema or vascular engorgement as responsible for differences in mucosal mass. Increased villus height may be the result of increased proliferation and accelerated migration along the villus, and is a marker for the increased

absorptive surface area and increased numbers of epithelial cells. Increased mucosal proliferation in functioning intestine as demonstrated by the increased cell proliferation index following oral insulin administration together with decreased cell death via apoptosis, suggests an activated enterocyte turnover and may be considered a main mechanism of mucosal hyperplasia in recovering bowel. Our data indicate that oral insulin did not prevent the damaging effect of LPS on gut. This is evident from unchanged injury score scale following insulin administration.

The intestinal mucosal surfaces are continuously exposed to large amounts of bacterial products such as LPS. LPS, a well-known bacterial pyrogen, is recognized by several receptors, including the Toll-like receptor (TLR) 4, on various cells including enterocytes. TLR4 recognizes LPS and transduces a proinflammatory signal through the adapter molecule myeloid differentiation marker MyD88 [21]. Many studies in various experimental models have established that TLR4 expression in different organs and tissues is up-regulated following LPS administration. Janardhan et al. [22] have shown that TLR4 expression in lung is sustained up to 36 h after intra-tracheal instillation of LPS. LPS-induced suppression of cardiac myocyte contractility is TLR4-dependent [23]. In accordance with other tissues, several experimental studies have shown that TLR4 mRNAs is upregulated in the small intestine after LPS administration [24]. The fact that the intestinal epithelium seems to be unresponsive to intestinal luminal LPS was explained by low or absent expression of TLR4, MD-2, and the co-receptor molecule CD14 in cells constituting the intestinal mucosal surface [25].

In the present study, we observed a 50% increase in the TLR4 receptor expression in jejunum following LPS administration; however, in ileum TLR4 expression remained unchanged. Therefore, we suggest that the signaling pathways leading from LPS to TLR4 activation in jejunum and ileum may be different. Because the bacterial contamination in ileum is significantly greater than that in jejunum, the mechanism of the ubiquitous activation of TLR4 in the presence of LPS is limited in the ileum to protect the mucosa against massive amounts of bacteria and bacterial LPS present in the intestinal lumen and do not initiate acute inflammatory responses as would be elicited along mucosal surface in jejunum. Our observations are consistent with data of other investigators who note that the human intestine exhibits specific mechanisms for LPS tolerance, given its proximity to the enteric flora and their otherwise strong innate response to LPS [25–27].

Exposure to oral insulin resulted in three-fold increase in TLR4 expression in jejunum compared to LPS-nontreated rats. This increase of TLR4 expression together with increased LPS did not lead to mucosal damage in this

group compared to LPS-animals. In contrast, LPS-INS rats showed a significantly enhanced cell turnover. It should be emphasized that parallel increase in LPS exposure and up-regulation of TLR4 expression has less significant damaging effect on intestinal mucosa compared to other organs and tissues. Indeed, insulin fragments themselves exert their stimulated effect on cell turnover through binding to the other receptors. It is likely that other specific growth-related genes are also up-regulated by insulin in the gastrointestinal tract. Similar to LPS, oral insulin exerted minimal effect on TLR4 expression in the ileum. This may be explained by the presence of bacteria in the ileum that may lead to a temporary insensitivity of cells toward subsequent LPS and insulin stimulation. The mechanism by which insulin increases TLR4 are unknown. Since one would assume that increased TLR4 is part of the LPS induced injury, it is reasonable to suggest that the adaptive response of the intestine to oral insulin is stronger than its effects on TLR4.

In conclusion, oral insulin does not prevent intestinal mucosal injury caused by LPS endotoxemia in the rat, but it enhances intestinal mucosal recovery following LPS administration. Increased enterocyte proliferation and decreased enterocyte apoptosis may be responsible for this positive effect. Oral insulin increases the stimulating effect of LPS on Toll-like receptor 4 expression in the proximal intestine, suggesting that TLR4 is not the mediator of injury in this model.

## References

- Deitch EA (1990) The role of intestinal barrier failure and bacterial translocation in the development of systemic infection and multiple organ failure. *Arch Surg* 125:403–404
- Pugin J, Chevrolet JC (1991) The intestine–liver–lung axis in septic syndrome. *Schweiz Med Wochenschr* 121:1538–1544
- Deitch EA (1993) Nutrition and the gut mucosal barrier. In: Daly J (ed) *Current opinions in general surgery*. Current Science, Philadelphia, PA, pp 85–91
- Swank GM, Deitch EA (1996) Role of the gut in multiple organ failure: bacterial translocation and permeability changes. *World J Surg* 20:411–417
- Mainous MR, Block EF, Deitch EA (1994) Nutritional support of the gut: how and why. *New Horiz* 2:193–201
- Lemaitre B, Nicolas E, Michaut L, Reichhart JM, Hoffmann JA (1996) The dorsoventral regulatory gene cassette *spätzle/Toll/cactus* controls the potent antifungal response in *Drosophila* adults. *Cell* 86:973–983
- Hemmi H, Takeuchi O, Kawai T, Kaisho T, Sato S, Sanjo H, Matsumoto M, Hoshino K, Wagner H, Takeda K, Akira S (2000) A toll-like receptor recognizes bacterial DNA. *Nature* 408:740–745
- Yoshimura A, Lien E, Ingalls RR, Tuomanen E, Dziarski R, Golenbock D (1999) Cutting edge: recognition of Gram-positive bacterial cell wall components by the innate immune system occurs via Toll-like receptor 2. *J Immunol* 163:1–5
- Carver JD, Barness LA (1996) Trophic factors for the gastrointestinal tract. *Clin Perinatol* 23:265–285
- Shulman RJ (1990) Oral insulin increases small intestinal mass and disaccharidase activity in the newborn miniature pig. *Pediatr Res* 28:171–175
- Shulman RJ, Tivey DR, Sunitha I, Dudley MA, Henning SJ (1992) Effect of oral insulin on lactase activity, mRNA, and posttranscriptional processing in the newborn pig. *J Pediatr Gastroenterol Nutr* 14:166–172
- Chromszynski P (1993) A reagent for the single-step simultaneous isolation of RNA, DNA and proteins from cell and tissue samples. *BioTechniques* 15:532–536
- Park PO, Haglund U, Bulkley GB, Falt K (1990) The sequence of development of intestinal tissue injury after strangulation ischemia and reperfusion. *Surgery* 107:574–580
- Shulman RJ (2002) Effect of enteral administration of insulin on intestinal development and feeding tolerance in preterm infants: a pilot study. *Arch Dis Child Fetal Neonatal Ed* 86:F131–F133
- Buts JP, De Keyser N, Marandi S, Maernoudt AS, Sokal EM, Rahier J, Hermans D (1997) Expression of insulin receptors and of 60-kDa receptor substrate in rat mature and immature enterocytes. *Am J Physiol* 273(1 Pt 1):G217–G226
- Buts JP, Durantont B, De Keyser N, Sokal EM, Maernhout AS, Raul F, Marandi S (1998) Premature stimulation of rat sucrase-isomaltase (SI) by exogenous insulin and the analog B-Asp10 is regulated by a receptor-mediated signal triggering SI gene transcription. *Pediatr Res* 43:585–591
- Shamir R, Muslach M, Sukhotnik I, Perlman R, Diamond E, Mogilner J, Shehadeh N (2005) Intestinal and systemic effects of oral insulin supplementation in rats after weaning. *Dig Dis Sci* 50:1239–1244
- Sukhotnik I, Shehadeh N, Shamir R, Bejar J, Bernshteyn A, Mogilner JG (2005) Oral insulin enhances intestinal re-growth following massive small bowel resection in rat. *Dig Dis Sci* 50:2379–2385
- Sukhotnik I, Shehadeh N, Mogilner J, Shamir R, Helou H, Lurie M, Shiloni E (2005) Beneficial effects of oral insulin on intestinal recovery following ischemia-reperfusion injury in rat. *J Surg Res* 128:108–113
- Sukhotnik I, Mogilner J, Krausz MM, Lurie M, Hirsh M, Coran AG, Shiloni E (2004) Oral arginine reduces gut mucosal injury caused by lipopolysaccharide endotoxemia in a rat. *J Surg Res* 122:256–262
- Fukata M, Michelsen KS, Eri R, Thomas LS, Hu B, Lukasek K, Nast CC, Lechago J, Xu R, Naiki Y, Soliman A, Arditi M, Abreu MT (2005) Toll-like receptor-4 is required for intestinal response to epithelial injury and limiting bacterial translocation in a murine model of acute colitis. *Am J Physiol Gastrointest Liver Physiol* 288:G1055–G1065
- Janardhan KS, McIsaac M, Fowlie J, Shrivastav A, Caldwell S, Sharma RK, Singh B (2006) Toll like receptor-4 expression in lipopolysaccharide induced lung inflammation. *Histol Histopathol* 21:687–696
- Baumgarten G, Knuefermann P, Schuhmacher G, Vervölgyi V, von Rappard J, Dreiner U, Fink K, Djoufack C, Hoelt A, Grohé C, Knowlton AA, Meyer R (2006) Toll-like receptor 4, nitric oxide, and myocardial depression in endotoxemia. *Shock* 25:43–49
- Miyaso H, Morimoto Y, Ozaki M, Haga S, Shinoura S, Choda Y, Iwagaki H, Tanaka N (2005) Obstructive jaundice increases sensitivity to lipopolysaccharide via TLR4 upregulation: possible involvement in gut-derived hepatocyte growth factor-protection of hepatocytes. *J Gastroenterol Hepatol* 20:1859–1866



25. Abreu MT, Vora P, Faure E, Thomas LS, Arnold ET, Arditi M (2001) Decreased expression of Toll-like receptor-4 and MD-2 correlates with intestinal epithelial cell protection against dysregulated proinflammatory gene expression in response to bacterial lipopolysaccharide. *J Immunol* 167:1609–1616
26. Poltorak A, Ricciardi-Castagnoli P, Citterio S, Beutler B (2000) Physical contact between lipopolysaccharide and Toll-like receptor 4 revealed by genetic complementation. *Proc Natl Acad Sci USA* 97:2163–2167
27. Ogawa H, Rafiee P, Heidemann J, Fisher PJ, Johnson NA, Otterson MF, Kalyanaraman B, Pritchard KA, Binion DG (2003) Mechanisms of endotoxin tolerance in human intestinal microvascular endothelial cells. *J Immunol* 170:5956–5964