

## CNS Manifestations Associated with *Mycoplasma pneumoniae* Infections: Summary of Cases at the University of Helsinki and Review

Marjaleena Koskiniemi

From the Department of Virology, University of Helsinki, Helsinki, Finland

CNS manifestations appear in one of 1,000 patients with *Mycoplasma pneumoniae*-associated infections. Encephalitis is the most frequent manifestation, but cases of meningitis, myelitis, and polyradiculitis, as well as many other symptoms (e.g., coma, ataxia, psychosis, and stroke), have been reported. The onset of these manifestations is usually acute, with lowered consciousness, convulsions, pareses, and other neurological signs. Severe, even fatal, cases are known. The pathophysiology of CNS manifestations is unknown. To our knowledge, *M. pneumoniae* has never been isolated from brain tissue, but instead it has been recovered from CSF specimens in at least seven cases. Besides direct invasion of *M. pneumoniae* into the brain, neurotoxic or autoimmune reaction within the brain tissue is suspected. At neuropathological examination, edema, demyelination, and microthrombi have been described. Improved diagnostic methods may reveal the pathophysiology of CNS manifestations associated with *M. pneumoniae* infection.

CNS manifestations are probably the most frequent extrapulmonary complications of infections due to *Mycoplasma pneumoniae* [1–3] and, as with *M. pneumoniae* infections in general [4], occur most frequently in children [5, 6]. Still, the incidence of these manifestations is only one per 1,000 patients with *M. pneumoniae* infections [1]. CNS symptoms are present in up to 7% of patients treated at hospitals for *M. pneumoniae* infection [6–10]. In turn, among patients with neurological syndromes, *M. pneumoniae* is associated with 5% to 10% of cases [11, 12]. Severe CNS diseases—even those with fatal outcomes—have been reported in association with *M. pneumoniae* infections [6, 13–16]. This circumstance emphasizes the need to learn more about these diseases, including their pathophysiology and diagnosis. Therefore, a summary of our own cases and a review of the literature are presented.

### Summary of Cases

#### Patients and Methods

Sixty-one patients, 30 males and 31 females, with neurological diseases were treated at the Children's Hospital or at the Department of Neurology, University of Helsinki, Helsinki, over a 24-year period from January 1967 to December 1990 (figure 1). These patients' diseases were associated with a diagnostic rise ( $\geq 4$ -fold) in titer of antibody to *M. pneumoniae* in paired sera or with a high titer ( $\geq 64$ ) of this antibody in a single sample of serum. A concomitant high titer of

antibody to *M. pneumoniae* was observed in 10 further patients in whom encephalitis apparently was associated with another microbe (coxsackie virus B in five and various microbes in five).

The routine schema for examining the patients included blood and urine analysis, CSF examination, electroencephalogram (EEG) recording, and electroneuromyography, if needed. Neuroradiological examinations, including computed tomography (CT) of the brain since the late 1970s and magnetic resonance imaging (MRI) of the brain since the early 1980s, were performed if needed. Screening for antibody was done by the CF test with 15–17 different antigens. These antigens included adenovirus, coronavirus (until 1982), coxsackie virus B5, cytomegalovirus, hepatitis B virus (since 1970), herpes simplex virus, influenza A and B viruses, parainfluenza 1 and 3 viruses, poliovirus, respiratory syncytial virus, rotavirus (since 1976), varicella zoster virus, *Chlamydia* group antigen, *M. pneumoniae*, and *Toxoplasma gondii*. Screening for arbovirus was dropped in the early 1980s because no cases were found.

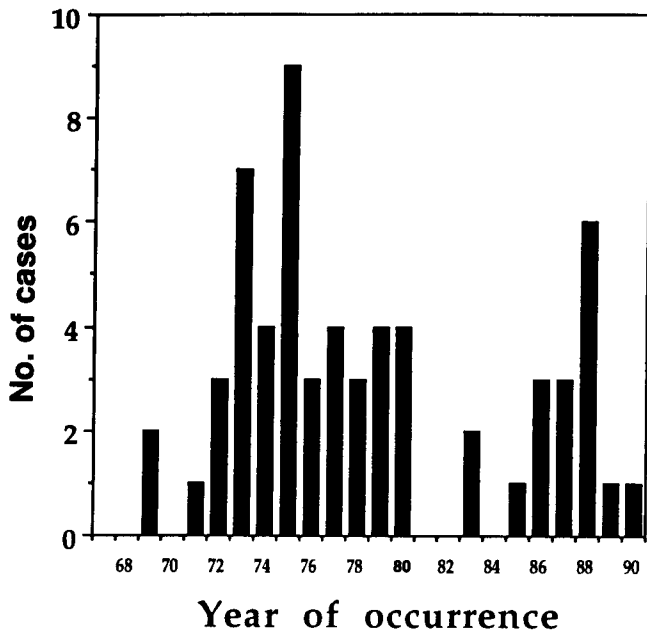
#### Clinical Entities

**Acute encephalitis.** All pediatric patients (45) had encephalitis. Of the adult patients, 10 (63%) had encephalitis (figure 2). Most patients (78%) had meningeal symptoms and signs: headache, nausea or vomiting, and neck stiffness (table 1). Many patients had high temperatures, though some patients' temperatures were normal. One-half of the patients had convulsions on admission or during their stay in the hospital. More than two-thirds of the patients were unconscious or somnolent on admission. In addition, focal neurological signs appeared, e.g., ataxia, deviation of the eye, hemiparesis, or paresthesia. More than one-third (38%) of the patients had an associated pneumonia or other respiratory disease. In some patients, carditis or Reye's syndrome was present.

---

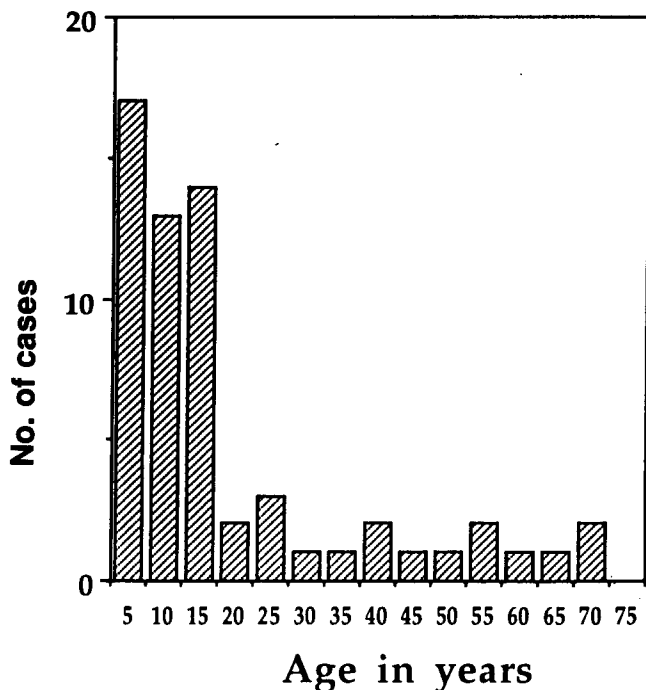
Reprints or correspondence: Dr. Marjaleena Koskiniemi, Department of Virology, University of Helsinki, Haartmaninkatu 3, SF-00290 Helsinki, Finland.

**Clinical Infectious Diseases** 1993;17(Suppl 1):S52–7  
 © 1993 by The University of Chicago. All rights reserved.  
 1058–4838/93/1702–0006\$02.00



**Figure 1.** Yearly distribution of patients with CNS manifestations and diagnostic or high titers of antibody to *M. pneumoniae*.

The symptoms were usually acute; in one-half of the cases, they lasted  $\leq 1$  day (figure 3). A large proportion (30%) of the patients needed intensive care, usually for a long period (mean period, 12 days). The hospital stay ranged from 1 day to 3 months (mean stay, 2–3 weeks).



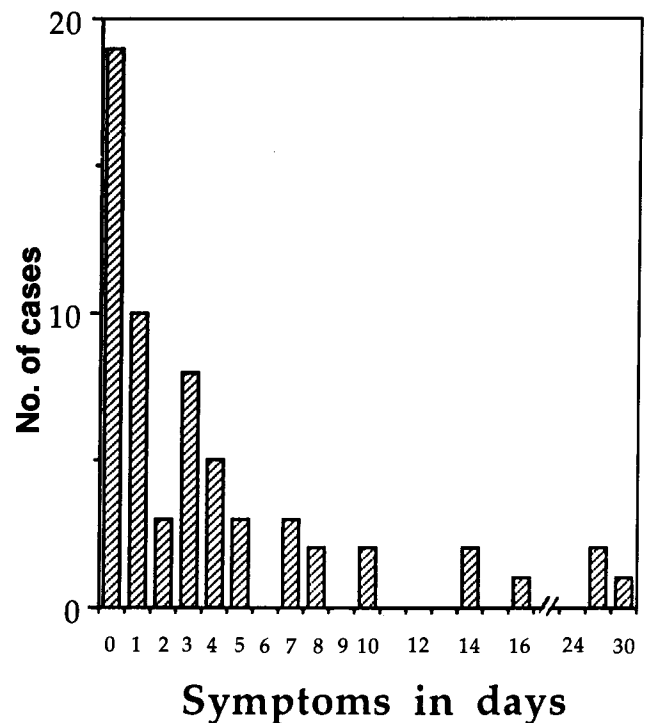
**Figure 2.** The distribution by age of patients with CNS manifestations and diagnostic or high titers of antibody to *M. pneumoniae*.

**Table 1.** Signs and symptoms of encephalitis that are associated with *M. pneumoniae* infections.

Signs and symptoms	Percentage of patients with signs and symptoms
Meningeal signs/symptoms*	78
High temperature ( $\geq 39^\circ\text{C}$ )	53
Convulsions	46
Unconsciousness	35
Somnolence	42
Ataxia	20
Ocular findings	15
Respiratory symptoms	38
Carditis	6
Reye's syndrome	7

\* Headache, nausea or vomiting, and neck stiffness.

**Other diseases.** Besides encephalitis, adult patients had meningitis, myelitis, and polyradiculitis, two cases of each (figure 2). Cases of meningitis were mild, resembling the clinical course of a usual case of serous meningitis. One patient with myelitis became tetraplegic; plasma exchange was done, and after 2 months she was able to walk. The other patient with myelitis had transverse involvement at the T-8 level; this patient recovered in 1 month with minor sequelae. Both patients with polyradiculitis became tetraplegic; one



**Figure 3.** The duration of symptoms in patients with encephalitis associated with diagnostic or high titers of antibody to *M. pneumoniae*.

was treated with plasma exchange, and the other was not. Both of these patients recovered in 6 weeks. Findings of electroneuromyography were consistent with polyradiculitis, while the protein concentration in the CSF was only slightly increased.

### Laboratory Findings

In our series, 60% of cases had normal findings for CSF (white blood cell count,  $0-230 \times 10^6/L$ ; protein concentration, 180–1,640 mg/L) at the onset of the manifestation. Most samples were taken on the first 3 days, and if results of CSF analysis were normal, specimens were not obtained later. Thus these findings are relevant to the beginning but not to the later course of the disease. Enterovirus was cultured concomitantly from feces from two patients, and herpes simplex virus antigen was detected in throat specimens from three patients.

Results of EEG recording were usually severely (51%) or moderately (27%) disturbed during the first week of neurological illness, and the disturbance was often seen for weeks after the onset.

Findings of CT/MRI were unremarkable in our cases, though these tests were performed for one-third of the patients. Evidence of edema, but not of focal lesions, was seen on some patients' scans.

### Outcome and Prognosis

Five patients (8%) died. Fourteen patients (23%) had severe sequelae: mental retardation, choreoathetosis, convulsions, and movement disorders. The duration of neurological symptoms before hospital admission was not associated with the outcome. Long-lasting unconsciousness was associated with poor outcome, though even after 8 days one patient recovered from unconsciousness. If an abnormality revealed by EEG recording was present for >4 weeks, sequelae were more common than on average [17].

### Literature Review

#### CNS Manifestations Associated with *M. pneumoniae* Infections

*M. pneumoniae*-associated CNS manifestations are variable (table 2). Encephalitis seems to be the main type in children [17, 18]; in adults the clinical picture is more diverse [19–21]. Encephalitis may be diffuse or focal [22], often expansive [23, 24]. It may resemble encephalitis lethargica [25]. This manifestation may concentrate in the cerebellum or pons regions [26, 27] and may cause hydrocephalus [28]. Sometimes encephalitis may be recurrent [29]. Meningitis is usually a mild manifestation [11, 30]. Myelitis may appear in different forms: diffuse, transverse [1, 11, 31, 32], or polioliike [33]. In addition, there are descrip-

**Table 2.** CNS and other neurological manifestations associated with *M. pneumoniae* infections.

---

Encephalitis, meningoencephalitis
Diffuse
Focal, tumorlike (expansive)
Cerebellar
Pontine
Recurrent
Meningitis
Myelitis
Transverse
Diffuse
Lower motor neuron (polioliike syndrome)
Other descriptions
Coma, stupor
Lethargy
Ataxia
Choreoathetosis
Psychosis
Stroke, cerebral infarction
Other neurological manifestations
Guillain-Barré syndrome
Cranial nerve neuropathy
Peripheral nerve neuropathy
Myositis, myalgia

---

tive terms that characterize *M. pneumoniae*-associated diseases; these terms include coma, stupor, ataxia, athetosis, psychosis [30, 34, 35], and even stroke [36], after which a real infarct may occur [37].

Other neurological manifestations include Guillain-Barré syndrome; *M. pneumoniae* infection may be associated with this syndrome in 5% of patients [38–40]. Neuropathy in cranial or peripheral nerves and myositis have been described as well [41].

### Diagnostic Criteria

The primary diagnosis of *M. pneumoniae*-associated disease is clinical. The first serology available was the test for cold agglutinins in 1941 [42]. This test, however, is positive in only one- or two-thirds of cases. Titers of CF antibodies may decline on admission to the hospital because often the patient has had the disease for some time. Throat cultures are positive in 65% of cases [43]. Antibody titers in the serum as well as those in the CSF may be nonspecific [44] apparently because of differences between antigens; lipid-containing antigen may be cross-reactive with brain antigens, making the results uncertain [45–47]. A CT scan may reveal hypodensity in parietal areas [48] or diffuse edema [18, 49]. Contrast enhancement and mass effect may be present [22] even if results of CT are normal for most patients [18, 21, 50].

### Isolation of *M. pneumoniae* from the CNS and Future Trends

*M. pneumoniae* has been isolated from CSF specimens in at least seven cases [51–55], but isolation will never be the

**Table 3.** Pathophysiology of and neuropathological findings associated with *M. pneumoniae* infections.

Pathophysiology
Direct invasion
Neurotoxic reaction
Autoimmune complex syndrome
Vasculopathy
Neuropathological findings
Edema
Perivascular infiltrations
Demyelination
Microthrombi

diagnostic method of choice [11]. Isolation of the organism from the CSF suggests that *M. pneumoniae* invades the CNS. However, to our knowledge, *M. pneumoniae* has never been isolated from brain tissue. Thus the theory of direct invasion of *M. pneumoniae* into brain tissue is somewhat loose. The RNA hybridization test (Gen-Probe, San Diego) has been diagnostic for throat specimens, tracheal aspirates, and lung tissue [56], but whether it is for CSF or brain tissue is unknown. As a new approach, the polymerase chain reaction is a promising method [57–60], although no reports on determinations of CSF have been published yet.

### Therapy

Both erythromycin and tetracycline are effective against *M. pneumoniae* in vitro and in vivo [61]. The results, however, are variable, and antibiotic therapy may be beneficial [50] or have no effect [5, 11, 22]. In CNS diseases associated with *M. pneumoniae*, the problem of therapy is unresolved. Corticosteroids, anti-inflammatory drugs, and antidiuretics have been used as well as antibiotics [22, 24, 62].

Plasma exchange has been reported in at least one case, and it appeared to be beneficial [63]. In our series, plasma exchange was done for one patient with myelitis and one with polyradiculitis, and both patients recovered; however, the other two patients with myelitis and polyradiculitis who did not undergo plasma exchange recovered as well.

### Pathophysiology of CNS Diseases

The pathophysiology behind the CNS symptomatology in *M. pneumoniae*-associated diseases remains hypothetical [64, 65]. *M. pneumoniae* itself may invade the CNS (in the CSF at least) because the organism has been isolated from CSF [52–55]. Still, involvement in brain tissue remains uncertain. Some neurotoxin may be released or there may be an autoimmune complex or vasculopathy (table 3) [49, 66, 67].

At neuropathological examination, the brain may be edematous throughout or on basal parts, and scattered areas of hemorrhages may be seen [49]. There may also be perivascu-

lar infiltration, microthrombi, and areas of demyelination [24, 49].

### Comment

It is evident that CNS manifestations associated with *M. pneumoniae* infections are real, but exact diagnostic methods are rarely available. Diagnostic difficulties include cross-reactivity of the antigen [46, 47, 68]. Newer technology may help us to make specific diagnoses. *M. pneumoniae* may be a concomitant or predisposing factor [69]. The pathophysiology of *M. pneumoniae*-associated CNS manifestations is largely unknown.

In spite of the diagnostic problems associated with titers of CF antibody, we argue for the existence of CNS manifestations in association with *M. pneumoniae* infections. In our large series, *M. pneumoniae* accounted for 13% of known or suggested etiologies in childhood encephalitides [70] and 7% in adult encephalitides [71]. Our present series of 61 patients with diagnostic or high titers of antibody to *M. pneumoniae* showed clinical diseases similar to those previously reported. The age spectrum of patients who have neurological diseases associated with *M. pneumoniae* infection seems to be a little higher than that of patients with respiratory diseases caused by *M. pneumoniae* [4, 12, 72]. The death rate and sequelae we observed resemble those observed by other investigators [3]. These results, many signs of persistent syndromes [25, 27], persistent brain stem dysfunction [50], and prolonged immunologic response [62] all emphasize the need for further study of *M. pneumoniae*-associated CNS manifestations.

### References

1. Yesnick L. Central nervous system complications of primary atypical pneumonia. *Arch Intern Med* 1956;97:93–8.
2. Noah ND. *Mycoplasma pneumoniae* infection in the United Kingdom: 1967–1973. *Br Med J* 1974;2:544–6.
3. Cassell GH, Cole BC. Mycoplasmas as agents of human disease. *N Engl J Med* 1981;304:80–9.
4. Fernald GW, Collier AM, Clyde WA Jr. Respiratory infections due to *Mycoplasma pneumoniae* in infants and children. *Pediatrics* 1975;55:327–35.
5. Lerer RJ, Kalavsky SM. Central nervous system disease associated with *Mycoplasma pneumoniae* infection: report of five cases and review of the literature. *Pediatrics* 1973;52:658–68.
6. Pönkä A. Central nervous system manifestations associated with serologically verified *Mycoplasma pneumoniae* infection. *Scand J Infect Dis* 1980;12:175–84.
7. Biberfeld G, Johnsson T, Jonsson J. Studies on *Mycoplasma pneumoniae* infection in Sweden. *Acta Pathol Microbiol Scand* 1965;63:469–75.
8. Sköldenberg B. Aseptic meningitis and meningoencephalitis in cold agglutinin positive infections. *Br Med J* 1965;1:100.
9. Smith C, Sangster G. *Mycoplasma pneumoniae* meningoencephalitis. *Scand J Infect Dis* 1972;4:69–71.
10. Levine DP, Lerner AM. The clinical spectrum of *Mycoplasma pneumoniae* infections. *Med Clin North Am* 1978;62:961–78.

11. Lind K, Zoffmann H, Larsen SO, Jessen O. Mycoplasma pneumoniae infection associated with affection of the central nervous system. *Acta Med Scand* 1979;205:325-32.
12. Urquhart GED. *Mycoplasma pneumoniae* infection and neurological complications [letter]. *Br Med J* 1979;2:1512.
13. Dorff B, Lind K. Two fatal cases of meningoencephalitis associated with *Mycoplasma pneumoniae* infection. *Scand J Infect Dis* 1976;8:49-51.
14. Weinblatt ME, Caplan ES. Fatal *Mycoplasma pneumoniae* encephalitis in an adult. *Arch Neurol* 1980;37:321.
15. Roberts JE, Isaacs D. Neurological and pulmonary complications of *Mycoplasma pneumoniae* infection in a pre-school child. *J Infect* 1986;12:251-2.
16. Hoen B, Gerard A, Canton Ph, Dureux JB. Manifestations neurologiques graves des infections à *Mycoplasma pneumoniae*. *Presse Med* 1989;18:229-30.
17. Lehtokoski-Lehtiniemi E, Koskiniemi ML. Mycoplasma pneumoniae encephalitis: a severe entity in children. *Pediatr Infect Dis J* 1989;8:651-3.
18. Scully RE, Mark EJ, McNeely BU. Case records of the Massachusetts General Hospital: weekly clinicopathological exercises. *N Engl J Med* 1981;305:507-14.
19. Hodges GR, Fass RJ, Saslaw S. Central nervous system disease associated with *Mycoplasma pneumoniae* infection. *Arch Intern Med* 1972;130:277-82.
20. Twomey JA, Espir MLE. Neurological manifestations and mycoplasma pneumoniae infection. *Br Med J* 1979;2:832-3.
21. Decaux G, Szyper M, Ectors M, Cornil A, Franken L. Central nervous system complications of *Mycoplasma pneumoniae*. *J Neurol Neurosurg Psychiatry* 1980;43:883-7.
22. Plotkin GR, Slovak JP Jr, Lentz PE. Case report. Mycoplasma pneumonia presenting as meningoencephalitis and hemolytic anemia. *Am J Med Sci* 1979;278:235-42.
23. Jones DB. Neurological manifestations and *Mycoplasma pneumoniae* infection [letter]. *Br Med J* 1979;2:1144.
24. Behan PO, Feldman RG, Segerra JM, Draper IT. Neurological aspects of mycoplasmal infection. *Acta Neurol Scand* 1986;74:314-22.
25. Al-Mateen M, Gibbs M, Dietrich R, Mitchell WG, Menkes JH. Encephalitis lethargica-like illness in a girl with mycoplasma infection. *Neurology* 1988;38:1155-8.
26. Jachuck SJ, Gardner-Thorpe C, Clark F, Foster JB. A brainstem syndrome associated with Mycoplasma pneumoniae infection—a report of two cases. *Postgrad Med J* 1975;51:475-7.
27. Mårdh PA, Ursing B, Lind K. Persistent cerebellar symptoms after infection with *Mycoplasma pneumoniae*. *Scand J Infect Dis* 1975;7:157-60.
28. Coleman RJ, Brown JS, Butler P, Swash M. Cerebellar syndrome with hydrocephalus due to *Mycoplasma pneumoniae* infection. *Postgrad Med J* 1990;66:554-6.
29. Burman LG, Löfgren S. Recurrent pneumonia and encephalitis due to *Mycoplasma pneumoniae*. *Scand J Infect Dis* 1979;11:170-2.
30. Sterner G, Biberfeld G. Central nervous system complications of *Mycoplasma pneumoniae* infection. *Scand J Infect Dis* 1969;1:203-8.
31. Nicholsson G. Transverse myelitis complicating Mycoplasma pneumoniae infection. *Postgrad Med J* 1977;53:86-7.
32. Klimek JJ, Russman BS, Quintiliani R. *Mycoplasma pneumoniae* meningoencephalitis and transverse myelitis in association with low cerebrospinal fluid glucose. *Pediatrics* 1976;58:133-5.
33. Warren P, Fischbein C, Mascoli N, Rudolph J, Hodder DH. Poliomyelitis-like syndrome caused by *Mycoplasma pneumoniae*. *J Pediatr* 1978;93:451-2.
34. Balassanian N, Robbins FC. *Mycoplasma pneumoniae* infection in families. *N Engl J Med* 1967;277:719-25.
35. Moskal MJ, Kaylarian VH, Doro JM. Psychosis complicating *Mycoplasma pneumoniae* infection. *Pediatr Infect Dis* 1984;3:63-6.
36. Mulder LJMM, Spierings ELH. Stroke in a young adult with *Mycoplasma pneumoniae* infection complicated by intravascular coagulation. *Neurology* 1987;37:1430-1.
37. Parker P, Puck J, Fernandez F. Cerebral infarction associated with *Mycoplasma pneumoniae*. *Pediatrics* 1981;67:373-5.
38. Sangster G. Neurological complications of primary atypical pneumonia. *Br J Clin Pract* 1966;20:89-92.
39. Steele JC, Gladstone RM, Thanasophon S, Fleming PC. *Mycoplasma pneumoniae* as a determinant of the Guillain-Barré syndrome. *Lancet* 1969;2:710-4.
40. Goldschmidt B, Menonna J, Fortunato J, Dowling P, Cook S. Mycoplasma antibody in Guillain-Barré syndrome and other neurological disorders. *Ann Neurol* 1980;7:108-12.
41. Rothstein TL, Kenny GE. Cranial neuropathy, myeloradiculopathy, and myositis: complications of *Mycoplasma pneumoniae* infection. *Arch Neurol* 1979;36:476-7.
42. Smith GN, Weir WRC. Cold agglutinins accompanying *Mycoplasma pneumoniae* infection. *Br Med J* 1980;281:1391-2.
43. Stevens D, Swift PGF, Johnston PGB, Kearney PJ, Corner BD, Burman D. *Mycoplasma pneumoniae* infections in children. *Arch Dis Child* 1978;53:38-42.
44. Räisänen SM, Suni JI, Leinikki PO. Serological diagnosis of *Mycoplasma pneumoniae* infection by enzyme immunoassay. *J Clin Pathol* 1980;33:836-40.
45. Biberfeld G. Antibodies to brain and other tissues in cases of *Mycoplasma pneumoniae* infection. *Clin Exp Immunol* 1971;8:319-33.
46. Leinikki PO, Panzar P, Tykkä H. Immunoglobulin M antibody response against *Mycoplasma pneumoniae* lipid antigen in patients with acute pancreatitis. *J Clin Microbiol* 1978;8:113-8.
47. Kleemola M, Käyhty H. Increase in titers of antibodies to *Mycoplasma pneumoniae* in patients with purulent meningitis. *J Infect Dis* 1982;146:284-8.
48. Heijer JCD, Peters ACB, Van Gemert GW. Postinfectious meningoencephalitis complicating *Mycoplasma pneumoniae* in a child [letter]. *J Neurol Neurosurg Psychiatry* 1986;49:600-2.
49. Fisher RS, Clark AW, Wolinsky JS, Parhad IM, Moses H, Mardiney MR. Postinfectious leukoencephalitis complicating *Mycoplasma pneumoniae* infection. *Arch Neurol* 1983;40:109-13.
50. Ong ELC, Ellis ME, Yuill GM. Neurological complications of *Mycoplasma pneumoniae* infection. *Respir Med* 1989;83:441-2.
51. Fleischhauer P, Huben U, Mertens H, Sethi KK, Thurmann D. Nachweis von *Mycoplasma pneumoniae* im liquor bei akuter polyneuritis. *Dtsch Med Wochenschr* 1972;97:678-82.
52. Bayer AS, Galpin JE, Theofilopoulos AN, Guze LB. Neurologic disease associated with *Mycoplasma pneumoniae* pneumonitis: Demonstration of viable *Mycoplasma pneumoniae* in cerebrospinal fluid and blood by radioisotopic and immunofluorescent tissue culture techniques. *Ann Intern Med* 1981;94:15-20.
53. Kasahara I, Otsubo Y, Yanase T, Oshima H, Ichimaru H, Nakamura M. Isolation and characterization of *Mycoplasma pneumoniae* from cerebrospinal fluid of a patient with pneumonia and meningoencephalitis. *J Infect Dis* 1985;152:823-5.
54. Abramovitz P, Schwartzman P, Harel D, Lis I, Naot Y. Direct invasion of the central nervous system by *Mycoplasma pneumoniae*: a report of two cases. *J Infect Dis* 1987;155:482-7.
55. Nagayama Y, Sakurai N, Tamai K, Niwa A, Yamamoto K. Isolation of *Mycoplasma pneumoniae* from pleural fluid and/or cerebrospinal fluid: report of four cases. *Scand J Infect Dis* 1987;19:521-4.
56. Hyman HC, Yogev D, Razin S. DNA probes for detection and identification of *Mycoplasma pneumoniae* and *Mycoplasma genitalium*. *J Clin Microbiol* 1987;25:726-8.
57. Bernet C, Garret M, de Barbeyrac B, Bebear C, Bonnet J. Detection of

- Mycoplasma pneumoniae* by using the polymerase chain reaction. *J Clin Microbiol* 1989;27:2492-6.
58. Jensen JS, Søndergård-Andersen J, Uldum SA, Lind K. Detection of *Mycoplasma pneumoniae* in simulated clinical samples by polymerase chain reaction. *APMIS* 1989;97:1046-8.
  59. Hata D, Kuze F, Mochizuki Y, et al. Evaluation of DNA probe test for rapid diagnosis of *Mycoplasma pneumoniae* infections. *J Pediatr* 1990;116:273-6.
  60. Dular R, Kajioka R, Kasatiya S. Comparison of Gen-Probe commercial kit and culture technique for the diagnosis of *Mycoplasma pneumoniae* infection. *J Clin Microbiol* 1988;26:1068-9.
  61. Slotkin RI, Clyde WA Jr, Denny FW. The effect of antibiotics on *Mycoplasma pneumoniae* *in vitro* and *in vivo*. *Am J Epidemiol* 1967;86:225-37.
  62. Denny FW, Clyde WA Jr, Glezen WP. *Mycoplasma pneumoniae* disease: clinical spectrum, pathophysiology, epidemiology, and control. *J Infect Dis* 1971;123:74-92.
  63. Cotter FE, Bainbridge D, Newland AC. Neurological deficit associated with *Mycoplasma pneumoniae* reversed by plasma exchange. *Br Med J* 1983;286:22.
  64. Clyde WA Jr. Neurological syndromes and mycoplasmal infections. *Arch Neurol* 1980;37:65-6.
  65. Barile MF. Mycoplasma-tissue cell interactions. In: Tully JG, Whitcomb RF, eds. *The mycoplasmas*. Vol 2. New York: Academic Press, 1979:425-74.
  66. Reik L Jr. Disseminated vasculomyelinopathy: an immune complex disease. *Ann Neurol* 1980;7:291-6.
  67. Thomas L. The possible role of pleuropneumonia-like organisms in neurological disease. *Res Publ Assoc Res Nerv Ment Dis* 1968;44:102-12.
  68. Pönkä A, Pönkä T, Sarna S, Penttinen K. Questionable specificity of lipid antigen in the *Mycoplasma pneumoniae* complement fixation test in patients with extrapulmonary manifestations. *J Infect* 1981;3:332-8.
  69. Krasinski K, Nelson JD, Butler S, Luby JP, Kusmiesz H. Possible association of *Mycoplasma* and viral respiratory infections with bacterial meningitis. *Am J Epidemiol* 1987;125:499-508.
  70. Koskiniemi M, Vahe A. Effect of measles, mumps, rubella vaccination on pattern of encephalitis in children. *Lancet* 1989;1:31-4.
  71. Koskiniemi ML, Vahe A. Acute encephalitis of viral origin. *Scand J Infect Dis* 1982;14:181-7.
  72. Pönkä A, Ukkonen P. Age-related prevalence of complement-fixing antibody to *Mycoplasma pneumoniae* during an 8-year period. *J Clin Microbiol* 1983;17:571-5.