



Since January 2020 Elsevier has created a COVID-19 resource centre with free information in English and Mandarin on the novel coronavirus COVID-19. The COVID-19 resource centre is hosted on Elsevier Connect, the company's public news and information website.

Elsevier hereby grants permission to make all its COVID-19-related research that is available on the COVID-19 resource centre - including this research content - immediately available in PubMed Central and other publicly funded repositories, such as the WHO COVID database with rights for unrestricted research re-use and analyses in any form or by any means with acknowledgement of the original source. These permissions are granted for free by Elsevier for as long as the COVID-19 resource centre remains active.

Available online at www.sciencedirect.com

ScienceDirect

journal homepage: www.jfma-online.com

Correspondence

Necessitating repeated chest CT in COVID-19 pneumonia



An outbreak of novel coronavirus, severe acute respiratory syndrome corona-virus 2 (SARS-CoV-2) began in Wuhan, China, has spread rapidly.¹ The disease caused by SARS-CoV-2 was named as coronavirus disease 2019 (COVID-19) by the World Health Organization.² Chest computed tomography (CT) is easily available and is highly strongly recommended for screening patients for rapid confirmation of SARS-CoV-2 infected COVID-19.³ We report a case with COVID-19 pneumonia which has outlined the main patterns of evolution seen on CT imaging though real-time fluorescence polymerase chain reaction results were negative for a total of four times.

Case report

A 38-year-old man working in a hospital in Wuhan is a dentist with a 2-days history of cough, fever (body temperature up to 38 °C), myalgia without chills and rigor and nasal discharge. Laboratory studies showed decreased lymphocyte percentage (13.3%, normal range, 20.0%–40.0%), normal total white blood cell count ($8.72 \times 10^9/L$, normal range, $3.3\text{--}9.6 \times 10^9/L$) and normal blood level for C-reactive protein ($<0.5 \text{ mg/L}$; normal range, $<10 \text{ mg/L}$).

Unenhanced chest CT showed patchy shadow in upper lobe tongue segment of the left lung (Fig. 1a). Repeat chest CT showed the lesion had quick changes with formation of new lesions in other areas and extended from the

peripheral to the central area suggesting progression of the disease on day 5 (Fig. 1b). After 14 days of therapy, the follow-up CT showed partial resolution and partially added of patchy consolidations and ground-glass opacities in both lungs (Fig. 1c). Real-time fluorescence polymerase chain reaction of the patient's oropharyngeal swab was negative for SARS-CoV-2 nucleic acid on 2, 5, 11, 14 days after hospitalization, respectively.

Discussion

This patient presented typical pattern of CT imaging features and showed the disease progression at the first but partial improvement at the second CT follow-up.⁴ The main evolution seen on CT imaging of this case was differentiated from other pneumonia caused by other viruses or by other microorganisms. And laboratory tests had revealed at early stage normal counts of peripheral blood leukocytes and C-reactive protein were useful for differentiation of bacterial pneumonia. Besides, this case had a typical clinical presentation with definite epidemical history which greatly helps determine COVID-19 pneumonia.

The case we reported was probably prone to misdiagnosis in the clinic because of the lack of molecular confirmation of SARS-CoV-2 infection. Compared to chest CT, current SARS-CoV-2 nucleic acid test is time-consuming and may be initial negative. Typical chest CT findings are

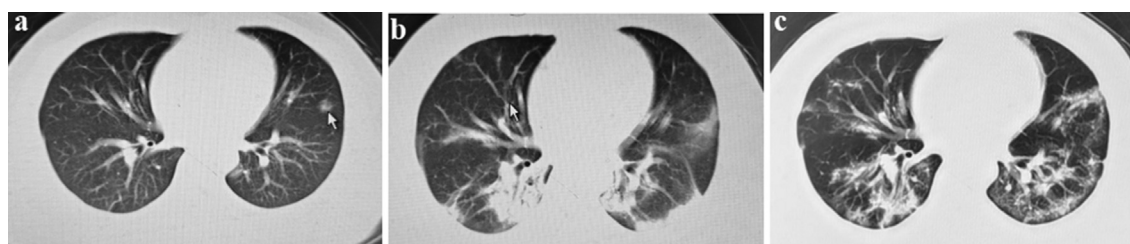


Figure 1 CT scans (slice thickness = 1.2 mm) changes in the course of disease over time. (a: January 29; b: February 04; c: Feb. 19).

<https://doi.org/10.1016/j.jfma.2020.03.006>

0929-6646/Copyright © 2020, Formosan Medical Association. Published by Elsevier Taiwan LLC. This is an open access article under the CC BY-NC-ND license (<http://creativecommons.org/licenses/by-nc-nd/4.0/>).

helpful for initial screening detection and timely isolation of the COVID-19 pneumonia.⁵ Meanwhile, repeated CT scanning could facilitate monitoring disease progression and implementing proper treatment.

Declaration of Competing Interest

The authors have no conflicts of interest relevant to this article.

Acknowledgements

This work was supported by grant from the Emergency Research Project of Dongzhimen Hospital in 2020 (grant 2020-dzmyy-lcyjzx-yj002)

References

1. Wang C, Horby PW, Hayden FG, Gao GF. A novel coronavirus outbreak of global health concern. *Lancet* 2020:470–3.
2. Lorusso A, Calistri P, Petrini A, Savini G, Decaro N. Novel coronavirus (SARS-CoV-2) epidemic: a veterinary perspective. *Vet Ital* 2020. <https://doi.org/10.12834/VetIt.2173.11599.1> [Epub ahead of print].
3. Jin YH, Cai L, Cheng ZS, Cheng H, Deng T, Fan YP, et al. A rapid advice guideline for the diagnosis and treatment of 2019 novel coronavirus (2019-nCoV) infected pneumonia (standard version). *Mil Med Res* 2020. <https://doi.org/10.1186/s40779-020-0233-6> [Epub ahead of print].
4. Shi H, Han X, Jiang N, Cao Y, Alwalid O, Gu J, et al. Radiological findings from 81 patients with COVID-19 pneumonia in Wuhan, China: a descriptive study. *Lancet Infect Dis* 2020. [https://doi.org/10.1016/S1473-3099\(20\)30086-4](https://doi.org/10.1016/S1473-3099(20)30086-4) [Epub ahead of print].
5. Cheng SC, Chang YC, Fan Chiang YL, Chien YC, Cheng M, Yang CH, et al. First case of coronavirus disease 2019 (COVID-19) pneumonia in Taiwan. *J Formos Med Assoc* 2020;119:747–51.

Meng Li¹

Department of Cardiology, Beijing University of Chinese Medicine Affiliated Dongzhimen Hospital, Beijing, China

Li-Jing Zhang¹

Department of Cardiology, Beijing University of Chinese Medicine Affiliated Dongzhimen Hospital, Beijing, China

Gui-Hua Tian^{*,2}

Key Laboratory of Chinese Internal Medicine of Ministry of Education, Beijing University of Chinese Medicine Affiliated Dongzhimen Hospital, Beijing, China

Xue-Zeng Hao^{**,2}

Department of Cardiology, Beijing University of Chinese Medicine Affiliated Dongzhimen Hospital, Beijing, China

Department of Pulmonology, Hubei Provincial Hospital of Integrated Traditional Chinese and Western Medicine, Wuhan, China

*Corresponding author.

E-mail address: rossetgh@163.com (G.-H. Tian)

**Corresponding author.

E-mail address: dzmxnk@163.com (X.-Z. Hao)

7 March 2020

¹ These two authors contributed equally.

² No.5, Haiyuncang Hutong., Dongcheng Dist., Beijing City 100700, China