



Since January 2020 Elsevier has created a COVID-19 resource centre with free information in English and Mandarin on the novel coronavirus COVID-19. The COVID-19 resource centre is hosted on Elsevier Connect, the company's public news and information website.

Elsevier hereby grants permission to make all its COVID-19-related research that is available on the COVID-19 resource centre - including this research content - immediately available in PubMed Central and other publicly funded repositories, such as the WHO COVID database with rights for unrestricted research re-use and analyses in any form or by any means with acknowledgement of the original source. These permissions are granted for free by Elsevier for as long as the COVID-19 resource centre remains active.

JNI 00952

Short Communication

The effects of irradiation on major histocompatibility complex expression and lymphocytic infiltration in the normal rat brain and the 9L gliosarcoma brain tumor model

P. Wen¹, J.S. Loeffler², J.H. Morris³ and L.A. Lampson¹

The Brain Tumor Group; ¹ The Center for Neurologic Diseases, Division of Neurology, Department of Medicine; ² The Joint Center for Radiation Therapy; and ³ the Department of Pathology, Brigham and Women's Hospital; and the Departments of Neurology, Radiation Therapy and Pathology, Harvard Medical School, Boston, MA 02115, U.S.A.

(Received 4 October 1989)

(Revised, received 16 January 1990)

(Accepted 16 January 1990)

Key words: Irradiation; Major histocompatibility complex antigen; Lymphocytic infiltration; Brain tumor; 9L gliosarcoma

Summary

The effects of irradiation on major histocompatibility complex (MHC) expression and lymphocytic infiltration in the normal rat brain and the 9L gliosarcoma brain tumor model were examined. Doses of irradiation administered were biologically equivalent to that used in the treatment of patients with malignant gliomas. No significant change in immune parameters was observed following irradiation in the normal rat brain. In the 9L gliosarcoma model irradiation did not suppress MHC expression or lymphocytic infiltration. These findings suggest that prior exposure to therapeutic irradiation need not adversely affect subsequent immunotherapies, and provide a foundation for future studies of immunomodulation in the irradiated brain.

Introduction

The limitation of current therapy for patients with malignant glioma has led to renewed interest in immunotherapy as an adjunctive mode of treatment. Immunotherapy is likely to be most effective in the early weeks following maximal cytore-

duction with surgery and radiation therapy. The immunosuppressive effects of ionizing radiation are well known (Markoe and Saluk, 1987). Irradiation has been shown to decrease major histocompatibility complex (MHC) expression and lymphocytic infiltration in melanoma (Jager et al., 1988) and reduce the effectiveness of some forms of immunotherapy (Ettinghausen et al., 1985). However, under certain circumstances, irradiation can enhance the host immune response, and increase the efficacy of immunotherapeutic regimens (Hellstrom et al., 1978; Tilkin et al., 1981; North, 1984). Recent work has defined a growing number

Address for correspondence: Patrick Wen, M.D., Division of Neurology, Brigham and Women's Hospital, Boston, MA 02115, U.S.A.

of pathological and experimental situations in which the brain's immune environment is altered (Lampson, 1987). Yet few studies have addressed the possible effects of irradiation on immune parameters in the normal or tumor-bearing brain. In this study, we examined the effects of irradiation, biologically equivalent to that used in the treatment of patients with malignant gliomas, during the time period when immunotherapy is most likely to be attempted. MHC expression and lymphocyte infiltration were examined in irradiated tumor-free brains and in the 9L gliosarcoma brain tumor model.

Materials and methods

Rats. Female CDF rats (125–150 g) were purchased from Charles River Lab. (Wilmington, MA, U.S.A.).

Antibodies. Immunocytochemistry was carried out with rabbit serum against glial fibrillary acidic protein (GFAP) (Dako) and the monoclonal antibodies OX6 (class II), OX18 (class I MHC), OX1 (LCA), W3/13 (T cells), W3/25 (T helper), OX8 (T cytotoxic/suppressor), OX33 (B cells) and OX42 (microglia) using a modification of the ABC Vectastain procedure (Whelan et al., 1986). Briefly, sections were fixed in absolute methanol (-20°C for 2 min) and incubated in succession with 2% normal goat serum (30 min), diluted primary antibody (4°C , overnight), biotinylated horse anti-mouse IgG (pre-incubated for 30 min with 2% normal rat serum to reduce background staining) (30 min) and ABC complex (1 h). The primary antibodies were diluted 1/10 except for OX18 which was diluted 1/3. Specific binding was visualized with a solution containing 0.05% diaminobenzidine tetrahydrochloride, 0.001% hydrogen peroxide, and 0.01 M imidazole for 10 min. P3/X63 culture supernatant was used as a negative control. For GFAP staining, the sections were serially incubated with 2% normal goat serum, rabbit anti-cow GFAP antibody (1:10,000) and biotinylated goat anti-rabbit IgG. The remainder of the procedure was unchanged from the one outlined above. Normal rabbit serum was used as a negative control.

Irradiation of tumor-free brain. The posterior

half of the brains of 12 anesthetized rats was irradiated with a single dose of 1200 cGy using a GE Maximar XRay generator. This dose was biologically equivalent to the high doses of fractionated radiation used clinically in the treatment of patients with malignant gliomas (Ellis, 1971; Kramer et al., 1977; Henderson et al., 1981). Lead foil blocks shielded the anterior half of the brain, which acted as an internal control. Two unirradiated rats served as additional controls. The animals were sacrificed on days 0 (immediately after irradiation), 1, 2 and 5 and weeks 1, 2, 3, 4, 5, 7, 10 and 16. $6\ \mu\text{m}$ coronal frozen sections of the brains were obtained through the irradiated parietal lobes and the shielded frontal lobes and examined for histologic changes (hematoxylin and eosin; H&E) and demyelination (Luxol Fast Blue), and immunocytochemically. Sections from the corresponding areas of the brains of the unirradiated rats served as additional controls. Normal lymph nodes and brains from two rats that had 20,000 units of recombinant γ -interferon (IFN- γ) (Biogen Biologicals) injected into the parietal lobes 3 days prior to being sacrificed served as positive controls.

Irradiation of tumor-bearing animals. The 9L gliosarcoma cell line was originally derived from tumors induced in CDF rats by weekly intravenous injections of *N*-nitrosomethylurea (Schmiddek et al., 1971). 2×10^4 9L cells were stereotactically implanted into the right caudate nucleus of CDF rats using a modification of the method of Kobayashi (Kobayashi et al., 1980). On day 12 after implantation half the animals were anesthetized and the whole brain irradiated with a single dose of 1200 cGy. 1–2 irradiated and 1–2 non-irradiated rats were then sacrificed on days 0, 1, 2, 3, 5, 7, 10, 14 and 21. Although an attempt was made to match irradiated with non-irradiated controls as closely as possible, none of the non-irradiated tumor-bearing animals survived beyond day 14 (26 days after implantation). Coronal frozen sections were obtained through the center of the tumors and assayed immunocytochemically. With each antibody, the percentages of positively staining cells/total number of all cells from six random high-powered fields within the tumor (minimum of 900 cells) were obtained and the average determined (Whelan et al., 1985).

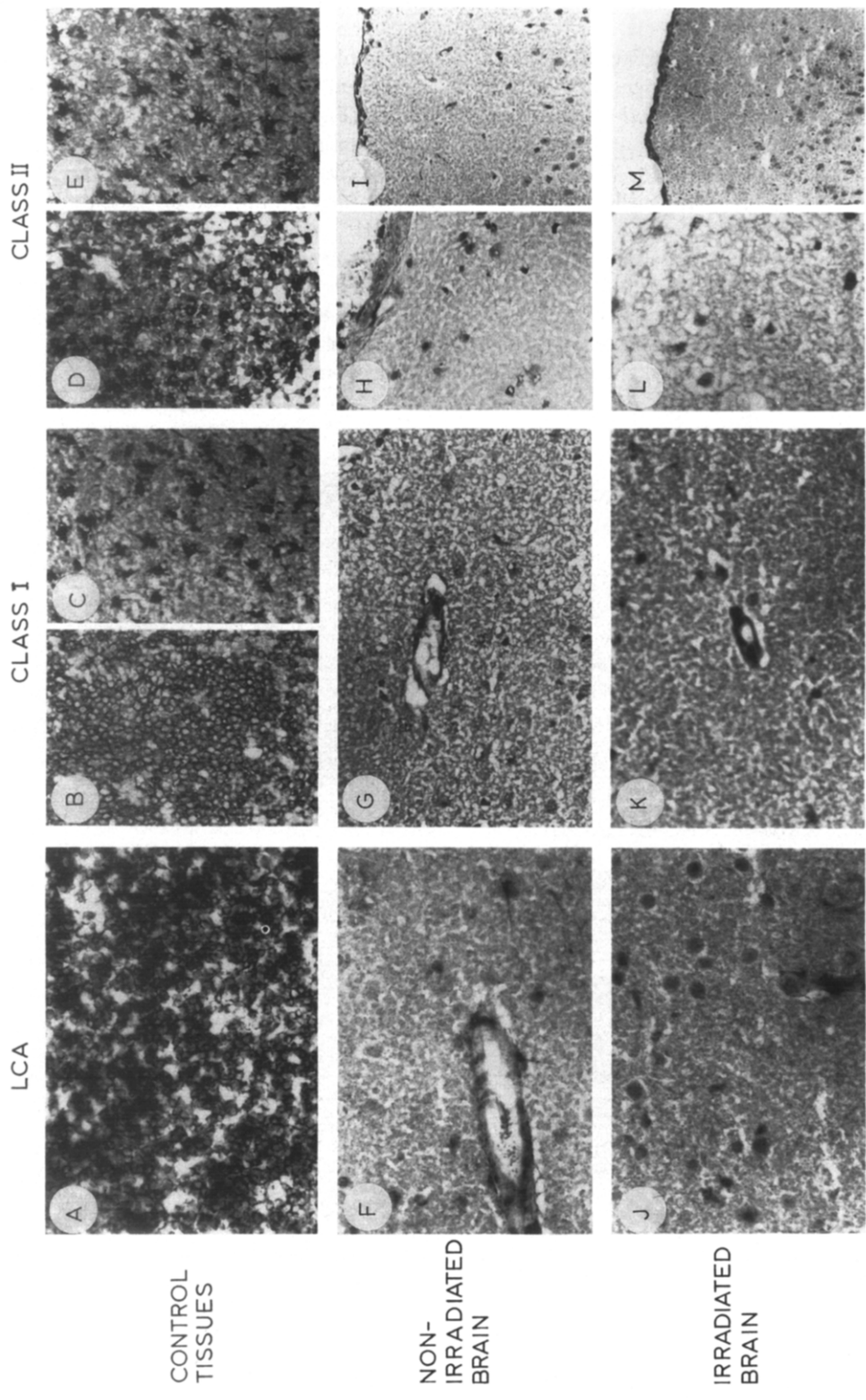


Fig. 1. The effect of irradiation on leucocytic infiltration and MHC expression in the normal rat brain. Positive controls: Lymph nodes stained with OX1 (LCA) (A), OX18 (class I MHC) (B) and OX6 (class II MHC) (D), show many positive cells. (C) shows class I-positive cells and (E) shows class II-positive cells in rat brain injected with IFN- γ . Experimental tissues: Sections through the parietal lobes of non-irradiated brain stained with OX1 (F), OX18 (G) and OX6 (H, I) show the absence of positive cells except for slight staining of a blood vessel wall in (G). Sections through the parietal lobes of irradiated brain stained with OX1 (J), OX18 (K) and OX6 (L, M) show the absence of positive cells except in the wall of a blood vessel in (K). All pictures photographed at 400 \times except for I and M which were photographed at 200 \times .

Results

In the normal rat brain, irradiation did not produce significant histologic changes, demyelination or gliosis within the time period studied. The monoclonal antibodies to class I and II MHC antigens produced dense staining of the lymph node controls, and of dendritic cells in control brains that had been treated with IFN- γ . No differences were detected in the staining patterns in irradiated brain areas compared to unirradiated areas or normal brains: class I was restricted to blood vessel walls, and class II to occasional cells associated with the leptomeninges, choroid plexus and blood vessels, and rare dendritic cells. The

antibody to LCA (OX1) produced strong staining in lymphoid controls, but stained only occasional inflammatory cells in the leptomeninges in both irradiated and unirradiated areas and control brains (Fig. 1).

In unirradiated tumor-bearing animals, no strong class I activity was seen in the tumor cells or the surrounding neural cells. In contrast, many class II⁺ cells were seen, especially at the periphery of the tumors. The number of class II⁺ cells increased with time after tumor implantation, reaching 40% of the cells within selected areas of the tumor mass. Most of the class II⁺ cells had a dendritic morphology suggestive of microglia. Rare cells (5%) had the morphologic characteristics of

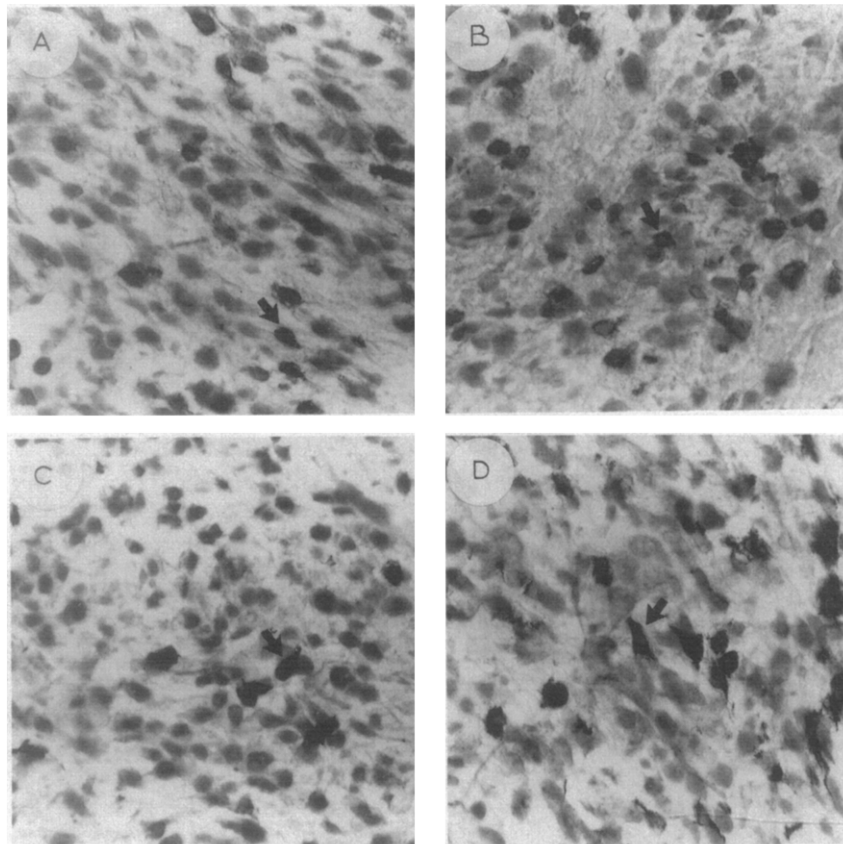


Fig. 2. The effect of irradiation on leucocytic infiltration and class II MHC expression in the 9L gliosarcoma brain tumor model. In both the irradiated and non-irradiated tumors there was variable staining of cells with OX1 and OX6 which was not seen in the tumors stained with P3/X63 control. Non-irradiated 9L tumor (A) and irradiated 9L tumor (B) show the presence of OX1 (LCA)-positive cells. Non-irradiated tumor (C) and irradiated tumor (D) show the presence of OX6 (class II)-positive cells. The sections were obtained through the center of the tumors irradiated 5 days previously and photographed at 400 \times . The negative cells in the background showed only H & E counterstain.

macrophages, lymphocytes, and occasionally astrocytes. Neither the numbers nor the proportions of cells were significantly changed following irradiation. These identifications were confirmed by serial sections stained with OX6 and antibody to GFAP and with OX6 and OX42. Two kinds of evidence suggest that the class II-positive cells were not tumor cells. In vitro, no class II was detected on 9L cells, even after incubation with IFN- γ , suggesting that the 9L cells may not have the potential to express class II MHC molecules. In work to be reported separately, 9L cells were transfected with the *Escherichia coli* β -galactosidase gene so that they could be identified histochemically (Lampson et al., 1989). Double-labelling studies using the modified cells did not reveal class II-positive tumor cells within the brain.

Many infiltrating leucocytes were also seen in the tumor-containing areas. As many as 40% of the cells within the tumors were LCA⁺. Analysis of lymphocyte subsets showed many T cells, including helper cells (up to 25% of all cells within the tumor mass), fewer cytotoxic/suppressor cells (up to 12%) and rare B cells (less than 5%). In control studies, 9L cells themselves did not cross-react with the antibodies to lymphocyte subsets.

Irradiation produced only slight necrosis. There was no significant effect on class I MHC expression in tumor-bearing rats. No significant change

was noted in class II MHC expression or lymphocytic infiltration on the first 2 days after irradiation. From day 3 onwards there was a slight increase in the numbers of class II-positive cells and lymphocytes in the irradiated tumors. However, these differences did not reach statistical significance in the Wilcoxon sign rank test (Figs. 2 and 3).

Discussion

Under normal circumstances there is little detectable MHC expression on neural cells or lymphocytic infiltration in the brain. However, both enhanced MHC expression and lymphocytic infiltration can occur in a variety of conditions, enabling neural cells to become subjected to cell-mediated immune reactions (Sobel et al., 1984; Wong et al., 1985; Lampson and Hickey, 1986; Suzumura et al., 1986; Lampson, 1987; Traugott, 1987; McGeer et al., 1988; Streit et al., 1989). In this study, we have found that a dose of irradiation biologically equivalent to that used in the treatment of malignant glioma did not produce major histologic changes, leucocytic infiltration, or induction of MHC antigens in the brain in the time covered. Surprisingly, our study also suggested that irradiation did not decrease class II

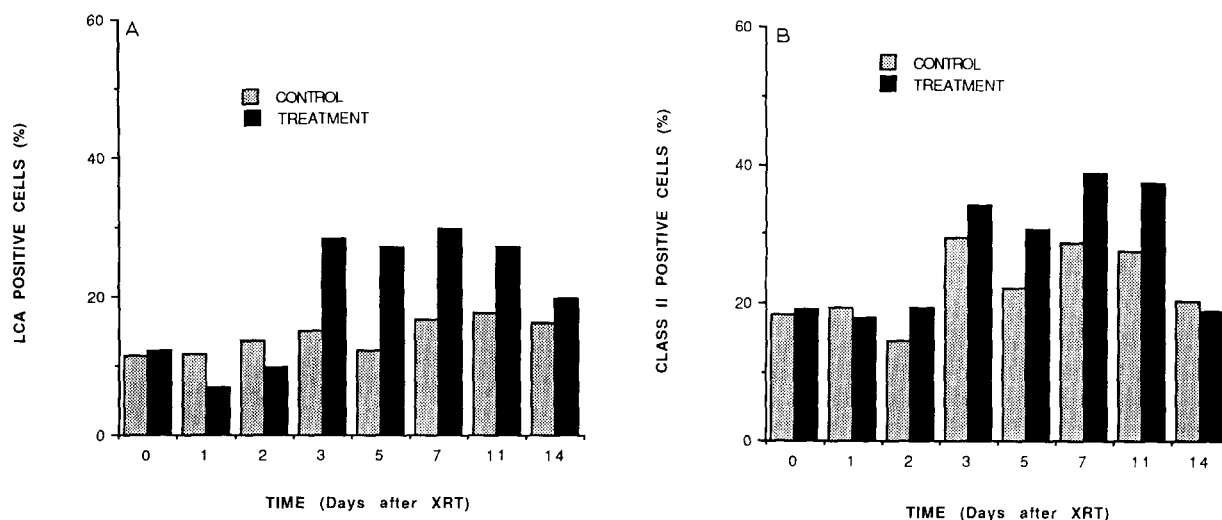


Fig. 3. Graph of percentage of antibody positive cells in control or irradiated 9L tumor at different times after irradiation (cell counts and statistics as in text). (a) LCA-positive cells; (b) class II-positive cells.

MHC expression or lymphocytic infiltration in the 9L gliosarcoma brain tumor model. These findings lay a foundation for future studies of immunomodulation in the brain when, as in the case of brain tumor patients, high doses of radiotherapy have been given previously.

Acknowledgements

This work was supported by grants from the National Multiple Sclerosis Society, the National Institutes of Health (NS 24878) and the Alex Coffin Fund for Brain Tumor Research. We gratefully acknowledge the help of Dr. Mustapha El-Azzouzi with the surgical techniques, the gift of the 9L gliosarcoma line and the support of Dr. Peter Black and the technical assistance of Victoria Roman, William Turner and Andrew Sloan.

References

- Ellis, F. (1971) Nominal standard dose and the rat. *Br. J. Radiol.* 44, 101–108.
- Ettinghausen, S.E., Lipford, E.H., Mule, J.J. and Rosenberg, S.A. (1985) Systemic administration of recombinant interleukin 2 stimulates *in vivo* lymphoid proliferation in tissues. *J. Immunol.* 135, 1488–1497.
- Hellstrom, K.E., Kant, J.A. and Tamerius, J.D. (1978) Regression and inhibition of sarcoma growth by interference with a radiosensitive T-cell population. *J. Exp. Med.* 148, 799–804.
- Henderson, S.D., Kimler, B.F. and Morantz, R.A. (1981) Radiation therapy of 9L rat brain tumors. *Int. J. Radiat. Oncol. Biol. Phys.* 7, 497–502.
- Jager, M.J., van der Pol, J.P., de Wolff-Rouendaal, D., de Jong, P.T.V.M. and Ruiter, D.J. (1988) Decreased expression of HLA class II antigens on human uveal melanoma cells after *in vivo* X-ray irradiation. *Am. J. Ophthalmol.* 105, 78–86.
- Kobayashi, N., Allen, N., Clendenon, N.R. and Ko, L.-W. (1980) An improved rat brain tumor model. *J. Neurosurg.* 53, 808–815.
- Kramer, S., Henderson, F., Zelen, M. and Schotz, W. (1977) Therapeutic trials in the management of metastatic brain tumors by different time/dose fraction schemes of radiation therapy. *Natl. Cancer Inst. Monogr.* 46, 213–221.
- Lampson, L.A. (1987) Molecular basis of the immune response to neural antigens. *Trends Neurosci.* 10, 211–216.
- Lampson, L.A. and Hickey, W.F. (1986) Monoclonal antibody analysis of MHC expression in human brain biopsies: tissue ranging from 'histologically normal' to that showing different levels of glial tumor involvement. *J. Immunol.* 136, 4054–4062.
- Lampson, L.A., Morris, J.M., Roman, V.A., Wen, P. and Sarid, J. (1989) Interactions between leucocytes and individual brain tumor cells in the rat brain. *J. Neurooncol.* (abstract) (in press).
- Markoe, A.M. and Saluk, P.H. (1987) Radiation immunobiology and immunomodulation. In: C.A. Perez and L.W. Brady (Eds.), *Principles and Practice of Radiation Oncology*, J.B. Lippincott, New York.
- McGeer, P.L., Itagaki, S., Boyes, B.E. and McGeer, E.G. (1988) Reactive microglia are positive for HLA-DR in the substantia nigra of Parkinson's and Alzheimer's disease brains. *Neurology* 38, 1285–1291.
- North, R.J. (1984) γ -Irradiation facilitates the expression of adoptive immunity against established tumors by eliminating suppressor T cells. *Cancer Immunol. Immunother.* 16, 175–181.
- Schmidek, H.H., Nielson, S.L., Schillel, A.L. and Messer, J. (1971) Morphological studies of rat brain tumors induced by *N*-nitrosomethylurea. *J. Neurosurg.* 34, 335–340.
- Sobel, R.A., Blanchette, B.W., Atul, K.B. and Colvin, R.B. (1984) The immunopathology of experimental allergic encephalomyelitis. II. Endothelial cell Ia increases prior to inflammatory infiltration. *J. Immunol.* 132, 2402–2407.
- Streit, W.J., Graeber, M.B. and Kreutzberg, G.W. (1989) Peripheral nerve lesion produces increased levels of MHC antigens in the CNS. *J. Neuroimmunol.* 21, 117–123.
- Suzumura, A., Lavi, E., Weiss, S.R. and Silberberg, D.H. (1986) Corona virus infection induces H-2 antigen expression in oligodendrocytes and astrocytes. *Science* 232, 991–993.
- Tilkin, A.F., Schaaf-Lafontaine, N., Van Acker, A. et al. (1981) Reduced tumor growth after low dose irradiation or immunization against blastic suppressor cells. *Proc. Natl. Acad. Sci. U.S.A.* 78, 1809–1812.
- Traugott, U. (1987) Multiple sclerosis: relevance of class I and class II MHC expressing cells to lesion development. *J. Neuroimmunol.* 16, 283–302.
- Whelan, J.P., Chatten, J. and Lampson, L.A. (1985) HLA class I and β_2 -microglobulin expression in frozen and formaldehyde-fixed paraffin sections of neuroblastoma tumors. *Cancer Res.* 45, 5976–5983.
- Whelan, J.P., Wysocki, C.J. and Lampson, L.A. (1986) Distribution of β_2 -microglobulin in olfactory epithelium: a proliferating neuroepithelium not protected by a blood-tissue barrier. *J. Immunol.* 137, 2567–2571.
- Wong, G.H., Bartlett, P.F., Clark-Lewis, I., McKimm-Breschkin, J.L. and Schrader, J.W. (1985) Interferon- γ induces the expression of H-2 and Ia antigens on brain cells. *J. Neuroimmunol.* 7, 225–278.