



Since January 2020 Elsevier has created a COVID-19 resource centre with free information in English and Mandarin on the novel coronavirus COVID-19. The COVID-19 resource centre is hosted on Elsevier Connect, the company's public news and information website.

Elsevier hereby grants permission to make all its COVID-19-related research that is available on the COVID-19 resource centre - including this research content - immediately available in PubMed Central and other publicly funded repositories, such as the WHO COVID database with rights for unrestricted research re-use and analyses in any form or by any means with acknowledgement of the original source. These permissions are granted for free by Elsevier for as long as the COVID-19 resource centre remains active.



Available online at [www.sciencedirect.com](http://www.sciencedirect.com)

ScienceDirect

journal homepage: [www.e-jmii.com](http://www.e-jmii.com)



## Correspondence

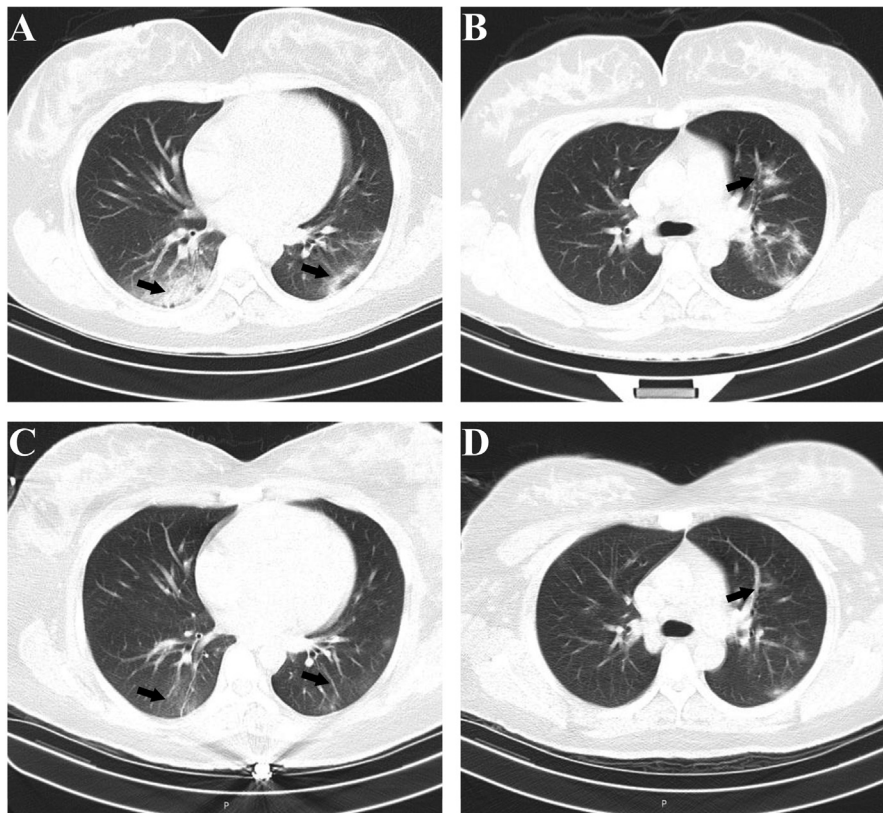
# A patient with SARS-CoV-2 infection during pregnancy in Qingdao, China



Dear Editor,

Since December 2019, an outbreak of infection with the novel coronavirus (SARS-CoV-2) has developed in Wuhan, China, and has spread through the country.<sup>1,2</sup> The first confirmed imported case of SARS-CoV-2 infection was reported on Jan 21 in Qingdao, Shandong.<sup>3</sup> Here, we present the only case with SARS-CoV-2 infection during pregnancy in Qingdao.

On Feb 4, a 31-year-old female at 30 weeks gestation presented with mild diarrhea (2–3 times a day) for one day. She was afebrile and breathing normally, and did not have cough or chest pain. On Jan 22, she has the contact history with Hubei province relatives, her mother and brother (confirmed SARS-CoV-2 infection on Feb 3 and 4, respectively). Based on this contact history with the Coronavirus Disease-19 (COVID-19) patients, SARS-CoV-2 real-time



**Figure 1.** CT images of patient's lungs with SARS-CoV-2 infection. **A and B.** Bilateral lower lungs and left upper lung show multifocal regions of patchy consolidation and ground glass opacities, mainly distribute on the subpleural regions and along the bronchovascular bundles (Feb 7). **C and D.** Major improvement of previous bilateral lung infiltrates with ground glass opacities (Feb 11).

<https://doi.org/10.1016/j.jmii.2020.03.004>

1684-1182/Copyright © 2020, Taiwan Society of Microbiology. Published by Elsevier Taiwan LLC. This is an open access article under the CC BY-NC-ND license (<http://creativecommons.org/licenses/by-nc-nd/4.0/>).

reverse-transcription polymerase chain reaction (RT-PCR) tests were performed on Feb 5. Nasopharyngeal swabs and sputum were positive for SARS-CoV-2 with ORF1ab gene and E (Centers for Disease Control, Qingdao). On Feb 7, axial chest CT images showed multiple regions of patchy consolidation and ground glass opacities with indistinct border in the bilateral lower lungs and left upper lung. The lesions were distributed along the bronchial bundles or within the subpleural lung regions (Fig. 1 A and B). A little amount of pleural fluid was found on left chest. Lymphadenopathy wasn't found. Combined PCR and CT, she was diagnosed as pregnancy with COVID-19.

On Day 2 of hospitalization, the patient received supportive therapies. Aerosolized interferon inhalation 5,000,000 IU bid and lopinavir and ritonavir 2 tablets bid were added from Feb 7. On Feb 11, CT showed a significant resolution of the initial lung abnormalities while the patient was receiving therapy (Fig. 1 C and D). On Feb 13, two-repeated nasopharyngeal swabs were negative on RT-PCR for SARS-CoV-2. On Feb 14, her sputum by RT-PCR for SARS-CoV-2 was positive. From Feb 16 to Feb 19, her nasopharyngeal swabs and sputum were all negative every 24 h. She made a recovery and discharged on Feb 20. The fetus developed normally and wasn't birth during hospitalization. We will follow up the labor and the outcome of the fetus.

From the recently published literature, pregnant women with COVID-19 showed a similar pattern of clinical characteristics to non-pregnant adult patients, including a fever and cough, less diarrhea and shortness of breath.<sup>4</sup> The symptom in our case is merely diarrhea, which shouldn't be ignored in the clinical management.

From Jan 23, she underwent self-isolation in home. Her bother and mother were diagnosed as SARS-CoV-2 infection

on Feb 3 and Feb 4, respectively. This suggests incubation period of SARS-CoV-2 can transmission and transmission shortly.

## References

1. Zhu N, Zhang DY, Wang WL, Li XW, Yang B, Song JD, et al. A novel coronavirus from patients with pneumonia in China. *N Engl J Med* 2020;**382**:727–33.
2. WHO. *Novel coronavirus (2019-nCoV): situation report-1*. 2019. <https://www.who.int/docs/default-source/coronaviruse/situation-reports/20200121-sitrep-1-2019-ncov.pdf>. [Accessed 21 January 2020].
3. Qingdao Municipal Health Commission. *The first confirmed imported case of SARS-CoV-2 infection in Qingdao*. 2020. <http://wsjsw.qingdao.gov.cn/n28356065/n32563060/n32563061/200121221134468808.html>. [Accessed 21 January 2020].
4. Chen HJ, Guo JJ, Wang C, Luo F, Yu XC, Zhang W, et al. Clinical characteristics and intrauterine vertical transmission potential of COVID-19 infection in nine pregnant women: a retrospective review of medical records. *Lancet* 2020;**395**:809–15.

Rong Wen\*

Yue Sun

Quan-Sheng Xing

Qingdao Women and Children's Hospital, No.7 Tongfu Road, Shibei, Qingdao, 266034, China

\*Corresponding author. Fax: +53268661310.

E-mail addresses: [wenxueqian\\_1111@163.com](mailto:wenxueqian_1111@163.com) (R. Wen), [101799@qdfc.com](mailto:101799@qdfc.com) (Y. Sun), [xingquansheng@qdfc.com](mailto:xingquansheng@qdfc.com) (Q.-S. Xing)

7 March 2020

Available online 10 March 2020