



Since January 2020 Elsevier has created a COVID-19 resource centre with free information in English and Mandarin on the novel coronavirus COVID-19. The COVID-19 resource centre is hosted on Elsevier Connect, the company's public news and information website.

Elsevier hereby grants permission to make all its COVID-19-related research that is available on the COVID-19 resource centre - including this research content - immediately available in PubMed Central and other publicly funded repositories, such as the WHO COVID database with rights for unrestricted research re-use and analyses in any form or by any means with acknowledgement of the original source. These permissions are granted for free by Elsevier for as long as the COVID-19 resource centre remains active.

Feline Epilepsy

Karen L. Kline

The diagnosis and management of seizures in the cat require an understanding of the more common diseases that predispose to feline epilepsy. Feline seizures may occur secondary to intracranial or extracranial disease. Intracranial causes include inflammatory, neoplastic, vascular, and traumatic disorders. Extracranial causes include various metabolic and toxic insults. Previous brain insults that are no longer active may leave "seizure foci." Idiopathic epilepsy is uncommon in the cat relative to the dog but should be considered if no cause can be found. Regardless of the etiology, ictal events in cats can manifest themselves in multiple forms and levels of severity. Therapy should be directed at controlling seizure frequency and treating the underlying cause. An aggressive diagnostic and therapeutic approach to feline epilepsy may improve prognosis and lead to a favorable outcome. Copyright © 1998 by W.B. Saunders Company

Knowledge of clinical signs, etiologies, and treatment strategies of seizures in the cat is critical to successful patient management. Clinical recognition of feline epilepsy may not be as straightforward as it is in the canine. Similarly, etiological considerations in the cat with seizures differ from those in the dog. This report discusses the diagnosis and treatment of seizures in the cat. As feline epilepsy is often secondary to an underlying disease, therapeutic management of the primary disorder will be emphasized.

Description of the Cat With Seizures (Clinical Classification)

Feline seizures, regardless of cause, can manifest themselves in a variety of ways. Seizures in the cat tend to be much more variable in their presentation than those in the dog. Consequently, an ictal event may not be noticed as readily by owners resulting in a delay in diagnosis and treatment.

The aura or pre-ictus in the feline can be comprised of subtle changes in behavior that include aggressiveness, pacing, restlessness, crying, hiding, unusual affection, pupil dilation, salivation, frantic running, hissing, growling, and acting fearful. This phase can last anywhere from seconds to days; but the usual duration is several minutes.¹⁻⁷ The ictus or actual seizure event usually lasts from seconds to minutes. During this phase, the cat may exhibit a number of abnormal behavioral patterns depending on whether the seizure is partial or generalized. With generalized, tonic-clonic or grand mal seizures, there is loss of consciousness, recumbency, and tonic-clonic motor

activity. The major motor activity consists of generalized tonic movements of the limbs in extension with purposeless limb movement and paddling, almost as if they were running in place. Opisthotonos and claw extension as well as mouth-chomping and pupillary dilation may occur. At times, tonic flexion (emprostotonus) is observed.¹ These movements can be followed by moderate to severe muscle twitching (clonic phase). During clonic seizures, the cat may or may not lose consciousness. During this activity, the cat may jump into the air violently as if thrown and may be quite aggressive and agitated. Autonomic release (urination and defecation) usually accompanies the motor activity as well as facial twitching, salivation, kicking, piloerection and chewing.¹ The post-ictal period is similar to that described in the canine.

Simple partial seizures are characterized by near normal or normal mentation and the appearance of unilateral motor signs involving a part of or all of the body. Cats with focal seizures will twitch the eyelids, whiskers and/or ears either in combination or separately. Head shaking may occur as well as jerking of the body. They may salivate, urinate and their pupils may transiently dilate. Simultaneously, they may vocalize continuously and they may experience a temperature increase caused by hyperthermia. Hyperthermia is commonly experienced in focal seizure patients because of continuous seizure activity that may go unnoticed for minutes to hours.⁵ In cats, focal, continuous seizures occur more often as a presentation of status epilepticus than in canines. Cats with complex partial seizures or psychomotor seizures exhibit an altered state of consciousness with stereotypical behavioral or motor responses.^{2,3} These activities can include turning of the head to one side, chewing motions, transient staggering, ventral flexion of the head often initiated by a short, piteous cry, intermittent episodes of aggression or fright, raising of a single limb (repetitive movements), tail piloerection, transient periods of incoordination, uncontrollable frantic running, or bizarre aimless movements. Many cats will be described by owners as acting "possessed," in a trance or as if they are hallucinating. Compulsive behaviors such as circling, biting and self-chewing can be seen.^{1,3,7} Partial complex seizures may be most common form of epilepsy in the cat. Both complex partial and simple partial seizures can evolve into the "classic" generalized seizure.

Etiological Classification

Seizures in cats may be due to a variety of causes (Table 1). Structural causes of feline seizures can represent any process that disrupts or changes the normal character of the brain tissue or vasculature, such as neoplasia, inflammation, vascular lesions and trauma. Extracranial causes of feline seizures disrupt normal brain function and include metabolic disorders such as hepatic encephalopathy, hyperthyroidism, hypoglycemia, uremia, and toxins. Idiopathic epilepsy accounts for a

From Iowa State University, College of Veterinary Medicine, Ames, IA. Address reprint requests to Karen L. Kline, DVM, Diplomate ACVIM (Neurology); Assistant Professor, Iowa State University, College of Veterinary Medicine, Ames IA 50011-1250.

Copyright © 1998 by W.B. Saunders Company
1071-0949/98/1303-0004\$8.00/0

TABLE 1. Etiology of Feline Seizures

I. Intracranial
Neoplasia
Meningioma
Lymphoma
Glial Tumors
Pituitary adenoma/adenocarcinoma
Choroid plexus papilloma/carcinoma
Metastatic
Inflammatory/Infectious
Toxoplasmosis
Cryptococcosis
Cladosporium
Blastomycosis
FIP
FELV/FIV
Rabies
Other unknown viral causes
Traumatic
Degenerative/Congenital/Anomalous
Storage Diseases
Hydrocephalus
Vascular
Feline Ischemic Encephalopathy
Embolism from underlying cardiac disease
Hypertension
Polycythemia
Relative
Absolute—Primary vs Secondary
II. Extracranial
Metabolic
Hepatic Encephalopathy
Portosystemic shunt (PDS)
Cholangitis/Cholangiohepatitis
Lipidosis
Neoplasia
Cirrhosis
Renal Disease
Uremia
Hyperthyroidism
Hyperparathyroidism
Hypoglycemia
Insulin-secreting tumor (insulinoma)
Insulin overdose
Sepsis
Toxins
Lead
Organophosphates
Ethylene Glycol
Nutritional
Thiamine deficiency (Terminal Stages)

small percentage of cats with seizures. More commonly, an underlying cause is suspected but never proven antemortem. In this case, close inspection of the brain at postmortem may reveal a symptomatic cause.

Intracranial Causes of Seizures

Neoplasia. The most common central nervous system (CNS) neoplasm in the cat is the meningioma. Meningiomas in cats are characterized as being slow-growing, space-occupying masses that have a histopathologically benign character in most cases. This is dependent upon the location of the mass and its size. These tumors can occur singly or in multiple sites. Meningiomas will typically affect the older feline patient (>8 years); males are disproportionately affected over female.⁷⁻⁹ Clinical signs tend to vary according to location of the mass. The most common site affected is the forebrain, and because of this, one of the prime presenting complaints is seizures, either generalized or focal. Other forebrain signs include behavior changes, circling in the direction of the lesion, contralateral vision loss, contralateral partial cranial nerve deficits, mild

contralateral hemiparesis, contralateral conscious proprioceptive loss, and hemisensory loss. These signs usually occur insidiously and are gradually progressive in nature, sometimes over months. Owners may complain of abnormal sleep/wake patterns, poor elimination habits and abnormal vocalization; these signs will often times improve dramatically after one or more doses of corticosteroids. This response occurs secondary to the transient decrease in the tremendous peritumoral edema caused by these masses. Once the medication is discontinued, the aforementioned signs usually recur.

Cats with meningiomas are, in some instances, prone to either caudal transtentorial or foramen magnum brain herniation, which can arise suddenly and cause a rapid deterioration due to brainstem compression. Positional nystagmus was observed with transtentorial herniation in one report.⁹ Other signs of herniation include: anisocoria progressing to dilated, nonresponsive pupils, changes in mentation and levels of consciousness, and respiratory patterns, and changes in motor extensor tone.

Another neoplastic cause of feline seizures is primary and secondary CNS lymphoma (LSA). The signalment of cats with CNS lymphoma differs from that of meningioma, in that these cats tend to be young to middle-aged (between 7 and 10 years). There is no sex predilection.¹⁰ As with meningioma, LSA has a predilection for the forebrain, but also affects peripheral nerves. Presenting complaints range from seizures alone, to multiple contralateral cranial nerve deficits and long tract signs, depending on lesion location. In one study, out of 18 cats diagnosed with CNS lymphoma, 8 had focal cerebral signs and 3 had diffuse cerebral signs.¹⁰

Other intracranial tumors in the feline patient include glial tumors (astrocytomas, oligodendrogliomas), pituitary adenoma/adenocarcinomas, ependymomas, medulloblastoma and gangliocytoma. The most common metastatic tumors are lymphoma and mammary adenocarcinomas. These tumors can compress and infiltrate healthy brain tissue to cause vasogenic edema, obstructive hydrocephalus and, potentially, herniation.

Diagnosis of intracranial neoplasms in the feline can be aided by the use of cerebrospinal fluid (CSF) analysis, skull radiographs, magnetic resonance imaging (MRI), and computerized tomography (CT) (Fig 1). CSF analysis may be normal, have an increased total protein (>25 mg/dL) in the absence of any cells (albuminocytologic dissociation), contain malignant lymphocytes (as with CNS LSA), or have a mildly increased cell count if there is presence of tumoral necrosis.⁷⁻¹⁰ Care must be taken in performing a CSF tap on a cat with a suspected mass, because herniation may occur subsequent to CSF removal.

Survey radiographs may show tumoral mineralization or lysis or hyperostosis in the overlying skull if a meningioma is present. Some individuals advocate a modified occipital view, in which the x-ray beam is directed at the foramen magnum.⁹ EEG may also be done to help localize the location of the lesion and/or identify paroxysmal epileptiform discharges. If available, CT scan and/or MRI allow more definitive identification of forebrain lesions such as meningiomas and other neoplasms. MRI provides greater soft tissue and anatomic detail than CT and so is the preferred modality for imaging intracranial neoplasia. On both CT and MRI, most meningiomas are superficial (extraaxial), attached broadly to the meninges, and uniformly enhance with contrast. Glial tumors and LSA tend to be located within the brain (intraaxial) and may show a pattern

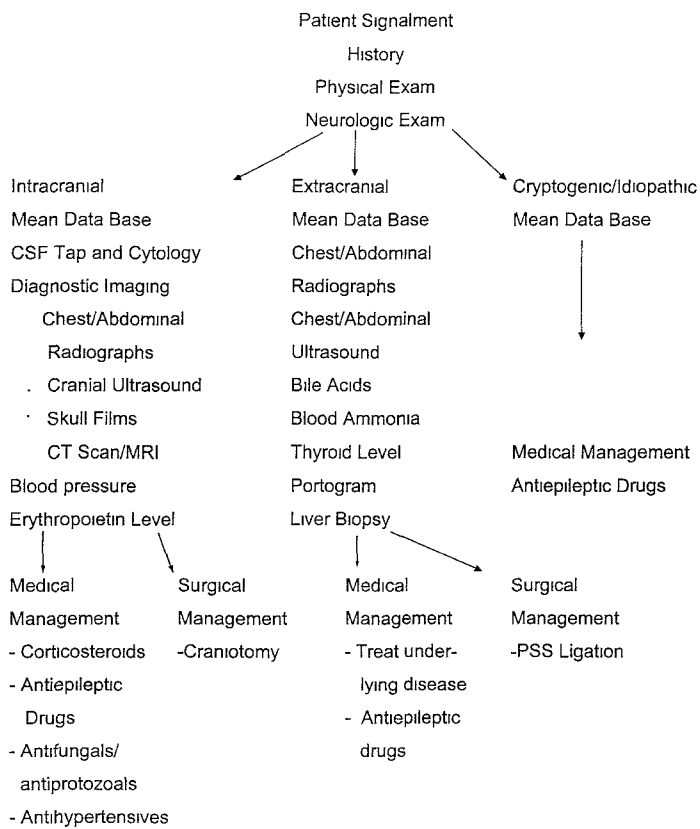


Fig 1. Approach to feline epilepsy.

of ring enhancement and/or poor enhancement with contrast, respectively. Vasogenic edema and obstructive hydrocephalus can also be observed with CT and MRI. Ideally, definitive diagnosis should be based upon biopsy and histopathology.

Treatment for intracranial neoplasms can be either surgical, involve chemotherapy, radiation therapy or a combination of the above.⁷⁻¹⁰ Surgical resection of feline meningiomas is the treatment of choice and, in many cases, may be curative, since regrowth is so slow. Improvement can often be observed within 24 hours to 1 week after surgery and may continue thereafter. Postoperative use of antiepileptic drugs is recommended if prior seizures have occurred.⁷

Tumors other than meningiomas are less amenable to surgical intervention. Chemotherapy and/or radiation therapy should be considered for these tumor types. In general, the glial tumors have a poor response to the above modes of treatment. The corticosteroids, prednisone and dexamethasone, may be of some benefit in the relief of peritumoral edema. These palliative effects may last for weeks to months with minimal side effects. Forebrain lymphoma has been treated with a combination of surgery, chemotherapy (either using corticosteroids alone or in combination with other chemotherapeutic agents such as vincristine, cyclophosphamide, L-asparaginase and doxorubicin) and radiation therapy with variable success.¹⁰

Prognosis for the feline seizure patient with a forebrain mass depends upon the type and location of the mass and the response to therapy. A cat with a surgically resectable meningioma has the potential to live a number of years after the procedure and may be cured, while the cat with a glial tumor or lymphoma has a less favorable prognosis for long term remission.

Inflammatory Diseases. Inflammatory diseases are a common cause of feline seizures and can affect the patient at any

age. Encephalitis and meningitis can be caused by a number of infectious agents including viruses, protozoal agents, and fungal agents. The most common inflammatory cause of seizures is described by some as a meningoencephalitis of unknown origin. It is currently believed that these cases are likely due to a nonFIP virus that has yet to be identified.¹¹⁻¹⁶

Inflammatory lesions of the CNS are often multifocal in distribution and cause multifocal signs. An example of a multifocal localization would be a cat who is seizing, but also has signs of hind limb weakness, proprioceptive loss and thoracolumbar pain. Affected cats may present with signs that come on rapidly or are slowly progressive, depending upon whether the forebrain, brain stem, spinal cord, or a combination thereof is involved. For these reasons, a thorough history and neurologic examination is critical in the work-up of a cat suspected of having an infectious disease (Fig 1). The patient should also be screened for concurrent diseases that predispose to infection (eg, feline leukemia virus, feline immunodeficiency virus).

Toxoplasmosis. Toxoplasmosis is caused by the protozoal organism, *Toxoplasma gondii*. Antibodies to this protozoan have been identified in 15% to 64% of cats in the U.S. with most seropositive cats being clinically normal.⁹ Cats can become infected by sporulated oocyst ingestion, or, more commonly, by ingestion of tissue cysts. The life cycle of *T. gondii* involves five stages and has been described; the tachyzoite or most rapidly dividing stage causes tissue destruction and is responsible for dissemination of infection. Immunosuppression due to concomitant steroid use or coexistent disease may lead to active infection.^{9,11,17} Lesions are most commonly observed in the liver, lung, GI tract, and brain. In the CNS, a nonsuppurative meningoencephalitis is seen histologically.

Fever is a common presenting complaint but other systemic signs such as dyspnea, polyuria, icterus, abdominal discomfort, peripheral lymphadenopathy, uveitis, and chorioretinitis may also be seen.¹⁷ Neurologic signs may be focal or multifocal and include seizures (either generalized or partial), paralysis, behavior changes, hypothermia, total or partial blindness, stupor, ataxia, head bobbing, atypical crying, and increased affectionate behavior. These signs may have a slowly progressive onset or may occur acutely.⁹ Diagnosis can, at times, be a challenge due to the various forms of the disease, and the lack of one definitive diagnostic test. High frequency, low amplitude waveforms on electroencephalography (EEG) are generally seen with focal inflammatory lesions.¹⁸ Several serologic tests are available for use in cats. Using the ELISA test, IgM titers > 1.256 or circulating antigens without antibodies suggest recent systemic infection, and a fourfold increase in IgG titer over 2 to 3 weeks indicates active infection. Other methods of detection have also been described.^{9,15} CSF analysis and titer measurements are preferred for the diagnosis of CNS infection. A nonspecific mononuclear pleocytosis and high total protein levels may be seen on CSF analysis. Organisms may, in rare instances, be seen in the CSF. Because *T. gondii* specific IgG has been observed in the CSF of clinically normal cats, IgM and IgG titers on the CSF compared to serum antibody levels are preferred. Direct demonstration of *T. gondii* organisms in biopsied tissue is most definitive.

Treatment for CNS toxoplasmosis is the same as for the systemic form of the disease. Clindamycin in the treatment of choice at a dose of 25 mg/kg orally daily divided every 8 or 12 hours, for up to 6 weeks. Pyrimethamine in combination with

trimethoprim sulfa has also been used. Prognosis for CNS toxoplasmosis depends upon the extent of neurologic involvement as well as the extent of other systemic effects. Long-term therapy (weeks to months) may be required for partial or complete resolution of clinical signs.^{9,17,19}

Feline Infectious Peritonitis. Feline Infectious Peritonitis (FIP) virus is a member of the corona-virus family. The virus induces an Arthus Type III Ag-Ab Immune Complex reaction that results in a pyogranulomatous inflammatory cell infiltrate in the meninges, choroid plexus, and superficial neuropil. These lesions have a predilection for the brain stem and spinal cord in young (less than 2 years of age) or geriatric cats. The pyogranulomatous infiltrate also affects other organs including the eye, liver, and kidney. Two-thirds of the cats with neurologic FIP have the "dry" or non-effusive form of the disease.^{9,11-13} Clinical signs are progressive and include waxing and waning fever, lethargy, icterus, and/or ocular signs (uveitis, hypopyon, retinal lesions). Neurological signs are primarily central vestibular in origin, but also can include seizures, multiple cranial nerve deficits, and para- or tetraparesis.^{12,13} Diagnostic tests may reveal a nonregenerative anemia, hyperproteinemia, hypergammaglobulinemia, and elevated liver enzymes, either alone or in combination. Serum FIP titers are inconclusive due to cross reactivity with other corona viruses such as feline enteric corona virus. The cisternal CSF tap is characterized by a pyogranulomatous pleocytosis (neutrophils, lymphocytes, macrophages) and a very high total protein in many cases.^{20,21} Polymerase Chain Reaction (PCR) on CSF fluid can also be performed, and is quite sensitive. In certain instances, no CSF fluid is retrieved from the cisternal tap; the term used for this is a "dry" or "dry well tap" and is believed to be due to the blockage of CSF flow from the lateral apertures to the subarachnoid space in cats that have severe inflammatory lesions.^{12,13} CT and/or MRI may reveal obstructive hydrocephalus which can occur secondary to the blockage of CSF flow previously described.¹² Those cats with hydrocephalus can exhibit the same neurologic signs as described previously, but may be even more dull or stuporous. All the described diagnostic tests can only lead to a presumptive diagnosis of FIP. A tissue biopsy demonstrating pyogranulomatous infiltrates is most suggestive of FIP but is often not obtainable antemortem.

Treatment for the neurologic form of FIP is palliative. Prednisone, dexamethasone, aspirin, and other antiinflammatories may help limit the degree of inflammation, but their effects are transient. The immunomodulatory properties of methotrexate and interferon may delay progression of signs temporarily. Prognosis for FIP is guarded to poor once neurologic signs are observed.

Cryptococcosis. The most common fungi that infect the feline CNS are *Cryptococcus neoformans*, *Blastomyces dermatitidis*, and *Cladosporium bantianum*. Of these, cryptococcosis is the most common.^{9,11} The nasal cavity is the most common site of entry for these organisms because they are soil inhabitants and are usually inhaled as spores. From the nasal cavity, hematogenous extension to other tissues, including the brain, can occur. Direct extension from the nasal cavity to brain can occur through the cribriform plate. The yeast form of the cryptococcal organisms has a characteristic "soap bubble" appearance and can induce a cystic necrosis of adjacent brain tissue. A key histopathologic feature of CNS cryptococcosis is the lack of a significant inflammatory response in the face of

large aggregates of organisms within the meninges and parenchyma.⁹

A common presenting complaint in the feline patient with cryptococcosis is an upper respiratory infection that is unresponsive to antibiotics. The neurologic signs usually occur relatively acutely and progress rapidly and include depression, seizures, circling, ataxia, and paresis. These signs may be accompanied by cutaneous lesions on the head and nose, peripheral lymphadenopathy and ocular lesions (retinal detachment, granulomas, and anterior uveitis).⁹ Aspirates of cutaneous nodules and lymph nodes may reveal the organisms. Serum titers to cryptococcal polysaccharide capsular antigen may be determined using either a complement fixation test or an antibody coated latex-particle agglutination test. Cryptococcal titers can be run on the CSF and are useful for an antemortem diagnosis.^{9,11,21} CSF analysis may reveal a moderate to marked pleocytosis to include eosinophilia and increased total protein. Cryptococcal organisms may occasionally be identified in the CSF. CT scans have identified focal granulomas and variable degrees of obstructive hydrocephalus in some cases.⁹ Itraconazole and Fluconazole have been described as the drugs of choice for treating Cryptococcosis.⁹ Fluconazole is more lipid soluble and has good blood brain barrier penetration. The dose for either drug is 5 mg/kg by mouth with food twice daily for a minimum of 2 to 3 months. Neurological signs may have a variable remission rate and some cats will need to be on lifetime therapy.

Vascular Disease

The feline patient with seizures secondary to vascular disease often presents with signs of a peracute to acute onset of lateralizing or diffuse forebrain deficits, variable degrees of tetra- or paraparesis, and ataxia that improve over a period of days to months. Some cats will improve and then reach a state in which residual neurologic deficits remain but are well-compensated for. CNS vascular diseases in cats can either have a primary or secondary origin.²²⁻²⁶

Feline Ischemic Encephalopathy (FIE)

FIE is a disorder of cerebral infarction characterized by an acute onset of lateralizing forebrain signs. Thrombosis or vasospasm of the middle cerebral artery is believed to lead to the cerebral ischemia observed. Cardiomyopathy-associated thrombosis, FIP-induced vasculitis, aberrant nematode migration, and cerebral cuterebrais have all been proposed as mechanisms of this vascular injury. Multiple causative factors may be involved.^{9,22,23} There is no sex or breed predilection for this syndrome and young adult cats are most commonly affected. Generalized or partial seizures, partial cranial nerve deficits, hemiparesis or plegia, and unilateral proprioceptive loss are common. In one investigator's experience, FIE was the second most common cause of seizures in cats.³ A small percentage of cats will progress to brain herniation or undergo further hemorrhage or infarction. Signs usually resolve completely over a period of several weeks, but seizures, unilateral cranial nerve signs and behavior changes can persist.⁹

The CSF is usually characterized by a mild elevation in total protein (<100 mg/dL) with minimal to no inflammation. Some cats will have a moderate mononuclear pleocytosis (10 to 200 cells/ μ L) and, occasionally, erythrophagocytosis is present.²⁴ A previous area of infarction may be visualized on MRI as an area

of mild to marked asymmetry of the cerebral hemispheres along with excessive CSF filling of the subarachnoid space in the parietotemporal areas; this reflects the compensatory pooling of CSF over atrophied gyri and widened sulci.

In the acute stages of this disease, methylprednisolone sodium succinate (SOLUMEDROL, Pharmacia and Upjohn, Kalamazoo, MI) at a dose of 30 mg/kg, IV, repeated at half the dose 4 hours later, may be beneficial in severely affected cats to help reduce initial brain edema.⁹ The use of steroids in human infarction is controversial. Anticoagulants may be used, but there is no data that indicate a benefit to their use. Antiepileptic drugs are used for seizure control.

Hypertension

With the development of more simple and accurate means of measuring blood pressure, hypertension is being recognized more frequently in the cat. In the feline, normal systolic blood pressure should be less than 160 mmHg. Hypertension occurs most frequently as a sequela to chronic renal disease, hyperthyroidism, or hypertrophic cardiomyopathy. A mean data base, radiography, ECG, cardiac echo and thyroid level are essential in delineating the cause of hypertension. Hypertensive cats most commonly present with retinopathy (retinal detachment/hemorrhage) and blindness, but vascular changes in the brain may lead to arteriosclerosis, focal hemorrhage, and a variety of neurological deficits.²⁵ Seizures, ataxia, nystagmus, sudden collapse, and paraparesis have been reported. MRI may demonstrate either focal or multifocal areas of hemorrhage; in some instances, the scan may be normal.²⁵ Therapy is directed at reversing the hypertension and treating the underlying cause. Some antihypertensive agents can cause cerebral vasodilation (eg, nitroglycerin) which can worsen the encephalopathy. Other antihypertensives include the Beta blockers, Atenolol, and Propranolol.

Polycythemia

The pathophysiology and pathogenesis of polycythemia is complex, and has been described in great detail.^{26,27} Polycythemia is defined as an increase in the total red blood cell number in circulation. Absolute polycythemia involves an absolute increase in RBC numbers and can be termed secondary (appropriate vs. inappropriate) versus primary (polycythemia vera). Secondary polycythemia can occur due to chronic hypoxic states (appropriate release of erythropoietin) or due to inappropriate production of erythropoietin secondary to hydronephrosis, renal carcinoma, or other neoplasia. These causes should be ruled out with appropriate tests. Polycythemia vera (primary erythrocytosis) is the most common of the polycythemias and is a chronic myeloproliferative disorder characterized by autonomous proliferation of erythroid precursors that mature into normal erythrocytes. The result is increased total RBC volume with normal to low blood erythropoietin concentration.^{9,26,27} Increased RBC volume increases blood volume and viscosity causing impaired blood flow, stasis, and tissue hypoxia. Neurologic signs include seizures, blindness, abnormal behavior, aggression, ataxia, pupillary dilation, and ptialism. Other clinical signs include PU/PD, lethargy, head bobbing, and muscle twitching. Most cats with clinical signs will have hematocrits greater than 63% without any identifiable causes of relative or secondary polycythemia.^{26,27} The drug of choice for treatment of primary polycythemia is

hydroxyurea (Roxane Laboratories, Columbus, OH) which inhibits DNA synthesis in the bone marrow: 500 mg orally every 7 days has been recommended, but 125 mg twice weekly for 2 weeks, then 500 mg once a week has been advocated to avoid adverse effects which include methemoglobinemia and Heinz body anemia. Intermittent phlebotomy may be necessary if the PCV remains elevated on drug therapy. Antiepileptic drugs should be instituted for seizure control. Prognosis is good for the feline patient if appropriate therapy is administered promptly and follow-up is done on a routine basis.

Head Trauma

Car accidents, falls, and other forms of blunt trauma can lead to head trauma in the cat. The clinical signs observed with trauma depend upon the location and severity of the lesion.^{3-5,9} Neurologic signs can include seizures (either immediate or delayed), diffuse or lateralizing forebrain signs, ataxia and hemi- or tetraparesis. Skull radiography, CT, or MRI aid in the assessment for skull fractures or contusions and help determine the need for surgical intervention.⁹ Treatment consists of immediate stabilization of shock, administration of steroids (though controversial), nursing support, and observation for signs of herniation. Mannitol and diuretics may be required if elevated intracranial pressure is present. Once a critical period of 36 to 48 hours has elapsed without progression of signs, the prognosis is good. Signs will usually improve, but residual deficits may persist. Owners should be informed of the potential need for antiepileptic drugs either at the time of the trauma or in the future.

Extracranial Causes

Hyperthyroidism. Hyperthyroidism is commonly diagnosed in cats more than 6 years of age. Hyperthyroidism may affect the CNS, the neuromuscular system, or both.²⁸ Normally, the brain maintains thyroxine (T4) and triiodothyronine (T3) concentrations in a narrow range. The pathogenesis of seizures may be linked to the ability of thyroid hormones to directly decrease the electrical threshold of cerebral tissue. Other pathogenic factors involve changes in cerebral oxygen and glucose consumption, as well as altered cerebral blood flow. Additionally, elevated thyroid hormone levels can alter a variety of neurotransmitters.^{25,28}

The clinical signs associated with thyrotoxicosis include weight loss, diarrhea, vomiting, polyuria/polydipsia and hyperactivity, although 10% of cats are described as having apathetic hyperthyroidism. Central nervous system signs include restlessness, aggression, irritability, hyperexcitability, aimless wandering, pacing and circling, abnormal sleep/wake patterns, generalized or partial motor seizures, and acute focal neurologic deficits (similar to cerebrovascular accidents). Lateralizing deficits are uncommon and are most likely secondary to hypertension-induced cerebrovascular accidents.^{25,28} Elevated thyroxine (T4) levels (greater than 4 mg/dL) and/or nuclear scintigraphy aid in the diagnosis of hyperthyroidism. Treatment of this disease through either antithyroid drugs, radioactive iodine (¹³¹I), or surgical thyroidectomy will, in the majority of cases, lead to clinical resolution of most of the CNS and neuromuscular signs observed, including seizures. Some patients, however, may need to be maintained on antiepileptic drugs for an extended period.

Hepatic Encephalopathy. Seizures associated with hepatic encephalopathy (HE) occur infrequently in the feline patient. Causes of hepatic encephalopathy in the cat include portosystemic shunts, severe lipidosis, and cholangitis/cholangiohepatitis (either primary or secondary to infectious diseases such as FIP).^{29,30} A myriad of metabolic imbalances and toxins act synergistically to produce the neurologic signs observed. Ammonia, mercaptans, indoles, and aromatic amino acids mainly act as false neurotransmitters and have a predominantly inhibitory action on brain function. More recently, increases in excitatory neurotransmitters such as glutamate and alterations of endogenous benzodiazepines have also been implicated.^{25,29,30} The role of these metabolic by-products in the generation of seizures is not understood.

Depending on the underlying cause, most cats with HE will be systemically ill. Neurologic signs are referable to a diffuse forebrain dysfunction and are commonly episodic. Aberrant or bizarre behavior, dementia, aggression, ataxia, head pressing, propulsive circling, blindness, mydriasis, ptyalism, and partial or generalized seizures may be observed. In the patient with a portosystemic shunt, the above signs may occur several hours after a meal and may be accompanied by mild to severe ptyalism.^{29,30} Routine complete blood counts, serum chemistry panels, pre and post-bile acids, resting ammonia levels, abdominal ultrasound, rectal portal scintigraphy and intraoperative portography and liver biopsy are useful diagnostic aids. Fasting bile acid values may be normal or elevated (normal 0-5 $\mu\text{moles/L}$). The 2-hour postprandial samples are usually significantly elevated. Resting blood ammonia levels may also be elevated (normal <15 $\mu\text{moles/L}$), indicating significant dysfunction of the normal urea cycle. It is important to note that liver enzymes may be normal to only slightly elevated in the patient with a portosystemic shunt.^{25,29,30} Low-protein diets, oral and parenteral antibiotics, and lactulose given orally or as a dilute enema are indicated for medical therapy of HE. Surgical correction is the treatment of choice for an extrahepatic shunt.³⁰

Uremia. Uremia is a relatively uncommon cause of feline seizures and is usually quite severe before inducing either partial or generalized seizures. As with HE, the uremic toxins can act as false neurotransmitters and alter the brain's seizure threshold. Neurological signs are similar to those for HE. Systemic signs of severe renal insufficiency often accompany the neurological signs. Diagnosis is based upon findings on bloodwork and urinalysis, abdominal radiographs, and ultrasound. Therapy is directed at treatment of the underlying renal dysfunction with fluids, antiemetics, gastric protectants and supportive care. Once neurologic signs are observed, the prognosis is grave.

Hypoglycemia. Hypoglycemia in the feline can be caused by insulin-overdose, liver failure, sepsis, and, on rare occasions, insulinoma. Insulin overdose is the most common cause of hypoglycemia in the cat. Seizures are the most common sequela of hypoglycemia, but other clinical signs can be seen, depending on the severity and duration of the neuroglycopenia.^{31,32} Initial signs of hypoglycemia reflect the body's response to the decreasing blood glucose. In an effort to stimulate gluconeogenesis, sympathetic tone increases and this results in adrenergic signs of tachycardia, dilated pupils, tremors, irritability, vocalization, and nervousness.²⁵ As the brain's glucose levels decrease, cortical signs of seizures, dullness, and confusion occur initially; signs can then progress

to hypothermia, bradycardia, miosis, vestibular ataxia, and decerebrate rigidity. Terminally, tendon reflexes are affected and death can occur. Routine diagnostic tests and historical information will usually differentiate sepsis, insulin overdose, or liver disease.^{31,32} Immediate treatment with intravenous dextrose with concurrent treatment of the underlying disease is indicated. Prolonged hypoglycemia may lead to a permanent ischemic seizure focus. Antiepileptic drugs may be required if seizures persist after correction of the hypoglycemia.

Toxicities

Organophosphates and Carbamates. The organophosphates and carbamates, common ingredients in flea shampoos and dips, are acetylcholinesterase inhibitors, and their mechanisms of action have been described. With the accumulation of acetylcholine at nerve endings, the somatic, parasympathetic and the CNS are over stimulated. Signs of nicotinic, muscarinic, and CNS dysfunction are observed.³³ Muscarinic and nicotinic signs include profuse salivation, vomiting, diarrhea, lacrimation, and muscle twitching and weakness. CNS signs, if they occur, include hyperactivity and occasional generalized seizures. The diagnosis and management of organophosphate and carbamate intoxication are described in the chapter on "Metabolic and Toxic Causes of Seizures" in this issue.

Lead Poisoning. Common sources of lead include lead-based paint, cages, batteries, grease, and fishing sinkers. Cats will usually ingest lead paint chips, either directly or when grooming, when owners are remodeling old homes. Chronic exposure to small amounts of lead may lead to toxicosis. The effect of lead on the nervous system occurs secondary to decreased blood supply due to damage to capillaries and small arterioles. Laminar cortical necrosis is a common histological finding. Peripheral nerves may undergo segmental demyelination. Depression, anorexia, vomiting, constipation, and abdominal pain are common presenting signs. CNS signs can include depression, hyperexcitability, excessive meowing, seizures (either partial or generalized), opisthotonos, paraparesis/plegia, muscle spasms, hyperesthesia, mydriasis or blindness. Diagnosis is based upon compatible clinical signs, history, blood work (basophilic stippling and anemia) and blood lead levels greater than 0.35 ppm. EEG changes in the form of high amplitude delta waves may be observed. Treatment includes removal of lead from the gastrointestinal tract to prevent further absorption and removal of lead from the blood and body tissues using chelation therapy. A chelating agent such as calcium EDTA (ethylenediamine tetra-acetate) is used to bind the lead in a nonionized soluble complex that is excreted in the urine. The dose is 100 mg calcium EDTA per kg (diluted as 10 mg of calcium EDTA per 5 mL of a 5% dextrose solution) daily for 2 to 5 days with the daily dose being divided into four equal portions and administered subcutaneously.³³ Antiepileptic drugs may need to be administered during and after the course of treatment. Prognosis depends upon length of exposure, severity of signs, and response to therapy.

Undetermined and Idiopathic Causes of Epilepsy

A significant percentage of cats have seizures of undetermined etiology. In many cases of feline epilepsy, an underlying cause of the seizures is suspected but never proven antemortem. These include previous posttraumatic, postinflammatory and

postischemic lesions that are quiescent (in the interictal period) and nonprogressive. Partial or generalized seizures are the only residual signs observed. This form of epilepsy is probably more common than true idiopathic epilepsy in the cat.³ Diagnostic imaging (especially CT or MRI) may be of benefit in determining the presence of a past skull fracture or brain lesion. Subclinical viral encephalitides may lead to a gliotic scar (seizure focus) in brain which may not even be visible with MRI. Small epileptic foci may also go undetected on histological examination.^{3,15} The incidence of idiopathic epilepsy in the feline had been reported to range from 0% in some studies to as high as 59% in others.^{1,3,4} In the study reporting a 0% incidence, all cats (of which there were 30) were assumed to have structural brain disease on the basis of number and frequency of seizures, occurrence of partial seizures, focal neurological deficits, and/or CSF and MRI abnormalities. In the study with a 59% seizure incidence, idiopathic epilepsy was a presumptive diagnosis because no clinical cause could be identified after extensive examination; these cats were between the ages of 6 months and 3 years. Of the 12 cats necropsied in this study, 7 were found to have no histological changes that would account for their seizures, although in 4 of the 7, selective neuronal necrosis and/or sclerosis was observed in Ammon's horn, a portion of the hippocampus. These changes were thought to be caused by the seizures alone. On the basis of these findings, a presumptive diagnosis of idiopathic epilepsy was made.¹ Follow-up exams, drug levels, survival times, and eventually necropsy in a large population of cats with undetermined causes of seizures should be carried out to estimate the frequency of true idiopathic epilepsy in the cat.

Long-term treatment with antiepileptic drugs is warranted in both groups of patients. Phenobarbital at a dose of 2 mg/kg two to three times daily is the drug of choice. Oral diazepam can be used but can be associated with paradoxical excitation, increased appetite, and, rarely, hepatic necrosis.^{4,34} See discussion of the use of phenobarbital and diazepam in the cat in the chapter "Antiepileptic Drugs" in this issue.

Summary

In the majority of cases, feline epilepsy is caused by either an intracranial or extracranial process. The incidence of idiopathic epilepsy in the cat is relatively low compared to the dog. Patient history, physical examination, neurological examination, and appropriate diagnostic tests can be used to determine etiology and treatment. Prognosis for the epileptic cat primarily depends upon the underlying disorder and whether it is amenable to therapy.

References

- Schwartz-Porsche D, Kaiser E: Feline Epilepsy. In Indrieri RJ, (ed). *Problems in Veterinary Medicine*. Vol 1. Philadelphia, PA, Lippincott, 1989, pp 628-649
- Oliver JE: Seizure Disorders and Narcolepsy. In Oliver and Hoerlin, (ed). *Veterinary Neurology*, Vol 1. Philadelphia, PA, WB Saunders, 1987, pp 285-302
- Parent J, Quesnel AD: Seizures in cats. *Vet Clin North Am (Small Animal Practice)* 26:811-825, 1996
- Fenner WR: Epilepsy. In: August JR, (ed). *Consultation in Feline Medicine*. Vol (2). pp 437-447, 1994
- Kay WJ: Epilepsy in Cats. *JAAHA* 11:77-82, 1975
- Fenner WR: Seizures and Head Trauma. *Vet Clin North Am (Small Anim Pract)* 11:31-48, 1981
- Gorden LE, Thacher C, Matthisen DT, et al: Results of Craniotomy for the Treatment of Cerebral Meningioma in 42 cases. *Veterinary Surg* 23:94-100, 1994
- Nafe LA: Meningiomas in Cats: A Retrospective Clinical Study of 36 Cases 174: *JAVMA* 11:124-1227, 1979
- Kornegay JN: Altered Mental Attitude, Seizures, Blindness, Circling, Compulsive Walking. *Forebrain Diseases and Multiple Neurologic Deficits*. *Problems in Vet Med* 3:391-449, 1991
- Noonan M, Kline KL, Meleo K: Lymphoma of the Central Nervous System: A Retrospective Study of 18 Cats. *The Compendium* 10:497-503, 1997
- Braund KG, Brewer BD, Mayhew IG: Inflammatory, Infectious, Immune, Parasitic and Vascular Diseases. In Oliver and Hoerlin, (ed). *Veterinary Neurology*, Vol 1 1987, pp 216-254
- Kline KL, Joseph RJ, Averill DA: Feline Infectious Peritonitis with Neurologic Involvement. *Clinical and Pathologic Findings in 24 Cats*. *JAAHA* 30:111-118, 1994
- Krum S, Johnson K, Wilson J: Hydrocephalus Associated with the Noneffusive Form of Feline Infectious Peritonitis. *JAVMA* 167:746-748, 1975
- Schultze AE, Cribb AE, Tvedten HW: Eosinophilic Meningoencephalitis in a Cat. *JAAHA* 22:623-627, 1986
- Quesnel AD, Parent JM, McDonnell W, et al: Diagnostic Evaluation of Cats with Seizure Disorders: 30 Cases (1991-1993). *JAVMA* 210:65-71, 1997
- Plummer SB, Wheeler SJ, Thrall DE, et al: Computed Tomography of Primary Inflammatory Brain Disorders in Dogs and Cats. *Vet Radiology and Ultrasound* 33:307-312, 1992
- Lindsay DS, Blagburn BL, Dubey JP: Feline Toxoplasmosis and the Importance of the *Toxoplasma gondii* oocyst. *The Compendium* 19:448-459, 1997
- Holliday TA: Clinical Aspects of Some Encephalopathies of Domestic Cats. *Vet Clin North Am (Small Anim Pract)* 1:367-378, 1971
- Rand JS, Parent J, Jacobs R, et al: Reference interval for feline cerebrospinal fluid. Cell count and cytologic features. *Am J Vet Res* 51:1044-1048, 1990
- Rand JS, Parent J, Jacobs R, et al: Reference interval for feline cerebrospinal fluid: Biochemical and serologic variables, IgG concentration and electrophoretic fraction. *Am J Vet Res* 51:1049-1054, 1990
- Rand JS, Parent J, Percy D, et al: Clinical, cerebrospinal fluid and histologic data from thirty-four cats with primary noninflammatory disease of the central nervous system. *Can Vet J* 35:174-181, 1994
- Zaki FA, Nafe LA: Ischaemia encephalopathy and focal granulomatous meningoencephalitis in the cat. *J Small Anim Pract* 21:429-438, 1980
- DeLahunta A: Upper Motor Neuron System. In DeLahunta A, (ed). *Veterinary Neuroanatomy and Clinical Neurology*. (Ed 2). Philadelphia, PA, Saunders, 1983, pp 144-145
- Rand JS, Parent J, Percy D, et al: Clinical, cerebrospinal fluid and histologic data from thirty-four cats with primary noninflammatory disease of the central nervous system. *Can Vet J* 35:103-110, 1994
- O'Brien D, Kline KL: Metabolic Encephalopathies. In JR August, (ed). *Consultations in Feline Internal Medicine*. Vol. 3. Philadelphia, PA, Saunders, 1997. pp 373-379
- Khanna C, Bienzle D: Polycythemia vera in a cat: bone marrow culture in erythropoietin-deficient medium. *JAAHA* 30:45-49, 1994
- Watson AD, Moore AS, Helfand SC: Primary erythrocytosis in the cat: Treatment with Hydroxyurea. *J Small Anim Pract* 35:320-325, 1994
- Joseph RJ, Peterson ME: Review and Comparison of Neuromuscular and Central Nervous System manifestations of hyperthyroidism in cats and humans. *Progress Vet Neurology* 3:114-119, 1992
- Berger B, Whiting PG, Breznock EM, et al: Congenital Feline Portosystemic Shunts. *JAVMA* 188:517-521, 1986
- Scavelli TD, Hornbuckle WE, Roth L, et al: Portosystemic Shunts in Cats: Seven Cases (1976-1984). *JAVMA* 189 317-325, 1986
- Howerton TL, Shell LG: Neurologic Manifestations of Altered Serum Glucose. *Progress Vet Neurology* 3:57-64, 1992
- Hawks D, Hawkins KL, Rosebury WS: Insulin-secreting Pancreatic (islet cell) carcinoma in a cat. *J Vet Int Med* 6:193-196, 1992
- Oswieiler GD, Carson TL, Buck WB, VanGelder GA: *Clinical and Diagnostic Veterinary Toxicology*, (ed 3), Dubuque, IA, Kendall/Hunt, 1985
- Quesnel AD, Parent JM, McDonnell W: Clinical Management and Outcome of Cats with Seizure Disorders: 30 cases (1991-1993). *JAVMA* 210:72-77, 1997