



Since January 2020 Elsevier has created a COVID-19 resource centre with free information in English and Mandarin on the novel coronavirus COVID-19. The COVID-19 resource centre is hosted on Elsevier Connect, the company's public news and information website.

Elsevier hereby grants permission to make all its COVID-19-related research that is available on the COVID-19 resource centre - including this research content - immediately available in PubMed Central and other publicly funded repositories, such as the WHO COVID database with rights for unrestricted research re-use and analyses in any form or by any means with acknowledgement of the original source. These permissions are granted for free by Elsevier for as long as the COVID-19 resource centre remains active.

JNS 04010

The pathogenesis of multiple sclerosis

Additional considerations

Charles M. Poser

Department of Neurology, Harvard Medical School and Neurological Unit, Beth Israel Hospital, Boston, MA, USA

Key words: Multiple sclerosis; Pathogenesis; Blood–brain barrier; Trauma; Disease progression; Multiple sclerosis trait

Summary

Multiple sclerosis (MS) is acquired as a systemic “trait” by individuals who are genetically susceptible. This condition does not involve the central nervous system (CNS) and is characterized by a state of hyperactive immunocompetent responsiveness. It develops as the result of an antigenic challenge by a viral protein, either from a viral infection or a vaccination. In order for MS to become a disease affecting the CNS, it is necessary for the blood–brain barrier’s (BBB) impermeability to be altered. This is now a fully recognized fact. As a result of this change, the MS lesion, which consists of edema and inflammation occurs. It may but need not lead to demyelination. Several mechanisms can cause this increased permeability of the BBB. The role of the immune system, and in particular of T lymphocytes in initiating and continuing the process of lesion formation remains extremely controversial. In fact, there are unanswered questions regarding the actual target of MS: is it the myelin sheath itself or its forming cell, the oligodendrocyte, or is it the BBB itself leading to bystander demyelination? The role of mild, concussional trauma to the CNS in producing the alteration of the BBB and therefore acting as a trigger or facilitator in the development or enlargement of MS lesions in the CNS, is based on considerable clinical, neuropathological and experimental evidence. Along with another viral infection, it must be one of the commonest causes of progression of MS, and quite often leads to the onset of the clinical manifestations of an hitherto asymptomatic condition.

Introduction

A number of steps in the pathogenetic development of multiple sclerosis are still unknown.

In two previous publications (Poser 1986, 1992a) regarding the pathogenesis of MS, I proposed two new concepts: first, that a multiple sclerosis “trait” existed as a systemic condition, characterized by a state of hyperactive immunocompetent responsiveness, and second, that an alteration of the blood–brain barrier (BBB) was an obligatory step in the formation of the MS lesion, which consisted of edema and inflammation that can but does not always lead to demyelination. I emphasized that this change in BBB permeability is nonspecific, results in a greater vulnerability, which is inherent in the MS trait, and could be increased by a number of factors including immune responses, trauma, electrical injury, and others. Several publications have since provided further support for the view that the BBB plays a crucial role in the pathogenesis of MS.

It is the purpose of this paper to review this new material and to examine the process which results in the disease becoming progressive in some patients even following a single event which has changed the protection afforded by the BBB. Therefore, I further propose that in some instances, a major disturbance of BBB impermeability may affect the further course of the illness. In so doing, I no longer support some opinions which I had expressed some years ago (Poser 1979) but which do not seem valid in view of the publication since then of an enormous amount of important new information.

Because much of this material has already appeared in print, it will not be repeated here; rather the reader is referred to the 1986 and 1992a articles.

The multiple sclerosis trait

The fact that a genetically determined factor plays an important role in the acquisition of MS has now been established on the basis of twin studies, epidemiological surveys, and studies of the histocompatibility system. These studies have been discussed in detail by Compston (1991a). The

Correspondence to: Charles M. Poser, MD, Neurological Unit, Harvard Medical School, Beth Israel Hospital, 330 Brookline Avenue, Boston, MA 02215, USA. Fax: (617) 735-5216.

nature and mode of transmission of this genetic susceptibility remain unknown, although the latter appears to be particularly strong among the descendants of populations that originated in Scandinavia and Northeastern Europe (Poser 1992a). The presence of the genetic susceptibility in a person will determine if she or he will develop the MS "trait", although not necessarily exhibit the clinical manifestations of MS. The problem is complicated by the fact that a significant number of persons who have MS lesions go through life without exhibiting any symptoms of the disease (Poser et al. 1992). It is more than likely that the MS trait does not affect all members of a family.

It is most important to realize that the factors that cause an individual to develop the MS "trait" are quite different from those that cause the person to have MS lesions in the central nervous system, symptomatic or not.

The nature of the MS "trait"

The MS "trait" is defined as a permanent state of hyperactive or intensified immunocompetent responsiveness or capability, which is triggered in the genetically susceptible individual by exposure to a non-specific antigen that is almost certainly of viral origin, either an acute viral infection or a vaccination. The possible importance of the latter seems to have been generally overlooked. Despite the fact that there are still some adherents to the theory of a persistent specific viral agent, the most recent ones being the corona virus (Murray et al. 1992) and a still unidentified retrovirus (Rudge 1991), the consistent failure to confirm the role of such a specific organism in the pathogenesis of MS had raised grave doubts about its existence.

The presence of the MS "trait" simply means that a systemic condition, which does not itself involve the nervous system, is created that makes the person a potential victim of MS, a disease of the central nervous system (CNS), provided a further event takes place. The classic examples of a trait are acute intermittent porphyria and glucose-6-phosphate dehydrogenase deficiency. Not all the components of this MS trait have been defined. One of them appears to be a very vigorous antibody response to a great variety of viral, and possibly other, antigens. This was originally demonstrated by Brody et al. (1971) and confirmed by several other authors (Panelius et al. 1973, Woyciechowska et al. 1985, Kinnunen et al. 1990). Haile et al. (1981) were able to demonstrate the presence of circulating immune complexes in the blood of unaffected siblings of MS patients. This would be another expression of the MS "trait". The lack of specificity noted in the elevated titers of antiviral antibodies in these studies may be a reflection of the person's previous immunological experience. For example, vaccination against many diseases is widespread in developed countries where, perhaps coincidentally or because of ethnic factors, the prevalence of MS is highest. The phe-

nomenon of molecular mimicry (Fujinami et al. 1983) may play a role in the acquisition of the MS "trait", as it may do also at a later stage of the development of the disease (see below). Noble et al. (1977) showed that the administration of swine influenza vaccine to normal volunteers in New Jersey in 1976 caused a rise in titers of other influenza vaccines. It is germane to point out as did Isaacson and Stone (1971) that all vaccines contain a very large number of antigens in addition to the specific killed or attenuated virus that is the presumably "active" ingredient.

Another probable component of the MS trait consists of the presence in the CSF of unaffected siblings, including non-concordant twins, of MS patients, of immunoglobulin G oligoclonal bands (OB) (Xu and McFarlin 1984; Duquette 1991). It is true that some, but as far as is known, not all of these persons had abnormalities on magnetic resonance imaging (MRI) interpreted as being MS lesions and that they also developed clinical signs and symptoms of the disease. Nevertheless, Lynch and Rose's (1991) reply to Duquette's letter is most interesting in that it actually hints at the existence of the MS trait: "Previous studies have indicated that many otherwise healthy siblings with family members affected with MS have abnormal studies associated with MS such as MRI abnormalities and CSF oligoclonal bands. These individuals may represent a population who carry an MS susceptibility factor but did not encounter sufficient environmental stimulus to precipitate MS, or perhaps they carry one or two or three genetic susceptibility factors present in these families as suggested by Duquette". It is beyond the scope of this paper to discuss the possible significance of CSF OB in MS, since the topic has been explored by many authors, who have all come to the conclusion that it remains completely mysterious and may play no role whatsoever in the pathogenesis of the disease. However, CSF OB remain present for the entire life of the patient, regardless of the clinical state of the disease; the nature of the antibodies contained in them remains unknown, and, most intriguing, no one, including experts such as Link, Lowenthal, and Traugott (personal communications) seems to know if the cells that produce the IgG (presumably B-lymphocytes and plasma cells) are continuously introduced from peripheral blood or if they proliferate in situ within the CNS. Lymphocyte secretion of IgG may be an expression of the increased but non-specific immunocompetent responsiveness in the MS "trait".

Another aspect of this exaggerated immune response is an inflammatory, primarily lymphocytic, infiltration of small blood vessels, primarily venules and capillaries, that do not lead to the development of white matter alterations. This was clearly demonstrated by Adams et al. (1985) and further illustrated by Gay and Esiri (1991) who showed that these infiltrates found in normal white matter of MS patients which are both perivascular in nature and involve the blood vessel wall itself, produce a very minor alteration of the

BBB which cannot be demonstrated by gadolinium enhancement of magnetic resonance imaging (MRI). These vascular changes may be the pathway for B-lymphocytes to penetrate into the CNS where they produce OB.

Genetic susceptibility and host specificity

Many investigators have used experimental allergic encephalomyelitis (EAE) as the animal model for MS. There are similarities between the two conditions that have been well summarized by Allen (1991): "although there is evidence of the possible importance of immune-competent and antigen-presenting cells in demyelination in MS, there can be no firm conclusion that the disease is autoimmune. It is premature to deduce from the experimental evidence available that we have an exact or even a good model of MS". On the other hand, there is little question, as was pointed out by Lumsden (1972) that, up to a point, EAE (as well as its natural equivalents, post-infectious and post-vaccinal encephalomyelitis) have a similar pathogenetic sequence. It is quite clear that the speculations and conclusions found in many publications are extrapolations of EAE results to MS. Thus in their extensive review of the putative immunological basis of MS, Lassmann et al. (1991) suggest that "the minimal requirement to start brain inflammation is the presence of activated circulating T cells directed against a brain antigen and of antigen presenting cells in meninges and perivascular spaces. Other local and systemic immunological factors may profoundly lower the threshold for the induction of brain inflammation. They include antigen recognition on cells in brain parenchyma (microglia, astrocytes), local upregulation of MHC antigens and possibly adhesion molecules (by cytokines or as a *consequence of brain injury*) and the presence of additional humoral immune responses against brain antigens (autoantibodies). Focal production of cytokines by inflammatory cells as well as by resident cells of the brain plays an important role in determining the activity of the inflammatory process and in inducing effector cells and inflammatory mediators responsible for tissue destruction. Whereas in pure T-cell mediated EAE these activated effector mechanisms have low selectivity and mainly induce a 'bystander' damage of CNS tissue, additional presence of autoantibodies may focus the immune reaction to specific targets, thus inducing very selective tissue destruction". There is no convincing evidence at this time that this proposed mechanism is operative in MS.

It is important to recognize in both diseases that the response of the individual to the antigenic stimulus is host-dependent and not antigen-dependent. In other words, given the same infection or vaccine, the vast majority of persons will have no neurological response at all, some will develop typical encephalomyelitis, but others will develop MS.

Two dramatic reports illustrate the specificity of the host

response: of the 45 persons who died as a result of complications of anti-rabies vaccination in Japan in the 1950s, 36 had the neuropathological characteristic changes of post-vaccinal disseminated encephalomyelitis but 9 had lesions indistinguishable from those of MS (Uchimura and Shiraki 1957). Perhaps even more striking is the report that out of 11 persons given anti-rabies vaccine who were examined at autopsy in Colombia by Toro et al. (1977), 10 developed acute post-vaccinal disseminated encephalomyelitis, but one had lesions characteristic of MS.

The role of the immune system in the pathogenesis of MS

With the exception of the clearly demonstrable changes which are manifestations of the MS trait, the changes found in the immune system of MS patients are complex and numerous but most importantly, non-specific (Lisak 1986). It is unfortunate that many studies of immune changes are based upon extrapolations from EAE to MS, and often it is difficult if not impossible to tell which condition they refer to. For many years, researchers have made thousands of studies of the role of T-lymphocytes in the disease. These can be summarized as follows: they are found in and near the MS lesion; activated T-cells are able to penetrate through the presumably intact BBB; they do not play a direct role in the destruction of myelin (Compston 1991b), but there has been much speculation that they might secrete cytokines, which play such a role, but this has not yet been demonstrated. They do not attack oligodendrocytes. Raine (1991) states his strong belief in the importance of the T cell in MS pathogenesis in the title of his article: "MS: a pivotal role for the T cell in lesion development". There has also been general agreement that while myelin basic protein (MBP) or one of its component fragments is the antigen responsible for myelinoclasia in EAE, it does not play the same role in MS; what is most puzzling, however, is the fact, reported by several investigators, that peripheral blood T-cells in MS patients (but also in some healthy controls) are responsive to a host of myelin components such as myelin basic protein (MBP), myelin-oligodendrocyte glycoprotein (MOG), myelin proteolipid protein (PLP) and GM-1 ganglioside (Arnon et al. 1980; Johnson et al. 1986; Olsson et al. 1990; Zamvil and Steinman 1990; Martino et al. 1991; Sun et al. 1991; Chou et al. 1992).

Zamvil and Steinman (1990) stated in summary, "in MS we do not know if these myelin reactive T-cells are causative or if they occur secondarily". While one cannot be certain about the significance of T cell activation by all the components of myelin mentioned above, the role of MBP is certainly in doubt: Wekerle et al. (1986) injected very high numbers of activated MBP reactive T-lymphocytes into the CSF without inducing any tissue damage in the CNS parenchyma.

Jingzu et al. (1992) recently reported that the frequency

of MPB-reactive T-cells in the peripheral blood of normal subjects was essentially the same as that in MS patients and concluded that the relevance of T-cell responses to MBP to the pathogenesis of MS remains controversial. It is not yet known if the same statement applies to PLP, MOG or GM-1 ganglioside. Two possible explanations may be offered for the existence of the activation of T-lymphocytes by myelin components. The first one is that it is a manifestation of the phenomenon of molecular mimicry. Alvord (1985) and Jahnke et al. (1985) have demonstrated that several viruses share protein amino acid sequences with MBP (Table 1) and therefore a person who has the MS "trait" (but also normals) may respond to those antigens. This suggestion was supported by Chou et al. (1992). Another example of possibly relevant molecular mimicry is the report of protein sequence similarity between decapeptides from rubella and measles virus and human proteolipid protein (Atkins et al. 1990). Note that the same proteins are also contained in rubella and measles vaccines administered routinely to children in practically all the developed countries. It is probable although not yet shown that antigenic similarities may also exist between viral proteins and other myelin components. A second possibility, is that the obligatory opening of the BBB and the destruction of myelin, releases into the peripheral circulation breakdown products of myelin which then start T-cell activation. The origin of the substances from destroyed myelin was first mentioned by Oger et al. (1988) and also by Zamvil and Steinman (1990). Olsson (1990) pointed out that they had observed autoreactive T-cells as a result of BBB breakdown in acute cerebrovascular disease. However, in regard to MBP, the report by Jingzu et al. (1992) would contradict this. If indeed the T-cell plays a role in MS pathogenesis, as is firmly believed by many investigators, then the CNS-to-blood traffic through the opened BBB would provide a constant source of antigenically activating substances for T-cells.

A number of investigators have expressed doubt about the role played by immunological reactions in the pathogenesis of demyelination including Behan (personal communication), Wisniewski and Bloom (1985), Oger et al. (1988), Gay and Esiri (1991), but it was expressed most forcefully by Wolfgram (1979) who stated "Three decades of myopic preoccupation with EAE have resulted in limiting our investigation almost exclusively to immunology and virology although either discipline has yet to offer a credible explanation of the etiology of MS. ... The demyelination and the death of oligodendrocytes proceed; macrophages and lymphocytes invade the demyelinating areas and an immunologic reaction is generated. This immunological reaction has nothing to do with the demyelination except to clean up the debris. In short, we have mistaken the smoke for the fire".

What is the target organ in the pathogenesis of MS?

There is a consensus that MS is an inflammatory disease and that the primary change in the blood vessel wall that leads to a possible or eventual alteration of the BBB is an inflammatory one. The exact mechanism by which this occurs remains unknown, although a number of suggestions have been made.

It is likely that the most common cause of an inflammatory reaction involving the blood vessel is a viral infection. This has been demonstrated in canine distemper virus infection of the brain in which a perivascular reaction and inflammatory changes in the vessel wall were shown to be identical to those seen in MS (Summers et al. 1979; Axthelm and Krakowka 1987). The same can be observed as the result of a vaccination, a mechanism which is identical with what is seen in EAE (Poser 1969). Reik (19980) proposed that the inflammatory reaction was due to the deposition of immune complexes, and Coyle et al. (1980) and others felt that this was also the causative mechanism in MS. Gay and Esiri (1991) demonstrated the presence of immune complexes in the perivascular spaces of acute MS lesions, and commented that it may not be assumed that the finding of complexed material in lesions is certain evidence that the complexes are the cause of the damage, but a primary pathological role for the complexes is suggested by their exclusive association with acute plaques and their disposition within HLA-DR+ve macrophages in the advancing borders of small hyperactive lesions.

The phenomenon of molecular mimicry (Alvord 1985, Jahnke et al. 1985) may also play an extremely important role in causing the MS "trait" to become the actual CNS disease: because of the fact that excess antibodies against certain viral proteins are present in the blood of the MS "trait" carrier, an infection by a second virus, or vaccination containing viral proteins which share epitopes with the antigen(s) which originally produced the "trait" may result in a further increase in either or both humoral or cellular immunoresponsiveness, and the formation of immune complexes. It can be seen in Table 1 that, for example, assuming that measles caused the development of the trait, a subsequent infection by influenza or a vaccination against it, might produce such a scenario.

Hickey (1991) and others have proposed that the inflammatory reaction results from the action of activated lymphocytes and macrophages but without stipulating an exact mechanism. It has already been pointed out earlier that an inflammatory reaction of blood vessels resulting from an initial viral infection or vaccination may be considered to be part of the MS "trait" and not necessarily lead to an alteration of the BBB, at least one that is sufficient to affect myelin (Gay and Esiri 1991) or to cause MRI changes (Estes et al. 1990).

Before discussing the obligatory alteration of the BBB

TABLE 1

MOLECULAR MIMICRY BETWEEN MYELIN BASIC PROTEIN AND VIRUS PROTEINS

(1) 432-RH GELFRFIW	(2) 198-L QRF AWGSSN	(3) 27-FWR FLW GSSQ
RF	RF WG	RF WG
	RF WG	
	(7) 111-L SRFSW GAEG	
	SR RF FS SW	
SR RF	RF FS SW	RF FS SW
(4) 142-S RF GFENKE	(5) 31-CY ERFSW QRA	(6) 365-WAL ARFSW LN

Notes: (1) Epstein-Barr EC-RF2; (2) influenza A/UDORN/72 NS1; (3) adenovirus 2,5 early 21 K; (4) measles nucleocapsid; (5) influenza B/LEE/40 NS1; (6) Woodchuck hepatitis surface antigen; (7) myelin basic protein (homologous sequences are in bold type). Adapted from Alvord (1985) and Jahnke et al. (1985). Reprinted with permission from the Saudi Medical Journal (Poser 1992b).

impermeability in the formation of the MS lesion, some consideration must be given to examining what is the target organ in MS. There are several possibilities that are not necessarily mutually exclusive. They include the oligodendroglial cell (ODC), the myelin sheath itself, and the BBB. A number of experienced investigators have focused on the ODC as the primary target for the understandable reason that its cell membrane is the myelin sheath. Compston (1991b) speaks of acute changes in the ODC and Hughes (1992) wonders about damage to both the ODC and the myelin sheath. The question of early involvement of the ODC in MS remains unsolved: while neuropathologists all agree that these cells have disappeared from the older parts of the MS plaques, others have noted an actual increase in their number in the early lesions. In fact, a number of prominent neuropathologists (Allen, Esiri, Richardson, Schneck, personal communications) believe that the involvement may be secondary to the destruction of myelin. In my opinion, it is unlikely that ODC is the primary target in MS for a number of reasons: the areas of demyelination in MS characteristically have a very sharp edge which van Bogaert described as being made by a cookie-cutter and thus would not be restricted to the "territory" served by one or more ODCs; the MS lesions are scattered, suggesting that only some ODCs are affected. This is in contrast with the lesions seen in diseases in which it is known that the ODCs are the primary targets: the large confluent areas of demyelination of progressive multifocal leukoencephalopathy, and the almost total loss of myelin in the entire brain seen in some cases of subacute AIDS encephalitis in which the HIV can be found in the ODCs (Gyorkey et al. 1987). Gay (personal communication) noted that in the acute MS lesion even when activated cells have moved into the parenchyma and macrophages are attached to the myelin sheaths, ODCs are intact. The most powerful argument against the primary involvement of the ODC is that the initial, primary lesion of the brain in MS is edema and inflammation of the myelin sheath and not its destruction. This will be discussed in more detail below.

The myelin sheath as the target organ

Despite the fact that MS has classically been called a demyelinating disease, the destruction of the sheath is not the primary event in the disease. Even in EAE, which is considered by so many investigators as the model for MS, the initial lesion, as in MS, consists of inflammation and edema. Rosen et al. (1990) reported in experimental allergic neuritis (EAN) that endoneurial edema and myelin vesiculation appeared several days before macrophage-associated myelin stripping occurred. Dousset et al. (1992) using magnetization transfer imaging proved that lesions of EAE were edematous rather than demyelinating; they also demonstrated the same phenomena in several MS patients. The latter findings are particularly important in illustrating that the standard MRI may not reveal all MS lesions, in particular those in which myelinoclasia had not occurred. Poser et al. (1987) had already concluded that the areas of enhancement obtained with double dose delayed contrast enhancement in CT scanning in an MS patient during an acute relapse were the result of edema since they no longer appeared in an MRI obtained in the same patient shortly thereafter. Further confirmation of this idea came from the report by Newcombe et al. (1991) who were able to examine the brains of MS patients they had studied by means of serial MRIs: "These postmortem observations provide support for the view that the quickly resolving diffuse areas of high signal seen in vivo around lesions known from serial scanning and from gadolinium enhancement to be new, are due to edema". One of the major reasons for suspecting that demyelination is not the primary event in MS, is the remarkably rapid recovery in a matter of a few days, or even a few hours in so many MS patients, of major clinical signs and symptoms, which occurs much faster than could be expected from remyelination. Furthermore, there is the rapid and often dramatic response of MS patients to the administration of corticosteroids, which are primarily anti-inflammatory and anti-edema agents and have no known effect upon demyelination.

The blood-brain barrier as the target organ

In a recent review, Gay and Esiri (1991) have offered convincing evidence to the effect that the BBB, and in particular the blood vessel's endothelial lining, may in fact be the target organ for MS. Tsukada et al. (1987) were able to produce perivascular inflammatory, edematous and demyelinating lesions very similar to those seen in EAE and MS by injecting antibodies against the animal's endothelial cells. Hughes (1992) makes the following statement in his excellent essay on the pathogenesis of MS: "evidence for a primary or a very early abnormality of leukocyte endothelial interaction in MS comes from three sources. Firstly, the inflammatory cell infiltrates commonly surround blood vessels in the white matter of patients with MS even in the absence of demyelination. Secondly, retinal vasculitis has been discovered in 18% of 50 consecutive cases of MS and inflammation in the retina cannot be explained by a neighboring immune response against myelin since the retinal axons are not myelinated. Finally, the earliest radiologically detectable event in MRI studies is a lesion which enhances following the intravenous injection of gadolinium, indicating local breakdown of the BBB". The evidence that both B and T lymphocytes can penetrate through the intact BBB (Hickey 1991) and that inflammatory cells collect in the perivascular spaces of normal white matter in MS patients (Adams 1985; Gay and Esiri 1991) suggests that the involvement of the BBB in MS may be of two types: minor and major. The former would not lead to the formation of MS lesions but would be a component of the MS trait. This means that as part of the MS trait, the BBB is more vulnerable. The formation of MS lesions in the CNS in MS would require a major alteration of the impermeability of the BBB. Compston (1991b) has stated that "the available evidence suggests that cell surface adhesion molecule expression alters when circulating T lymphocytes and macrophages are activated, increasing their endothelial cell attachment; the secretion of cytokines and locally active enzymes leads to transendothelial passage, opening the barrier and bringing an array of potentially pathogenic inflammatory cells and mediators to the abluminal surface of blood vessels". This hypothesis remains to be proved.

The key word in Compston's statement is *mediators*, i.e. substances rather than cells. Hickey (1991) made essentially the same comment and even Lassmann et al. (1991) referred to a number of humoral agents such as complement, tumor necrosis factor and gamma-interferon which might conceivably play a role in a direct attack on myelin, or as effectors of bystander demyelination in MS. Gay and Esiri (1991) comment that "the appearance of considerable protein leakage in normally myelinated areas around plaques suggests that leakage per se is not necessarily demyelinating. Our results argue against specific humoral immune-mediated damage to myelin in MS and support the idea that myelin

may be damaged as an innocent bystander rather than as a specific target in the inflammatory reactions which develop around and within the walls of cerebral vessels". The concept of bystander demyelination deserves serious consideration because it is mentioned by a number of experienced and knowledgeable students of the problem of what happens after the BBB loses its impermeability.

The BBB in the pathogenesis of MS

It has been known since 1949 (Broman) that an alteration of the BBB existed in MS plaques, but the concept that such a breakdown was a crucial and obligatory step in the pathogenesis of the CNS MS lesions was not proposed until 1986 (Poser). The background for this hypothesis has been reviewed in detail elsewhere (Poser 1986, 1992a). The significance of this step in the pathogenetic sequence lies in that it activates the MS "trait" into producing the disease, leading to the development of CNS lesions, some of which may become permanent plaques, which may or may not become symptomatic either shortly thereafter or at a later date. The introduction of contrast-enhanced CT scanning, and more particularly the many studies using gadolinium-enhanced MRI, quickly transformed what had been an hypothesis into an accepted observation. The evidence produced in these studies has also been reviewed previously (Poser 1992a). Since the publication of that article, confirmation of the importance of this step has been made by a number of prominent investigators. Compston (1991b) stated that "BBB penetration can be regarded as the primary disease process without which none of the events directly responsible for myelin injury would occur". Rudge (1991) comments that "that the disease [MS] is focal, characterized by demyelinating plaques, rather than diffuse in nature could be explained in terms of local breakdown of the BBB. It is clear that such a breakdown is an early, if not the first, step in plaque generation".

Hughes (1992) succinctly pointed out that "an early event in the pathogenesis of MS must be an alteration of the blood-CNS barrier which does not normally permit passage of immunoglobulin or lymphocytes into the parenchyma of the brain and spinal cord". Hickey (1991) makes the statement that "it is obvious that any mechanism which physically destroys the components of the BBB will render the CNS open to the cellular and molecular constituents of the blood. This occurs in traumatic or surgical injury, infarction and hemorrhage. In such circumstances the required participants for inflammation are rapidly delivered to the site of injury in a gross, non-specific fashion". It is clear from all these statements that the breakdown of the BBB is obligatory, regardless of what mechanism then becomes activated, be it by immunocompetent cells, humoral factors or as a non-specific bystander phenomenon. This event is important for two reasons: first is that a major alteration of BBB

permeability has taken place, initiating the CNS phase of MS. Secondly, the nature of the event becomes important in that the greater the damage to the BBB the more massive the penetration into the CNS of potentially myelinoclastic elements can be. This would be the case in events such as those noted by Hickey (1991) above. In the MS age group, of all the events he mentions, trauma rather than infarction and hemorrhage would seem to be by far the most common and for this reason will be examined in greater detail.

The role of trauma in MS

Much of the relevant material has already been reviewed (Poser 1986, 1987, 1992a) and will not be repeated. It is worth reiterating that trauma never actually causes MS and that in order for trauma to be considered significant in aggravating or accelerating the course of the disease, there must be evidence of injury to the head, the neck, or the back above the lumbo-sacral region, i.e. above the conus.

The importance of trauma in some MS patients, at some times, is that it greatly facilitates the entry into the brain and/or spinal cord of whatever cellular or humoral substances will result in the formation of new lesions or the enlargement of already existing MS lesions. I am not suggesting that trauma is the most common facilitator or trigger for the formation or enlargement of MS lesions in the CNS. In addition to the much more common infections, and the underestimated role of vaccines, other, rarer events and factors may have similar consequences (Poser 1992a). I have recently observed the triggering effect of toxins in two unique cases, able to penetrate the BBB *in MS patients*, causing *further* injury to an already damaged myelin system: an organophosphate insecticide (Wadia et al. 1974; Abou-Donia 1981; Naqvi et al. 1988) and toluene (Escobar and Aruffo 1980; Rosenberg et al. 1988; Filley et al. 1990).

The effect of concussion on the brain

There has been a great deal of misunderstanding regard-

ing the degree of trauma that must be sustained in order to cause organic changes in the nervous system including alterations of the BBB. A number of excellent publications, reviewed by Rimel et al. (1981), Binder (1986), and Jenkins et al. (1986) have stressed the severity of mild trauma. Kelly et al. (1991) reported a classification devised by the Colorado Medical Society which helped clarify the definition of concussion. They recognized three stages of concussion: grade 1: confusion without amnesia or loss of consciousness; grade 2: confusion with amnesia but without loss of consciousness, and grade 3: loss of consciousness. The fact that concussion could cause anatomic alterations of the brain, i.e. recognizable lesions, had been pointed out as long ago as 1964 by Ommaya et al., by Nevin (1967), and again by Oppenheimer in 1968. The classic review of the effect of trauma on the nervous system by Hardman (1979) reinforces these views.

The effect of concussion on the BBB

The fact that trauma could result in alterations of the BBB in man, which was already recognized by Bakay et al. in 1977, was reinforced by a number of studies using the MRI: Jenkins et al. (1986) and Levin et al. (1987, 1988, 1992). In a number of these papers, MRI abnormalities were found in both gray and white matter. Levin et al. (1988) indicated that out of 50 of their patients who had suffered mild head injuries, lesions restricted to the subcortical white matter were present in nine.

The fact that trauma can produce white matter lesions visible by MRI is illustrated: a healthy 32-year-old man hit his head on the windshield of his car when it was hit from behind. He suffered from a grade 1 concussion. Because of persistent headaches, he was seen about 2 weeks later. His neurological examination was entirely normal except for some mild spasm of the cervical musculature. An MRI (Fig. 1) showed bilateral frontal white matter lesions on the T₂-weighted image. The patient made a complete recovery about a month later. The MRI was not repeated.

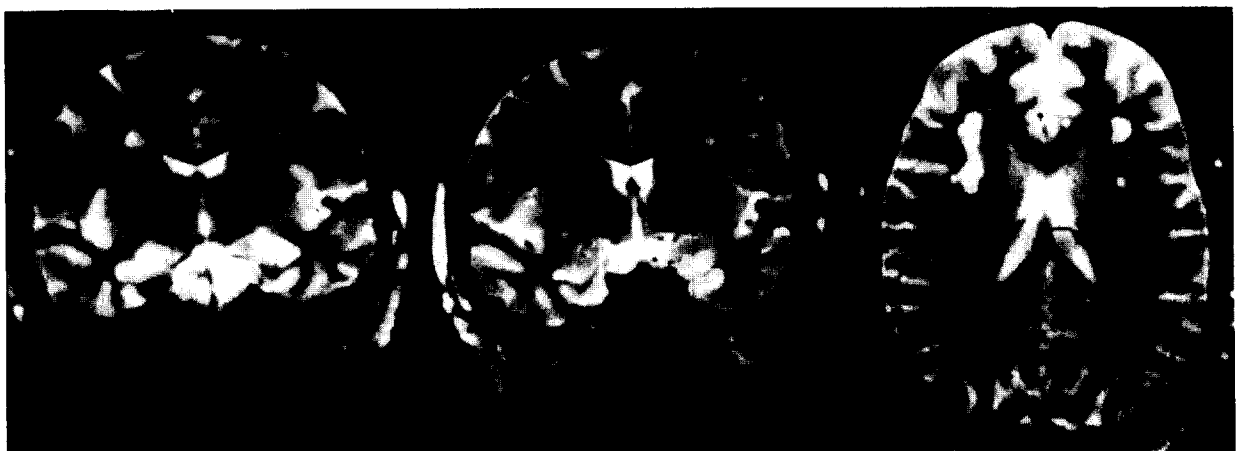

Fig. 1. MRI, T₂-weighted images of a patient who had sustained a mild concussion.

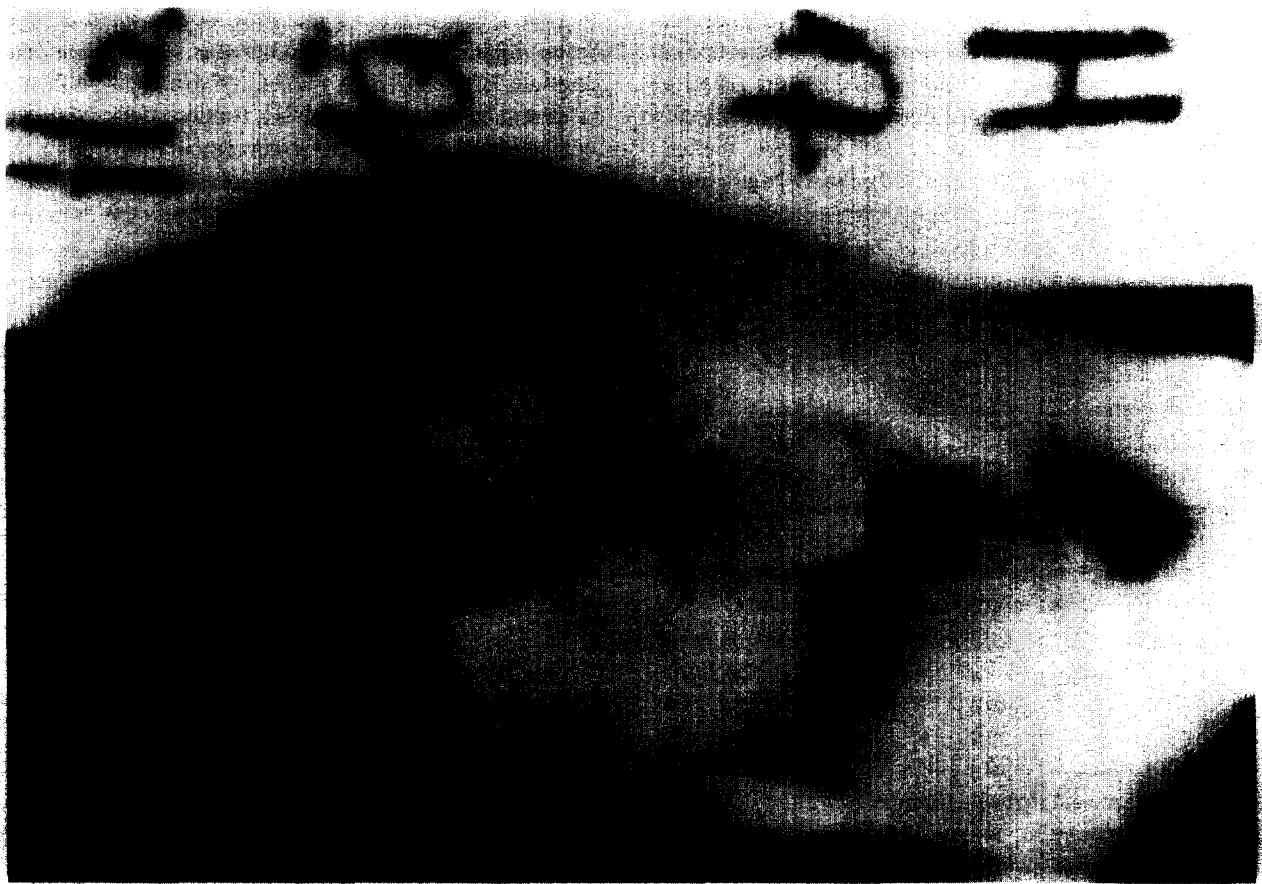

Fig. 2. Evans blue leakage at the anterior angle of the lateral ventricle (arrow) of a rabbit after concussional trauma to the right parietal area. The site of injury also shows leakage of Evans blue dye. Courtesy of Prof. Gunnar Gudmundsson, Landspítalinn, and University of Iceland School of Medicine, Reykjavik, Iceland.

Much of the animal experimental data showing that alterations of the BBB can be produced by mild concussional trauma has been reviewed (Poser 1986, 1992a). Some additional material is worth mentioning. What was undoubtedly the first observation that an alteration of the BBB could occur in the brain in an area removed from the site of injury was made by Gudmundsson in 1959 (Fig. 2; unpublished observation). Maxwell et al. (1988) produced petechial hemorrhages, including areas of disruption of endothelial cells, in the central white matter of baboons subjected to lateral head acceleration. Ultrastructural changes resulting from concussional trauma to the spinal cord of animals were also demonstrated by Hsu et al. (1985), Kapadia (1984) and by Goodman et al. (1976). A particularly interesting publication is the one by Domer et al. (1979), who used intravenously administered radioactive pertechnetate to show a significant increase in BBB permeability in animals subjected to a whiplash injury who sustained no trauma to the head. There is, therefore, ample evidence to support the idea that mild concussional trauma may cause an alteration of BBB.

The effect of trauma on the BBB in MS

Gonsette et al. (1966) were the first to recognize that opening the BBB by using a brain needle to perform a thalamotomy on several MS patients, resulted in the formation of new plaques near the needle tract. Riechert et al. (1975) also noted this but commented that it did not always occur. Brain and Wilkinson (1957) noted the effect of cervical spondylosis on the presence of MS plaques in the cervical cord, an observation that Oppenheimer (1978) confirmed by post-mortem examination. Indeed Rudge (1991) agreed when he stated that "although there are many potential reasons for the BBB to break, a simple model of traumatic damage could account for the commoner sites of lesions being in the highly mobile optic nerve and cervical cord, especially when tethered by the dentate ligaments [Oppenheimer's (1978) exact words], and the periventricular areas, particularly those where acute angles occur resulting in high shear stress".

If one is willing to assume, as so many MS researchers do, that many similarities (although not identity) exist between EAE and MS, there can be no more convincing

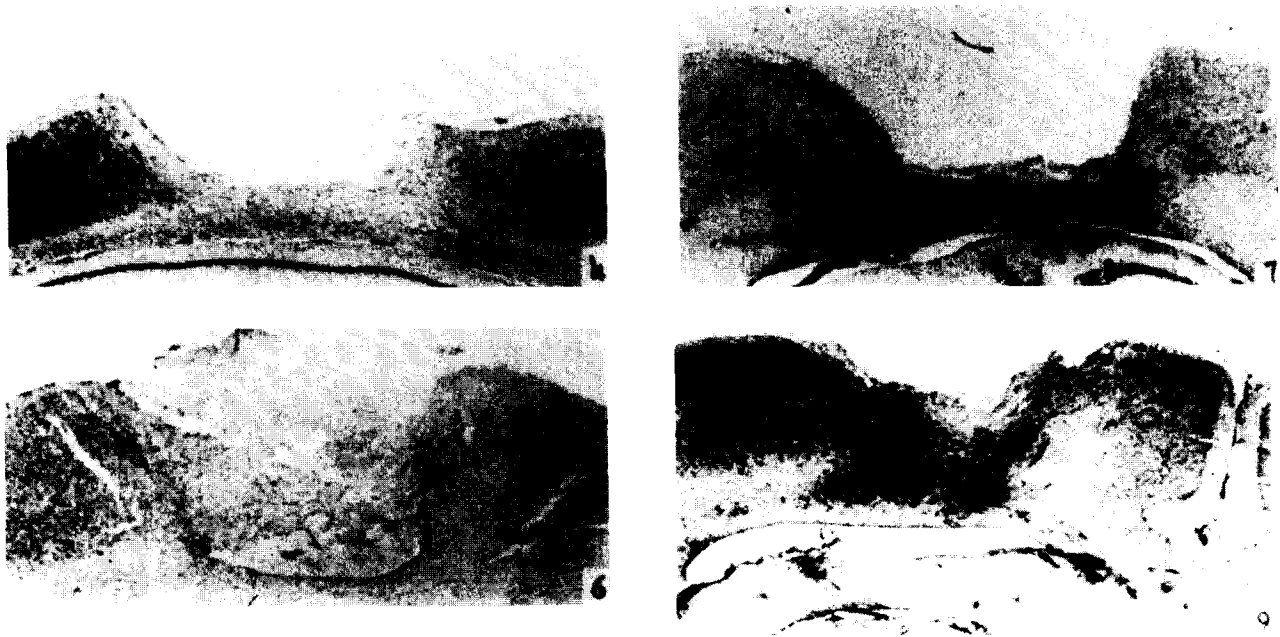


Fig. 3. Left (Nrs. 4 and 6): site of electrolytic lesion in cortex of rat. Right (Nrs. 7 and 9): concentration of lesions of EAE at the site of the previously produced electrolytic lesion. From Clark and Bogdanove (1955). Reproduced with permission from the *Journal of Neuropathology and Experimental Neurology*.

example of the crucial role that can be played by traumatic injury to the BBB in facilitating the formation of lesions than the classic experiments of Clark and Bogdanove (1955). They showed that the lesions of EAE, which are usually disseminated throughout the white matter, could be localized to an area where the BBB had been previously disrupted by an electrolytic lesion (Fig. 3). Levine and Hoenig (1968) did the same thing after producing a local thermal injury to the BBB. It is unfortunately not possible at the present time to produce MRI-confirmed similar examples of lesion localization in MS patients.

Because the degree of vulnerability of the BBB undoubtedly varies from patient to patient as well as from time to time in individual patients, depending upon many factors such as age, the duration of disease, the state of immunological responsiveness, and other unknown factors, it is as unrealistic to expect every MS patient to have a clinical exacerbation following trauma to head, neck or back as to expect every individual to develop the Guillain-Barré syndrome or other neurological illness after influenza vaccination. In fact, in clinical practice it is not at all unusual to have patients suffer trauma without any sequelae, and then to have a later episode that is followed by a serious exacerbation. In fact, Weintraub (1988) commenting on the frequency with which MRI lesions are seen in patients who have just become symptomatic in their twenties or thirties, suggests that these lesions might have resulted from many minor childhood head and neck injuries. Matthews (1991), although he may not have had trauma in mind, almost echoed this when he said that repeated episodes of asymp-

tomatic breakdown of the BBB are envisaged as eventually leading to demyelination and symptomatic relapse.

Notes on the progression of MS

Several years ago (Poser 1985) I suggested that MS was a steadily progressive disease and that exacerbations were entirely dependent upon the clinical location and size of the particular lesion. I suggested an analogy with the Hawaiian Islands. The islands themselves representing clinical exacerbations, while the undersea volcanoes continued to have activity which was unseen and unsuspected. Serial MRI studies have shown that some "lesions" (i.e. areas of increased signal intensity on long TR images) may disappear (Baum et al. 1985) whereas others may appear (Johnson et al. 1984; Uhlenbrock et al. 1989). Serial gadolinium enhanced MRIs have now confirmed this concept (Thompson et al. 1991) (Fig. 4).

It is important, however, to clearly differentiate between the progression of clinical manifestations and the progression of the disease itself, the latter potentially remaining completely asymptomatic for many years, possibly even for the individual's entire life (Poser et al. 1992). There are a number of mechanisms that can explain the progression of clinical symptoms: for example, the scar resulting from the glial response to demyelination may actually extend beyond the confines of the area from which myelin has been lost, thus causing more damage to the nervous system; as axons become destroyed (as often happens in the center of all lesions), Wallerian degeneration ensues, causing an increase

in the severity of signs and symptoms. In regard to the progression of the disease itself, regardless of its clinical manifestations, the problem must, at least at this time, be explained on a different basis. The simplest one is (Fig. 5) that with activity of the disease process, whether symptomatic or not, there is a decrease in the safety margin available for various myelinated systems within the CNS. In other words, the myelinated systems become increasingly vulnerable as the safety margin becomes smaller and smaller, eventually disappears completely, and irreversible changes leading to permanent signs and symptoms appear. Obviously, the temporary impairment of the safety margin or of the system itself may be caused by edema and inflammation which are reversible, but become permanent once myelin is destroyed. The evidence for functional remyelination remains extremely unimpressive.

Another important consideration is that it has been shown (Barnes et al. 1991), by means of serial gadolinium-enhanced MRIs that after alterations of the BBB, complete repair does not always occur and that the normal impermeability of the BBB may not be restored for quite some time. They noted that in pathological examinations of MS brains evidence of active inflammation is occasionally seen at the margins of lesions but is usually absent within them. On the other hand there is pathological evidence to suggest that a

THE PROGRESSION OF MULTIPLE SCLEROSIS

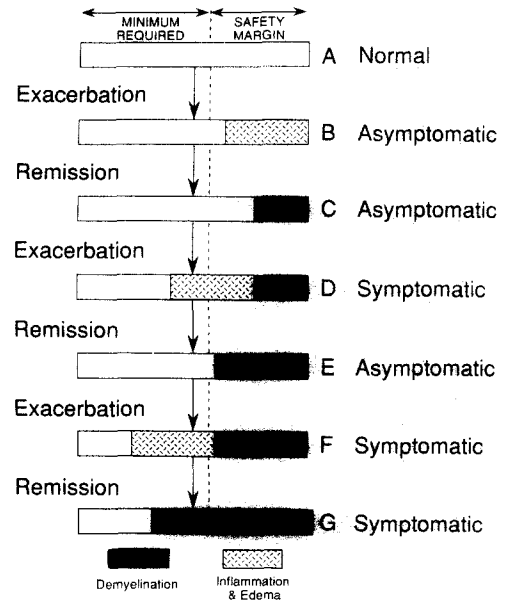


Fig. 5. The progression of MS lesions and their symptoms as related to the decrease in the safety margin. This figure was drawn by Dr. Glenn Rosen, Harvard Medical School – Beth Israel Hospital, Boston, MA.

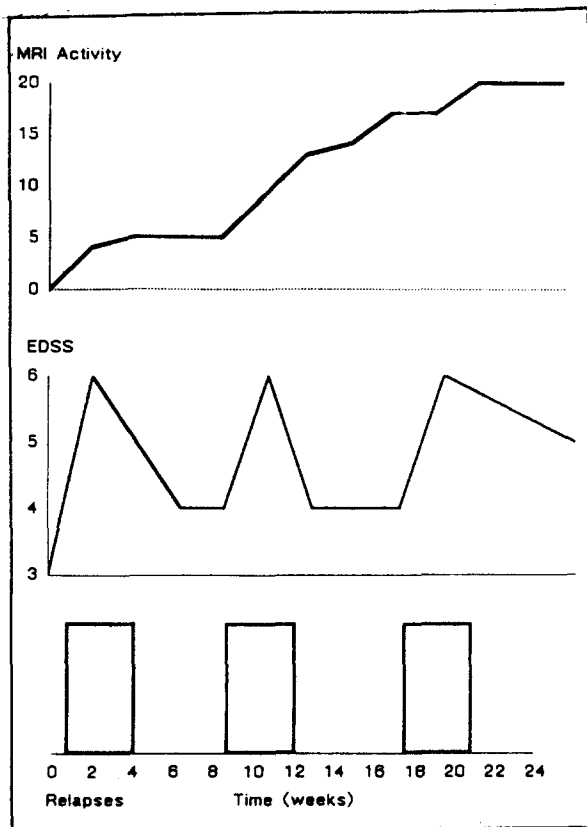


Fig. 4. A comparison of relapses, changes in EDSS score and evidence of activity of MS by MRI. From Thompson et al. (1992). Reproduced with permission from *Neurology*.

disturbance of BBB function continues to exist in these lesions. They have studied some of these plaques by MRI and concluded that the possibility arose that a BBB defect may persist in long-standing lesions and be of pathogenetic significance in the progression of the disease. Evidence of BBB damage was found in 70% of lesions, was less severe than that seen in acute lesions and may result from repeated previous inflammatory insults. The findings implied progressive axonal loss in lesions as they age, accelerating the progression of the disease.

What has not been determined with certainty from imaging studies in MS is whether a more subtle BBB defect exists in long-standing lesions. In the present study, Barnes et al. (1991) found a slow, modest pattern of enhancement in eight out of 53 lesions, distinct from the type seen in acute lesions but similar to that previously reported in demyelinating cervical cord lesions. They concluded that "the type of enhancement seen in our eight lesions may reflect a noninflammatory BBB defect resulting from incomplete repair following repeated previous inflammatory insults. If, as has been suggested blood-borne disease mediators such as complement are important in MS, then a chronic BBB defect of the kind we have observed might allow such mediators to diffuse through open lesions and promote new inflammation at their myelinative margins, as is commonly seen both pathologically and on MRI".

It should also be remembered that as was demonstrated by Adams (1985) and by Gay and Esiri (1992) inflammatory changes can be seen in blood vessels in normal white matter of MS patients and may then be considered to be "at

risk" for the formation of lesions.

The persistence of an open BBB obviously creates a two-way street, since myelin *abbau* substances such as MBP, PLP, and MOG as well as other substances, may leave the CNS and enter the peripheral circulation, where they may activate immunocompetent cells and humoral mediators. The possibility also exists that there is a constant exchange of immunologically active or (inactive) substances that may play a role in either maintaining the alteration of the BBB, or participating in the myelinoclastic process, either directly or indirectly, by unknown means. Whatever the role of activated lymphocytes may be, this scenario was suggested by Zamvil and Steinman (1990). Oger et al. (1988) and Davison (1992) made somewhat similar suggestions. It is extended here to include non-cellular elements. What it really means is that as long as the BBB remains permeable, MS must be considered a self-perpetuating disease. This indicates that a single event, whether it is an infection, vaccination, trauma, or any other trigger, may initiate a cascade of neuropathological events which will result in progression of the disease itself as well as, in many instances, of its clinical manifestations. In other words, there is no way of knowing when and if a lesion which resulted from the BBB alteration that was caused by a triggering episode and which remained asymptomatic, may at any time in the future, as a result of another trigger (perhaps an insignificant viral infection) become symptomatic (Fig. 5).

In this light, it is difficult to explain the fact that a number of MS patients, in particular those who have suffered from the disease for 15 or 20 years, quite often stabilize, so that the disease appears to be "burned out". This has not yet been confirmed by serial MRI studies but certainly appears to be so from clinical observation. It is possible that the blood-brain barrier eventually is restored to its impermeability, that the activity of the immune system quiets down or that some other changes take place which cause the myelinoclastic mechanism to disappear.

Conclusions

Many unanswered questions and unexplained puzzling observations remain in terms of the exact pathogenesis of MS. It is not appropriate today to state that the etiology of MS is unknown, a concept which does not apply here as it does in bacterial pneumonia or myocardial infarction. There is no longer any doubt about the initiatory role of a non-specific viral infection or of a viral antigen in producing a systemic condition known as the MS trait. It is now quite well established that an alteration of the BBB is an obligatory step in the formation of the MS lesion in the CNS. This lesion consists of edema and inflammation and may, but need not, go on to demyelination. Several mechanisms can lead to the increased BBB permeability among which the

most common are viral infections and concussional trauma, although it is clear that these triggering events will not necessarily result in changes in the CNS in all cases or on every occasion in the same patient. Evidence has now become available which establishes that the BBB impermeability may not be fully restored and that cellular and humoral mediators may move in both directions across the BBB; this would imply that MS may be a self-perpetuating disease process. The exact course of events which results in the actual destruction of the myelin sheath remains a mystery.

Acknowledgements I wish to express my gratitude to Dr. Luigi Pugnetti, Milan, for his extraordinary patience and continued encouragement in writing this review. I am much indebted to Dr. Derek Gay, Colchester General Hospital, Essex, UK, and to Dr. Scott Zamvil, Harvard Medical School, Boston, MA, USA, for their constructive comments and suggestions. The opinions expressed herein are my own and do not necessarily reflect their views. Della Grigsby's superb typing skills, and Joan Crawford Poser's judicious editorial review are hereby gratefully acknowledged.

References

- Abou-Dia, M. (1981) Organophosphorous ester-induced delayed neurotoxicity. *Annu. Rev. Pharmacol. Toxicol.*, 21: 511-548.
- Adams, C., R. Poston, S. Buk et al. (1985) Inflammatory vasculitis in MS. *J. Neurol. Sci.*, 69: 269-283.
- Allen, I. (1991) Aetiological implications. In: Matthews, W. (Ed.), *McAlpine's Multiple Sclerosis*, 2nd edn., Churchill Livingstone, Edinburgh, p. 375.
- Alvord, E. (1985) Experimental allergic encephalomyelitis and experimental allergic neuritis. In: Vinken, P.J., G.W. Bruyn and J. Koetsier (Ed.), *Handbook of Neurology: Demyelinating diseases*, vol. 3, Elsevier, Amsterdam, pp. 429-466.
- Amon, R., E. Crisp, R. Kelley, G. Ellison, L. Meyers and W. Tourtellotte (1980) Anti-ganglioside antibodies in MS. *J. Neurol. Sci.*, 46: 179-186.
- Atkins, G., E. Daly, B. Sheahan, D. Higgins and P. Sharp (1990) MS and molecular mimicry. *Neuropathol. Appl. Neurobiol.*, 16: 179.
- Axthelm, M. and S. Krakowka (1987) Canine distemper virus: the early blood-brain barrier lesion. *Acta Neuropathol.*, 75: 27-33.
- Bakay, L., J. Lee, G. Lee et al. (1977) Experimental cerebral concussion. Part I: An electron microscopic study. *J. Neurosurg.*, 47: 346-352.
- Barnes, D., P. Munro, B. Youl, J. Prineas and W. McDonald (1991) The longstanding MS lesion. *Brain*, 114: 1271-1280.
- Baum, K., W. Girke, T. Braeu et al. (1985) Zur Bedeutung der magnetischen Resonanz-Tomographie bei Encephalomyelitis disseminata. *Nervenarzt*, 56: 666-672.
- Binder, L. (1986) Persisting symptoms after mild head injury: A review of the postconcussive syndrome. *J. Clin. Exp. Neuropsychol.*, 8: 323-346.
- Brain, W. and M. Wilkinson (1957) The association of cervical spondylosis and disseminated sclerosis. *Brain*, 80: 456-478.
- Brody, J., J. Sever and T. Henson (1971) Virus antibody titers in MS patients, siblings and controls. *J.A.M.A.*, 216: 1441-1446.
- Broman, T. (1949) *The Permeability of the Cerebrospinal Vessels in Normal and Pathological Conditions*, Munksgaard, Copenhagen, p. 66.
- Chou, Y., D. Bourdette, H. Offner et al. (1992) Frequency of T cells specific for myelin basic protein and myelin proteolipid protein in blood and cerebrospinal fluid in MS. *J. Neuroimmunol.*, 38: 105-115.
- Clark, G. and L. Bogdanove (1955) The induction of the lesions of allergic meningoencephalomyelitis in a predetermined location. *J. Neuro-pathol. Exp. Neurol.*, 14: 433-437.
- Compston, D. (1991a) Immunological aspects of MS. In: Matthews, W. (Ed.), *McAlpine's Multiple Sclerosis*, 2nd edn., Churchill Livingstone,

- Edinburgh, p. 328.
- Compston, D. (1991b) Limiting and repairing the damage in MS. *J. Neurol. Neurosurg. Psychiat.*, 54: 945–948.
- Coyle, P., R. Hirsch, P. O'Donnell et al. (1980) Cerebrospinal fluid lymphocyte population and immune complexes in active MS. *Lancet*, 2: 229–232.
- Davison, A. (1992) The relevance of experimental allergic encephalomyelitis to MS. *J. R. Soc. Med.*, 85: 425–426.
- Domer, F., Y. Liu, K. Chandran and K. Krieger (1979) Effect of hyperextension-hyperflexion (whiplash) on the function of the blood-brain barrier of Rhesus monkeys. *Exp. Neurol.*, 63: 304–310.
- Dousset, V., R. Grossman, K. Ramer et al. (1992) Experimental allergic encephalomyelitis and MS: lesion characterization with magnetization transfer imaging. *Radiology*, 182: 483–491.
- Duquette, P. (1991) Familial subclinical MS. *Neurology*, 41: 159.
- Escobar, A. and C. Aruffo (1980) Chronic thinner intoxication: clinico-pathologic report of a human case. *J. Neurol. Neurosurg. Psychiat.*, 43: 986–994.
- Estes, M., R. Rudick, G. Barnett and R. Ransohoff (1990) Stereotactic biopsy of an active MS lesion. *Arch. Neurol.*, 47: 1299–1303.
- Filley, C., R. Heaton and N. Rosenberg (1990) White matter dementia in chronic toluene abuse. *Neurology*, 40: 532–534.
- Fredrikson, S., J. Michelsberg, J. Hillert et al. (1992) Conjugal MS: Immunogenetic characterization and analysis of T- and B-cell reactivity to myelin proteins. *Neurology*, 42: 577–582.
- Fujinami, R., M. Oldstone, Z. Wroblewska et al. (1983) Molecular mimicry in virus infections. *Proc. Natl. Acad. Sci. USA* 80: 2346–2350.
- Gay, D. and M. Esiri (1991) Blood-brain barrier damage in acute MS plaques. *Brain*, 114: 557–572.
- Gonsette, R., G. Andre-Balisax and P. Delmotte (1966) La perméabilité des vaisseaux cérébraux. VI. Démyélinisation expérimentale provoquée par des substances agissant sur la barrière hémato-encéphalique. *Acta Neurol. Belg.*, 66: 247–262.
- Goodman, J., W. Bingham and W. Hunt (1976) Ultrastructural blood-brain barrier alteration and edema formation in acute spinal cord trauma. *J. Neurosurg.*, 44: 418–424.
- Gyorkey, F., J. Melnick and P. Gyorkey (1987) Human immunodeficiency virus in brain biopsies of patients with AIDS and progressive encephalopathy. *J. Infect. Dis.*, 155: 870–876.
- Haile, R., L. Karavodin, B. Visscher and R. Detels (1981) Similar levels of immune complexes in cases of MS and their unaffected relatives. *J. Neuroimmunol.*, 1: 183–190.
- Hardman, J. (1979) The pathology of traumatic brain injuries. *Adv. Pathol.*, 22: 15–50.
- Hickey, W. (1991) Migration of hematogenous cells through the blood-brain barrier and the initiation of CNS inflammation. *Brain Pathol.*, 1: 97–105.
- Hsu, C., E. Hogan, R. Gadsden, K. Spicer, M. Shi and R. Cox (1985) Vascular permeability in experimental spinal cord injury. *J. Neurol. Sci.*, 70: 275–282.
- Hughes, R. (1992) Pathogenesis of MS. *J. R. Soc. Med.*, 85: 373–375.
- Isacson, P. and A. Stone (1971) Allergic reactions associated with viral vaccines. *Progr. Med. Virol.*, 13: 239–270.
- Jahnke, U., E. Fischer and E. Alvord (1985) Sequence homology between certain viral proteins and proteins related to encephalomyelitis and neuritis. *Science*, 229: 282–284.
- Jenkins, A., G. Teasdale, M. Howley, P. Macpherson and J. Rowan (1986) Brain lesions detected by MRI in mild and severe head injuries. *Lancet*, 2: 445–446.
- Jingzu, Z., R. Medaer, G. Hashim, Y. Chin, E. van den Berg-Loonen and J. Raus (1992) Myelin basic protein specific T lymphocytes in MS and controls: precursor frequency, fine specificity, and cytotoxicity. *Ann. Neurol.*, 32: 330–338.
- Johnson, D., D. Hafler, G. Fallis et al. (1986) Cell-mediated immunity to myelin-associated glycoprotein, proteolipid protein, and myelin basic protein in MS. *J. Neuroimmunol.*, 13: 99–108.
- Johnson, M., D. Li, D. Bryant et al. (1984) Magnetic resonance imaging: serial observations in MS. *A.J.N.R.*, 5: 495–499.
- Kapadia, S. (1984) Ultrastructural alterations in blood vessels of the white matter after experimental cord trauma. *J. Neurosurg.*, 61: 539–544.
- Kelly, J., J. Nichols, C. Filley, K. Lillehei, D. Rubinstein and B. Kleinschmidt-DeMasters (1991) Concussion in sports: guidelines for the prevention of catastrophic outcome. *J.A.M.A.*, 266: 2867–2869.
- Kinnunen, E., M. Valle, L. Piirainen et al. (1990) Viral antibodies in MS: an nationwide co-twin study. *Arch. Neurol.*, 47: 743–746.
- Lassmann, H., F. Zimprich, K. Rossler and K. Vass (1991) Inflammation in the nervous system: basic mechanisms and immunological concepts. *Rev. Neurol.*, 147: 763–781.
- Levin, H., E. Amparo, H. Eisenberg et al. (1987) Magnetic resonance imaging and computerized tomography in relation to neurobehavioral sequelae of mild and moderate head injuries. *J. Neurosurg.*, 66: 706–713.
- Levin, H., D. Williams, M. Crofford et al. (1988) Relationship of depth of brain lesions to consciousness and outcome of closed head injury. *J. Neurosurg.*, 69: 861–866.
- Levin, H., D. Williams, H. Eisenberg, W. High and F. Guinto (1992) Serial MRI and neurobehavioural findings after mild to moderate head injury. *J. Neurol. Neurosurg. Psychiat.*, 55: 255–262.
- Levine, S. and E. Hoenig (1968) Induced localization of allergic adrenalitis and encephalomyelitis at sites of thermal injury. *J. Immunol.*, 100: 1310–1318.
- Lisak, R. (1986) Immunological abnormalities. In: McDonald, W. and D. Silberberg (Eds.), *Multiple Sclerosis*, Butterworths, London, p. 74.
- Lumsden, C. (1972) The clinical immunology of MS. In: McAlpine, D., C. Lumsden and E. Acheson (Eds.), *Multiple Sclerosis: a reappraisal*, 2nd edn., Williams and Wilkins, Baltimore, MD, pp. 518–519.
- Lynch, S. and J. Rose (1991) Reply to "Familial subclinical MS" by Duquette, P. *Neurology*, 41: 159.
- Martino, G., T. Olsson, S. Fredrikson et al. (1991) Cells producing antibodies specific for myelin basic protein region 70–89 are predominant in cerebrospinal fluid from patients with MS. *Eur. J. Immunol.*, 21: 2971–2976.
- Matthews, W. (1991) Pathophysiology. In: Matthews, W. (Ed.), *McAlpine's Multiple Sclerosis*, 2nd edn., Churchill Livingstone, Edinburgh, p. 243.
- Maxwell, W., A. Irvine, J. Hume Adams, D. Graham and T. Gennarelli (1988) Response of cerebral microvasculature to brain injury. *J. Pathol.*, 155: 327–335.
- Murray, R., B. Brown, D. Brian and G. Cabirac (1992) Detection of Corona virus RNA and antigen in MS brain. *Ann. Neurol.*, 31: 525–533.
- Nevin, N. (1967) Neuropathologic change in the white matter following head injury. *J. Neuropathol. Exp. Neurol.*, 26: 77–84.
- Newcombe, J., C. Hawkins, C. Henderson et al. (1991) Histopathology of MS lesions detected by MRI in unfixed postmortem central nervous system. *Brain*, 114: 1013–1023.
- Naqvi, S.H. Mahdi and S. Haider (1988) Neurochemical effects of phosphamidon on lipid fraction and lipid peroxidation in the rat central nervous system. *Indian J. Med. Res.*, 88: 85–90.
- Noble, G., H. Kaye, A. Kendal and W. Dowdle (1977) Age-related heterologous antibody responses to influenza virus vaccination. *J. Infect. Dis.*, 136 (Suppl.): S686–692.
- Oger, J., L. Kastrukoff, D. Li et al. (1988) MS: in relapsing patients, immune functions vary with disease activity as assessed by MRI. *Neurology*, 38: 1739–1744.
- Olsson, T., W. Zhi, B. Hojeberg et al. (1990) Autoreactive T lymphocytes in MS determined by antigen-induced secretion of interferon-gamma. *J. Clin. Invest.*, 86: 981–985.
- Ommaya, A., D. Rockoff and M. Baldwin (1964) Experimental concussion: a first report. *J. Neurosurg.*, 21: 249–265.
- Oppenheimer, D. (1968) Microscopic lesions in the brain following head injury. *J. Neurol. Neurosurg. Psychiat.*, 31: 299–306.
- Oppenheimer, D. (1978) The cervical cord in MS. *Neuropathol. Appl. Neurobiol.*, 4: 151–162.
- Panelius, M., A. Salmi, P. Halonen et al. (1973) Virus antibodies in serum

- specimens from patients with MS, from siblings, and matched controls. A final report. *Acta Neurol. Scand.*, 49: 85–107.
- Poser, C. (1969) Disseminated vasculomyelinopathy. *Acta Neurol. Scand.*, 45: Suppl. 37: 1–44.
- Poser, C. (1979) Trauma, stress and MS. *Bull. Am. Acad. Psychiat. Law*, 7: 208–219.
- Poser, C. (1985) The course of MS. *Arch. Neurol.*, 42: 1035.
- Poser, C. (1986) The pathogenesis of MS: a critical reappraisal. *Acta Neuropathol.*, 71: 1–10.
- Poser, C. (1987) Trauma and multiple sclerosis. *J. Neurol.*, 254: 155–159.
- Poser, C. (1992a) Multiple sclerosis. Observations and reflections – a personal memoir. *J. Neurol. Sci.*, 107: 127–140.
- Poser, C. (1992b) Neurological complications of infections and vaccinations. *Saudi Med. J.*, 13: 379–386.
- Poser, C., J. Kleefield, G. O'Reilly and F. Jolesz (1987) Neuro-imaging and the lesion of MS. *A.J.N.R.*, 8: 549–552.
- Poser, C., J. Benedikz and P. Hibberd (1992) The epidemiology of MS: the Iceland model. Onset-adjusted prevalence rate and other methodological considerations. *J. Neurol. Sci.*, 111: 143–152.
- Reik, L. (1980) Disseminated vasculomyelinopathy. *Ann. Neurol.*, 7: 291–296.
- Raine, C. (1991) MS: a pivotal role for the T cell in lesion development. *Neuropathol. Appl. Neurobiol.*, 17: 265–274.
- Riechert, T., R. Hassler and F. Munding (1975) Pathologic-anatomical findings and cerebral localization in stereotactic treatment of extrapyramidal motor disturbances in MS. *Confin. Neurol.*, 37: 24–40.
- Rimel, B., B. Giordani, J. Barth, T. Boll and J. Jane (1981) Disability caused by minor head injury. *Neurosurgery*, 9: 221–228.
- Rosen, J., M. Brown, W. Hickey and A. Rostami (1990) Early myelin lesions in experimental allergic neuritis. *Muscle Nerve*, 13: 629–636.
- Rosenberg, N., B. Kleinschmidt-DeMasters, K. Davis, J. Dreisbach, J. Hornes and C. Filley (1988) Toluene causes diffuse central nervous system white matter changes. *Ann. Neurol.*, 23: 611–614.
- Rudge, P. (1991) Does a retrovirally encoded superantigen cause MS? *J. Neurol. Neurosurg. Psychiat.*, 54: 853–855.
- Summers, B., H. Greisen and M. Appel (1979) Early events in canine distemper demyelinating encephalomyelitis. *Acta Neuropathol.*, 46: 1–10.
- Sun, J., H. Link, T. Olsson et al. (1991) T and B cell responses to myelin-oligodendrocyte glycoprotein in MS. *J. Immunol.*, 146: 1490–1495.
- Thompson, A., D. Miller, B. Youl et al (1992) Serial gadolinium-enhanced MRI in relapsing/remitting MS of varying disease duration. *Neurology*, 42: 60–63.
- Toro, G., I. Vergara and G. Roman (1977) Neuroparalytic accidents of anti-rabies vaccination with suckling mouse brain vaccine. *Arch. Neurol.*, 34: 694–700.
- Tsukada, N., C. Koh, N. Yanagisawa et al. (1987) A new model for MS: chronic experimental encephalomyelitis induced by immunization with cerebral endothelial cell membrane. *Acta Neuropathol.*, 73: 259–266.
- Uchimura, I., and Shiraki, H. (1957) A contribution to the classification and pathogenesis of demyelinating encephalomyelitis with special reference to the central nervous system lesions caused by preventive inoculation against rabies. *J. Neuropathol. Exp. Neurol.*, 16: 139–203.
- Uhlenbrock, D., E. Herbe, D. Seidel et al. (1989) One-year MR imaging follow-up of patients with MS under cortisone therapy. *Neuroradiology*, 31: 3–7.
- Wadia, R., C. Sadagopan, R. Amin and H. Sardesai (1974) Neurological manifestations of organophosphorous insecticide poisoning. *J. Neurol. Neurosurg. Psychiat.*, 37: 841–847.
- Weintraub, M.: Trauma and MS: medico-legal implications (1988) *Dev. Med. Child Neurol.*, 30: 407–408.
- Wekerle, H., C. Linington, H. Lassmann and R. Meyerman (1986) Cellular immune reactivity within the CNS. *Trends Neurol. Sci.*, 9: 271–277.
- Wisniewski, H. and B. Bloom (1975) Primary demyelination as a nonspecific consequence of cell-mediated immune reaction. *J. Exp. Med.*, 141: 346–359.
- Wolfgram, F. (1979) What if MS isn't an immunological or viral disease? *Neurochem. Res.*, 4: 1–14.
- Woyciechowska, J., J. Dambrozia, P. Leinikki, et al (1985) Viral antibodies in twins with MS. *Neurology*, 35: 1176–1180.
- Xu, X. and D. McFarlin (1984) Oligoclonal bands in CSF: twins with MS. *Neurology*, 34: 769–774.
- Zamvil, S. and L. Steinman (1990) The T lymphocyte in experimental allergic encephalomyelitis. *Annu. Rev. Immunol.*, 89: 579–621.