



Since January 2020 Elsevier has created a COVID-19 resource centre with free information in English and Mandarin on the novel coronavirus COVID-19. The COVID-19 resource centre is hosted on Elsevier Connect, the company's public news and information website.

Elsevier hereby grants permission to make all its COVID-19-related research that is available on the COVID-19 resource centre - including this research content - immediately available in PubMed Central and other publicly funded repositories, such as the WHO COVID database with rights for unrestricted research re-use and analyses in any form or by any means with acknowledgement of the original source. These permissions are granted for free by Elsevier for as long as the COVID-19 resource centre remains active.



Immunohistochemical Demonstration of Spread of Aujeszky's Disease Virus to the Porcine Central Nervous System after Intestinal Inoculation

M. Narita, K. Kimura, N. Tanimura, S. Arai and A. Uchimura

*National Institute of Animal Health, Ministry of Agriculture, Forestry and Fisheries,
3-1-1 Kannondai, Tsukuba, Ibaraki 305-0856, Japan*

Summary

Aujeszky's disease virus (ADV) was injected into the duodenal lumen of eight specific pathogen-free pigs aged 5 weeks. The infected pigs did not show any diarrhoea or nervous symptoms, but they developed characteristic necrotizing enteritis and myenteric plexitis, accompanied by follicular necrosis in the Peyer's patches. ADV antigen was detected in the submucosa of the dome area of Peyer's patches, lymphatic follicles, Meissner's and Auerbach's plexuses, solar ganglia and thoracic spinal ganglia. These findings suggest that ADV spreads from the intestinal mucosa to the central nervous system via the autonomic nerves.

© 1998 W.B. Saunders Company Limited

Introduction

Aujeszky's disease is a severe, highly fatal disease of young pigs. Aujeszky's disease virus (ADV), a neurotropic herpesvirus, spreads via the nerves from the primary site of infection to the central nervous system (CNS) (Corner, 1965; McFerran and Dow, 1965; Bergmann and Becker, 1967; Rajcani *et al.*, 1969; Sabo *et al.*, 1969; Narita *et al.*, 1991). In piglets, initial replication of ADV in the naso-pharyngeal mucosa and tonsillar epithelium leads to systemic infection with necrotic hepatitis, adrenitis and encephalitis (Corner, 1965; McFerran and Dow, 1965; Olander *et al.*, 1966). Recent studies showed that some strains of ADV produce necrotic lesions in the gastrointestinal tract and myenteric plexuses (Narita *et al.*, 1984, 1998; Ezura *et al.*, 1995; Zhao *et al.*, 1996). However, there has been no demonstration of viral spread to the CNS via the myenteric plexuses in the small intestine and solar ganglia following intestinal infection with ADV. The purpose of the present study was to investigate this point.

Materials and Methods

Animals

Nine specific pathogen-free pigs aged 5 weeks were used. The animals had no neutralizing antibody against ADV. They were housed separately in a barrier-maintained room.

Virus

The Yamagata strain (YS-81) of ADV, isolated from the brain and tonsils of naturally infected pigs (Fukusho *et al.*, 1981), was passaged serially five times in porcine kidney (PK-15) cell culture (Narita *et al.*, 1982, 1984, 1991). The infected cell culture fluid was used, after appropriate dilution, to inoculate the pigs.

Experimental Procedure

After an intramuscular injection of atropine hydrochloride (0.05 g/kg), pigs were anaesthetized with a mixture of halothane and O₂, delivered by means of a mask and closed circuit system. Laparotomy was performed by incision along the linea alba.

Eight pigs (nos 1–8) were given 10 ml of ADV suspension (10⁶ TCID₅₀/ml) by injection into the lumen of the duodenum; pig 9 (control) was inoculated with sterile culture medium. After closure of the abdomen, the pigs were allowed free access to water. During the experiment, all pigs were observed at least twice daily for clinical signs. The infected pigs were killed in pairs by intravenous overdoses of pentobarbital sodium on post-inoculation day (PID) 3, 5, 7 and 10; the non-infected control (pig 9) was killed on PID 10.

Histopathological and Immunohistochemical Examination

The sites from which specimens were taken are listed in Table 1. Specimens from the gut, spinal cord and ganglia included: two longitudinal specimens from the duodenum; three, four and three specimens from the upper, middle and lower parts of the jejunum, respectively; three and two from the upper and lower parts of the ileum, respectively; two from the caecum; four from the colon; two from the rectum; eight from the cervical spinal cord and ganglia; 12 from the thoracic spinal cord and ganglia; and seven from the lumbar spinal cord and ganglia. The specimens were fixed in buffered 10% formalin, embedded in paraffin wax, sectioned (3 µm), and stained with haematoxylin and eosin (HE).

Most of the sections were examined immunohistochemically. Viral antigens were demonstrated by the avidin-biotin complex immunoperoxidase method (ABC-IP), as described previously (Narita *et al.*, 1991), with the Vectastain ABC kit (Vector Laboratories, Burlingame, CA, USA). Rabbit antisera against ADV, porcine rotavirus, porcine epidemic diarrhoea virus (PEDV) and transmissible gastroenteritis virus (TGEV), kindly provided by Drs T. Imada and T. Tsuda, National Institute of Animal Health, were used as the primary antibody at dilutions of 1 in 2048, 1 in 1024, 1 in 1024 and 1 in 2048, respectively. Sections were counter-stained with methyl green. Tissue sections from pig 9 and serum from a non-immunized rabbit were used for negative control purposes. In addition, sections of small intestine from pigs experimentally infected with rotavirus, PEDV or TGEV were used as positive controls.

Results

Clinical Observations

In pigs 1–8, the initial signs of disease were pyrexia (up to 39.5°C), which persisted for 2 or 3 days. No diarrhoea or nervous symptoms were observed. The control pig (no. 9) remained apparently healthy.

Pathology

Macroscopically, no intestinal lesions were observed in any pig. Histologically, characteristic lesions of ADV infection were observed in the small intestine,

Table 1
Distribution of histological lesions and ADV antigen in inoculated pigs

Site	<i>Histological lesions/ADV antigen in pig no.</i>								
	1 (3)*	2 (3)	3 (5)	4 (5)	5 (7)	6 (7)	7 (10)	8 (10)	9 (10)
Duodenum									
Villi	+++	-/-	-/-	+++	-/-	-/-	-/-	-/-	-/-
Submucosa	+++	-/-	-/-	+++	-/-	-/-	-/-	-/-	-/-
Myenteric plexuses	-/-	+++	+++	+++	-/-	+/-	-/-	-/-	-/-
Jejunum									
Villi	+++	+++	+++	+++	-/-	-/-	-/-	-/-	-/-
Submucosa	+++	+++	+++	+++	-/-	-/-	-/-	-/-	-/-
Lymphoid follicle	-/-	-/-	+++	+++	-/-	-/-	-/-	-/-	-/-
Myenteric plexuses	-/-	+/-	+++	+++	+/-	+/-	-/-	-/-	-/-
Ileum									
Villi	-/-	-/-	-/-	-/-	-/-	-/-	-/-	-/-	-/-
Submucosa	-/-	-/-	-/-	-/-	-/-	-/-	-/-	-/-	-/-
Lymphoid follicle	-/-	-/-	-/-	-/-	-/-	-/-	-/-	-/-	-/-
Myenteric plexuses	-/-	-/-	+/-	-/-	-/-	-/-	-/-	-/-	-/-
Caecum	-/-	-/-	-/-	-/-	-/-	-/-	-/-	-/-	-/-
Colon	-/-	-/-	-/-	-/-	-/-	-/-	-/-	-/-	-/-
Rectum	-/-	-/-	-/-	-/-	-/-	-/-	-/-	-/-	-/-
Adrenal gland	-/-	-/-	-/-	+++	-/-	-/-	-/-	-/-	-/-
Solar ganglia	-/-	+/-	+++	+++	+++	+/-	+/-	+/-	-/-
Lumbar sc and sg	-/-	+/-	-/-	+/-	+/-	+/-	-/-	+/-	-/-
Thoracic sc and sg	-/-	+/-	+/-	+++	+/-	+/-	+/-	+/-	-/-
Cervical sc and sg	-/-	-/-	-/-	+/-	+/-	+/-	-/-	+/-	-/-
Trigeminal ganglia	-/-	-/-	-/-	-/-	-/-	-/-	-/-	-/-	-/-
Medulla oblongata	-/-	-/-	-/-	+/-	+/-	+/-	-/-	-/-	-/-
Cerebrum	-/-	-/-	-/-	-/-	-/-	-/-	-/-	-/-	-/-
Other tissues†	-/-	-/-	-/-	-/-	-/-	-/-	-/-	-/-	-/-

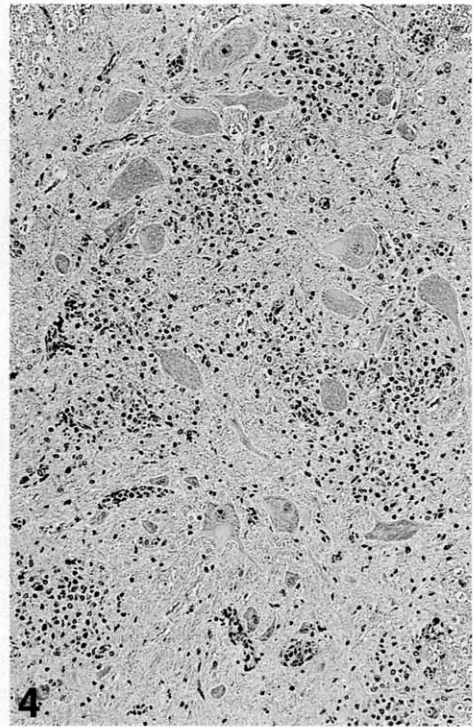
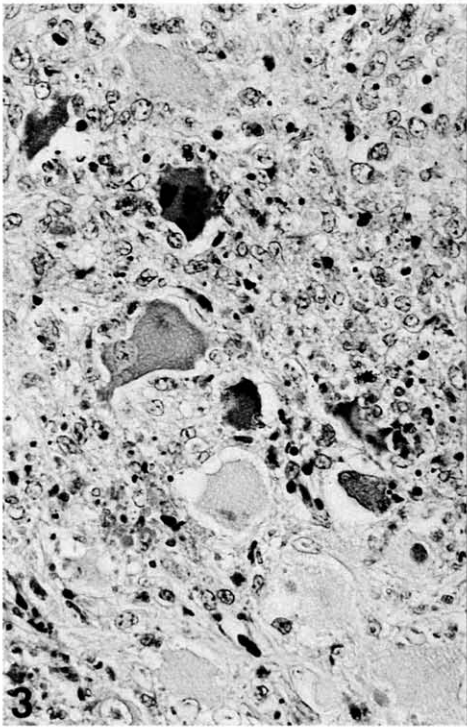
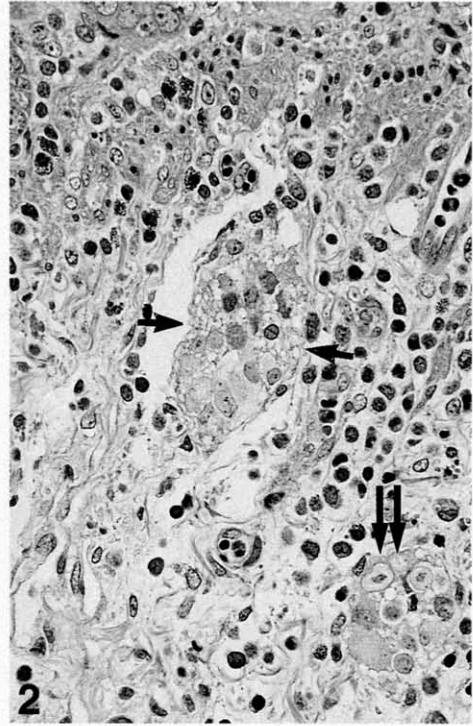
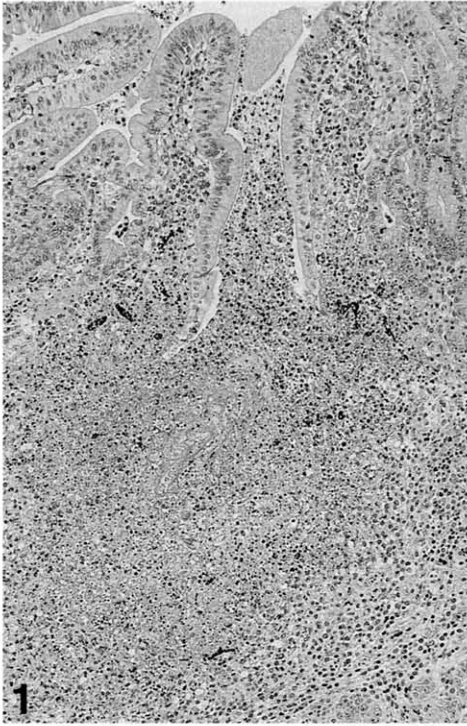
* Interval (days) between inoculation and killing are given in parentheses.

† Liver, spleen, kidney, heart, lung.

-, Absent; +, present; sc, spinal cord; sg, spinal ganglia.

solar ganglia and thoracic-lumbar spinal cord and associated ganglia, but not in the other tissues (Table 1).

On PID 3 and 5, four infected pigs (nos 1-4) showed prominent intestinal lesions in the duodenum and jejunum, characterized by karyorrhectic necrotic foci; these lesions occurred in the epithelium of the villi and crypts, and in associated Peyer's patches (Fig. 1) and Meissner's (Fig. 2) and Auerbach's plexuses. The nuclei of the degenerating cells contained a few eosinophilic intranuclear inclusion bodies. In the two pigs killed on PID 7, lesions were found in the myenteric plexuses, but on PID 10, no intestinal lesions were seen. More frequently, necrotic and inflammatory changes were shown in the solar ganglia (Fig. 3) and plexus, and in the thoracic-lumbar spinal cord (Fig. 4) and associated ganglia. The changes were localized mainly to the dorsal and ventral horns and the funiculus dorsalis and funiculus ventralis. Three pigs (nos 4, 5 and 6) showed slight non-suppurative encephalitis in the medulla oblongata, with perivascular cuffing and focal gliosis. Pig 4 had a small necrotic focus with intranuclear inclusion bodies in the adrenal gland. No lesions were found in the non-infected control pig.



Immunohistochemistry

ADV antigen was observed in the intestinal specimens on PID 3 and 5, and in the solar ganglia on PID 3, 5 and 7. ADV antigen was closely associated with the karyorrhectic necrotic foci (Table 1). ADV antigen was found in the epithelial cells of the villi and crypts. Some was also associated with the dome of Peyer's patches, extending into the deeper regions of the lymphoid follicles (Fig. 5). A moderate amount of ADV antigen was detected in the degenerating neuronal cells of Meissner's (Fig. 6) and Auerbach's plexuses (Fig. 7), the duodenum and jejunum, solar plexus and ganglia (Fig. 8), and the thoracic-lumbar spinal ganglia. Pig 4 showed a small amount of ADV antigen in the adrenal gland. No other viral antigens (porcine rotavirus, PEDV or TGEV) were detected in any pigs.

Discussion

The pathogenesis of experimental ADV is variable, depending on the viral strain, age of the pig, size of the inoculum and route of infection (Kluge *et al.*, 1992). In the present intestinal infections with ADV, the pigs did not develop diarrhoea or nervous symptoms but had characteristic necrotizing enteritis and myenteric plexitis, accompanied by follicular necrosis in the Peyer's patches. The intestinal necrotic lesions closely resembled those described in previous reports of experimentally (Narita *et al.*, 1984; Zhao *et al.*, 1996; Narita *et al.*, 1998) and naturally (Ezura *et al.*, 1995) infected pigs.

Immunohistologically, ADV antigen was demonstrated first on PID 3 in the submucosa of the dome area, the lymphatic follicles of the Peyer's patches, the neuronal cells of Meissner's and Auerbach's plexuses, and the solar plexus and its ganglia. It was subsequently detected in the cells of the thoracic spinal ganglia. The distribution of ADV antigen was closely associated with the necrotic foci, suggesting that ADV replication led to cell death. Moreover, the distribution of ADV antigen in the small intestine resembled that observed in closed intestinal loops inoculated with ADV (Zhao *et al.*, 1996; Narita *et al.*, 1998).

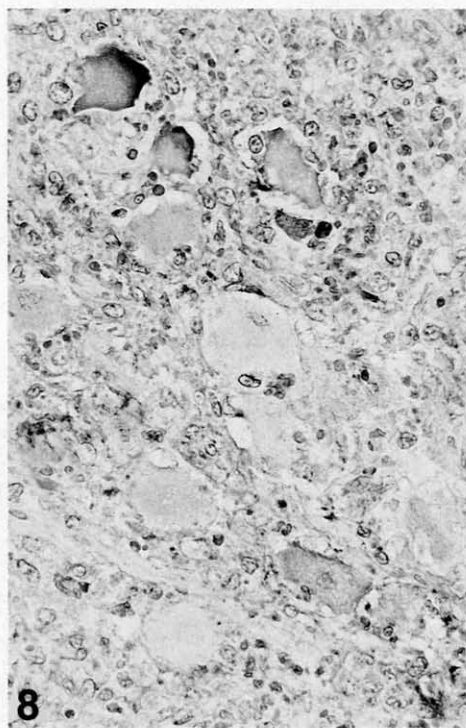
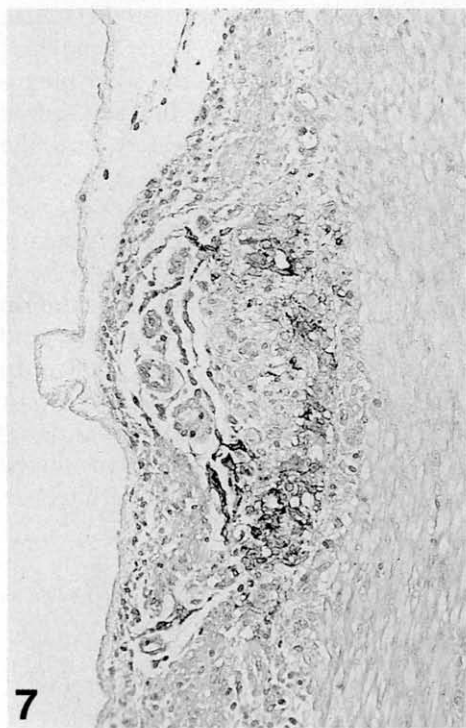
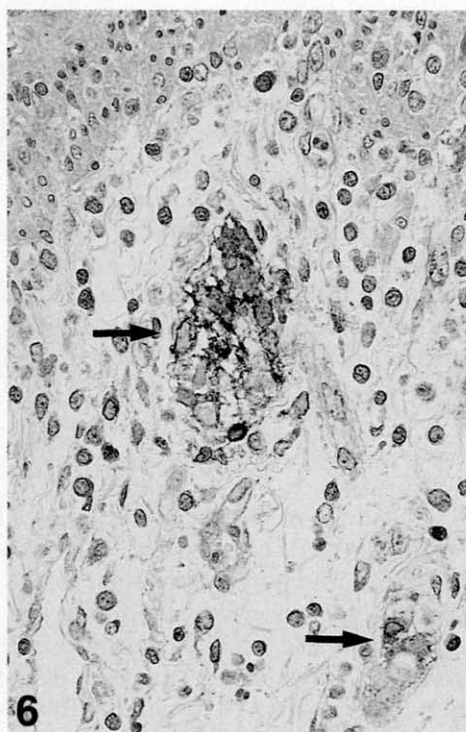
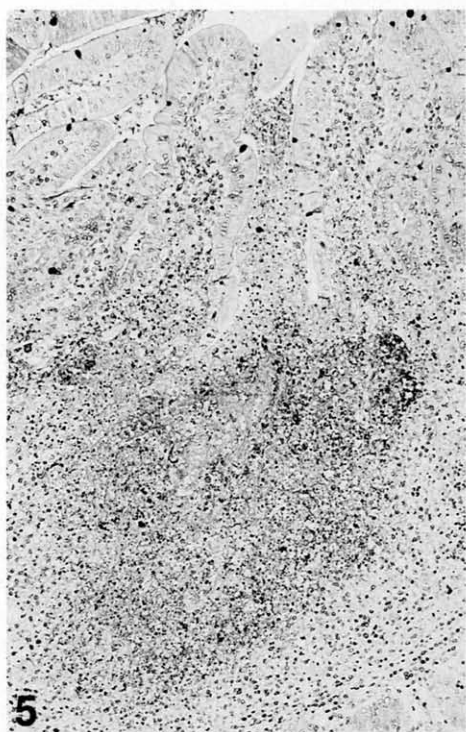
In-vivo experiments suggest that herpes viruses migrate from the inoculation site along peripheral nerves towards the associated peripheral ganglia, and then proceed to the corresponding segments of the CNS (Irie *et al.*, 1989). In ADV infection in piglets, necrotizing enteritis and myenteric plexitis occur (Narita *et al.*, 1984; Ezura *et al.*, 1995) in addition to encephalitis (Olander *et al.*, 1966; Rajcani *et al.*, 1969; Sabo *et al.*, 1969). The neuronal lesions produced in the present study suggested that ADV spread from the myenteric plexuses

Fig. 1. Karyorrhectic necrotic foci in the dome area of Peyer's patch in the jejunum of pig 3 killed on PID 5. HE. $\times 100$.

Fig. 2. Degeneration of neuronal cells (short arrows) and inclusion body (long arrows) in the Meissner's plexus in the jejunum of pig 4 killed on PID 5. HE. $\times 400$.

Fig. 3. Necrosis of the cells in solar ganglion of pig 4 killed on PID 5. HE. $\times 400$.

Fig. 4. Glial cell accumulation and perivascular cuffing in the thoracic spinal cord in pig 3 killed on PID 5. HE. $\times 100$.



via the solar plexus and ganglia, and travelled to the spinal ganglia as far as the dorsal and ventral horns of the thoracic-lumbar spinal cord. Thus, it would appear that ADV spreads from the intestinal mucosae to the CNS via autonomic nerves.

Many enteropathogenic viruses, such as PEDV (Pospischil *et al.*, 1981; Ducatelle *et al.*, 1982), porcine rotavirus (Pearson and McNulty, 1977; Narita *et al.*, 1982; Collins *et al.*, 1989) and TGEV (Hooper and Haelterman, 1969; Shepherd *et al.*, 1979), when injected oro-nasally into pigs, produce severe gastroenteritis and villous atrophy; however, infected villous epithelial cells are replaced rapidly as epithelial cells migrate from the crypts of Lieberkühn. In the present study, the pigs inoculated intestinally with ADV showed characteristic necrotizing enteritis in the jejunum, and necrotic foci in the dome area of Peyer's patches extended into the lymphoid follicles and the myenteric plexuses. Such lesions can therefore be taken to suggest the presence of enteropathogenic ADV in pigs.

Acknowledgments

We thank Mr M. Kobayashi and Ms M. Simada for preparing the histopathological sections, and Dr Y. Ando and Mr T. Fujisawa for the photographs.

References

- Bergmann, V. and Becker, C.-H. (1967). Untersuchungen zur pathomorphologie und pathogenese der Aujeszky'schen krankheit. *Pathologica Veterinaria*, **4**, 97-119.
- Collins, J. E., Benfield, D. A. and Duimstra, J. R. (1989). Comparative virulence of two porcine group-A rotavirus isolates in gnotobiotic pigs. *American Journal of Veterinary Research*, **50**, 827-835.
- Corner, A. H. (1965). Pathology of experimental Aujeszky's disease in piglets. *Research in Veterinary Science*, **6**, 337-343.
- Ducatelle, R., Coussement, W., DeBouck, P. and Hoorens, J. (1982). Pathology of experimental CV777 coronavirus enteritis in piglets. I. Histological and histochemical study. *Veterinary Pathology*, **19**, 46-56.
- Ezura, K., Usami, Y., Tajima, K., Komaniwa, H., Nagai, S., Narita, M. and Kawashima, K. (1995). Gastrointestinal and skin lesions in piglets naturally infected with pseudorabies virus. *Journal of Veterinary Diagnostic Investigation*, **7**, 451-455.
- Fukusho, A., Shimizu, M., Kubo, M., Nanba, K., Shimizu, Y., Konno, S., Suzuki, K. and Otaki, T. (1981). The first outbreak of Aujeszky's disease in swine in Japan. II. Virus isolation. *Bulletin of the National Institute of Animal Health*, **82**, 5-11.
- Hooper, B. E. and Haelterman, E. O. (1969). Lesions of the gastrointestinal tract of pigs infected with transmissible gastroenteritis. *Canadian Journal of Comparative Medicine*, **33**, 29-36.
- Irie, H., Harada, Y., Yoshihashi, H., Kitamura, T., Kojima, M., Kataoka, M., Saito, M., Sugawara, Y. and Mori, W. (1989). Spread of herpes virus type 1 (Miyama + G

Fig. 5. ADV antigen in the dome area of Peyer's patch shown in Fig. 1. ABC-IP. $\times 100$.

Fig. 6. ADV antigen in the neuronal cells in the Meissner's plexus (arrows) shown in Fig. 2. ABC-IP. $\times 400$.

Fig. 7. ADV antigen in Auerbach's plexus in pig 4. ABC-IP. $\times 200$.

Fig. 8. ADV antigen in the cells of the solar ganglion shown in Fig. 3. ABC-IP. $\times 200$.

- C strain) to the central nervous system after intraperitoneal inoculation: the role of the myenteric plexus of the gut. *Archives of Virology*, **105**, 247–257.
- Kluge, J. P., Beran, G. W., Hill, H. T. and Platt, K. B. (1982). Pseudorabies (Aujeszky's disease). In: *Disease of Swine*, 7th Edit., S. D'Allaire and D. J. Taylor, Eds, Iowa State University Press, Ames, pp. 312–323.
- McFerran, J. B. and Dow, C. (1965). The distribution of the virus of Aujeszky's disease (pseudorabies virus) in experimentally infected swine. *American Journal of Veterinary Research*, **26**, 631–635.
- Narita, M., Fukusho, A. and Shimizu, Y. (1982). Electron microscopy of the intestine of gnotobiotic piglets infected with porcine rotavirus. *Journal of Comparative Pathology*, **92**, 589–597.
- Narita, M., Imada, T. and Haritani, M. (1991). Immunohistological demonstration of spread of Aujeszky's disease virus via the olfactory pathway in HPCD pigs. *Journal of Comparative Pathology*, **105**, 141–145.
- Narita, M., Kubo, M., Fukusho, A., Haritani, M. and Moriwaki, M. (1984). Necrotizing enteritis in piglets associated with Aujeszky's disease virus infection. *Veterinary Pathology*, **21**, 450–452.
- Narita, M., Zhao, Y. M., Kawashima, K., Arai, S., Hirose, H., Yamada, S. and Ezura, K. (1998). Enteric lesions induced by different pseudorabies (Aujeszky's disease) virus strains inoculated into closed intestinal loops of pigs. *Journal of Veterinary Diagnostic Investigation*, in press.
- Olander, H. J., Saunders, J. R., Gustafson, D. P. and Jones, R. K. (1966). Pathologic findings in swine affected with a virulent strain of Aujeszky's virus. *Pathologica Veterinaria*, **3**, 64–82.
- Pospischil, A., Hess, R. G. and Bachmann, P. A. (1981). Light microscopy and ultrahistology of intestinal changes in pigs infected with enzootic diarrhea virus (PED): comparison with transmissible gastroenteritis (TGE) virus and porcine rotavirus infections. *Zentralblatt für Veterinärmedizin B*, **28**, 564–577.
- Pearson, G. R. and McNulty, M. S. (1977). Pathological changes in the small intestine of neonatal pigs inoculated with a pig reovirus-like agent (rotavirus). *Journal of Comparative Pathology*, **87**, 363–375.
- Rajcani, J., Sabo, A. and Blaskovic, D. (1969). Studies on the pathogenesis of Aujeszky's disease. II. The distribution of virus after subcutaneous inoculation. *Acta Virologica*, **13**, 52–59.
- Sabo, A., Rajcani, J. and Blaskovic, D. (1969). Studies on the pathogenesis of Aujeszky's disease. III. The distribution of virulent virus in piglets after intranasal infection. *Acta Virologica*, **13**, 407–414.
- Shepherd, R. W., Gall, D. G., Butler, D. G. and Hamilton, J. R. (1979). Determinates of diarrhea in viral enteritis. The role of ion transport and epithelial changes in the ileum in transmissible gastroenteritis in piglets. *Gastroenterology*, **76**, 20–24.
- Zhao, Y. M., Narita, M. and Kawashima, K. (1996). Pathologic changes in closed porcine intestinal loops inoculated with Aujeszky's disease virus. *Journal of Veterinary Medical Science*, **58**, 809–810.

[Received, September 26th, 1997]

[Accepted, February 12th, 1998]