



Since January 2020 Elsevier has created a COVID-19 resource centre with free information in English and Mandarin on the novel coronavirus COVID-19. The COVID-19 resource centre is hosted on Elsevier Connect, the company's public news and information website.

Elsevier hereby grants permission to make all its COVID-19-related research that is available on the COVID-19 resource centre - including this research content - immediately available in PubMed Central and other publicly funded repositories, such as the WHO COVID database with rights for unrestricted research re-use and analyses in any form or by any means with acknowledgement of the original source. These permissions are granted for free by Elsevier for as long as the COVID-19 resource centre remains active.

# **NEONATAL NECROTIZING ENTEROCOLITIS: PATHOGENESIS, CLASSIFICATION, AND SPECTRUM OF ILLNESS**

Although hundreds of new and important investigations have been published on the epidemiology and pathophysiology of neonatal necrotizing enterocolitis (NEC) in the last decade, NEC remains a disease of unknown etiology. Originally reported in the literature in the later part of the 19th century, neonatal NEC has stimulated increased interest with the advent of modern neonatal intensive care units (NICUs) during the 1960s.<sup>144, 171, 183</sup> Because of this disease's propensity to affect low-birth-weight infants in neonatal intensive care units, clinicians hypothesized that some factor or factors associated with the care of sick premature infants caused or initiated the disease. This hypothesis generated a search for multiple risk factors that were purported to contribute to the etiology of NEC. Early hypotheses suggested chorioamnionitis and swallowed pathogenic bacteria at birth as additional risk factors. Finally an observation that almost all infants with NEC were fed milk formula prior to the illness focused attention on neonatal feeding practices, including the composition of the formula, total daily volume, and the rate at which feedings were increased. In the 1980s we began to realize that neonatal NEC is a complex, and probably multifactorial, disease. Nonetheless, the pathogenesis has yet to be determined.

Among hospitalized premature infants in neonatal intensive care units NEC is the most common serious acquired gastrointestinal tract disease.<sup>31, 110</sup> Indeed in a recent study from the Medical Center Hospital of San Antonio (Texas), which included 31,000 births, NEC followed immediately behind respiratory distress syndrome (RDS) as a significant cause of neonatal mortality at that center.<sup>27</sup> Respiratory distress syndrome was the presumptive cause of death in 7% while NEC accounted for 6% of deaths.<sup>27</sup> As a cause of intestinal perforation NEC exceeds gastrointestinal obstruction, spontaneous perforation of the bowel, Hirschsprung's disease, feeding tube accidents,

and meconium ileus.<sup>10</sup> In the United States approximately 2,000 to 4,000 newborn infants each year develop NEC.<sup>31, 110</sup> Although many of these infants develop the disease in an NICU during the course of treatment of the diseases common to all premature infants, an increasing number of patients are developing NEC or a NEC-like illness in level I well-baby nurseries in community hospitals.

In addition to being aware that the patient population at risk is no longer limited to the sick premature infant, we also have begun to realize that NEC may present as a broad spectrum of disease manifestations and severity.<sup>110</sup> The spectrum extends from mildly affected patients with abdominal distention and hematochezia to severely ill patients who appear septic and develop bacteremia, disseminated intravascular coagulation, intestinal perforation, peritonitis, and shock.<sup>110</sup> The majority of infants with NEC, regardless of severity, share the radiologic findings of pneumatosis intestinalis or hepatic portal venous gas. Both roentgenographic signs are relatively specific for NEC and are helpful in confirming the diagnosis (see below). Furthermore, NEC may occur as an endemic or sporadic disease or may occur as intermittent epidemics superimposed on the endemic rate. In either form of disease, bacterial, viral, or fungal agents are isolated from some patients but not others.<sup>106, 107</sup>

Prior investigations have not always taken the spectrum of disease or other associated covariables into consideration in investigations of the epidemiology, etiology, or outcome of NEC. These variables confound studies and can make it difficult to determine whether NEC is caused by a single agent or whether the gastrointestinal symptoms noted in NEC are a nonspecific end-organ response to multiple agents or factors. Just as pneumonia is manifested as an infiltrate on a chest roentgenogram, regardless of whether the underlying etiology is viral, bacterial, fungal, parasitic, allergic, vasculitic, or a foreign body, so may the neonatal bowel respond to a variety of injurious agents with only a few stereotypic patterns of manifestation, of which NEC is the most common.

This monograph reviews current understanding of the epidemiology and pathogenesis of NEC. Topics related to neonatal gastrointestinal physiology are discussed that are relevant to the proposed etiologic factors for NEC, including enteric alimentation, gastrointestinal ischemia, and gastrointestinal infectious diseases. A system is presented to help classify the various different subgroups of disease patterns that present as NEC. In addition, an expanded staging system that combines systemic signs, intestinal signs, and radiologic findings is discussed. With the use of these staging criteria, appropriate therapy can be initiated that corresponds to the severity of the stage of NEC.

## EPIDEMIOLOGY

Neonatal NEC is predominantly a disease of premature infants that develops during their hospitalization in a level III NICU.<sup>78, 80, 107, 171, 205</sup> Nonetheless, approximately 7% to 10% of patients are not premature, but are full-term infants admitted to the NICU for cyanotic heart disease, diarrhea, polycythemia, or antecedent anatomical intestinal malformations.<sup>107, 160</sup> Some of these more mature infants have had operative palliation of cyanotic heart disease or repair of congenital gastrointestinal tract anomalies.

Recently, we and others have observed NEC developing in babies in level I nurseries. These patients were either previously healthy full-term infants or "larger" premature infants. This latter group includes premature infants who were "reverse transferred" back to a level I nursery from a level III NICU. These premature infants were recovering from the usual diseases of prematurity and most of these infants required only additional time and nutritional care to "gain and grow." The other group of premature infants who have developed NEC in level I nurseries are those who were thought to be well enough (on the basis of size, ability to feed, and the absence of significant cardiopulmonary disease) to remain in a well-baby nursery. It is important to emphasize that in addition to infants with documented classical NEC, other infants in these nurseries simultaneously have also developed milder gastrointestinal disturbances, often characterized by abdominal distention, occult blood, or frank hematochezia.<sup>176</sup>

Among patients who develop NEC in level III neonatal units, the average birth weight is 1,400 to 1,500 gm, and mean gestational age is usually 30 to 32 weeks.<sup>106-113</sup> When compared with the general population of infants with neonatal problems admitted to the same intensive care nursery, there are usually no differences in birth weight or gestational age for patients with and without NEC. Thus, it would appear that the disease affects premature infants in the NICU indiscriminately.

The incidence of NEC varies from nursery to nursery and region to region. Even within the same residency training center in the same city serving four major hospitals, the incidence of NEC varies between NICUs. Some of this variation may be due to intermittent epidemics of NEC superimposed on a baseline endemic or sporadic rate of one to two cases every 1 to 3 months. Nonetheless, many large pediatric hospitals report no outbreaks of neonatal NEC.

The overall annual incidence of NEC in tertiary level neonatal intensive care units is usually between 2% and 7%.<sup>31, 106-113</sup> The average reported incidence is 5%. However, these data have many potentially confounding factors. Most investigations of the incidence of neonatal

have developed NEC on the first day of life. These infants tend to be more mature, have no history of being fed, do not always demonstrate pneumatosis intestinalis, and may be born to women with preeclampsia.<sup>107</sup> In contrast to patients who develop NEC on the first day of life, the usual interval between the initiation of feeding and the onset of NEC is between 6 and 7 days.<sup>113</sup> In these patients, enteric alimentation was usually begun on the second to fifth day of life.

As stated previously, there are two distinct patterns of neonatal NEC occurrence: endemic and epidemic. We and others have observed endemic or sporadic cases of neonatal NEC, such as none to two patients with disease during a 1- to 3-month time period. Superimposed on this endemic rate may be intermittent epidemics of cases clustered in location and time.<sup>107, 145</sup> At our institution there have been years with fewer than six cases that have been interrupted by a 1-month epidemic of 10 to 12 cases of neonatal NEC. Although seasonal epidemics have been suggested, there is a paucity of evidence that suggests a consistent relationship between NEC and seasonality.<sup>175</sup>

Patient characteristics appear to be different during clustered cases of NEC. Epidemic patients tend to be older or more mature, have fewer antecedent neonatal diseases, develop NEC later, and have been fed for a longer period of time than patients with endemic NEC.<sup>107, 145</sup>

In the past, epidemics have been thought to be related to overcrowding in the NICU, to suboptimal nurse-to-patient ratios, or to large numbers of "very sick" infants. Nevertheless, these hypotheses have not been proved. We were unable to document any changes in patient acuity or crowding during previous epidemics at our institution.

No association has been found between necrotizing enterocolitis and race, sex, or inborn vs. transport status. On rare occasions, NEC has been reported in siblings during different pregnancies. Nonetheless, most studies do not demonstrate familial or genetic factors that predispose patients to this disease. Twin status has been investigated among patients with neonatal NEC. In an earlier report from our hospital, 13 of 123 patients with NEC were from multiple gestations.<sup>107</sup> Of these infants, in only one set of twins did both infants develop NEC within 24 hours of each other. Both infants also had bacteremia with identical *Escherichia coli*. Multiple gestation is a common cause of prematurity and the incidence of twins among patients with neonatal NEC is not different than the incidence of twins in the general population of premature infants who do not develop NEC. In a study of NEC among multiple gestations, Samm and colleagues investigated the epidemiology of NEC in twins and demonstrated that the firstborn "A" twin was always the twin to

NEC report the total number of cases of NEC in an NICU, and compare that with the total number of patients admitted to that unit. This includes many severely ill, premature infants who die in the first three days of life due to complex cardiorespiratory diseases. The vast majority (over 90%) of patients who develop neonatal NEC do so after the initiation of enteric alimentation with milk feedings. Thus, by including infants who die before a time when NEC would usually develop, these figures underestimate the incidence of NEC in the population at risk. The remaining at-risk group consists of the surviving premature infants who are ready to initiate enteric milk feedings. If infants who die early are excluded and only infants who have been fed are included, the incidence of NEC in level III NICUs approaches 15%.<sup>113</sup>

Although the mean gestational age or birth weight of patients with NEC is similar to the usual demography of the individual nursery, some authors feel that the incidence of NEC is higher among the smaller premature infants than among larger preterm patients.<sup>211, 212</sup> The incidence from their studies decreases as weight increases, from patients below 1,000 gm, to those between 1,001 and 1,500 gm, and to those above 1,500 gm. Nonetheless, because there are more patients who are admitted and who survive with birth weights above 1,000 gm, the weight group at greatest risk for NEC is usually between 1,000 and 1,500 gm.

An explanation for the more frequent occurrence of NEC in smaller infants is the time needed to achieve postnatal intestinal maturity. A premature infant born at 27 weeks may not develop a mature intestine until a gestational age of 36 to 40 weeks. This infant requires an additional 9 to 13 weeks of extrauterine or postnatal life to develop mature gastrointestinal defense mechanisms and digestive function. It has been demonstrated that the onset of NEC may be delayed among very immature infants.<sup>211, 212</sup> These infants may be susceptible for a longer time than larger premature infants who are more mature at birth and therefore need a shorter period to achieve gut maturity. Alternate explanations for the older age at onset among less mature infants could be (1) a delay in initiating enteral alimentation in smaller, sicker premature infants; (2) a longer period of exposure to NICU practices; or (3) a longer period of exposure to abnormal microbial flora, either endogenous fecal flora or that of the NICU environment.

The mean day of onset of necrotizing enterocolitis is day 12 of life.<sup>106-113</sup> The median day is the seventh day of life, while the most common day (mode) was the third day of life. Infants may present with disease from the first to the 99th day of their hospitalization. It has been proposed that more mature infants born closer to term develop NEC much sooner after the initiation of enteric alimentation than less mature infants. Although a rare occurrence, some infants

develop NEC.<sup>182</sup> This was unexpected, because these authors hypothesized that the "B," or second twin, was at greater risk for development of NEC due to increased perinatal stresses such as asphyxia. Prior to the onset of NEC it was thought that "A" twins were more stable than their paired "B" twin. Furthermore, as will be discussed in detail later, the "A" twin may have been fed sooner and more rapidly than the sicker "B" twin.

Risk factors for neonatal NEC will be discussed in more detail under the sections on feeding, ischemia, and infection. Nonetheless, it is important to note that many infants who develop NEC are similar to those "A" twins reported by Sann and associates.<sup>182</sup> They are usually healthy "low-risk" infants who have mild antecedent illnesses and receive enteric alimentation early during the course of their hospitalization. They are often the "gainer and grower" in the convalescent rather than the acutely ill premature infant receiving respiratory support and multiple medication infusions in the sickest area of the neonatal intensive care unit. Between 10% to 30% of patients who develop NEC have no identifiable risk factors other than prematurity.<sup>106, 154</sup> Indeed, the whole concept of risk factors for NEC was generated by descriptive epidemiology without a comparative control group. Thus, early reports of the preceding illnesses associated with infants who develop NEC included low Apgar scores, hypothermia, RDS, patent ductus arteriosus, anemia, and umbilical artery catheterization. These are problems common to all patients in the NICU and may not be specific risk factors for neonatal NEC. When carefully designed controlled studies were performed and patients with neonatal NEC were matched with control patients by gestational age, it became evident that there are few, if any, antecedent identifiable risk factors that are consistently found to be more frequent in patients with NEC than in the general population of premature infants in that NICU during the specific time of study.

## **DISEASE CHARACTERISTICS**

### *Diagnosis and Pathology*

Neonatal NEC is characterized by a broad spectrum of clinical manifestations resulting in a wide range of severity, complications, and mortality. The disease may present with mild signs and symptoms, such as mild abdominal distention and retained gastric aspirates. On the other hand, the infant may present with marked abdominal distention, tenderness, shock, and signs of peritonitis, and rapidly progress to gastrointestinal perforation and death within 24 hours of the onset of the illness. The latter presentation may be indistinguishable from the acute, fulminant manifestations of neonatal

sepsis. The diagnosis of neonatal NEC will be considered only after more specific gastrointestinal manifestations have been identified.

Nonspecific signs of NEC may also be found in many neonatal diseases, such as sepsis, hypoglycemia, and intraventricular hemorrhage. These signs include apnea, bradycardia, lethargy, temperature instability, poor cutaneous circulation, and a "septic" appearance (Table 1). More specific findings related to gastrointestinal dysfunction include, in order of decreasing frequency, abdominal distention, abdominal tenderness, the presence of occult or frank blood in the stools, anterior abdominal wall erythema, and a right lower quadrant mass. When these latter manifestations are present the diagnosis of NEC must be considered and a thorough evaluation performed (see Table 1).

The hallmark for the diagnosis of NEC is documentation of abnormal intestinal gas production as evidenced by pneumatosis intestinalis or hepatic venous portal gas on plain roentgenograms of the abdomen<sup>102, 183, 187</sup> (Figs 1–6). Macroscopically, pneumatosis intestinalis appears as small, grape-sized, gas-filled submucosal or subserosal cysts that may be present from the ileum to the rectum (see Fig 1). The presence or degree of involvement on roentgenogram does not predict the severity of the disease, but the presence of pneumatosis intestinalis is essential in confirming the diagnosis of NEC. Pneumatosis intestinalis is often confused with the bubbly intraluminal appearance of gas mixed with meconium in the meconium ileus syndrome. Furthermore, blood mixed with intraluminal gas may produce similar bubbles (see Figs 4 and 5). True pneuma-

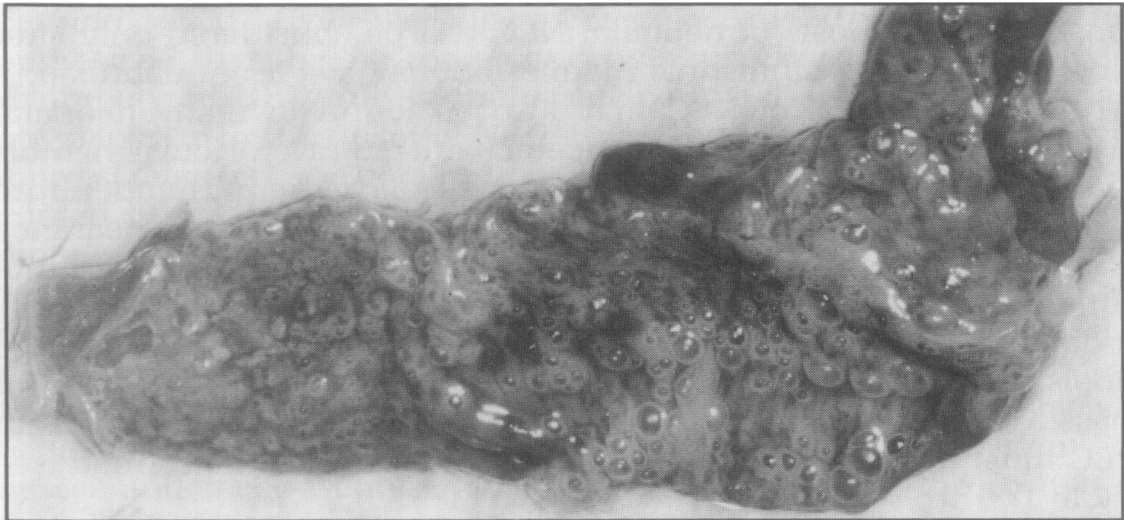
TABLE 1.  
Signs of Necrotizing Enterocolitis

---

Specific
Abdominal distention
Abdominal tenderness
Occult or frank blood in stool
Bilious emesis
Gastric aspirates
Abdominal wall erythema
Right lower quadrant mass
Diarrhea
Nonspecific
Apnea and bradycardia
Shock
Lethargy
Acidosis
Temperature instability
Cyanosis
Acidosis

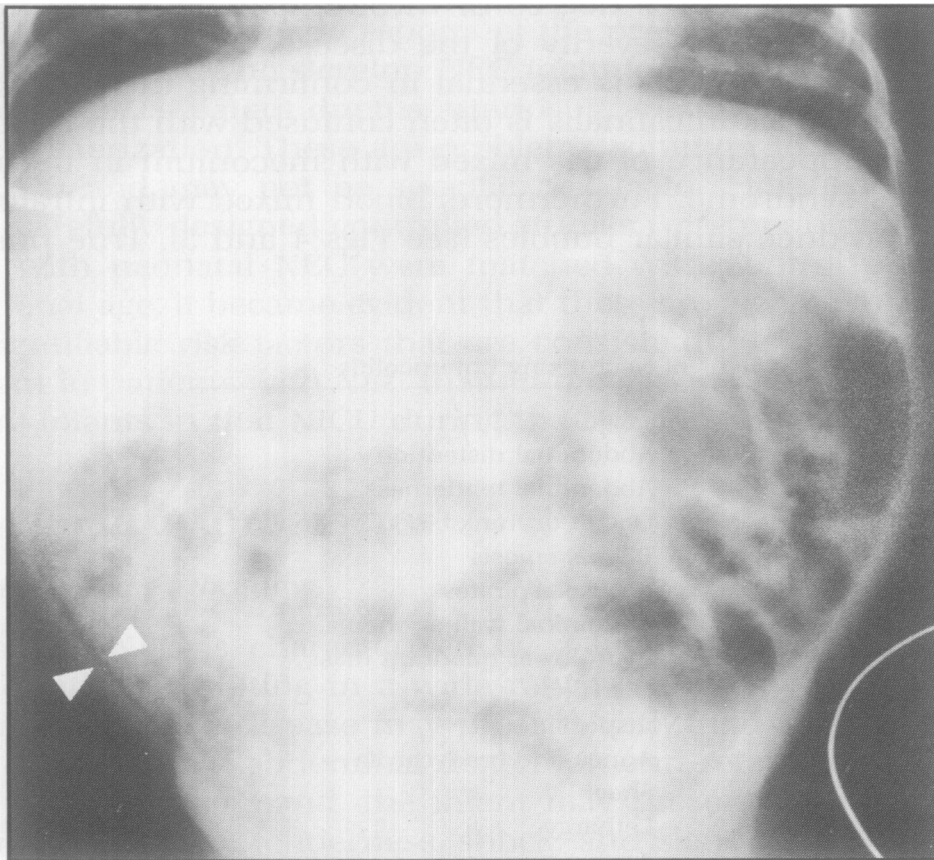
---





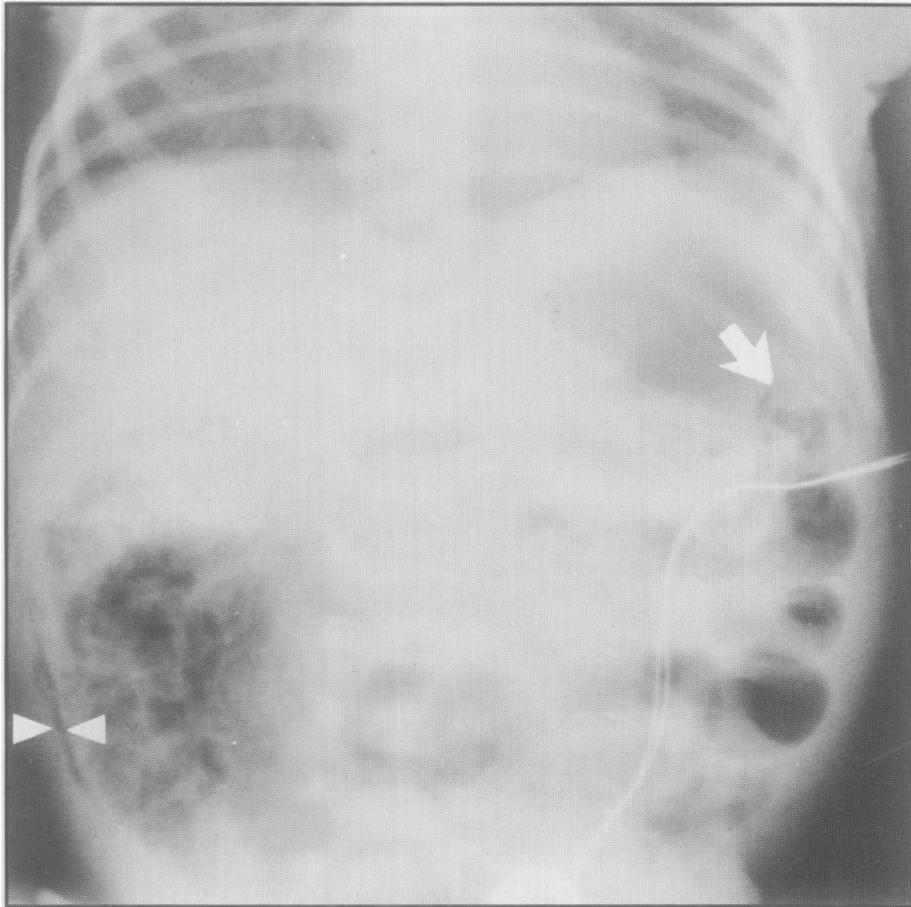
**FIG 1.**

Resected specimen placed under water at the time of laparotomy to demonstrate pea-sized bubbles or cysts of pneumatosis intestinalis. (From Walsh MC, Kliegman RM: Necrotizing enterocolitis: Treatment based on staging criteria. *Pediatr Clin North Am* 1986; 33:179. Used by permission.)



**FIG 2.**

Abdominal distention, dilated loop of bowel, and the linear pattern of pneumatosis intestinalis in the right lower quadrant (*arrowheads*) in a premature patient with NEC.



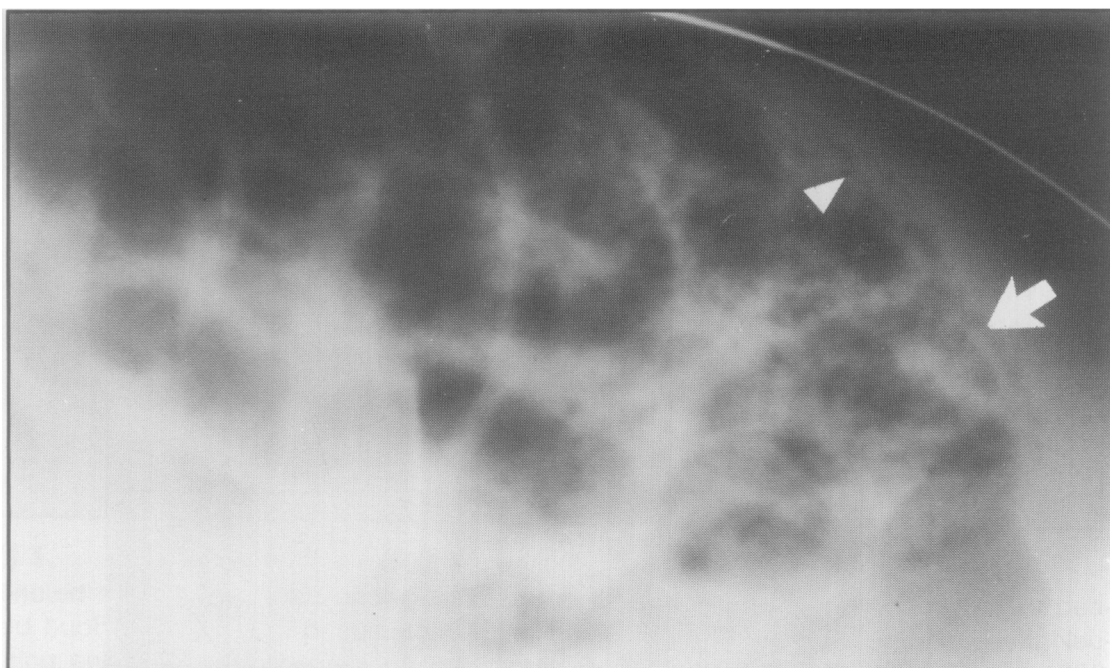
**FIG 3.**

Another patient with NEC demonstrating two areas of linear pneumatosis intestinalis (*arrowheads*) and a markedly abnormal bowel loop pattern (*arrow*) with distention.

toxis intestinalis appears as cystic lesions in a linear pattern along the outside of the bowel for various lengths, which are seen in both anterior-posterior and cross-table lateral roentgenographic positions. Hepatic portal venous gas appears as gas within the portal venous system of the liver. Although some studies have suggested that patients with hepatic gas have a more severe disease, other investigations have not been able to confirm this as a more serious sign of disease.<sup>33</sup>

The gas present within the cysts is composed of the bacterial fermentation products of malabsorbed formula, i.e., hydrogen, methane, and carbon dioxide.<sup>62</sup> As hydrogen cannot be produced by any known human pathway of metabolism and because bacteria that ferment carbohydrate are known to produce hydrogen, a causal relationship between intestinal bacteria and the etiology of NEC is suggested (see below).<sup>68</sup>

Although pneumatosis intestinalis is the hallmark of NEC, many patients who subsequently are documented as having NEC do not demonstrate pneumatosis intestinalis or hepatic venous gas on plain



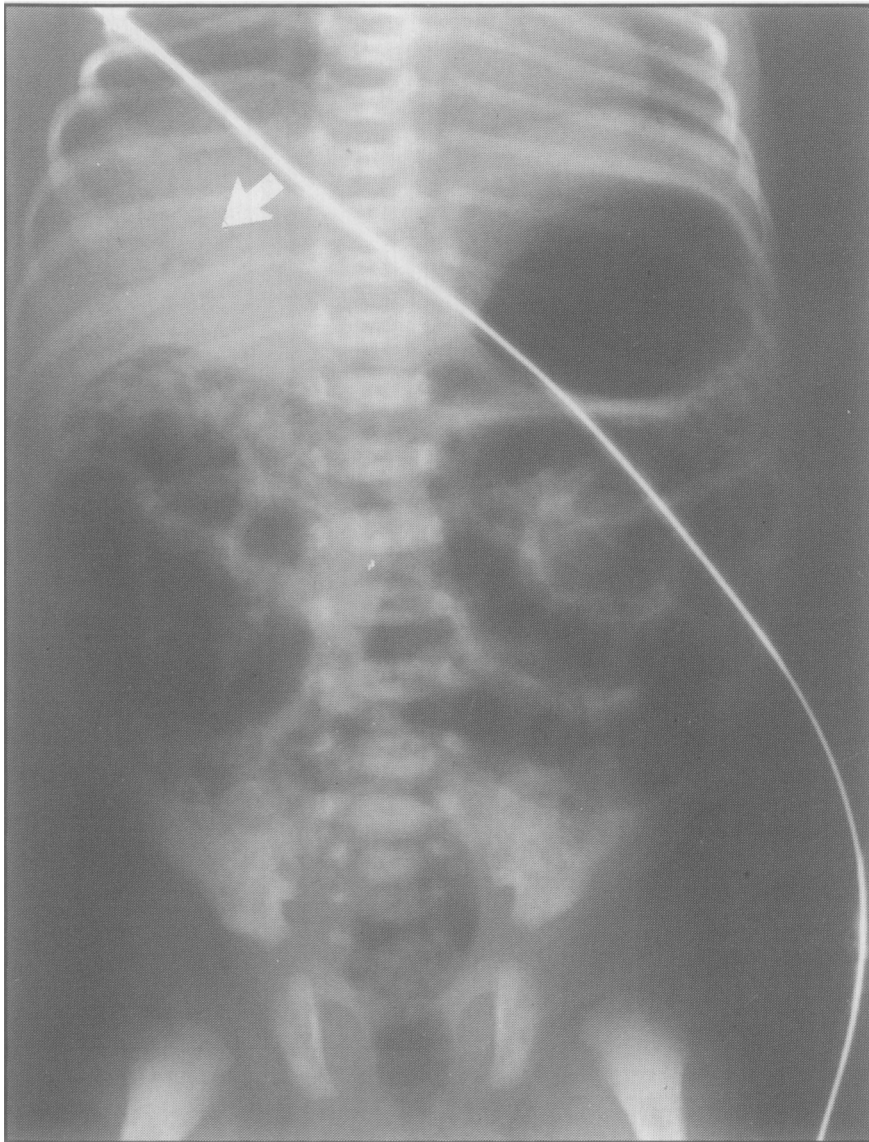
**FIG 4.**

Cross table lateral radiogram demonstrating pneumatosis intestinalis in a linear pattern (*arrow*) and the bubbly pattern (*arrowhead*). There is marked gastrointestinal distention with dilated loops of bowel.

roentgenogram of the abdomen.<sup>109</sup> In one study of patients with documented NEC, only 45% demonstrated pneumatosis intestinalis, and 17% had portal venous gas.<sup>108</sup> In a second study, 14% of patients with documented NEC did not have these roentgenographic signs.<sup>109</sup> Furthermore, when NEC is suspected there is often disagreement between observers on the interpretation of these roentgenograms as to the presence or absence of pneumatosis intestinalis.<sup>142</sup>

The diagnosis in many of these patients is confirmed at surgery following intestinal perforation and subsequently supported by the histopathologic evidence of NEC. Neonatal NEC is the most common cause of intestinal perforation in the NICU.<sup>10</sup> It is so common that the diagnosis of NEC should be seriously considered in any patient with evidence of pneumoperitoneum. Free gas within the abdomen is best visualized with a cross-table lateral x-ray film, as pneumoperitoneum is difficult to appreciate with the usual flat plate of the abdomen (Figs 7 and 8).

Some patients in whom NEC was not confirmed radiologically and who subsequently died have had the diagnosis substantiated at autopsy. The pathologic findings of NEC have been described, for obvious reasons, by examination of the sickest patients who died or who had intestinal perforation and resection of necrotic gangrenous bowel. Overall, 20% to 30% of patients with neonatal NEC will develop intestinal perforation. The overall mortality is also between 20% and 40%. Thus, pathologic examinations have been available for

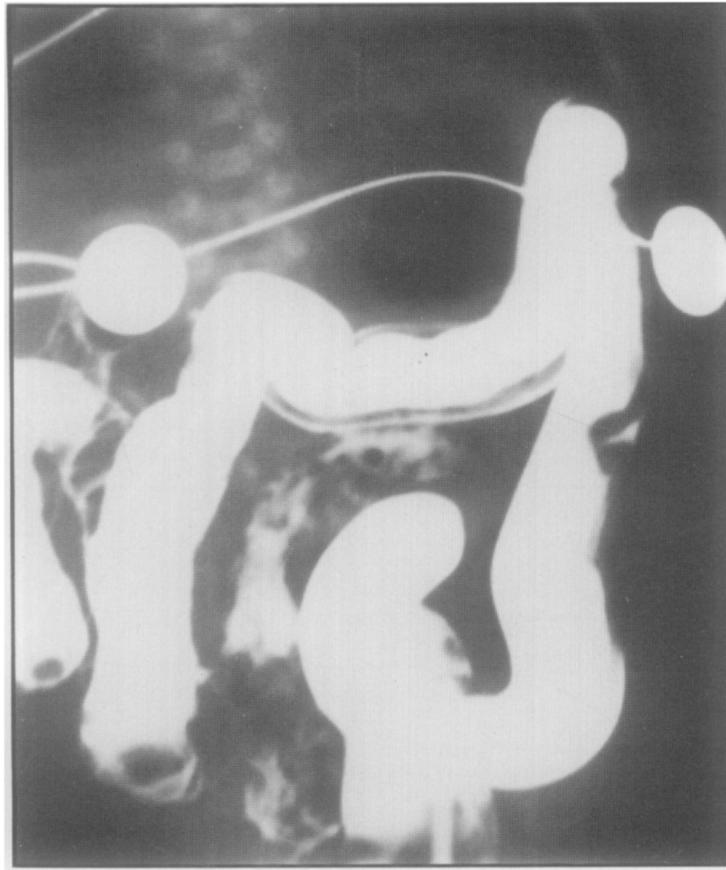


**FIG 5.**

Radiograph demonstrating distention, bubbly pattern of pneumatosis intestinalis or blood mixed with gas in the bowel lumen and the hepatic venous gas pattern (*arrow*).

fewer than 50% of the cases with NEC and, again, all of these patients were seriously ill.

The gross pathologic examination of patients with NEC reveals involvement predominantly in the terminal ileum and proximal colon.<sup>14, 51, 99, 183, 200</sup> More severe cases demonstrate extensive involvement with abnormalities of the bowel noted from the stomach to the rectum. The bowel is distended and edematous and the bowel wall width is attenuated, while the lumen contains hemorrhagic fluid. There are obvious areas of hemorrhage within the bowel wall, mixed with green to black areas of frank gangrene. In most but not all patients, submucosal and subserosal gas-filled cysts are observed macroscopically. In addition to the changes of the bowel wall there



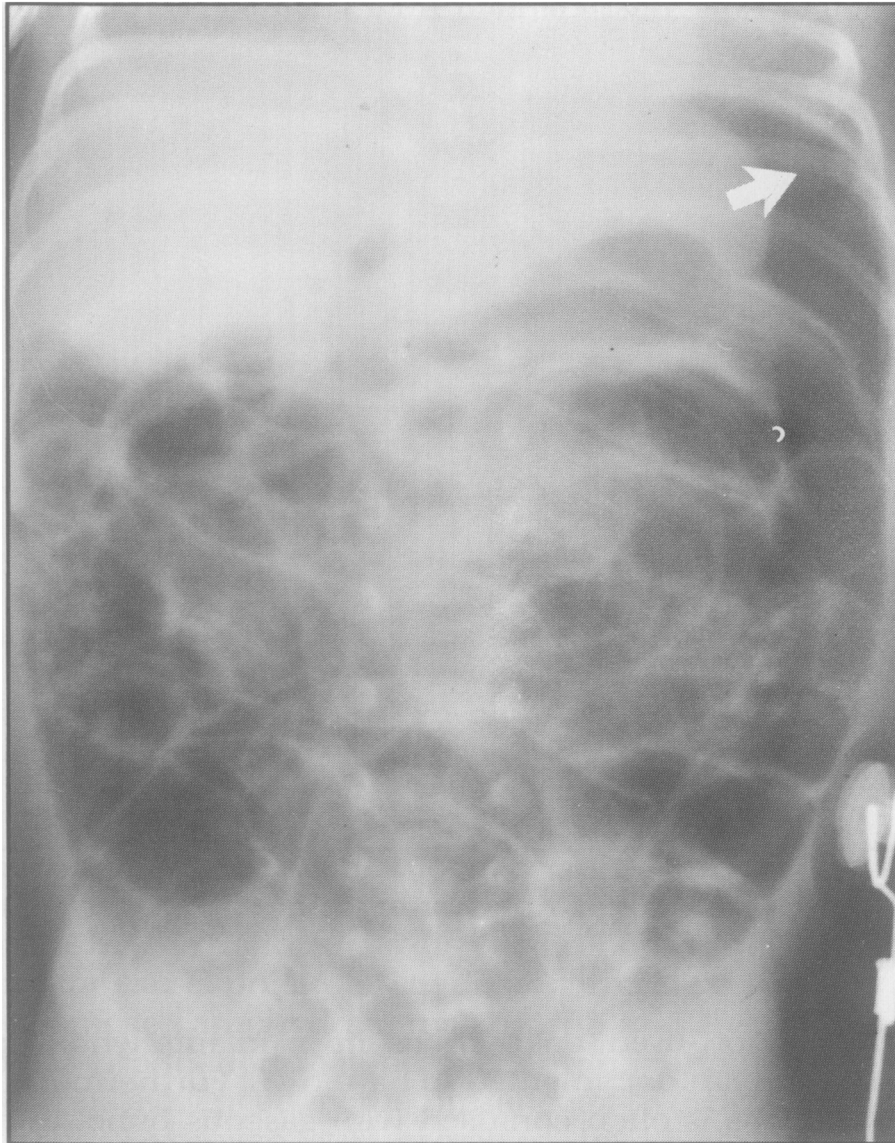**FIG 6.**

Contrast enema in a child with distention and bloody stools demonstrating pneumatosis intestinalis predominantly along the transverse colon.

are often signs of fibrinous to purulent peritonitis and ascites. With solitary or multifocal intestinal perforation, fecal material will also stain the peritoneal surfaces of the bowel.

Microscopic examination of intestine from these severely affected patients reveals mucosal edema, hemorrhage, coagulation necrosis, and mucosal ulceration covered with a diphtheritic-like pseudomembrane of necrotic debris and fibrin.<sup>14, 51, 99, 183, 200</sup> Although NEC is initially a mucosal disease, severe cases demonstrate transmural coagulation necrosis and gangrene, which may result in intestinal perforation. Previous investigators often could not differentiate the severe coagulation necrosis from postmortem autolysis; however, it is well established that coagulation necrosis is typical of the bowel pathology of neonatal NEC. Large or even small arterial or venous thrombosis of the mesenteric or other vascular system is not commonly noted in patients with neonatal NEC.

Cystic gas-filled lesions are often seen in the early stages of the disease. Bacteria may be present within the cyst or outside the cyst wall. Gas may be produced locally by bacteria in contact with the cyst or gas may dissect into the submucosa from intraluminal gas



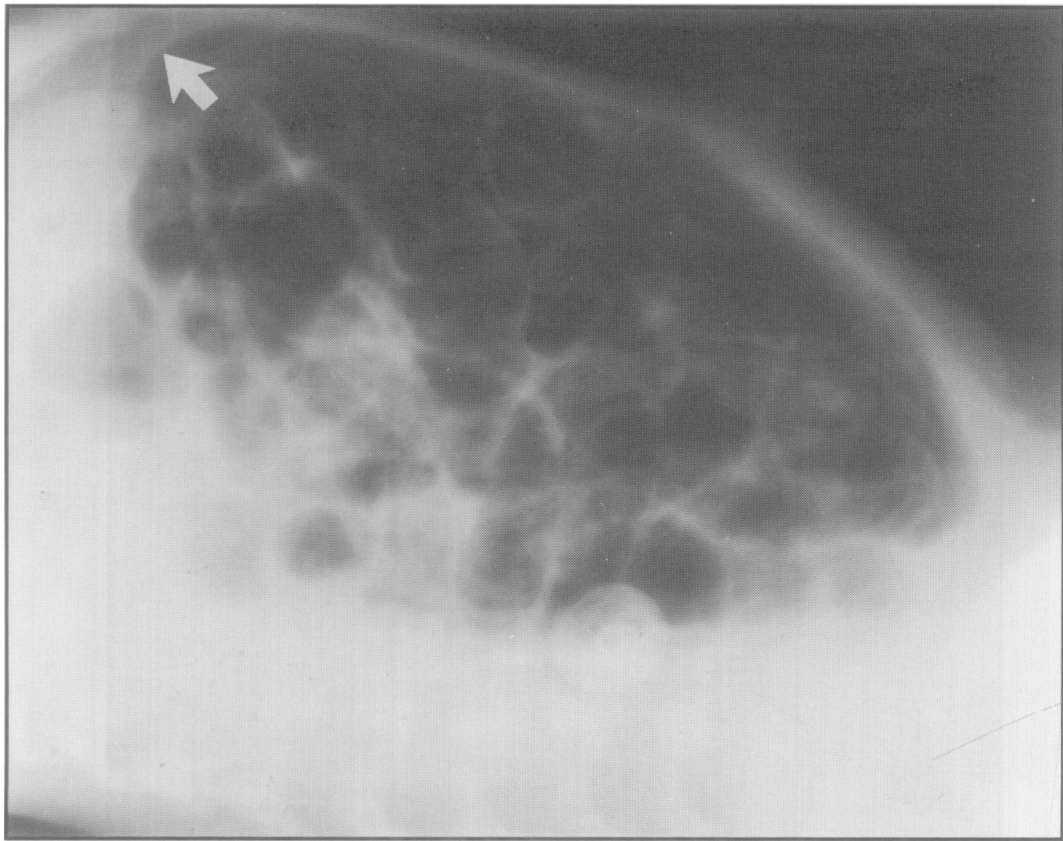
**FIG 7.**

Free intraperitoneal gas as demonstrated on an anterior-posterior film. Note gas around the edge of the liver (*arrow*) and the appearance of gas on both sides of the bowel wall, or double lumen sign.

production and overdistention of the intestinal lumen.<sup>62</sup> Although bacterial gas production is associated with cyst formation and bacteria may be seen along the cyst wall and within the luminal cellular debris, histologic examination of involved tissue often reveals a paucity of inflammatory cells and eosinophils.

Interestingly, reparative processes are often noted juxtaposed to areas of severe involvement.<sup>99</sup> Repair may be evident by the observation of fibrosis and epithelial proliferation (see below for discussion of post-NEC strictures) during the acute stage of the disease.<sup>99</sup>

Pneumatosis intestinalis is currently required to confirm the diagnosis of NEC. However, as we have discussed, this radiologic sign



**FIG 8.**

Pneumoperitoneum as demonstrated by a cross table lateral radiogram. Note the gas above the liver (*arrow*).

may be subtle, short-lived, or even absent in infants who at pathologic examination are documented to have NEC. Furthermore, pneumatosis intestinalis is often confused with gaseous bubbles in stool or blood within the bowel lumen.<sup>142, 163</sup> Clearly, additional specific and sensitive diagnostic tests need to be developed to separate patients who have neonatal NEC from those with more benign neonatal gastrointestinal disturbances.<sup>133, 142, 163</sup> Several new diagnostic methods are emerging that may add to our ability to detect the presence of pneumatosis intestinalis and portal venous gas. Upper gastrointestinal tract series with metrizamide contrast studies have helped to identify gaseous blebs even before they were detectable on plain roentgenograms.<sup>101</sup> Although metrizamide is isotonic, safe, and without reported complications, we should remain cautious about the use of this agent until further experience has been reported. Ultrasonographic demonstration of hepatic portal venous gas has been a new, safe, and more sensitive method of detecting "microbubbles" of gas that are below the resolution of the plain abdominal x-ray film. Malin and co-workers<sup>139</sup> originally described an incidental finding of "microbubbles" entering the heart from below the diaphragm in a child who developed fulminant NEC.<sup>139</sup> Subsequent reports

studied additional patients with neonatal NEC and demonstrated a characteristic ultrasonographic pattern of intermittent "microbubbles" within the portal vein of the liver. In some patients plain x-ray films showed no evidence of portal gas or pneumatosis intestinalis. This method holds great promise as a new and sensitive tool for the diagnosis of the abnormal intestinal gas production in NEC.<sup>190</sup> The usefulness of ultrasound to detect intravascular gas must be interpreted with caution in patients with intravenous infusions in the lower extremity. "Microbubbles" generated with such infusions may result in false-positive signs of intravascular gas. Ultrasound is not helpful in diagnosing pneumatosis intestinalis because the gaseous distention of the bowel greatly interferes with the ability to identify mucosal cysts. Additional radiologic tests to diagnose NEC include radionucleotide scans with a radiolabel tagged to leukocytes or platelets.<sup>84</sup> Although these new methods hold some promise, there is concern about the dose of radioactive label and the overall sensitivity and specificity of these scans. Much more work is required to define the lowest (safest) radioactive dose possible and to determine the false-positive and false-negative rate.

Another means to detect abnormal enteric bacterial gas production is to measure the excretion of hydrogen by the respiratory system.<sup>68, 157</sup> Undigested lactose enters the large colon where bacteria ferment this substrate to organic acids and hydrogen gas. After production by the intestinal bacteria, hydrogen gas is absorbed into the circulation by the venous plexus of the bowel and transported to the lungs for excretion. Breath hydrogen excretion is a well accepted test to diagnose carbohydrate malabsorption. Because excessive hydrogen gas production may be part of the pathophysiology of neonatal NEC, as evidenced by the presence of hydrogen gas in the mucosal blebs, hydrogen gas excretion has been proposed as a potentially useful tool to diagnose NEC. Kirschner et al.<sup>104</sup> have demonstrated increased breath hydrogen excretion in a few patients with NEC. However, other studies were unable to confirm the specificity of this test for neonatal NEC as many well premature infants demonstrate excessive and prolonged breath hydrogen excretion following a lactose-containing formula feeding. Newborn infants often demonstrate a persistently elevated hydrogen excretion with no additional increase after, or fall before, the subsequent feeding. Breath hydrogen levels as high as 70 to 100 ppm have been noted in normal preterm infants. Hydrogen production is dependent on formula malabsorption plus bacteria that can ferment lactose to this gas. As some bacteria do not produce hydrogen gas, this test may not be helpful in every case of NEC. Infants who have NEC but do not demonstrate pneumatosis intestinalis may also have bacteria that do not produce hydrogen gas and thus do not develop mucosal blebs.<sup>62</sup>

D-Lactate is another fermentation product generated by the intes-



tinal flora. This unusual organic acid is not produced by humans and may be a marker for abnormal rates of colonic bacterial fermentation. Garcia and colleagues were able to demonstrate increased urinary excretion of D-lactate in nine infants with NEC.<sup>69a</sup> Nonetheless, this test, as well as enzyme markers such as hexosaminidase, require special methods and much further testing with larger numbers of patients with documented NEC before the true usefulness of their application can be determined.<sup>167</sup>

Examination of tissue to confirm the diagnosis of NEC is available from all patients who have intestinal perforation and resection of the involved segments of bowel. Obviously these patients have more serious disease as evidenced by the presence of transmural necrosis and perforation. The histopathologic findings in these patients may represent a combination of events, e.g., those that initiated NEC and those subsequent to perforation and secondary bacterial invasion or peritonitis. Thus the initiating event or its pathological picture may be masked in those patients undergoing intestinal resection or those seen at autopsy. Furthermore, the majority of patients with NEC do not require exploratory laparotomy because they do not have severe disease that results in perforation. In an attempt to provide useful information on the pathogenesis of NEC and to provide possible diagnostic criteria for this disease, many authors have studied endoscopy and, on occasion, mucosal biopsy. Because NEC is predominantly (in the early stages) a mucosal disease, colonic or rectal mucosal biopsy may provide useful diagnostic information for both clinicians and epidemiologic investigators. Preliminary data from Graham demonstrated severe colitis in a few patients thought to have neonatal NEC.<sup>76</sup> Subsequently, Taxman and co-workers<sup>201</sup> investigated 41 newborn infants with rectal bleeding of unknown etiology and ten infants with documented NEC with flexible proctosigmoidoscopy and colonic mucosal biopsy.<sup>201</sup> Ninety percent of all the patients (NEC and non-NEC patients) demonstrated colitis of varying severity by endoscopic visualization. Involvement varied from mild erythema and edema to severe ulceration, exudation, spontaneous hemorrhage, and friability. Half of the total population demonstrated biopsy evidence of allergic colitis with mucosal eosinophilia. Eosinophilic infiltration was also found in patients with biopsy evidence of a severe inflammatory response with inflammatory cell infiltration of the lamina propria.<sup>201</sup> Interestingly, the blood eosinophil count, the endoscopic appearance of the mucosa, the severity of mucosal inflammation, or the presence of eosinophilic infiltration did not differentiate patients with NEC from those with rectal bleeding of unknown etiology. Although Silber and Klish<sup>191</sup> and others have found that sigmoidoscopy or colonoscopy with biopsy is helpful in differentiating allergic from nonspecific colitis in older infants with rectal bleeding, we cannot recommend its use in neonates with

NEC.<sup>38, 47, 191</sup> Colonoscopy may be beneficial in a few newborn infants with persistent rectal bleeding of unknown etiology because a specific diagnosis may be made and specific therapy can be initiated, especially in the presence of allergic colitis.<sup>38, 47, 191</sup>

## STAGING BASED ON CLINICAL MANIFESTATIONS

Earlier, the broad range of severity of neonatal NEC was discussed. The spectrum includes a mild or benign form of neonatal NEC with no sequelae and excellent prognosis. However, neonatal NEC may also present as an acute fulminant process mimicking septic shock, with serious sequelae and a high mortality. The sequelae may include transmural intestinal necrosis, peritonitis, and even necrotic gangrene and distention of the gallbladder.<sup>181</sup> Usually, the severity of the clinical course that NEC will follow is uncertain during the first 24 hours of the illness. However, during the next day the severity of the disease process can be more accurately estimated. It is very unusual for an appropriately treated infant manifesting mild signs of NEC for 24 to 48 hours, to suddenly deteriorate and develop septic shock and intestinal perforation. Thus, an infant with slight abdominal distention, mild abdominal tenderness, and pneumatosis intestinalis, which persists for 24 to 48 hours, but who has no neutropenia, acidosis, thrombocytopenia, or hypotension, is unlikely to advance to a more serious stage. Without therapy, and with continued stress of the gastrointestinal system by enteric feedings, a mild illness may progress to a more serious stage. On the other hand, most patients with severe NEC worsen rapidly and manifest an exquisitely tender abdomen, acidosis, neutropenia, thrombocytopenia, shock, and bacteremia within 24 to 48 hours of onset. Indeed the mean time for development of documented intestinal perforation in these seriously ill patients is 36 hours, while the median time is less than 24 hours and the mode or most frequent time of perforation is less than 12 hours after the onset of symptoms.<sup>108</sup>

Investigations of the therapy and pathogenesis of NEC have been hindered by the failure to uniformly define the severity of the disease at the time of diagnosis. Just as there are grades of severity of neonatal intraventricular hemorrhage, NEC should be staged according to the severity of the systemic, gastrointestinal and radiologic signs. Specific grading criteria will permit accurate comparisons of patients with disease of similar severity. Staging according to severity will also be useful in guiding therapeutic decisions (see following). We have modified Bell's initial staging criteria and included systemic, intestinal, and radiographic signs to present uniform and consistent descriptive and therapeutic criteria for neonatal NEC<sup>12</sup> (Table 2).

Stage I includes infants who are suspected or "rule-out" NEC pa-

**TABLE 2.**  
**Modified Bell's Staging Criteria for Neonatal Necrotizing Enterocolitis\***

STAGE	SYSTEMIC SIGNS	INTESTINAL SIGNS	RADIOLOGIC SIGNS	TREATMENT
IA—Suspected NEC	Temperature instability, apnea, bradycardia, lethargy	Elevated pregavage residuals, mild abdominal distention, emesis, guaiac-positive stool	Normal or intestinal dilation; mild ileus	Nothing by mouth, antibiotics for 3 days pending cultures
IB—Suspected NEC	Same as above	Bright red blood from rectum	Same as above	Same as above
IIA—Definite NEC, mildly ill	Same as above	Same as above <i>plus</i> diminished or absent bowel sounds with or without abdominal tenderness	Intestinal dilation, ileus, pneumatosis intestinalis	Nothing by mouth, antibiotics for 7–10 days if examination is normal in 24–48 hours
IIB—Definite NEC, moderately ill	Above <i>plus</i> mild metabolic acidosis and mild thrombocytopenia	Above <i>plus</i> definite abdominal tenderness, with or without abdominal cellulitis, or right lower quadrant mass, absent bowel sounds	Same as stage IIA with or without portal vein gas, with or without ascites	Nothing by mouth, antibiotics for 14 days, NaHCO <sub>3</sub> for acidosis
IIIA—Advanced NEC, severely ill, bowel intact	Same as stage IIB <i>plus</i> hypotension, bradycardia, severe apneas, combined respiratory and metabolic acidosis, disseminated intravascular coagulation, neutropenia, anuria	Above <i>plus</i> signs of generalized peritonitis, marked tenderness, distention of abdomen, and abdominal wall erythema	Same as stage IIB, definite ascites	Same as above <i>plus</i> 200 + ml/kg fluids, fresh frozen plasma, inotropic agents, intubation, ventilation therapy, paracentesis, surgical intervention if patient fails to improve with medical management within 24–48 hr
IIIB—Advanced NEC, severely ill, bowel perforated	Same as stage IIIA	Same as stage IIIA	Same as stage IIB <i>plus</i> pneumoperitoneum	Same as above <i>plus</i> surgical intervention

\*Adapted from Bell MJ, Ternberg JL, Feigin RD, et al: Neonatal necrotizing enterocolitis: Therapeutic decisions based upon clinical staging. *Ann Surg* 1978; 187:1–7.

tients. These infants have mild systemic signs or symptoms such as temperature instability, apnea, bradycardia, or lethargy. Intestinal manifestations are not specific and include mild abdominal distention, elevated gastric aspirate volume, emesis, and occult blood in the stool. Radiologic signs demonstrate nonspecific ileus with or without intestinal dilation. It should be noted that the first radiologic sign of neonatal NEC is not necessarily pneumatosis intestinalis or free abdominal gas, but rather dilated loops of bowel.

Some stage I infants, referred to as stage IB, also demonstrate bright red blood per rectum. Although these infants may have NEC in the absence of pneumatosis intestinalis, other diagnostic possibilities need to be considered and include milk protein allergy; swallowed maternal blood; lymphonodular hyperplasia; nonspecific colitis; infectious colitis caused by *Salmonella*, *Shigella*, or *Campylobacter*; and true anatomical problems, such as Meckel's diverticulum, midgut volvulus, and intussusception.

Most infants without frank hematochezia (stage IA) probably have diseases other than NEC. In all probability many of these patients have neonatal feeding intolerance and not a serious gastrointestinal illness. Nonetheless, it should be emphasized that during epidemics of well-documented neonatal NEC the prevalence of stage IA and IB disease also increases in parallel with the prevalence of true neonatal NEC.<sup>176</sup> This again underscores the wide spectrum of the illness, which may appear as an apparently benign condition without specific radiographic findings or as a more severe gastrointestinal disease with definitive radiologic signs.

Stage II is definite neonatal NEC confirmed by the relatively specific radiologic signs of pneumatosis intestinalis.<sup>134, 168</sup> Stage IIA is similar to stage IB except that pneumatosis intestinalis is present and the patient may manifest diminished to absent bowel sounds and abdominal tenderness. Stage IIA has also been reported and classified as benign neonatal pneumatosis coli (see following section on classification).<sup>168</sup>

CASE 1.—A white baby girl (twin A), was born weighing 1,370 gm, after a 31-week gestation. The mother was a 25-year-old primigravida. Pregnancy was uncomplicated until the onset of premature labor. Twins were delivered by cesarean section. Apgar scores were 7 at 1 minute and 8 at 5 minutes in both infants. The early neonatal course was complicated by mild respiratory distress syndrome, which required supplemental inspired oxygen. Maximum oxygen requirement was 35%, administered by hood. She was in room air by day 4 of life. Feedings were begun on day 3 of life and increased by 40-cc/kg/day increments. On day 8, lethargy, abdominal distention, bilious nasogastric drainage, and guaiac-positive stools developed. A complete evaluation for sepsis was performed. The white blood cell (WBC) count was 14,800 with 40% polymorphonuclear forms, and 10% band forms. Lumbar puncture was unremarkable, as was an arterial blood gas analysis. An anterior-posterior portable roentgenogram of the abdomen revealed a

discrete area of pneumatosis intestinalis in the descending colon, with generalized distention of the bowel. The cross-table lateral examination showed no free air. The infant was given nothing by mouth (NPO), the bowel was decompressed with nasogastric drainage, and intravenous administration of ticarcillin and gentamicin was started. Serial complete blood cell counts and blood gas analyses were performed, and cross-table lateral roentgenograms of the abdomen were performed every 6 hours. The leukocyte count was stable. Twelve hours after the acute onset, an x-ray showed the pneumatosis to be resolved. The infant clinically was more alert, but still had mild tenderness to abdominal palpation. She appeared completely well 48 hours after presentation. She was treated with bowel rest and intravenous antibiotics for 10 days. Feedings were resumed with an elemental formula and increased to 150 cc/kg/day over 10 days without difficulty. The infant was discharged to home weighing 2.0 kg at 9 weeks' chronologic age, 2 1/2 weeks after her sibling was discharged."

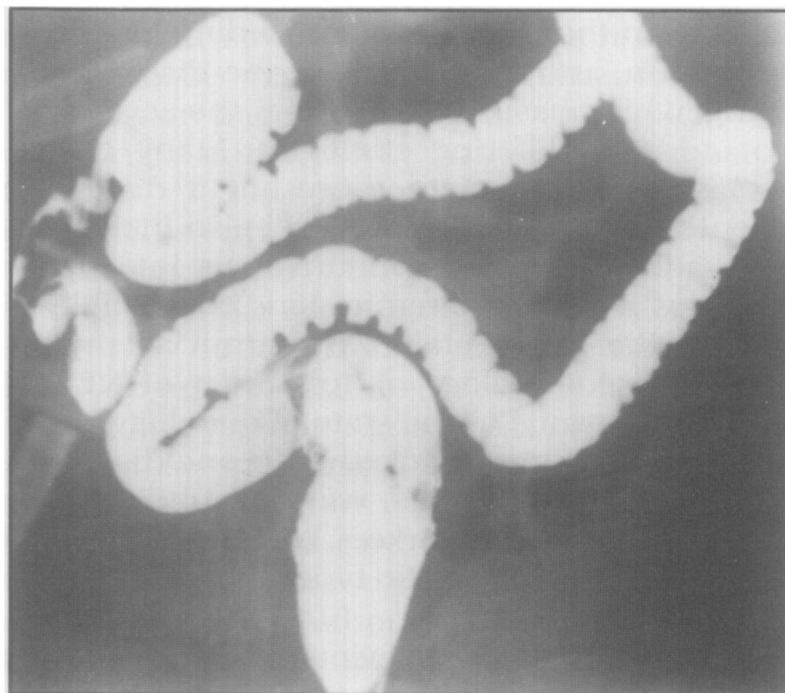
Stage IIB patients are moderately ill and have more advanced disease than patients with benign NEC in stage IIA. In stage IIB, a mild metabolic acidosis or thrombocytopenia may be present in addition to more serious abdominal signs, such as abdominal wall cellulitis or a right lower quadrant mass. The latter represents matted loops of inflamed bowel or, more rarely, a sealed-off microperforation of the terminal ileum with local peritonitis. Portal venous gas may be present in stage IIB in addition to ascites.

Advanced neonatal NEC has the greatest risk for intestinal perforation, adverse long-term sequelae and death. Stage IIIA consists of severely ill patients without evidence of intestinal perforation who often, but not always, progress to intestinal perforation, which defines stage IIIB. These seriously ill infants manifest hypotension, acidosis, apnea, respiratory failure, disseminated intravascular coagulation, thrombocytopenia, and neutropenia. Abdominal examination reveals a rigid, tender abdomen, even prior to perforation. More mature infants with stage IIIA NEC lie still with their legs motionless, as every slight movement elicits pain. Radiologic studies of stage IIIA infants often demonstrate a gasless abdomen or floating bowel and distended flanks, suggestive of tense ascites, while the signs of free gas in the abdomen predominate among infants with stage IIIB NEC.

CASE 2.—A black baby boy was born weighing 1,580 gm, after a 34-week gestation. The mother was a 22-year-old woman, whose pregnancy had been complicated only by premature labor. The infant was delivered vaginally. Apgar scores were 7 at 1 minute and 9 at 5 minutes. There was no respiratory distress. Evaluation for sepsis was unrevealing, however ampicillin and gentamicin were administered until negative culture results were available. No umbilical catheterization was performed. The infant began oral feedings on day 3 of life and advanced to 140 cc/kg/day over 72 hours. The infant developed abdominal distention and stool positive for reducing substances. Feedings were discontinued. The infant then developed hematochezia, bilious gastric drainage, lethargy, apnea, and bradycardia. Stools be-

came progressively melanotic and, finally, frankly bloody. The abdomen was markedly distended and tender to palpation. Hematocrit fell over the next 6 hours from 38% to 31% while the WBC count rose from 15,100 to 31,300. Platelets were then 150,000. An anterior-posterior roentgenogram of the abdomen revealed distended loops of bowel with extensive pneumatosis intestinalis. Cross-table lateral examination at this time showed no free air. Serial arterial blood gas analyses revealed a mixed respiratory and metabolic acidosis. The infant was intubated and placed on mechanical ventilation. Following culture of the blood and spinal fluid, intravenous ticarcillin and gentamicin were administered. Pediatric surgical consultation was obtained and followed with serial examinations. Serial cross-table lateral roentgenograms, complete blood cell counts, and arterial blood gas analyses were performed every 4 hours. Twelve hours after presentation, a cross-table roentgenogram revealed a pneumoperitoneum. The infant was taken immediately to the operating room where a gangrenous perforated bowel was found. Twenty centimeters of terminal ileum and ascending colon were resected, and a colostomy and ileostomy were created. Postoperatively, the infant required volume resuscitation to counteract third-space fluid losses. Disseminated intravascular coagulation responded to therapy with fresh-frozen plasma and platelet transfusions. The infant remained NPO and received intravenous ticarcillin and gentamicin for a total of 14 days. He was supported with hyperalimentation during this period. Extubation was performed on postoperative day 4.

Feedings were cautiously initiated on day 5, and advanced slowly over the next 2 weeks. The infant tolerated this without complications. Four weeks following the acute illness, a barium study revealed a 3-cm stricture proximal to the ostomy site (Fig 9). The infant underwent resection of the



**FIG 9.**

Stricture formation in right lower quadrant. Patient presented with obstipation, distention, and emesis.

stricture and reanastomosis of bowel. He was discharged home to be cared for by his pediatrician with consultation by his pediatric surgeon and neonatologist. When seen at follow-up at 8 months, he had a normal motor and mental developmental examination, and normal growth parameters.

Progression from stage IIA to further stages is extremely rare. Nonetheless, stage IIB and, more often, stage IIIA, may progress to intestinal perforation within 12 to 48 hours of onset. We have cared for patients who had stage IIIA neonatal NEC, who developed a gasless abdomen with ascites. Ascites persisted for 5 to 7 days before gastrointestinal perforation was documented on radiologic examination. These patients were atypical because, as stated earlier, most infants with neonatal NEC suffer perforation within 48 hours after the onset of symptoms.

### **CLASSIFICATION OF NEONATAL NECROTIZING ENTEROCOLITIS**

Through the use of staging criteria we can gain a better appreciation of the wide range of severity of neonatal NEC. In addition to staging the severity of the disease process, there is an additional need to classify NEC according to the clinical patterns of this disease.<sup>110</sup> Necrotizing enterocolitis has been reported to present with different, but characteristic, clinical patterns. Furthermore, many neonatal gastrointestinal illnesses are not NEC but may mimic NEC, and need to be considered in the differential diagnoses. We propose to subdivide NEC on the basis of the preceding historical events, the clinical presentation, and the pattern of the disease. This is not the same as staging, which basically considers the severity of the illness, but does not address differing etiologies. Many of the subgroups within this classification system represent a distinct clinical and pathological entity. This classification will also include illnesses that are clinically distinct, and have pneumatosis intestinalis and more or less severe intestinal and systemic signs compatible with classical NEC. Such a classification system will permit accurate comparison of studies on the epidemiology or treatment of NEC. The present situation may be analogous to the state of oncology in previous years when all leukemia was lumped together in one disease category. Today, using sophisticated methods, we can subdivide the leukemias on the basis of cell type, cell markers, and other properties. Specific treatment protocols for the specific types of leukemia have increased survival from this serious illness.

Classical NEC, as described previously, presents within a broad spectrum of severity, but also has a typical clinical course. Furthermore, there are both endemic or sporadic and epidemic cases of classical NEC. Endemic (sporadic) cases occur infrequently, are

not clustered in place or time, and have no common pathogen isolated from patient materials. Epidemic NEC is common in some NICUs.<sup>83, 107, 145</sup> In an epidemic, the severity of the illness is usually similar among patients. Epidemics of mild or severe disease have been witnessed at the same neonatal intensive care unit at different time periods. During epidemics of well-documented NEC there is often an increased incidence of other neonatal gastrointestinal or systemic diseases. Hemorrhagic colitis, without pneumatosis intestinalis, is a milder form of gastrointestinal disease than NEC. Hemorrhagic colitis is characterized by frank, bright red blood per rectum and minimal abdominal distention. In one study of an epidemic of neonatal NEC due to rotavirus A, there was also an increased prevalence of hemorrhagic colitis.<sup>176</sup> Other investigators have also noted concomitant epidemics of NEC and hemorrhagic colitis caused not by rotavirus A, but by an unidentified infectious agent. Additionally, NEC due to enterovirus has been reported during neonatal intensive care unit epidemics.<sup>120</sup> In this report, NEC was only one manifestation of enteroviral disease; other patients manifested viral sepsis, myocarditis, or hepatitis.

Because of the complexity and possible multifactorial etiology of NEC it is important that future reports of NEC provide data on the endemic vs. epidemic nature of this disease. As discussed previously, it appears that the patient populations in whom neonatal NEC develops during epidemic periods differ from the patient populations seen during endemic periods.<sup>145</sup> Furthermore, our own experience suggests that covariable factors, such as enteric alimentation practices, probably have a greater influence on patients with endemic NEC than on patients during an epidemic.

One distinct clinical entity of NEC has been called benign neonatal pneumatosis coli.<sup>134, 168</sup> This is a mild condition, corresponding to stage IIA disease. This entity characteristically occurs in larger, more mature, or even term infants who present with bright red blood per rectum. An abdominal flat-plate x-ray film reveals pneumatosis intestinalis, which may be localized to the rectosigmoid region. Leonidas and Hall<sup>134</sup> originally described seven infants with this typical constellation of mild systemic signs, gross bright red blood per rectum, and pneumatosis intestinalis limited to distal colonic areas.<sup>134</sup> Patients subsequently reported with this mild variant usually responded to standard medical care within 24 hours. Intestinal perforation or other signs of serious disease have never been reported in patients with benign NEC. Although colonic stricture is a very remote possibility, it is very uncommon following benign NEC. Overall the prognosis for this milder form of NEC is excellent.

Necrotizing enterocolitis following exchange transfusion also appears to have a distinct clinical presentation and clinical course.<sup>45, 100, 155, 187</sup> These patients are also larger at birth and of a



more mature gestational age than the usual newborn infant with classical NEC. Most require exchange transfusion for ABO incompatibility or Rh group disease during the first week of life. They usually have no other medical problems except for the possible concomitant occurrence of anemia, often associated with the severe forms of hemolysis. Almost all of the exchange transfusions were performed through the umbilical vessels, usually the umbilical vein and rarely the umbilical artery. Studies in preterm infants have demonstrated marked changes of heart rate and blood pressure during withdrawal and infusion of transfused blood during the exchange transfusion.<sup>203</sup> Studies in newborn mammals have demonstrated shunting of blood away from the portal and mesenteric circulations alternating with marked increases of portal venous pressure during a simulated exchange transfusion. These data suggest that the changes of both blood pressure and flow during the exchange process or the location of the catheter tip may result in mesenteric ischemia. Necrotizing enterocolitis often presents acutely within 12 to 24 hours after the exchange transfusion.<sup>45, 100</sup> Sudden onset of abdominal distention precedes intestinal perforation that occurs commonly in these patients. The pathologic finding is often localized to a small area of the colon, which is very suggestive of an embolic phenomenon. Unless there is acute perforation or colonic surgery, the morbidity and mortality are usually low among patients with NEC following exchange transfusion. Despite evidence of a relationship between exchange transfusion and NEC, covariables may also be important in the etiology of NEC in these infants. Shapiro et al.<sup>187</sup> described an epidemic of NEC associated with an enteritis of unknown etiology affecting other neonatal patients.<sup>187</sup> A single transfusion team had performed 269 exchange transfusions in several wards in a hospital. Necrotizing enterocolitis occurred following exchange transfusion only in infants in one ward, in which a diarrhea epidemic occurred. Similar observations were made by Karayalcin and co-workers in upstate New York,<sup>100</sup> where a clustering of cases of NEC occurred in patients undergoing exchange transfusion.<sup>100</sup> Although NEC following exchange transfusion appears to affect a specific population of infants and appears to follow a typical pattern, additional variables may predispose these infants to more serious gastrointestinal disease.

Agents that cause intestinal mucosal injury may also cause a disease characterized by pneumatosis intestinalis and other features similar to classical NEC. These will be discussed in more detail in the following section on pathogenesis, specifically related to neonatal feeding practices. Nonetheless, hypertonic formula feeding, polycythemia, chronic nonspecific diarrhea, and administration of drugs may all have direct or indirect effects on mucosal integrity. In addition, the role of cow's or soy milk protein allergy in neonatal eosin-

ophilic colitis should be considered as another etiologic variable in an unusual subgroup of patients with NEC.<sup>6,189</sup> Typically, patients with milk protein allergy are older infants between 2 to 6 months of age who manifest anemia, occult or gross blood loss in the stool, and other signs of allergic phenomena such as eczema, gastroesophageal reflux, or wheezing.<sup>72</sup> These infants develop a direct immune response toward milk protein with immunologic injury to specific organs, such as the colon.<sup>149,206</sup> Few, if any, of these full-term patients have development of pneumatosis intestinalis and NEC. Nonetheless, Powell<sup>161</sup> and Aziz<sup>6</sup> have independently reported term infants with bloody diarrhea and pneumatosis intestinalis that was thought to be due to milk protein allergy. Other workers have also observed milk protein allergy associated with pneumatosis intestinalis and eosinophilic colitis. Although most newborn infants with eosinophilic colitis do not manifest pneumatosis intestinalis or NEC, some premature patients with NEC have been reported to have eosinophilic infiltration of the colonic mucosa.<sup>38</sup> Hemagglutinin titers to soy or cow's milk protein may be present in cord blood and may produce antigen-antibody complexes that mediate immune injury to the immature colon.<sup>172</sup> Furthermore, breast milk may contain small but significant quantities of cow's milk antigen if the mother consumes cow's milk products.<sup>122</sup> Such an immune-mediated colonic injury should be considered in all term infants with bloody stools and in premature infants with any gastrointestinal illness who have peripheral blood eosinophilia, eosinophils in the stool, or eosinophilic infiltration of the epithelial cells of the colonic mucosa. Specific protein-free formula will prevent recurrence of each of these disease processes.

Pneumatosis intestinalis is often seen in infants sometimes before, but more often after, the patient has undergone surgery for a structural gastrointestinal obstruction. Midgut volvulus, Hirschsprung's colitis, ileal atresia, "Christmas tree" deformity, and pyloric stenosis may all be associated with obstruction, intestinal perforation, enterocolitis, and, on rare occasion, pneumatosis intestinalis with NEC<sup>15,44</sup> (Table 3). These diseases represent a small proportion of intestinal perforations in an NICU, but should be considered in a newborn infant who presents with signs more typical of an anatomical obstruction than of NEC. Clues to the diagnosis of an anatomical obstruction may include excessive amniotic fluid or polyhydramnios, bile-stained emesis, and abdominal distention within the first day of life, obstipation, intermittent episodes of distention, intra-abdominal calcifications, or distention without abdominal tenderness. Necrotizing enterocolitis is unusual on the first day of life, usually presents with blood in the stool, does not have a saltatory pattern of progression, and is usually characterized by abdominal distention with tenderness. Nonetheless, NEC with pneumatosis intestinalis

TABLE 3.

## Differential Diagnosis of Necrotizing Enterocolitis

---

Sepsis
Dissecting pneumothorax with pneumoperitoneum
Volvulus
"Christmas tree" deformity
Pseudomembranous colitis
Hirschsprung's colitis
Reduplication
Intussusception
Postasphyxial bowel necrosis
Umbilical catheter thromboembolism
Spontaneous bowel perforation
Hepatic-splenic-adrenal hemorrhage
Stress ulcers
Meconium ileus
Esophagitis
Milk protein intolerance

---

can complicate the preoperative, but more often the postoperative, course of neonatal patients with anatomical bowel disease.

Spontaneous perforation of the intestine is another entity that some authors hypothesize is related to NEC.<sup>137</sup> Spontaneous perforation usually occurs in previously healthy term infants on the first day of life.<sup>10, 137</sup> Isolated perforation along the greater curvature of the stomach is the most frequent site, followed by colonic and ileal perforations.<sup>10, 137</sup> Microscopic examination reveals a small isolated area of perforation with or without hemorrhagic coagulation necrosis.<sup>137</sup> Pneumatosis intestinalis is never observed as the only radiographic evidence of intestinal disease in pneumoperitoneum. Spontaneous gastric perforation is the second most common cause of a perforated viscus. We believe that spontaneous intestinal perforation is not the same disease process as NEC. The former may be due to congenital weakness of the bowel wall or other unidentified factors. Additional important causes of gastrointestinal perforation include feeding tube accidents and gastrointestinal perforation among infants receiving positive-pressure ventilation through nasal prongs or a face mask.<sup>69</sup>

Inflammation of the appendix during the neonatal period is another disease that simulates NEC.<sup>119</sup> Whether this is a true appendicitis as seen in older patients, or represents NEC localized to the appendix is uncertain. Patients may be preterm or term and present with various nonspecific signs that may delay the appropriate diagnosis. Mortality is usually very high with this intra-abdominal catastrophe, as the condition is often unrecognized until severe peritonitis develops. Pneumatosis intestinalis is not usually observed in patients with neonatal appendicitis.

Pseudomembranous colitis is another gastrointestinal disease that

may resemble NEC. Pseudomembranous colitis is a common disease in adults receiving antibiotics such as clindamycin or ampicillin.<sup>8, 77, 173</sup> Toxin or toxins produced by *Clostridium difficile* in the fecal flora result in hemorrhage, mucosal ulceration, and pseudomembrane formation.<sup>77, 124, 135, 202</sup> This bacterium is not frequently found in normal adults and has been reported as a contagious pathogen in adults.<sup>77, 173</sup> In contrast, *C. difficile* and its toxin are often recovered from stool specimens from normal asymptomatic preterm or term infants.<sup>54, 170, 188</sup> Pseudomembranous colitis has been reported in newborn infants with or without previous antibiotic treatment.<sup>186</sup> Although pseudomembrane formation is a component of the pathology of NEC, pseudomembranous colitis involves only the mucosa, while severe NEC may involve all layers of the intestine. In general, pseudomembranous colitis is probably very rare in newborn infants with bloody stools regardless of prior antibiotic treatment.<sup>194</sup> Furthermore, although toxin or *C. difficile* may be isolated from a patient, the presence of the organism and/or the toxin is so common among asymptomatic neonatal patients that we question the possibility of a true pseudomembranous colitis in newborn patients.<sup>54, 170, 188</sup> Proper documentation of pseudomembranous colitis must include the endoscopic description of the mucosa together with biopsy and recovery of both the organism and the toxin. When this syndrome had been described in newborn patients, the patients always had mild symptoms and did not demonstrate evidence of pneumatosis intestinalis.

Of interest are the many isolated reports of nonneonatal pneumatosis intestinalis in older pediatric patients and adults.<sup>148, 184</sup> Many of these cases are cancer patients who are immunosuppressed and neutropenic.<sup>24, 46, 105</sup> Other associated conditions include cardiac surgery, hypotension, cystic fibrosis, transplantation, collagen vascular disease, inflammatory bowel disease, trauma, pseudo-obstruction, and ischemic enteritis.<sup>93, 214</sup> Pneumatosis intestinalis and enterocolitis in these immunocompromised patients is a serious disorder that does not always respond to intestinal decompression or broad-spectrum antibiotics.

The differential diagnosis of NEC has been discussed in part in the preceding sections and also in Table 3. Sepsis, with an ileus, in addition to other intestinal diseases such as volvulus, are important disorders that require specific therapy. If a pneumothorax or pneumomediastinum dissects below the diaphragm, it may cause pneumoperitoneum and abdominal distention with or without tenderness. This problem often raises important clinical decisions of whether to perform exploratory laparotomy or to just observe the patient carefully and concentrate on the problem in the thorax and not the abdomen. The history is often helpful, as is documentation of an intrathoracic air leak. Many of these seriously ill patients are

on high ventilator settings, are not being fed, and thus are not the usual patients in whom NEC develops. Indeed, most patients with NEC have had little or only mild RDS and usually do not develop NEC during the acute phase of respiratory management.<sup>112</sup> Although contrast dye studies have been proposed for identifying the suspected site of intestinal perforation, we feel this is unnecessary in most cases associated with pneumothorax. Given the nature of the pulmonary disease with an intrathoracic air leak, the pneumoperitoneum can be managed conservatively, as it poses no serious threat to the patient. Peritonitis is not likely because there is no intestinal perforation.

## **PATHOGENESIS**

Presently, the cause of neonatal necrotizing enterocolitis is unknown and there is no unifying etiologic theory that takes into consideration potential contributing or predisposing factors.<sup>31, 110, 121</sup> Early theories considered the etiology of NEC as a multifactorial process involving previous episodes of intestinal ischemia, enteric alimentation and secondary bacterial invasion as contributing factors.<sup>144, 183</sup> It was proposed that the many diseases and treatments of the high-risk premature infant could produce intestinal ischemia. After the mucosal barrier was damaged from the antecedent hypoxia, bacteria (in the presence of formula as a substrate for bacterial growth) would become secondary invaders of the unprotected mucosa. Abnormal and excessive intestinal gas would then be produced, causing distention. Distention could produce increased luminal pressure and further deterioration of mucosal blood flow. Severe abdominal distention has also been shown to reduce systemic blood pressure and renal blood flow.

More recently, NEC has been noted to occur in both term and preterm infants in the absence of risk factors that could produce gastrointestinal ischemia.<sup>106, 154, 182</sup> In addition, as will be discussed in more detail in a later section, the multiple neonatal disease states present before the onset of NEC probably do not represent risk factors because they are seen with the same frequency in neonatal patients who never develop NEC.

It is possible that NEC is caused by a single microbiologic agent, which, to date, has not been identified. Glass<sup>71</sup> has recently reviewed the major epidemiologic advances in the last decade on diseases of unknown but suspected infectious etiology. Acquired immunodeficiency syndrome (AIDS), toxic shock syndrome, Lyme disease, and legionnaires' syndrome are all infectious diseases whose causative agent required considerable time and effort to eventually discover. Glass considers neonatal NEC to be one of the next diseases for which a specific agent will be identified.

An alternate hypothesis is that NEC is the final common pathway for multiple initiating and propagating disease processes of infectious, toxic, immunologic, or circulatory origin. As alluded to earlier, an analogy between the radiographic findings of a pneumonic infiltrate and the radiographic findings of pneumatosis intestinalis is possible, as both pneumonia with tachypnea and rales and NEC with bloody stool and abdominal distention produce signs that do not connote a specific diagnosis. Pneumonic infiltrates may be caused by bacteria, viruses, fungi, parasites, toxins, foreign bodies, or immunologic mechanisms. Pneumatosis intestinalis, like an infiltrate on a chest roentgenogram, may signal a diseased organ but may not be specific for any one etiologic agent. In the following three sections the proposed pathophysiologic relationships between bowel ischemia, enteric alimentation, and gastrointestinal infectious disease processes and the etiology of NEC are explored.

### *Hypoxia-Ischemia as a Risk for Necrotizing Enterocolitis*

All previous theories of the etiology of NEC invoked some preceding event that produced gastrointestinal ischemia or hypoxia as important contributing factors for NEC<sup>51, 132, 144, 183, 204</sup> (Table 4). Some authors hypothesized that gastrointestinal ischemia was the only initiating variable producing NEC.<sup>51</sup> These theories were based on the similarity between the histopathology of NEC and that observed in ischemic gastroenteritis among adults and animal models.<sup>51, 183</sup> Additional supportive evidence of the role of systemic hypoxia is the physiologic response of the mammalian fetus to hypoxia. This response, similar to that observed in diving mammals, has been called the "dive reflex." In response to in utero hypoxia the fetus redistributes the circulation from nonvital organs such as the skin, lungs, kidneys, and intestines to vital organs, such as the placenta, brain, heart, and adrenal gland.<sup>204</sup> Additional animal models of fetal or neo-

TABLE 4.  
Purported Hypoxic-Ischemic Risks for  
Necrotizing Enterocolitis

---

Asphyxia
RDS (hypoxia)
Umbilical catheterization
•Exchange transfusion
Shock
Patent ductus arteriosus
Congenital heart disease
Polycythemia
Thrombocytosis
Anemia

---

natal hypoxia demonstrate even more shunting of blood away from the intestinal mucosa than the rest of the bowel wall.<sup>204</sup> Reduction of mesenteric blood flow is due to local vasoconstriction. The initial period of intense vasoconstriction may not directly affect the intestine. However, once vasoconstriction has abated, reperfusion of the ischemic bowel, possibly in combination with free radical oxygen or superoxide generation, may result in tissue damage. Cytoprotection or cellular preservation with free-radical "scavengers" has been proposed to be beneficial in animal models of reperfusion-induced intestinal disease. This potential ischemic-hypoxic gastrointestinal injury may result in a breakdown of the protective glycocalyx layer overlying the mucosal cells. This breakdown could render the exposed and damaged mucosa susceptible to bacterial invasion or the effects of bacterial toxins. The role of bacteria in experimental ischemic bowel injury is critical because germ-free animals do not develop severe bowel disease while animals contaminated with bacteria have a much faster demise than germ-free animals.<sup>215</sup>

Systemic or selective gastrointestinal ischemia-hypoxia may occur in the perinatal period during episodes of intrauterine fetal distress, birth asphyxia, RDS, umbilical catheter placement in the aorta, hypotension, patent ductus arteriosus, cyanotic heart disease, or neonatal exchange transfusion.<sup>26, 183</sup> Previous uncontrolled descriptive reports of patients with NEC reported that many of these risk factors were common among patients with NEC.<sup>107, 183</sup> However, these conditions are common neonatal problems and probably representative of all premature patients in the NICU. Since the original reports, there has been additional evidence to suggest that there are very few, if any, truly identifiable ischemic risk factors for NEC. Necrotizing enterocolitis has been identified in premature and full-term infants who have no known risk other than low gestational age. In addition, over a dozen case- or cohort-controlled studies to date have been unable to consistently identify RDS, patent ductus arteriosus, exchange transfusion, cyanotic heart disease, apnea of prematurity, asphyxia, hypothermia, hypotension, or umbilical vessel catheterization as being more common in patients who developed NEC than in an age- and time-matched group of unaffected high-risk infants.<sup>32, 49, 67, 83, 112, 145, 156, 175, 182, 195, 198, 209, 216</sup> These data suggest that most purported risk factors are common to the entire population of low-birth-weight infants and are not specific antecedent events for the pathogenesis of NEC.

Umbilical artery catheterization has been implicated as a potentially ischemic event that might predispose patients to NEC.<sup>183</sup> The catheter could directly occlude the mesenteric orifices in the aorta or serve as a nidus for thromboembolism. Furthermore, plasticizer may be leached from the catheter and produce vasospasm.<sup>92</sup> Nonetheless, large-vessel thrombi or thromboemboli in the mesenteric

circulation have been a rare and inconsistently observed finding in patients with NEC. If the arterial catheter is an important factor, then infants with catheters placed below the orifices of the mesenteric vessels should have a lower incidence of NEC than those with catheters above the mesenteric orifices. In a recent prospective randomized study of umbilical artery catheter placement allocated to high or low aortic position among 341 high-risk infants, we were unable to find any difference in the incidence of NEC between the two catheter positions.<sup>198a</sup>

Lehmiller and Kanto<sup>132</sup> had previously postulated that enteric feeding with an umbilical artery catheter in place may be responsible for some cases of NEC. Evidence for mesenteric thromboembolism in their study was obtained from a retrospective review of pathology cases in an institution that apparently did not always employ heparinized infusions through the umbilical arterial catheter. Thirty percent of never-fed infants with a catheter in place had evidence of mesenteric thromboembolism while 73% (11/15) of all infants (e.g., those with NEC and controls) fed orally with a catheter in place had mesenteric thrombi. Nonetheless, there was no statistical relationship between oral feedings and mesenteric thromboembolism. Thrombosis was also evident on the venous side of the circulation as 36% had pulmonary emboli. These data suggest that thromboembolism in these patients could relate to other factors such as unheparinized infusion solutions or coagulopathy. Indeed, over half of the patients in the study had evidence of abnormal coagulation status as demonstrated by a prolonged partial thromboplastin time and thrombocytopenia. Experience in our nursery from 1984 to 1986 does not support a relationship between enteric alimentation and the development of NEC. In our NICU very-low-birth-weight infants may receive full caloric nutrition by intermittent or continuous nasogastric feeding while also receiving ventilator therapy with an umbilical artery catheter in place for 1 to 3 weeks. We have seen no cases of NEC during this feeding regimen even when the umbilical artery catheter is in situ. If NEC developed in these patients it occurred after the catheter was removed and the infant was off the ventilator. The incidence of NEC was similar whether the patients were fed with an umbilical catheter in place or not.

Although most preceding or concomitant systemic hypoxic ischemic events have not consistently been associated with NEC in well-controlled studies, polycythemia does appear to be a potential risk factor for NEC.<sup>128</sup> It is presently unclear whether NEC is due to the stasis and sluggish mesenteric microcirculation caused by polycythemia-hyperviscosity or to the exchange transfusion required to treat the polycythemia. LeBlanc and colleagues<sup>131</sup> suggest polycythemia contributes to a bowel disease like NEC in newborn puppies. In another study, Black and associates<sup>16</sup> report an increased incidence



of NEC among term infants treated with partial exchange transfusions compared with term polycythemic infants who were randomized to conservative management without exchange transfusion. In the latter study, 81% of polycythemic infants who received exchange transfusion developed some gastrointestinal problem while only 58% of polycythemic infants who had no exchange transfusion had intestinal symptoms. These symptoms included bloody stools, distention, and poor feeding. Thus, although exchange transfusion may contribute to the gastrointestinal morbidity of polycythemia, there is also a high rate of gastrointestinal disturbances in the group of patients with polycythemia alone who have not undergone exchange transfusion.

Although many of the previously purported risk factors that may produce systemic and local mesenteric ischemia or hypoxia have not been found to be significant contributing variables in the pathogenesis of NEC, abnormalities may be caused by alterations of the normal mesenteric vascular responses to digestion. In adult mammals local blood flow to the bowel significantly increases during a meal. Blood flow increases specifically to the intestinal mucosa during a standard feeding. This mucosal hyperemia assists the digestion and absorption of nutrients and is due in part to local vasodilation reflexes, humoral signals, and specific metabolic changes associated with nutrient absorption. These may also be mediated by vasodilator agents such as prostacyclin or glucagon. The result is increased local mucosal flow, oxygen extraction, and oxygen consumption.<sup>56</sup> A similar response has been noted in some, but not all, neonatal mammals as evidenced by postprandial intestinal hyperemia.<sup>56</sup> Presently, there is a paucity of comparative physiologic studies on the maturation of intestinal blood flow or on the potential relationship between abnormalities of the regulation of intestinal blood flow and serious neonatal gastrointestinal diseases such as NEC.

One indirect measure of circulatory changes during a feeding is to determine perturbations of extremity or calf blood flow.<sup>164</sup> Term infants respond to an enteric feeding with a decreased blood flow to the calf while in marked contrast, preterm infants demonstrate no significant change of calf flow during a feeding. The peripheral vascular response of full-term infants indirectly suggests shunting of blood to the intestines, while the response of premature infants, although circumstantial, suggests poor intestinal autoregulation with no increase of intestinal blood flow during a feeding. Combining these preliminary data with the consistent absence of evidence for preceding episodes of documented ischemia in the pathogenesis of NEC, we can only begin to speculate on the role of immature gastrointestinal circulatory reflexes in the etiology of neonatal bowel disease.

## *Enteric Alimentation as a Risk for Necrotizing Enterocolitis*

### **GASTROINTESTINAL IMMATURITY**

There is a major transition for the intestine after birth among all newborn mammals.<sup>129</sup> Enteric nutritional absorption is not a significant source of fuels for the fetus as the placenta provides almost all the nutrient needs. Within minutes after birth the gastrointestinal system of the newborn infant must become functional for energy and water homeostasis and future growth. Although most viable premature infants can be fed effectively by the enteric route, very immature infants demonstrate marked instability of gastrointestinal function compared with term infants. Qualitatively the intestinal anatomy (both gross and microscopic) is not very different in the preterm and the term infant. However, enzyme, hormonal, and functional immaturity are all present in the former, as evidenced by the high incidence of feeding problems among preterm infants.

Gastrointestinal motility is determined by local myoenteric reflexes, with autonomic nervous system input, and is modulated by gastrointestinal hormones.<sup>179</sup> Although the fetus must swallow amniotic fluid to maintain amniotic fluid balance, the actions of sucking, glottal closure, and esophageal motility are not well coordinated in the preterm infant before 30 to 32 weeks' gestational age. This dyscoordination necessitates tube feeding, usually by oral or nasogastric tube. Tube feeding also raises the possibility of the many technical problems associated with tube placement; esophageal irritation, perforation, bacterial colonization, reflux, and aspiration pneumonia. Gastric emptying is less well-coordinated in the newborn than the adult and the gastric emptying time is prolonged in premature infants and newborns with gastroesophageal reflux, compared with normal term infants.<sup>130</sup> Systemic illnesses such as RDS may also delay gastric emptying.<sup>130</sup> Formula composition may also effect gastric emptying, as long-chain fatty acids delay emptying while medium-chain fatty acids, or high caloric density, usually have no effect.<sup>130</sup>

The development of the enteric nervous system helps determine enteric motor activity in the newborn infant. Peristalsis is present in utero, as evidenced by fetal swallowing of amniotic fluid and the presence of contrast material in the midtrimester fetal intestine after intra-amniotic injection to outline the fetal abdomen during intra-uterine transfusion for erythroblastosis. "Hunger contractions" are present in the term sleeping newborn, while colonic peristaltic waves have been observed in the first-trimester fetus. Duodenal motility, as studied by intraluminal manometry, is immature prior to 29 weeks gestational age.<sup>147</sup> Thereafter, the number of contractions, the rate of contractions, and the luminal pressure generated increase.

The premature newborn infant has a normal distribution of intestinal ganglion cells. During the time of development from the first trimester to term the intestine elongates 1,000-fold and at term the small intestine is six times that of the colon. In term infants the small bowel is approximately three times the length of the infant. Despite these early developmental observations there is a paucity of data about the role of the enteric nervous system and human neonatal gastrointestinal disease.

In addition to a specific enteric nervous system, there are local enteric hormones that have a marked influence on intestinal function.<sup>5</sup> One persistent observation among newborn infants is a greatly elevated plasma gastrin level in the presence of a paradoxically decreased gastric acid secretion during the first few days after birth.<sup>136</sup> This physiologic hypergastrinemia may be an important stimulant for mucosal cell growth, may be a result of the neonatal diet, or result from a functional hyporesponsiveness of the parietal cells.<sup>136</sup>

Additional enteric hormones associated with postnatal adaptation to postnatal enteric alimentation have been reviewed by Aynsley-Green.<sup>5</sup> There is a marked rise of blood levels of enteroglucagon, motilin, neurotensin, gastric inhibitory polypeptide (GIP), and pancreatic polypeptide in preterm infants after the onset of enteral alimentation. This increase of local "gut" hormones does not occur in infants kept NPO and fed with intravenous alimentation. These hormones are important regulators of gastrointestinal function and perhaps mucosal growth. Motilin may increase gastrointestinal motility and gastric emptying while gastrin and enteroglucagon may stimulate mucosal cell growth. Corticosteroids may also have a direct effect on intestinal maturation. Alterations of "gut" hormone physiology during prolonged periods of abstinence from enteric alimentation may place the immature intestine in jeopardy for feeding intolerance or serious gastrointestinal disease such as NEC.

An interesting and related observation in mammals is the development of intestinal mucosal atrophy during prolonged periods of total parenteral alimentation (TPN).<sup>4</sup> Despite body growth and positive nitrogen balance during TPN, enteric cell proliferation decreases, resulting in the histologic appearance of flattened villi and decreased intestinal surface area. We recently hypothesized that enteric alimentation (even in small "trophic" quantities) could enhance neonatal gastrointestinal function in very small sick premature infants during the first week of life.<sup>95</sup> Prior to this study, most sick infants in our nursery were kept NPO during their acute medical illnesses. To provide "gut stimulation" (as the nurses named our investigation), we fed very-low-birth-weight infants small hypocaloric quantities of regular premature formula and compared these infants with a randomized group who remained NPO for 10 days. The "gut stimulation" group had significantly lower indirect bilirubin levels,

required less phototherapy, and had lower incidences of cholestatic jaundice and of severely elevated serum alkaline phosphatase levels.<sup>95</sup> There were no complications and NEC was seen with equal frequency in both groups. These data suggest that early hypocaloric feeds have a beneficial effect on the gastrointestinal function of the very-low-birth-weight infant.

### *Enteral Feedings*

Five factors related to enteric feeding have been proposed as being implicated in the pathogenesis of NEC: the osmolality of the formula, the absence of immunoprotective factors in commercial milks, the volume or rate of feeding, the role of formula malabsorption and resulting enteric gas production, and abnormal milk protein immunologic responses (Table 5).

Hypertonic formulas have been implicated in the pathogenesis of NEC. Book and colleagues<sup>20</sup> described a series of infants fed a hyperosmolar formula (osmolality of 650 mOsm/L) who developed NEC. deLemos and co-workers<sup>50</sup> demonstrated that hypertonic formula could produce severe mucosal lesions in the intestines of newborn goats. Presently, hypertonic formulas are rarely employed in the NICU. Nonetheless, many oral medications are formulated in syrups or elixirs that are very hypertonic and could contribute to "hidden" osmoles during enteric therapy.<sup>207, 208</sup> These hypertonic medications may produce mucosal injury by a direct local effect. Such hypertonic preparations include acetaminophen, calcium glubionate, chloral hydrate, dexamethasone, digoxin, ferrous sulfate, furosemide, multivitamins, phenobarbital, potassium chloride, vitamins D<sub>2</sub> and E, theophylline, and Kayexalate. Hypertonic substances may directly irritate or injure the gastrointestinal mucosa. Hypertonic solutions may also result in a requirement for increased gastrointestinal blood flow, which may possibly contribute to altered mucosal function in a sick premature infant.

In addition to the carrier solution, which may produce mucosal

TABLE 5.  
Feeding Risks for Neonatal Necrotizing  
Enterocolitis

---

Hypertonic formula
Hypertonic medication
Medication direct—toxic
Feed too much
Feed too fast
Non-breast milk formula
Nasojejunal feeding

---

injury, the drug itself may produce gastrointestinal damage. Xanthines have been associated with the development of NEC in uncontrolled studies.<sup>79</sup> Davis and co-workers, however, were not able to confirm that NEC was due to theophylline therapy in newborn infants.<sup>49</sup> Interestingly, the theophylline-treated group consisted of younger and more immature patients; thus, as a group they would be expected to have a higher incidence of NEC. It may not always be the drug that is responsible for NEC; for example, apnea, for which theophylline is given, may itself be an early presentation of NEC. Other drugs associated with the onset of NEC include indomethacin and vitamin E.<sup>98, 151</sup> Although the evidence for the former is not convincing, preliminary data suggest that vitamin E therapy may place the premature infant at risk for both septicemia and NEC.<sup>88</sup> Excessively high serum vitamin E levels may interfere with neutrophil oxidant action and increase susceptibility to infection.

Human breast milk feeding had been proposed as possible protection against the development of NEC.<sup>7, 159, 183</sup> Human milk, with its many immunoprotective properties, has been thought to be effective in preventing many infectious diseases, including upper respiratory tract infections, gastroenteritis, neonatal sepsis, and, possibly, NEC.<sup>75, 89, 124, 213</sup> At birth there is a paucity of local intestinal secretory IgA present. Human milk is a rich source of IgA and other immunoprotective factors, such as lysozyme, lactoperoxidase, lactoferrin, interferon, bifidus factor, and a high carbohydrate composition, which decreases luminal pH.<sup>3, 89</sup> The alteration of luminal pH enhances the growth of *Lactobacillus bifidus*, which inhibits the growth of gram-negative pathogens. In addition to these components, human milk also contains neutrophils, lymphocytes, and macrophages. The latter cell represents 80% to 90% of breast milk cells. The macrophage is thought to be the most active immunoprotective cell in human milk. Animal models of NEC suggest that breast milk but not formula can protect newborn pups.<sup>7</sup> Fresh, but not frozen, breast milk was protective. Further studies determined that the breast milk macrophage was the factor that prevented the experimental NEC in this newborn animal model. However, we should always be careful when extrapolating animal data to those related to human disease. Necrotizing enterocolitis has been reported in preterm infants fed exclusively with fresh pasteurized or frozen human milk.<sup>63, 113, 146, 166</sup> The nature and the incidence of NEC in patients fed refrigerated human milk was not different than that in formula-fed infants.<sup>113</sup> In the other studies, the mode of treatment of the milk may be a factor as freezing, pasteurizing, or boiling human milk will interfere with or destroy the various immunologic components of fresh milk. Nonetheless, it would appear that feeding even immunologically intact human milk does not decrease the incidence or severity of NEC. Bauchner and co-workers<sup>9</sup> have critically reviewed the literature on

the effectiveness of breast feeding in prevention of many other infectious diseases of the older infant. After eliminating many poorly controlled studies these authors concluded that there was little if any strong evidence that breast-feeding reduces the incidence of infections in term infants in an industrialized society.<sup>9</sup> Breast-feeding also had no effect on the incidence of rotavirus enteritis compared with that in formula-fed infants. Thus, although there are many beneficial effects of breast-feeding, there is little evidence to support the hypothesis that the absence of human milk feedings contributes to the etiology of neonatal NEC.

Another hypothesis concerning the relationship between enteral alimentation and the etiology of neonatal NEC relates to the timing, volume, and rate of formula feeding of low-birth-weight infants.<sup>30, 61, 118</sup> In most NICUs prior to the mid-1980s, the sick very-low-birth-weight neonates received parenteral alimentation for the first week of life and more mature infants for shorter periods.<sup>40, 63, 64</sup> The mean time from birth to onset of feeding (almost always intermittent or continuous nasogastric) even now is usually modified by size of the infant, even a more important factor is the severity of illness. Once enteral alimentation is initiated it has been recommended that the rate of feeding increment should be slow, so that full enteral alimentation is not achieved until 1 to 2 weeks after the start of oral feeding.<sup>64</sup>

Because more than 95% of patients who develop neonatal NEC have been fed, many nurseries have attempted to prevent NEC by delaying enteral alimentation. In a well-controlled investigation, which compared the efficacy of enteral vs. parenteral alimentation to support neonatal growth, one serendipitous result was a lower incidence of NEC among those patients randomized to NPO and TPA. This lower incidence of NEC was isolated to the study period; once enteral alimentation was initiated among the parenterally fed infants, NEC then developed among these infants. Thus, parenteral alimentation may not prevent neonatal NEC but only delay its onset. Similar observations were noted by Ostertag and co-workers<sup>156</sup> in another prospective study comparing high-risk infants fed initially with a diluted formula with those who received parenteral alimentation alone.<sup>156</sup>

Brown and Sweet have advocated a very cautious and slow feeding schedule to prevent neonatal NEC.<sup>30, 31</sup> These experienced neonatologists suggested that the rate of feeding and the absolute volume of individual feedings may place the "high-risk" infant at risk for NEC. Although most of their assumptions are based on retrospective analyses of their data from one hospital, they claim that the incidence of NEC decreased substantially in their nursery after the introduction of this very conservative feeding protocol. For example, they propose that a typical 1,000-gm infant should be fed slowly and

not advanced to full feedings by mouth until 2 weeks into his feeding schedule. Signs of feeding intolerance, distention, Hematest-positive stools, or apnea warrants the discontinuation of enteric alimentation for various periods of time. Goldman also reported that the incidence of NEC increased in his nursery when large feeding increments or large absolute daily volumes were given to preterm infants.<sup>73</sup> The maximal volume increase was greater than 60 ml/kg/day and maximum total daily feeding was greater than 150 ml/kg/day. Book and co-workers also suspected that a change in the feeding policy in their nursery resulted in an increased incidence of NEC.<sup>21</sup> During the period with a higher incidence of NEC the rate of increment of feeding advancement increased from 8.6 ml/kg/day to 20 ml/kg/day. In a small prospective study of 29 patients comparing a slow increment of formula feeding of 10 ml/kg/day with a moderate increment of 20 ml/kg/day, Book and colleagues were unable to demonstrate an increased incidence of NEC in their more rapidly fed group. We recently evaluated the effects of feeding practices on endemic cases of NEC in a case-controlled study (unpublished data, 1986). Although average day-to-day feeding practices were not different between patients with NEC and their time and gestational age-matched controls, we observed that very significant differences were hidden by averaging. When the data were reanalyzed it became evident that the patients who developed NEC were fed greater volumes of formula and at a faster rate than age-matched controls. The day of maximum feeding increment was day 3 of feeding; on that day, patients with NEC received an increase of 57 ml/kg/day compared with an increment of 22 ml/kg/day in patients who did not develop NEC. The day of life of maximum feed volume was day 8; on that day, patients who developed NEC received 124 ml/kg/day with a day-to-day increment of 28 ml/kg/day vs. a total of 83 ml/kg/day and an increment of 17 ml/kg/day in controls. Both our data and previous reports also found a relationship between total fluid intake and NEC. Patients who developed NEC also had a greater total (intravenous plus enteric) intake than controls. These data strongly suggest that the total volume given to very-low-birth-weight infants should be monitored carefully and that daily increments of greater than 25 ml/kg/day may stress the immature gastrointestinal system. Although this was not a randomized study, the control group and NEC patients were equivalent in terms of birth weight and other significant "risk factors." We conclude from all these data that the very small premature infant should be fed cautiously during the first 1 to 2 weeks of life. We recommend avoiding large day-to-day volume increments and gradually advancing the feeding schedule. A recommended feeding protocol is presented in Table 6.

The mechanism by which excessive feeding volumes predispose the premature infant to development of NEC is not certain. Excessive

TABLE 6.

## Simplified Feeding Protocol for Premature Infants\*

CONCENTRATION	WEIGHT			
	500-750 GM	751-1,000 GM	1,001-1,500 GM	1,501-2,000 GM
	FEEDING INTERVAL			
	2 HR VOLUME-DURATION	2 HR VOLUME-DURATION	2 HR VOLUME-DURATION	3 HR VOLUME-DURATION
PERIOD I: CONCENTRATION INCREASED WHILE VOLUME IS CONSTANT				
10 cal/oz	1 cc × 6 feeds	1 cc × 6 feeds	2 cc × 4 feeds	4 cc × 3 feeds
15 cal/oz	1 cc × 6 feeds	1 cc × 6 feeds	2 cc × 4 feeds	4 cc × 3 feeds
20 cal/oz	1 cc × 6 feeds	1 cc × 6 feeds	2 cc × 4 feeds	4 cc × 3 feeds
PERIOD II: 20-CAL/OZ FORMULA WITH VOLUME PROGRESSIVELY INCREASED				
20 cal/oz	1.5 cc × 12 feeds	2 cc × 12 feeds	3 cc × 12 feeds	5 cc × 3 feeds
20 cal/oz	2.0 cc × 12 feeds	3 cc × 12 feeds	4 cc × 6 feeds	6 cc × 3 feeds
20 cal/oz	2.5 cc × 12 feeds	4 cc × 12 feeds	5 cc × 6 feeds	7 cc × 3 feeds
20 cal/oz	3.0 cc × 12 feeds	5 cc × 12 feeds	6 cc × 6 feeds	8 cc × 4 feeds
20 cal/oz	3.5 cc × 12 feeds	6 cc × 12 feeds	7 cc × 6 feeds	10 cc × 4 feeds
20 cal/oz	4.0 cc × 12 feeds	7 cc × 12 feeds	8 cc × 6 feeds	12 cc × 4 feeds
20 cal/oz	4.5 cc × 12 feeds	8 cc × 12 feeds	9 cc × 6 feeds	14 cc × 4 feeds
20 cal/oz	5.0 cc × 12 feeds		10 cc × 6 feeds	16 cc × 4 feeds
20 cal/oz	5.5 cc × 12 feeds		11 cc × 6 feeds	18 cc × 4 feeds
20 cal/oz	6.0 cc × 12 feeds		12 cc × 6 feeds	20 cc × 4 feeds
20 cal/oz	6.5 cc × 12 feeds		13 cc × 6 feeds	22 cc × 4 feeds
				24 cc × 4 feeds
				26 cc × 4 feeds
				28 cc × 4 feeds
Time to reach 150 cc/kg/day by mouth	12.5 days	8.5 days	7 days	7 days

\*There is no agreement on an optimal feeding regimen for premature infants. All regimens have the common goal of gently challenging the immature GI tract while optimizing caloric intake. This protocol advances by 20-cc/kg/day increments, a rate that has been shown to be safe (see text). Hyperalimentation should be started when electrolytes have stabilized, generally by day 3 of life. Infants with birth weights less than 1,500 gm should advance to 24-cal/oz premature formula when oral feedings of 150 cc/kg/day are tolerated.

volume may produce an imbalance between mucosal blood flow, oxygen extraction, and nutrient absorption, which could result in a relative mucosal ischemia. Alternatively, an excessive milk load may overcome enzymatic capacity and result in lactose malabsorption. The activity of the enzyme lactase may be lower in the preterm infant than the term infant or older child. Lactose malabsorption would provide fermentable substrate for the enteric bacteria that inhabit the colonic flora. Normal premature infants malabsorb some lactose, as demonstrated by their increased rate of hydrogen production. When excessive lactose is available for the colonic bacterial flora, bacterial proliferation may ensue, producing even more hydrogen gas and initiating the pathogenesis of NEC. Engel demonstrated



that the gas in both the intestinal lumen and the submucosal cysts of pneumatosis intestinalis in patients with NEC is in part composed of hydrogen gas.<sup>62</sup> Furthermore, the bacteria isolated from these patients do not produce hydrogen gas in regular media unless infant formula is added to the incubation mixture. Enteric bacterial fermentation is the only known source for hydrogen gas in the human.<sup>157</sup> Additional evidence of the role of carbohydrate malabsorption in NEC is the observation that patients with this disease have increased fecal excretion of reducing substances, as determined by the Clinitest reaction.<sup>22</sup> These data strongly suggest that bacterial fermentation of formula-derived carbohydrates contributes to the pathophysiology of neonatal NEC. Whether gaseous distention itself interferes with intestinal or mucosal perfusion or is simply a marker for abnormal bacterial fermentation or proliferation has not been proved. The combination of carbohydrate fermentation, altered local redox states (from organic acid fermentation products), and stasis with bacterial overgrowth may perturb the bacterial microenvironment and result in the emergence of pathogenic bacteria with or without enterotoxin production.

Alterations of the intestinal microbiologic flora due to dietary changes or immaturity have been held responsible for other enteric infectious diseases. Normally there is a balance between the facultative anaerobic gram-negative organisms and the obligate anaerobic organisms.<sup>138, 192</sup> A system of symbiosis with "checks and balances" between the organisms of the colonic microflora called colonization resistance prevents the emergence of a pathologic strain. This system of bacterial interference is one of the antimicrobial mechanisms of breast milk feeding that stimulates growth of *Lactobacillus bifidus*, which in turn interferes with the growth of other enteric bacteria.<sup>174</sup> Perturbations such as dietary changes, inhibition of trypsin, suppression of facultative aerobic bacteria by broad-spectrum antibiotics, and changes in the local redox state following malabsorption interfere with this microbial symbiosis and may result in bacterial overgrowth or stimulate enterotoxin production.

Eosinophilic colitis with pneumatosis intestinalis is rare but has been reported in a few patients with NEC.<sup>6, 161</sup> Nevertheless, multiple histopathologic studies of severe cases of NEC (those following perforation or death) do not demonstrate significant mucosal eosinophilic infiltration. The primary pathologic event may have become obscured following peritonitis or secondary bacterial invasion of the mucosa. Some infants with stage II NEC have demonstrated eosinophilic infiltration of the lamina propria and epithelial cells to the same extent as those observed during milk protein-induced colitis.<sup>58</sup> Milk proteins may pass through the intestinal wall and enter the circulation in both preterm and term infants.<sup>52</sup> Gut closure to mac-

romolecules is incomplete during the neonatal period compared with that function in normal adults who do not usually absorb macromolecules across an intact bowel wall.<sup>52, 206</sup> Either transplacental passage of anti-milk protein antibodies or the endogenous production of antibodies against these proteins could initiate a local immune inflammatory response in the intestinal mucosa and submucosa. Recurrences of NEC may be more common among these "allergic" infants if they are refeed a milk protein-containing formula.<sup>161</sup> Overall, 3% to 7% of patients who have had NEC develop recurrent NEC; this incidence is unrelated to the duration of previous therapy.<sup>107, 108</sup>

Many additional factors of gastrointestinal function and enteric alimentation may relate to NEC.<sup>121</sup> Infants in ICUs develop a spontaneous increase of stool or blood endotoxin levels with the onset of oral feedings. Prior to enteric alimentation, stool endotoxin levels are very low, but with oral feeding endotoxin levels may increase tenfold.<sup>185</sup> Patients with feeding difficulty, or NEC, have a higher incidence of endotoxemia than patients without feeding problems. Endotoxemia can produce inflammation or a picture similar to sepsis. Although the precise consequences of neonatal endotoxemia are not clear, it is possible that endotoxin may contribute to the pathogenesis of NEC.

In addition to immaturity of specific enteric immunologic mechanisms there are nonspecific nonimmunologic gastrointestinal defense mechanisms that may also be deficient among preterm infants.<sup>121</sup> Bile salts may bind and neutralize endotoxin.<sup>52</sup> The bile salt pool size is decreased in preterm infants and this could be another contributing factor to neonatal bowel disease. Proteolytic activity may be diminished in the premature infant under certain circumstances. Reduced proteolytic activity, as depicted by reduced trypsin levels or inhibition of its activity, may prolong the half-life of locally produced enterotoxins. Furthermore, stasis and ileus, or even the usual hypomotility of the immature intestine, may enhance bacterial overgrowth and permit bacterial mucosal binding or may result in local toxin production without concomitant toxin neutralization.

Despite the abundant evidence that enteric alimentation may contribute to the pathogenesis of NEC there remain many inconsistencies with this theory. Neonatal NEC has been observed in patients who never received enteral alimentation.<sup>106, 107, 141</sup> In addition, NEC has been documented in the absence of pneumatosis intestinalis, which purportedly is produced by enteric bacterial fermentation products. Nonetheless, all preterm infants eventually receive enteric alimentation! Why one neonatal patient develops NEC while the remaining high-risk patients never have significant bowel disease does not have an obvious answer.

## *Infectious Aspects of Neonatal Necrotizing Enterocolitis*

As reviewed in the previous sections, the original hypothesis of the etiology of NEC was that hypoxic-ischemic injury first damaged the intestinal mucosa and that endogenous bacteria, in the presence of formula that serves as a fermentable source, then produced NEC. We have noted that many of the purported risk factors are probably not antecedent variables for the pathogenesis of NEC, as multiple case-controlled studies have been unable to document that these neonatal problems were more common among patients with NEC than among unaffected control infants.<sup>106, 175</sup> Although enteric alimentation is a risk factor, the precise mechanisms by which formula feeding predisposes the premature infant to develop NEC remain unclear.

Although bacteremia has been documented in approximately 30% of patients with NEC, this may represent a primary event or secondary invasion of a compromised intestinal epithelium.<sup>28, 106</sup> The most common organisms recovered from blood cultures include *Escherichia coli*, *Klebsiella pneumoniae*, *Staphylococcus aureus*, *S. epidermidis*, enterococcus, *Clostridium* sp., and *Pseudomonas* sp.<sup>28, 106</sup> Because these organisms are common components of the enteric flora, it has been proposed that their presence represents secondary bacterial invasion. Organisms recovered from blood cultures are often identical to the bacteria that grow from peritoneal cultures from the same infant, again suggesting secondary bacterial invasion of a damaged mucosa.

Other evidence in the literature emphasizes additional infectious disease aspects of neonatal NEC.<sup>11, 106, 175</sup> Beginning with the onset of the disease, NEC resembles neonatal septicemia. Infants with NEC develop bacteremia, neutropenia, disseminated intravascular coagulation, and shock. Many NICUs have epidemic, or clustered cases of NEC linked in time or place.<sup>23, 107, 145, 171, 175</sup> Because of high attack rates and significant morbidity and mortality, nurseries are often forced to close to further admissions until the epidemic can be controlled. To the frustration of many investigators, a single pathogen has not been recovered from all epidemics. Furthermore, standard microbiologic investigations of most epidemics often fail to reveal the cause of the epidemic. On occasion when a single agent has been recovered from patients with NEC, the same organism has also been recovered from asymptomatic control patients.<sup>28, 106, 188</sup>

The bacteria that have been isolated, in careful studies, from the stools of infants with NEC include *E. coli*, *K. pneumoniae*, *Enterobacter cloacae*, *Pseudomonas* sp., *Salmonella* sp., *S. epidermidis*, *Enterobacter sakazakii*, *Clostridium perfringens*, *C. difficile*, *C. butyricum*, coronavirus, rotavirus (both type A and non-A), and enteroviruses.<sup>48, 62, 81, 87, 90, 91, 94, 120, 125, 150, 162, 193, 195, 199</sup>

During epidemics of well-documented NEC there is often a general increase of gastrointestinal disturbances in other neonatal patients in the premature infant ICU. These gastrointestinal problems include bright red blood per rectum in infants without pneumatosis intestinalis.<sup>176</sup> There is also more symptomatology, an increased prevalence of "septic workups," and of infants placed on NPO for suspected NEC. Furthermore, before, during, and after an epidemic of NEC among neonatal patients, we and others have observed gastrointestinal illness among the house staff and nurses working in the ICU.<sup>70</sup> In addition, children in the community or their parents may also be affected by various forms of gastrointestinal disease characterized by cramps, emesis, or diarrhea. Epidemics of NEC have also been abated by employing strict infectious disease control measures to prevent the spread of the as yet unidentified agent (see following).<sup>23, 175</sup>

Alterations of the fecal flora have been reported in patients with NEC.<sup>11, 25, 67</sup> Although colonization of the stool does not necessarily indicate bacterial invasiveness or disease causation, it may reflect overrepresentation of one microorganism and a shift in the microflora, resulting in an imbalance between pathogenic and endogenous bacteria. Normally, colonized bacteria are not present in newborn infants at birth. The first meconium stool among normal infants is usually sterile. Infants born following prolonged rupture of the membranes may demonstrate umbilical, cutaneous, or nasopharyngeal colonization with the same bacteria that colonize the mother's vagina, cervix, or rectum.<sup>29, 74</sup> In infants born by vaginal delivery without prolonged rupture of the membranes, colonization occurs within 4 hours after birth with bacteria from the maternal genital or rectal flora and from the nursery environment.<sup>74</sup> There is a high correlation between maternal cervical or rectal bacteria and those later recovered in the neonatal gastric aspirate.<sup>29</sup> This sequence may be modified by cesarean section, maternal antibiotic treatment, premature birth, neonatal intensive care practices, and the mode of feeding (breast or formula milk).<sup>13, 74</sup> Colonization is delayed by antibiotic therapy, cesarean section, or being placed NPO. Broad-spectrum antibiotics often suppress the normal aerobic bacteria resulting in emergence of resistant organisms or overgrowth of anaerobic bacteria.

Within the first day of life the normal infant develops an intestinal flora composed of both aerobic and anaerobic bacteria.<sup>143</sup> Once colonization is established among formula-fed infants the intestinal bacterial colony counts per gram are lowest in the stomach or jejunum ( $10^5$ /gm of stool), higher in the ileum ( $10^8$ /gm of stool), and highest in the colon ( $10^{11}$ /gm of stool). Anaerobic bacteria predominate in the colon while an equal mixture of aerobic and anaerobic bacteria is found in the stomach and jejunum. *Clostridium perfrin-*

*gens* and *Bacteroides* sp. are present in the stool as early as the second day of life. In addition to the usual organisms, normal newborn infants may also have *C. difficile* or *C. butyricum* as part of their microbial flora. *Clostridium difficile* is extremely unusual in adults and in older patients. This organism is usually associated with pseudomembranous colitis in adult patients.

Alterations of the bowel flora either prior to or at the onset of NEC have been implicated in the etiology of NEC.<sup>17, 67</sup> *Escherichia coli* and *Klebsiella* have been the two most frequent organisms appearing in the stool in increased numbers during epidemics and disappearing during the periods when NEC prevalence is lower. In another study, *Bacteroides* sp. and lactobacilli were seen less frequently in patients with NEC, while *C. perfringens* was recovered more often in patients with this disease.<sup>17</sup> Nonetheless, these alterations of the fecal flora are not universally present in all cases or epidemics of NEC. Furthermore, increased colony counts of *E. coli* or *K. pneumoniae* may be the result of the primary pathogenic event and not the cause itself. For example, abnormal enteric microbiologic flora may occur after viral gastroenteritis if the normal colonic microenvironment is disturbed.

Neonatal NEC has similarities with the many enterotoxemias produced by clostridial species in newborn animals or older humans.<sup>66, 217</sup> In most of these diseases dietary changes and bloating or feasting have been implicated as the initiating event. Enterotoxemias of newborn animals have been known to veterinarians for many years. Epidemics of *C. perfringens* type C exotoxin has produced disease in newborn piglets. Colostral antibody production following maternal immunization can prevent the disease, while antitoxin therapy of the piglet can be used to treat the disease. *Clostridium perfringens* type B enterotoxemias cause serious gastrointestinal illness among newborn fowl, calves, piglets, and lambs. The histopathology of many of these diseases resembles that of neonatal NEC.

Pigbel is a human enterotoxemia due to *C. perfringens* type C toxin. The histopathology of this disease, which affects infants and adults alike, includes mucosal edema, hemorrhage, and submucosal and subserosal gas-filled cysts.<sup>126, 127</sup> When the disease is severe, there may be intestinal perforation and gangrene. Pigbel may occur in a range from mild illness to a severe state similar to that of stage IIIB NEC. Pigbel has occurred following sudden dietary changes during a seasonal pig feast in Papua, New Guinea. Alterations of diet, combined with borderline malnutrition, may initiate enteric toxin production, while trypsin deficiency or trypsin neutralization may prolong the toxin's half-life. Prior to the identification of *C. perfringens* toxin, pigbel was a disease of unknown origin thought to be due to many different causes, including gastrointestinal ischemia. The latter was based on the histopathologic appearance of the intes-

tinal tissue. Because of excellent epidemiologic and microbiologic investigations, the agent and its toxin have been identified. Today, treatment is available with antitoxin while prevention is possible by immunization with *C. perfringens* toxoid.<sup>126</sup>

*Clostridium perfringens* has been isolated from neonatal patients with NEC.<sup>62, 111, 117, 158</sup> Furthermore, *Clostridium*-like organisms have been identified within or around the cysts of pneumatosis intestinalis. Clostridia are required to produce gas in experimental models of intestinal gangrene. Survival is greatly reduced following experimental intestinal ischemia in germ-free rats when clostridia are introduced to the bowel. However, there is presently a paucity of clinical evidence for clostridial toxin production as a cause of NEC. The theoretical basis for a role of clostridia in the pathogenesis of NEC is much greater than the documented evidence.<sup>19, 35, 36, 111, 117, 125</sup> Much more work is needed in this area to further define the role of these anaerobic bacteria.

In the last decade we have begun to recognize many new enteropathogenic bacteria producing disease in normal or immunocompromised patients. New bacterial agents include *Campylobacter jejuni*, *C. difficile*, *Yersinia enterocolitica*, new *Vibrio* organisms, *Aeromonas hydrophila*, *Plesiomonas shigelloides*, and vero-toxin-producing *E. coli*.<sup>18, 57, 59</sup> New protozoan pathogens include *Cryptosporidium* and *Isospora* sp., while new viral enteric agents include new "rat" rotavirus, enteric adenovirus, calicivirus, Norwalk virus, and cytomegalovirus. Although research laboratories with a wide breadth of viral and bacterial expertise can identify a pathogenic agent in over 80% of cases of diarrhea, routine clinical laboratories are successful only in less than 20% to 30% of cases.<sup>18</sup> The next step needed to determine the pathogenesis of NEC must involve the same intense research laboratory efforts that have been successful in identifying the cause of many of the contagious mysteries of the 1980s (Table 7). As discussed by Glass,<sup>71</sup> we have successfully unraveled the infectious etiology of acquired immunodeficiency syndrome (AIDS), legionnaires' disease, and toxic shock syndrome, but the etiology of other common infectious-like diseases such as NEC has (to date) escaped detection. If 10% of all births in the United States

TABLE 7.  
New Potential Pathogens for Neonatal  
Necrotizing Enterocolitis

---

Rotavirus type A  
"Rat" rotavirus non-type A  
Coronavirus  
Anaerobic bacteria  
New enteric pathogens

---

are low-birth-weight infants and if the lowest incidence of NEC as reported is 1% of premature infants, then 1% of 250,000 or 2,500 cases of NEC occur each year in the United States. This is probably a very conservative estimate of a common neonatal problem. Approximately 20% to 40% of patients with NEC will die. Many of the patients with NEC had been successfully treated for other neonatal problems, such as RDS and patent ductus arteriosus. The occurrence of another lethal neonatal disease is even more tragic after overcoming a previous neonatal illness. These data suggest that NEC is a substantial perinatal public health concern that warrants close attention. To further unravel the etiologic agent or agents of NEC, the same intense effort is needed as has been applied to previous successful epidemiologic and infectious disease investigations (see Table 7).

### **TREATMENT OF NEONATAL NECROTIZING ENTEROCOLITIS**

There have been very few controlled studies of the various recommended treatment protocols for neonatal NEC. The following section is based in part on an extensive review of the literature plus the authors' review of more than 250 cases at our institution since 1970 and our direct personal experience with the management of more than 150 cases.

Because there is strong circumstantial evidence that NEC is infectious in nature, both preventive (see following) and therapeutic regimens must be directed toward infection control.<sup>106, 176</sup> Regardless of the initiating event, secondary bacterial invasion of the injured intestinal mucosa and the subsequent effects of bacterial peritonitis require prompt antimicrobial therapy. Bowel rest to reduce distention, remove fermentable substrate, and lower the oxygen requirements of the stressed intestine is also an essential component of the treatment of NEC.

Treatment must therefore be instituted when early signs of NEC appear. Current treatment protocols involve various periods of bowel rest and intestinal decompression, various periods of broad-spectrum parenteral antibiotics, and very intensive monitoring of vital signs, urine output, white blood cell and platelet counts, coagulation profile, and acid-base status.

The initial approach to the patient with suspected neonatal NEC must be similar to that of a patient with neonatal sepsis. In addition, if NEC is suspected we recommend that the surgical team be given notice of each patient with a presumptive diagnosis of NEC. Prompt notification of the surgical team involves their expertise early in the course of the illness. Prior to determining the presence or absence of pneumatosis intestinalis, all patients should have stool, blood, and urine cultures, a lumbar puncture, complete blood cell and

platelet counts, and an arterial blood gas analysis. If evidence of a bleeding disorder is manifested by ecchymosis, oozing from puncture sites, thrombocytopenia, or a microangiopathic blood smear, the coagulation status should be evaluated with a prothrombin time, partial thromboplastin time, fibrinogen level, and a check for the presence of fibrin split products. Once NEC is documented by the presence of pneumatosis intestinalis or portal venous gas on an abdominal flat plate and cross-table lateral roentgenogram, only the cross-table lateral roentgenogram needs to be repeated. The cross-table lateral position is the most appropriate view to determine if intestinal perforation has occurred as depicted by free gas within the abdomen. During the acute phase of the disease (usually day 1 to 3) this radiographic examination should be repeated every 6 to 8 hours as intestinal perforation may be "silent" or asymptomatic. Because intestinal perforation increases the risk of peritonitis and is a marker for necrotic bowel it is important to document this event, because surgery should be performed to resect the nonviable perforated intestine.

As soon as NEC is suspected all enteral feeding is discontinued (Tables 8 and 9). A large nasogastric tube is placed in the stomach to relieve gaseous distention. Parenteral broad-spectrum antibiotics are initiated and should include a semisynthetic penicillin that has activity against most gram-negative bacteria including *Pseudomonas* sp. and also has good activity against enteric anaerobic bacteria. In our nursery we employ carbenicillin or ticarcillin. In addition, a second parenteral antibiotic is given and is always an aminoglycoside, such as gentamicin. With documented bacteremia and/or prolonged treatment (greater than 3 days) with the aminoglycosides, we recommend monitoring both renal function and peak and trough aminoglycoside levels to avoid ototoxicity and nephrotoxicity. The specific penicillin or aminoglycoside employed must be compatible

TABLE 8.  
Treatment of Necrotizing Enterocolitis

---

Nothing by mouth—bowel decompression
Broad-spectrum intravenous antibiotics
Fluid replacement—resuscitation
Inotropic-vasosupportive drugs
Respiratory support
Surgery
Possible exchange transfusion
Possible WBC transfusion
Possible platelet transfusion
Possible steroids
Paracentesis—abdominal drain
Possible intravenous immunoglobulin

---



TABLE 9.

## Infectious Disease Control Measures for Necrotizing Enterocolitis\*

1. Strict handwashing with Betadine or other germicidal agent.
2. Long-sleeved gowns and gloves at bedside of each patient.
3. Separate diaper and laundry bags for each patient. Wash hands after each diaper change.
4. Cohorting and isolation of confirmed cases. Separate room and separate nurses for confirmed cases: *No cross-covering!*
5. Personnel or visitors with gastrointestinal symptoms are excluded from the nursery.
6. Above measures to continue for 1 week after symptoms have cleared, or a minimum of 10 days from onset, or as long as epidemic is present.
7. Every attempt made to identify the "agent" to include stool bacteria and viral evaluation and plasma antibody response. Collect specimen from control infants.

\*Modified from Walsh MC, Kliegman RM: Necrotizing enterocolitis: Treatment based on staging criteria. *Pediatr Clin North Am* 1986; 33:179.

with the known sensitivities of the gram-negative organisms that are present in the particular NICU population of low-birth-weight infants. Institutions other than our own nursery will also add or substitute clindamycin for broader coverage of the few enteric anaerobic bacteria that are resistant to the semisynthetic penicillin. Nonetheless in one study of patients with NEC, clindamycin-, ampicillin- and gentamicin-treated infants did no better than patients treated with ampicillin and gentamicin alone.

Enteric administration of antibiotics, specifically aminoglycosides, is not indicated during the acute phase of NEC. Previously it was thought that enteric antibiotics could reduce the incidence of gastrointestinal perforation. Prospective studies have demonstrated that oral gentamicin does not prevent intestinal perforation or alter the course of the disease.<sup>88</sup> In addition, oral aminoglycosides may be absorbed across the damaged intestines and increase serum levels, thus potentially contributing to drug toxic effects.<sup>88</sup> Furthermore, aminoglycosides may be toxic to enteric cells.<sup>153</sup> For these reasons, we cannot recommend the use of enteric aminoglycosides during the acute phase of NEC.

The duration of treatment and degree of aggressive intervention should be modified according to the severity of the illness as determined by the modified staging system proposed in the previous section (see Table 2). Patients with stage I NEC, which is either subclinical or suspected NEC or hemorrhagic colitis, may benefit from bowel rest and antibiotic therapy for 72 hours, pending the results of the cultures and the clinical course. As discussed previously, it is very unusual for infants with stage I disease to progress to a more severe stage after 48 to 72 hours from the onset of signs or symptoms. Nonetheless, at the onset of presentation with distention and pneumatosis intestinalis, the rapidity of deterioration cannot be pre-

dicted. Because of this uncertainty it is imperative that these patients be managed in a level-three ICU. It is important to have surgical backup and the ability to ventilate such patients or treat shock. After 72 hours of therapy, if the cultures are negative and the patient's course has not progressed beyond stage I and the patient does not demonstrate pneumatosis intestinalis, feeding may be cautiously reinstated. Cow milk protein formula may be used unless there is a strong suspicion of milk protein allergy. If rectal bleeding recurs while the infant is receiving milk protein-based formula, a casein hydrolysate or soy protein formula may be more appropriate. We prefer casein hydrolysate formula for very low-birth-weight infants because of the high incidence of osteopenia of prematurity associated with soy-based formulas.

Patients with documented stage II NEC will require longer periods of treatment. Benign rectal NEC or stage IIA is a mild disease and has been adequately treated with a shorter course of bowel rest and antibiotics than patients with more advanced disease. Case reports of benign NEC (stage IIA) have documented a successful outcome following treatment for as short as 3 days or as long as 10 days.<sup>134, 168</sup> Unfortunately, there are no prospective clinical controlled studies on the treatment of NEC to guide us in our management. We prefer to treat stage IIA patients for a minimum of 7 days. These infants have minimal systemic and laboratory signs and often have a normal physical examination and laboratory data within 24 to 48 hours after the onset of illness. During the treatment period of 7 days, maintenance nutritional requirements can be provided by peripheral parenteral alimentation with glucose, amino acids, fat, minerals, and vitamins.

The critically ill infant with advanced stage III NEC presents with a septic shock-like clinical picture. Bacteremia, neutropenia, disseminated intravascular coagulation (DIC), metabolic acidosis, and severe peritonitis with ascites may be present in the *absence* of radiologic evidence of intestinal perforation. Bowel edema, peritonitis, and leaky intestinal capillaries and permeable capillaries throughout the body contribute to a large third-space fluid loss, which necessitates more than the usual amounts of fluid replacement. In our NICU these critically ill infants may require as much as 200 to 300 ml/kg/day above maintenance to improve perfusion, treat hypotension and acidosis, and increase urine output. The choice of crystalloid or colloid as fluid replacement has been controversial and has not been resolved. Crystalloid replacement may require more total fluid volume than that of colloid replacement, while colloid therapy may cause protein to leak into the interstitial space, thus aggravating pulmonary disease. Both replacement fluids will cause peripheral edema due in part to the "leaky capillary syndrome" associated with shock and sepsis. When coagulation abnor-

malities are present with severe NEC, we prefer to use fresh-frozen plasma as a replacement fluid. If anemia is present, packed red cells often will improve cardiac output. End points in fluid resuscitation are normalization of the heart rate, blood pressure, and urine output and reversal of metabolic acidosis as adequate tissue perfusion is restored. A metabolic acidosis may be due to poor tissue perfusion and lactic acid production. If fluid resuscitation does not improve perfusion and acidosis, judicious use of small doses (1 mEq/kg) of sodium bicarbonate may be helpful.

If anuria or oliguria is present, overly aggressive fluid replacement may result in pulmonary edema and congestive heart failure; evaluation of the central venous pressure and respiratory status to monitor for progressive hypoxia and hypercarbia suggestive of pulmonary edema are imperative. Nonetheless, there are other causes of hypoxia or hypercarbia, as most patients with advanced stage IIIA or IIIB NEC have respiratory compromise due to abdominal distention, abdominal pain, and splinting, which will cause hypoventilation. Bacteremia, hypotension, and acidosis are additional causes of respiratory compromise. Apnea and bradycardia are common among these critically ill infants. With even the slightest signs of respiratory embarrassment, we recommend prompt endotracheal intubation and mechanical ventilation to prevent hypoxia and further compromise of the intestine. Waiting for the patient with NEC to fulfill the more conservative criteria for mechanical ventilation recommended for patients with RDS may inappropriately delay stabilization of the airway and treatment of hypoxemia.

Inotropic drugs and vasoactive agents may be of great help in patients with severe advanced NEC who manifest hypotension, acidosis, or poor peripheral tissue perfusion that does not respond to fluid resuscitation. Furthermore, because fluid overload and congestive heart failure are complications of the treatment of advanced NEC in the presence of poor renal function, vasoactive drugs may help to avoid these problems. Dobutamine and dopamine may be useful agents to improve cardiac output and thus enhance urine output. Dopamine has a more specific effect on the renal artery and may be a better choice in the presence of reversible oliguria. Low-dose dopamine is most useful for improving renal blood flow and may also improve mesenteric blood flow. When peripheral perfusion is poor, the addition of sodium nitroprusside to dopamine or dobutamine may reduce peripheral vascular resistance.

Many patients with severe advanced NEC will develop thrombocytopenia (in the absence of DIC) and/or neutropenia during the course of their disease. Peripheral margination of leukocytes or increased peripheral utilization of white blood cells may be responsible for the neutropenia rather than the bone marrow storage pool depletion that is suggested as the cause of neutropenia associated

with neonatal sepsis.<sup>39</sup> At our institution, white blood cell transfusions have not been demonstrated to be effective in improving the outcome of neutropenic patients with NEC. Patients with stage III NEC with or without perforation may have thrombocytopenia and often never develop other manifestations of DIC or bleeding; thus, platelet transfusions are not indicated in the absence of DIC or signs of bleeding. Thrombocytopenia is also very common after bowel perforation and peritonitis among adult patients. As many as 85% of adults with these problems develop thrombocytopenia. In adults, only approximately 10% of thrombocytopenic patients have DIC. Furthermore, bone marrow examination often reveals a normal marrow. Treatment does not usually require platelet transfusion as thrombocytopenia without DIC is a transient phenomenon, lasting 5 to 7 days.

Currently, the most consistently agreed on indication for surgical intervention is intestinal perforation.<sup>110, 154</sup> Intestinal perforation may be heralded by apnea, bradycardia, or a sudden increase in abdominal girth, or it may be asymptomatic and detected by routine serial cross-table lateral abdominal films. Usually intestinal perforation occurs within the first 48 hours of illness, but this has been delayed on rare occasions for as long as 1 week.

In most NICUs intestinal perforation is detected by the presence of free intra-abdominal gas on abdominal roentgenograms. This sign has traditionally been an absolute indication for surgical treatment. Nonetheless, on rare occasions, NEC in the presence of perforation has been managed medically due to the temporary lack of availability of a surgeon at the time of an epidemic.<sup>165</sup> In this report, a small number of low-birth-weight infants did as well as other patients who had previously undergone operative intervention. Furthermore, there have been reports of conservative management replacing exploratory laparotomy and intestinal resection. These therapies include the placement of a peritoneal drain, with or without peritoneal lavage with an antibiotic solution.<sup>96</sup> Although these modalities have theoretical value they must be considered experimental as their true role in the management of patients with severe NEC has not been appropriately tested in a controlled trial.

A second method to determine the presence of intestinal perforation and intestinal gangrene is by performing abdominal paracentesis.<sup>114, 169</sup> It has been hypothesized that prior to the demonstration of free intra-abdominal gas there are microperforations due to intestinal gangrene of the bowel that may result in fecal contamination of the peritoneal cavity. Kosloske and co-workers<sup>116</sup> suggested that infants with a positive peritoneal tap who undergo exploratory laparotomy have a lower mortality than infants who undergo surgery for evidence of free intra-abdominal gas. Paracentesis is performed with the right or left lower abdominal quadrant dependent, using a

small, 25-gauge needle. The fluid is examined for color and the presence of bacteria. Positive paracentesis is indicated by (1) dark yellow to brown colored fluid; (2) presence of bacteria on Gram stain; or (3) both of these. Kosloske and co-workers<sup>116</sup> have the greatest experience with paracentesis for the diagnosis of intestinal gangrene. Brown peritoneal fluid or bacteria was observed in 26 of 36 infants with NEC in one study. All 26 with a positive tap had gangrenous bowel resected during exploratory laparotomy. Four of ten infants with a negative paracentesis required surgery and were found to have necrotic bowel. Ricketts<sup>169</sup> studied the usefulness of paracentesis in patients with severe NEC and compared the outcome of patients managed with abdominal taps with those who had sudden onset of pneumoperitoneum. There were 39 patients with severe NEC who did not initially demonstrate free intra-abdominal gas and who were suspected of having bowel necrosis based on a fixed tender abdominal mass, an isolated persistent loop of bowel, erythema of the abdominal wall, or clinical deterioration. Almost all of these patients' conditions would be categorized as stage IIIA NEC according to our criteria. Thirty-four of 36 taps were positive and were confirmed when bowel necrosis was observed at exploratory laparotomy. Another group of 68 infants developed NEC with perforation documented by the presence of pneumoperitoneum, and, therefore, paracentesis was not performed. There was no difference in mortality between those infants presenting with pneumoperitoneum (24%) vs. those with positive paracentesis (29%). Although a positive paracentesis is a good indicator of intestinal necrosis, the mortality rate is no different in this group than in a group of patients with pneumoperitoneum. Interestingly, three patients in each group had total bowel involvement with NEC and had an "open-and-close" procedure prior to their death.

During laparotomy the surgeon is too often faced with what appears to be severely necrotic bowel that is too extensively affected to resect.<sup>115</sup> It is very difficult to differentiate dusky hemorrhagic intestine from that with true gangrene. If the entire bowel looks necrotic the surgeon cannot resect the total intestine, and should leave a drain in place and close the abdomen. A "second look" operation should be performed within 48 to 72 hours to determine if any areas that appeared necrotic were actually viable. Rather than creating a short-gut syndrome, which is incompatible with life without total parenteral alimentation, second look operations have occasionally prevented unnecessary extensive bowel resection. There is presently an urgent need for a method to accurately differentiate viable from nonviable bowel. Unfortunately, initial enthusiasm for fluorescence angiography has not persisted.

Previously suggested indications for surgery, other than pneumoperitoneum or a positive paracentesis, have been proposed but have

never been universally accepted. These proposed indications included thrombocytopenia, acidosis, a right lower quadrant mass, anterior abdominal wall erythema, a persistent isolated loop of bowel, hepatic portal venous gas, and clinical deterioration with failure to respond to medical management.<sup>33, 152, 183</sup> Furthermore, early operation has been proposed to prevent intestinal perforation and to improve outcome. However, various studies and our experience have not consistently found these to be valid criteria. We feel that none of these criteria alone are indications for surgery. We have cared for many patients with thrombocytopenia, acidosis, a right lower quadrant mass, persistent isolated bowel loops, abdominal wall erythema, and hepatic portal venous gas who did not go on to develop pneumoperitoneum and who did well with aggressive medical management. Clinical deterioration and failure to respond to medical management require strict criteria (Table 10). Vigorous fluid resuscitation, high-dose dobutamine with low-dose dopamine, early endotracheal intubation and mechanical ventilation, and judicious use of sodium bicarbonate must be attempted for a minimum of 24 to 48 hours (in the absence of pneumoperitoneum) before medical management should be considered to have failed. Furthermore, right lower quadrant masses probably represent localized perforations or an inflammatory mass of bowel and can be appropriately managed with medical treatment. This is analogous to medical management of a mass in a child with suspected appendicitis, in which case surgery is not always indicated.<sup>140</sup> Potential adverse therapeutic factors are cited in Table 11.

When operative intervention is indicated the surgical procedure depends on the extent of necrotic bowel.<sup>154</sup> If a short segment of nondilated bowel is involved it may be resected and a primary anastomosis performed at the time of the laparotomy.<sup>103</sup> More extensive

TABLE 10.  
Immediate Complications of Neonatal  
Necrotizing Enterocolitis

---

Sepsis
Respiratory failure
Renal failure
Shock
Patent ductus arteriosus
Anemia
Leukopenia
Thrombocytopenia
DIC
Intestinal perforation
Ascites
Gallbladder necrosis

---

TABLE 11.  
Potential Adverse Therapeutic Factors

---

Subtherapeutic antibiotic levels
Low antibody levels
Polymicrobial peritonitis
Covariant disease states

---

involvement often requires resection and enterostomy diversion. Hemicolectomy, complete colectomy, and removal of the terminal ileum with or without resection of the ileocecal valve are the most common operative procedures.

Following surgery, infants should continue to receive broad-spectrum antibiotics, which should be modified based on the sensitivities of the organisms isolated from peritoneal cultures. The duration of antibiotic treatment varies from 14 to 21 days. Patients who undergo intestinal resection of a small segment of bowel can receive parenteral nutrition by peripheral vein for 14 to 21 days. Rather than specifying a time period, bowel function, as determined by absence of gastric retention or abdominal distention and the presence of bowel sounds and ostomy drainage, should determine the period of bowel rest. Infants who undergo very extensive resection should have a central venous catheter placed in anticipation of significant short bowel syndrome. Once enteral alimentation is reintroduced after bowel function returns, we would recommend an isotonic non-lactose-containing protein hydrolysate formula. Formula volume should be increased very slowly and supplemented with peripheral or central parenteral alimentation. In severe short bowel syndrome with carbohydrate malabsorption, simple monosaccharides may be necessary to initiate enteric feedings. The sooner a patient receives enteric feeding, the greater the chance of preventing mucosal atrophy, reestablishing intestinal mucosal growth, and preventing the many adverse effects of parenteral nutrition.

## PREVENTION OF NEONATAL NECROTIZING ENTEROCOLITIS

Because there is reasonable evidence suggesting that NEC is infectious in nature, preventive measures have been directed toward the control of microbiologic agents. Prophylaxis with oral kanamycin or gentamicin has been demonstrated to have either no effect or to decrease the incidence of NEC in treated patients compared with infants receiving placebo.<sup>25, 60, 82, 178</sup> Nonetheless, multiple antibiotic-resistant stool organisms have emerged from the treated patients. Superinfection with *S. epidermidis* or *Candida* may also develop. Even with documented suppression of the gram-negative fecal flora, NEC is not completely eliminated.<sup>25</sup> Enteric aminoglycosides may

astomosis prior to discharge from the hospital to avoid rehospitalization for severe diarrhea and dehydration.

Long-term neurodevelopmental follow-up studies of patients with NEC who do not develop the chronic sequelae of short bowel syndrome, cholestatic jaundice, or other hyperalimentation complications are very encouraging<sup>1, 86, 196</sup> (Table 15). Uncomplicated cases of NEC have an excellent long-term prognosis, which is basically similar to that of their peer group of low-birth-weight infants. Often the common diseases of prematurity, such as asphyxia, RDS, and intraventricular hemorrhage, are more significant in predicting neurodevelopmental outcome than the occurrence of NEC. Moderate to severe neurologic impairment with late morbidity is usually unrelated to problems of the gastrointestinal system.<sup>85, 86</sup>

The long-term follow-up of NEC following surgical resection is less optimistic than the results after medical treatment. Both mortality and morbidity are increased among infants with more severe NEC. Very small infants often require long-term ventilation therapy, which increases the risk of bronchopulmonary dysplasia. There is a delayed mortality of 10% to 25% in these complicated cases. This mortality relates to late-onset sepsis, respiratory failure, cardiopulmonary arrest, congenital anomalies, and TPN-associated hepatic failure (see Table 15). Morbidity is associated with cirrhosis, infections, and rickets. This sequence of prolonged, chronic neonatal illness resulted in significant developmental delay among the patients who had stage IIIB NEC.<sup>85, 86</sup>

## FUTURE DIRECTIONS

We can estimate that between 2,000 and 4,000 premature infants develop NEC each year. Neonatal NEC has been listed immediately after RDS as a significant cause of death in the NICU.<sup>27</sup> Today we continue to discuss the role of intestinal ischemia, enteric feeding practices, and microbiologic agents as part of a purported triad for the pathogenesis of NEC. Nonetheless, after years of investigation, the relative importance of each of these factors remains unknown. There is also a paucity of accurate diagnostic tests to determine if a patient has NEC. This is because we often do not detect the short-

TABLE 15.  
Cholestatic Jaundice

---

Metabolic bone disease
Failure to thrive
Cirrhosis
Hepatobiliary carcinoma

---



**TABLE 12.****Factors Indicating Poor Prognosis in Neonatal Necrotizing Enterocolitis**

---

Sepsis  
Rapid-onset shock  
DIC  
Persistent acidosis  
Persistent hypotension  
Persistent respiratory failure  
Anuria  
Perforation  
Total intestinal gangrene  
Very low birth weight

---

pneumatosis intestinalis that usually occurs during epidemics of documented NEC. In addition, epidemics of NEC often vary in severity. Some epidemics are associated with severe disease, while others only consist of patients with stage IIA disease and a few patients progressing to intestinal necrosis and gangrene. Mortality during epidemics will be quite low when NEC occurs, as benign pneumatosis coli and mortality will be high during epidemics of NEC manifested as shock, intestinal perforation, and septicemia.

Chronic sequelae are a good assessment of the morbidity of NEC<sup>41</sup> (Tables 13 and 14). One of the most common late complications of

**TABLE 13.****Late Complications of Neonatal Necrotizing Enterocolitis**

---

Wound infection  
Stoma complications  
Short bowel syndrome  
Malabsorption syndrome  
Stricture formation  
Anastomotic stenosis  
Anastomotic leak  
Cholestatic jaundice  
Metabolic bone disease  
Persistent rectal bleeding  
Recurrent NEC  
Central line complications  
Vitamin B<sub>12</sub> deficiency  
Chronic salt and water depletion  
Enterocolic fistula  
Enterocyst  
Subdiaphragmatic abscess  
Polyposis  
Aganglionosis  
Atresia

---

TABLE 14.  
Central Line Complications

---

Metabolic
Hyperglycemia-hypoglycemia
Hypernatremia-hyponatremia
Hyperaminoacidemia
Hyperammonemia
Mechanical
Thrombosis—atrial, superior vena cava
Emboli
Dislodgement—pneumothorax, hydrothorax
Infections
Entry site
Tract
Bacteremia
Fungemia

---

NEC is intestinal stricture.<sup>97</sup> Stricture formation may begin during the acute phase of the disease (see section on pathology of NEC) and is most often seen in the terminal ileum or colon, which are also the areas most often involved with the acute mucosal event.<sup>97,99</sup> Strictures may be seen in medically or surgically managed patients and may be unifocal or multiple (see Fig 9). Overall, between 10% and 22% of survivors of NEC develop intestinal strictures. Universal screening with barium enema in all infants with NEC may "produce" the higher frequency. Nonetheless, this method may detect nonobstructing strictures that would never have produced clinical signs. Obstipation, hematochezia, vomiting, and abdominal distention are common signs of stricture contraction and severe obstruction. These events are due to scarring and usually become evident 2 to 8 weeks after the acute onset of NEC. In addition to presenting with signs of obstruction, strictures may also present as recurrent rectal bleeding. This is a more common event than previously recognized. As part of the evaluation of post-NEC rectal bleeding we have demonstrated active bleeding from ulcers at the base of the stricture by proctosigmoidoscopy. Following resection, the typical cicatricial histopathology was noted in the stricture but the ulcer (quite unexpectedly) demonstrated the histopathology of active NEC weeks after the initial disease. Although the strictures in these patients were resected, more recently patients have presented with post-NEC rectal bleeding who had nonobstructing strictures that were managed conservatively without surgery. Resection is not indicated for bleeding alone. Patients who are at greatest risk for stricture formation had stage IIB or III NEC. Because not all strictures identified by barium enema become obstructive, we do not recommend barium studies but do recommend careful follow-up and observation of these pa-

tients for signs of intestinal obstruction. Nonetheless, all patients treated with surgical resection must have a barium study of the distal intestinal loop prior to reanastomosis. If reanastomosis is performed with an undetected stricture in the distal intestinal segment, postoperative distention and anastomotic leakage may develop.

Infants who require surgical resection during the acute phase of NEC often have a prolonged recovery phase.<sup>4,41</sup> Some infants with what would appear to be an insignificant length of bowel removed nonetheless develop diarrhea and malabsorption syndrome.<sup>4</sup> More commonly, patients who required removal of more than 70% of the intestine have the greatest postoperative problems and require subsequent enteric alimentation. Although there is a gradual period of intestinal adaptation, months to years of nutritional therapy may be required. Preservation of the terminal ileum and ileocecal valve is important, as successful enteral alimentation is probable when these anatomic landmarks remain intact.

Problems associated with short bowel syndrome include chronic malnutrition; dehydration; osmotic diarrhea; cholestasis; deficiencies of fat-soluble vitamins, vitamin B<sub>12</sub>, iron, and calcium (resulting in osteopenia and fractures); and renal stones due in part to hyperoxaluria<sup>42</sup> (see Table 13). Added to these complications are those of prolonged hospitalization and the mechanical and infectious risks of central venous catheterization for TPN<sup>41</sup> (see Table 14).

In the term infant, intestinal length is approximately 200 cm. The smallest reported length of intestine compatible with enteric alimentation is 15 cm with an intact ileocecal valve and 20 cm without the ileocecal valve. Cooper and colleagues<sup>43</sup> reviewed their experience with acquired short bowel syndrome in infancy. Neonatal NEC was the most common cause of short bowel syndrome. Survival was 81% overall, and survivors had 44 cm of small intestine vs. 30 cm in non-survivors. Causes of death were predominantly related to TPN-associated cholestasis and not specifically due to short bowel syndrome.<sup>41,43</sup> Survivors required 13 months to be weaned from TPN to full enteric feeding. Although they are experimental procedures, other authors have tried bowel-lengthening methods and colonic interposition or bowel reversal operations to decrease transit time and improve the success rate of enteric alimentation.

Infants with resected bowel and colostomy but without short bowel syndrome often develop severe dehydration if they develop community-acquired gastroenteritis.<sup>177</sup> Fluid losses occur suddenly and often result in life-threatening salt or water losses precipitated by an otherwise minor gastrointestinal illness. This syndrome occurs because the colonic absorptive capacity for fluid and electrolytes is bypassed by the ileostomy-colostomy procedure. We currently recommend that all infants with surgically treated NEC undergo rean-

astomosis prior to discharge from the hospital to avoid rehospitalization for severe diarrhea and dehydration.

Long-term neurodevelopmental follow-up studies of patients with NEC who do not develop the chronic sequelae of short bowel syndrome, cholestatic jaundice, or other hyperalimentation complications are very encouraging<sup>1, 86, 196</sup> (Table 15). Uncomplicated cases of NEC have an excellent long-term prognosis, which is basically similar to that of their peer group of low-birth-weight infants. Often the common diseases of prematurity, such as asphyxia, RDS, and intraventricular hemorrhage, are more significant in predicting neurodevelopmental outcome than the occurrence of NEC. Moderate to severe neurologic impairment with late morbidity is usually unrelated to problems of the gastrointestinal system.<sup>85, 86</sup>

The long-term follow-up of NEC following surgical resection is less optimistic than the results after medical treatment. Both mortality and morbidity are increased among infants with more severe NEC. Very small infants often require long-term ventilation therapy, which increases the risk of bronchopulmonary dysplasia. There is a delayed mortality of 10% to 25% in these complicated cases. This mortality relates to late-onset sepsis, respiratory failure, cardiopulmonary arrest, congenital anomalies, and TPN-associated hepatic failure (see Table 15). Morbidity is associated with cirrhosis, infections, and rickets. This sequence of prolonged, chronic neonatal illness resulted in significant developmental delay among the patients who had stage IIIB NEC.<sup>85, 86</sup>

## FUTURE DIRECTIONS

We can estimate that between 2,000 and 4,000 premature infants develop NEC each year. Neonatal NEC has been listed immediately after RDS as a significant cause of death in the NICU.<sup>27</sup> Today we continue to discuss the role of intestinal ischemia, enteric feeding practices, and microbiologic agents as part of a purported triad for the pathogenesis of NEC. Nonetheless, after years of investigation, the relative importance of each of these factors remains unknown. There is also a paucity of accurate diagnostic tests to determine if a patient has NEC. This is because we often do not detect the short-

TABLE 15.  
Cholestatic Jaundice

---

Metabolic bone disease
Failure to thrive
Cirrhosis
Hepatobiliary carcinoma

---

lived or fleeting appearance of pneumatosis intestinalis. Even when present, this radiographic sign is not consistently identified from the same x-ray by more than one observer.

Epidemics of NEC strongly suggest a central role of one or more infectious agents in the etiology of this serious neonatal enterocolitis. We should pride ourselves at our recent epidemiologic advances in determining the causes of previously suspected infectious diseases among adults. These diseases include AIDS, toxic shock syndrome, and legionnaires' disease. It is now time to mount the same intensive effort at a national level to determine the etiologic factors responsible for neonatal NEC.

### *Acknowledgment*

The authors wish to express appreciation to Dr. William T. Speck for "getting it all started," to Dr. Maureen Hack for her discussion on neonatal follow-up, and to Carolyn Grier for her expert editorial assistance.

This work was supported by a grant from the Rainbow Board of Trustees and by funds from the Mead Johnson Nutritional Division and from Wyeth Laboratories.

### REFERENCES

1. Abbasi S, Pereira GR, Johnson L, et al: Long-term assessment of growth, nutritional status, and gastrointestinal function in survivors of necrotizing enterocolitis. *J Pediatr* 1984; 104:550-554.
2. Agbayani M, Rosenfeld W, Evans H, et al: Evaluation of modified gowning procedures in a neonatal intensive care unit. *Am J Dis Child* 1981; 135:650-652.
3. Ahlstedt S, Carlsson B, Fallstrom SP, et al: Antibodies in human serum and milk induced by enterobacteria and food proteins, in *Immunology of the Gut*. Ciba Foundation Symposium 46. Amsterdam, Elsevier North-Holland, 1977, pp 115-129.
4. Al-Jurf AS, Younoszai MK, Chapman-Furr F: Effect of nutritional method on adaptation of the intestinal remnant after massive bowel resection. *J Pediatr Gastroenterol Nutr* 1985; 4:245-252.
5. Aynsley-Green A: Hormones and postnatal adaptation to enteral nutrition. *J Pediatr Gastroenterol Nutr* 1983; 2:418-427.
6. Aziz EM: Neonatal pneumatosis intestinalis associated with milk intolerance. *Am J Dis Child* 1973; 125:560-562.
7. Barlow B, Santulli TV, Heird WC, et al: An experimental study of acute neonatal enterocolitis—the importance of breast milk. *J Pediatr Surg* 1974; 9:587-594.
8. Bartlett JG, Chang TW, Gurwith M, et al: Antibiotic-associated pseudomembranous colitis due to toxin-producing clostridia. *N Engl J Med* 1978; 298:531-534.
9. Bauchner H, Leventhal JM, Shapiro ED: Studies of breast-feeding and infections. How good is the evidence? *JAMA* 1986; 256:887-892.

10. Bell MJ: Perforation of the gastrointestinal tract and peritonitis in the neonate. *Surg Gynecol Obstet* 1985; 160:20–26.
11. Bell MJ, Shackelford P, Feigin RD, et al: Epidemiologic and bacteriologic evaluation of neonatal necrotizing enterocolitis. *J Pediatr Surg* 1979; 14:1–8.
12. Bell MJ, Ternberg JL, Feigin RD, et al: Neonatal necrotizing enterocolitis: Therapeutic decisions based upon clinical staging. *Ann Surg* 1978; 187:1–7.
13. Bennet R, Eriksson M, Nord C, et al: Fecal bacterial microflora of newborn infants during intensive care management and treatment with five antibiotic regimens. *Pediatr Infect Dis* 1986; 5:533–539.
14. Benirschke K: Necrotizing enterocolitis in the newborn infant: Report of 68th Ross Conference on Pediatric Research. Columbus, Ohio, Ross Laboratories, 1974, p. 27.
15. Bill AH Jr, Chapman ND: The enterocolitis of Hirschsprung's disease: Its natural history and treatment. *Am J Surg* 1962; 103:70–74.
16. Black VD, Rumack CM, Lubchenco LO, et al: Gastrointestinal injury in polythemic term infants. *Pediatrics* 1985; 76:225–231.
17. Blakey JL, Lubitz L, Campbell NT, et al: Enteric colonization in sporadic neonatal necrotizing enterocolitis. *J Pediatr Gastroenterol Nutr* 1985; 4:591–595.
18. Blaser MJ: Infectious diarrheas: Acute, chronic, and iatrogenic. *Ann Intern Med* 1986; 105:785–787.
19. Bogdan JC, Rapkin RH: Clostridia infection in the newborn. *Pediatrics* 1976; 58:120–122.
20. Book LS, Herbst JJ, Atherton SO, et al: Necrotizing enterocolitis in low-birth-weight infants fed an elemental formula. *J Pediatr* 1975; 87:602–605.
21. Book LS, Herbst JJ, Jung AL: Comparison of fast- and slow-feeding rate schedules to the development of necrotizing enterocolitis. *J Pediatr* 1976; 89:463–466.
22. Book LS, Herbst JJ, Jung AL: Carbohydrate malabsorption in necrotizing enterocolitis. *Pediatrics* 1976; 57:201–204.
23. Book LS, Overall JC Jr, Herbst JJ, et al: Clustering of necrotizing enterocolitis: Interruption by infection-control measures. *N Engl J Med* 1977; 297:984–986.
24. Borns PF, Johnston TA: Indolent pneumatosis of the bowel wall associated with immune suppressive therapy. *Ann Radiol* 1973; 16:163–166.
25. Boyle R, Nelson JS, Stonestreet BS, et al: Alterations in stool flora resulting from oral kanamycin prophylaxis of necrotizing enterocolitis. *J. Pediatr* 1978; 93:857–861.
26. Braly P, Garite T, German JC: Fetal heart rate patterns in infants in whom necrotizing enterocolitis develops. *Arch Surg* 1980; 115:1050–1053.
27. Brans YW, Escobedo MB, Hayashi RH, et al: Perinatal mortality in a large perinatal center: Five-year review of 31,000 births. *Am J Obstet Gynecol* 1982; 148:284–289.
28. British Association for Perinatal Paediatrics and the Public Health Laboratory Service Communicable Disease Surveillance Centre: Surveillance of necrotising enterocolitis, 1981–1982. *Br Med J* 1983; 287:824–826.
29. Brook I, Barrett CT, Brinkman CR III, et al: Aerobic and anaerobic bacterial flora of the maternal cervix, and newborn gastric fluid and conjunctiva: A prospective study. *Pediatrics* 1979; 63:451–455.
30. Brown EG, Sweet AY: Preventing necrotizing enterocolitis in neonates. *JAMA* 1978; 240:2452–2454.
31. Brown EG, Sweet AY: Neonatal necrotizing enterocolitis. *Pediatr Clin North Am* 1982; 29:1149–1170.

32. Bunton GL, Durbin GM, McIntosh N, et al: Necrotizing enterocolitis: Controlled study of 3 years' experience in a neonatal intensive care unit. *Arch Dis Child* 1977; 52:772-777.
33. Buras R, Guzzetta P, Avery G, et al: Acidosis and hepatic portal venous gas: Indications for surgery in necrotizing enterocolitis. *Pediatrics* 1986; 78:273-277.
34. Burdon DW, Thompson H, Candy DCA, et al: Enterotoxins of *Clostridium difficile*. *Lancet* 1981; 2:258-259.
35. Cashore WJ, Peter G, Lauermann M, et al: Clostridia colonization and clostridial toxin in neonatal necrotizing enterocolitis. *J. Pediatr* 1981; 98:308-311.
36. Chaney NE: Clostridium infection in mother and infant. *Am J Dis Child* 1980; 134:1175-1176.
37. Chany C, Moscovici O, Lebon P, et al: Association of coronavirus infection with neonatal necrotizing enterocolitis. *Pediatrics* 1982; 69:209-218.
38. Chong SKF, Blackshaw AJ, Morson BC, et al: Prospective study of colitis in infancy and early childhood. *J Pediatr Gastroenterol Nutr* 1986; 5:352-358.
39. Christensen RD, Rothstein G, Anstall HB, et al: Granulocyte transfusions in neonates with bacterial infection, neutropenia, and depletion of mature marrow neutrophils. *Pediatrics* 1982; 70:1-6.
40. Churella HR, Bachhuber WL, MacLean WC: Survey: Methods of feeding low-birth-weight infants. *Pediatrics* 1985; 76:243-248.
41. Cikrit D, West KW, Schreiner R, et al: Long-term follow-up after surgical management of necrotizing enterocolitis: Sixty-three cases. *J Pediatr Surg* 1986; 21:535-535.
42. Collins JE, Rolles CJ, Sutton H, et al: Vitamin B<sub>12</sub> absorption after necrotizing enterocolitis. *Arch Dis Child* 1984; 59:731-734.
43. Cooper A, Floyd TF, Ross AJ III, et al: Morbidity and mortality of short-bowel syndrome acquired in infancy: An update. *J Pediatr Surg* 1984; 19:711-717.
44. Cooperstock MS: *Clostridium difficile*, enterocolitis and Hirschsprung's disease. *Lancet* 1982; 1:800.
45. Corkery JJ, Dubowitz V, Lister J, et al: Colonic perforation after exchange transfusion. *Br Med J* 1968; 4:345-349.
46. Couzigou P, Reiffers J, Richard-Molard B, et al: Necrotising enterocolitis during agranulocytosis and *clostridium difficile* colitis. *Lancet* 1982; 2:720.
47. Cucchiara S, Guandalini S, Staiano A, et al: Sigmoidoscopy, colonoscopy, and radiology in the evaluation of children with rectal bleeding. *J Pediatr Gastroenterol Nutr* 1983; 2:667-671.
48. Cushing AH: Necrotizing enterocolitis with *Escherichia coli*: Heat-labile enterotoxin. *Pediatrics* 1983; 71:626-630.
49. Davis JM, Abbasi S, Spitzer AR, et al: Role of theophylline in pathogenesis of necrotizing enterocolitis. *J Pediatr* 1986; 109:344-346.
50. deLemos RA, Rogers JH Jr, McLaughlin W: Experimental production of necrotizing enterocolitis in newborn goats. *Pediatr Res* 1974; 8:380.
51. DeSa DJ: The spectrum of ischemic bowel disease in the newborn. *Perspect Pediatr Pathol* 1976; 3:273-309.
52. Diaz J, Samson H, Kessler D, et al: Experimental necrotizing enterocolitis: The possible role of bile salts in its etiology and treatment. *Pediatr Res* 1980; 14:595.
53. Donta ST, Myers MG: *Clostridium difficile* toxin in asymptomatic neonates. *J Pediatr* 1982; 100:431-434.

54. Donta ST, Stuppy MS, Myers MG: Neonatal antibiotic-associated colitis. *Am J Dis Child* 1981; 135:181-182.
55. Eastham EJ, Lichauco T, Grady MI, et al: Antigenicity of infant formulas: Role of immature intestine on protein permeability. *J Pediatr* 1978; 93:561-564.
56. Edelstone DI, Holzman IR: Regulation of perinatal intestinal oxygenation. *Semin Perinatol* 1984; 8:226-233.
57. Editorial: Clostridia as intestinal pathogens. *Lancet* 1977; 2:1113-1114.
58. Editorial: Colitis in term babies. *Lancet* 1983; 1:1083-1084.
59. Editorial: Mechanisms in enteropathogenic *Escherichia coli* diarrhea. *Lancet* 1983; 1:1254-1256.
60. Egan EA, Mantilla G, Nelson RM, et al: A prospective controlled trial of oral kanamycin in the prevention of neonatal necrotizing enterocolitis. *J Pediatr* 1976; 89:467-470.
61. Eidelman AI, Inwood RJ: Necrotizing enterocolitis and enteral feedings: Is too much just too much? *Am J Dis Child* 1980; 134:545-546.
62. Engel R: Necrotizing enterocolitis in the newborn: Report of 68th Ross Conference on Pediatric Research. Columbus, Ohio, Ross Laboratories, 1974, pp 66-71.
63. Eyal F, Sagi E, Arad I, et al: Necrotizing enterocolitis in the very low birth weight infant: Expressed breast milk feeding compared with parenteral feeding. *Arch Dis Child* 1982; 57:274-276.
64. Fanaroff A, Hack M: Feeding the neonate weighing less than 1500 grams, nutrition and beyond. Proceedings of the 79th Ross Conference on Pediatric Research, Columbus, Ohio, Ross Laboratories, 1979, pp 3-10.
65. Fanaroff A, Klaus M: The gastrointestinal tract—feeding and selected disorders, in Klaus MH, Fanaroff AA (eds): *Care of the High Risk Neonate*, ed 2. Philadelphia, WB Saunders Co, 1979, pp 113-145.
66. Finegold SM: *Anaerobic Bacteria in Human Disease*. New York, Academic Press, 1977.
67. Frantz ID III, L'Heureux P, Engel RR, et al: Necrotizing enterocolitis. *J Pediatr* 1975; 86:259-263.
68. Gall LS: The role of intestinal flora in gas formation. *Ann NY Acad Sci* 1968; 150:27-30.
69. Garland JS, Nelson DB, Rice T, et al: Increased risk of gastrointestinal perforations in neonates mechanically ventilated with either face mask or nasal prongs. *Pediatrics* 1985; 76:406-410.
- 69a. Garcia J, Smith FR, Cucinelli SA: Urinary D-lactate excretion in infants with necrotizing enterocolitis. *J Pediatr* 1984; 104:268.
70. Gerber AR, Hopkins RS, Lauer BA, et al: Increased risk of illness among nursery staff caring for neonates with necrotizing enterocolitis. *Pediatr Infect Dis* 1985; 4:246-249.
71. Glass RI: New prospects for epidemiologic investigations. *Science* 1986; 234:951-955.
72. Goldman H, Proujansky R: Allergic proctitis and gastroenteritis in children. *Am J Surg Pathol* 1986; 10:75-86.
73. Goldman HI: Feeding and necrotizing enterocolitis. *Am J Dis Child* 1980; 134:553-555.
74. Goldmann DA, Leclair J, Maccone A: Bacterial colonization of neonates admitted to an intensive care environment. *J Pediatr* 1978; 93:288-293.
75. Gotoff SP: Neonatal immunity. *J Pediatr* 1974; 85:149-157.
76. Graham MF, Halpin TC: Flexible proctosigmoidoscopy in the evaluation of necrotizing enterocolitis. *Pediatr Res* 1979; 13:495.



77. Greenfield C, Burroughs A, Szawathowski M, et al: Is pseudomembranous colitis infectious? *Lancet* 1981; 1:371-372.
78. Gregory JR, Campbell JR, Harrison MW, et al: Neonatal necrotizing enterocolitis: A 10-year experience. *Am J Surg* 1981; 141:562-567.
79. Grosfeld JL, Dalsing MC, Hull M, et al: Neonatal apnea, xanthines, and necrotizing enterocolitis. *J Pediatr Surg* 1983; 18:80-84.
80. Gross I: Necrotizing enterocolitis in the newborn infant: Report of the 68th Ross Conference on Pediatric Research. Columbus, Ohio, Ross Laboratories, 1974, p. 78.
81. Gruskay JA, Abbasi S, Anday E, et al: *Staphylococcus epidermidis*-associated enterocolitis. *J Pediatr* 1986; 109:520-524.
82. Grylack LJ, Scanlon JW: Oral gentamicin therapy in the prevention of neonatal necrotizing enterocolitis: A controlled double-blind trial. *Am J Dis Child* 1978; 132:1192-1194.
83. Guinan M, Schaberg D, Bruhn FW, et al: Epidemic occurrence of neonatal necrotizing enterocolitis. *Am J Dis Child* 1979; 133:594-597.
84. Haase GM, Sfakianakis GN, Lobe TE, et al: Prospective evaluation of radio-nuclide scanning in detection of intestinal necrosis in neonatal necrotizing enterocolitis. *J Pediatr Surg* 1981; 16:241-245.
85. Hack M, DeMonterice D, Merkatz IR, et al: Rehospitalization of the very-low-birth-weight infant. *Am J Dis Child* 1981; 135:263-266.
86. Hack M, Gordon D, Jones P, et al: Necrotizing enterocolitis in the VLBW: An encouraging follow-up report. *Pediatr Res* 1981; 15:534.
87. Han VKM, Sayed H, Chance GW, et al: An outbreak of *Clostridium difficile* necrotizing enterocolitis: A case for oral vancomycin therapy? *Pediatrics* 1983; 71:935-941.
88. Hansen TN, Ritter DA, Speer ME, et al: A randomized controlled study of oral gentamicin in the treatment of neonatal necrotizing enterocolitis. *J Pediatr* 1980; 97:836-839.
89. Head JR: Immunobiology of lactation. *Semin Perinatol* 1977; 1:195-210.
90. Henderson A, Maclaurin J, Scott JM: *Pseudomonas* in a Glasgow baby unit. *Lancet* 1969; 2:316-317.
91. Hill HR, Hunt CE, Matsen JM: Nosocomial colonization with *Klebsiella*, type 26, in a neonatal intensive-care unit associated with an outbreak of sepsis, meningitis, and necrotizing enterocolitis. *J Pediatr* 1974; 85:415-419.
92. Hillman LS, Goodwin SL, Sherman WR: Identification and measurement of plasticizer in neonatal tissues after umbilical catheters and blood products. *N Engl J Med* 1975; 192:381-386.
93. Ho ECK, Moss AJ: The syndrome of "mesenteric arteritis" following surgical repair of aortic coarctation: Report of nine cases and review of the literature. *Pediatrics* 1972; 49:40-45.
94. Howard FM, Flynn DM, Bradley JM, et al: Outbreak of necrotizing enterocolitis caused by *Clostridium butyricum*. *Lancet* 1977; 2:1099-1101.
95. Hulman S, Dunn L, Weiner J, et al: Effects of hypocaloric enteric alimentation on neonatal gastrointestinal function. *Pediatr Res* 1987; in press.
96. Janik JS, Ein SH: Peritoneal drainage under local anesthesia for necrotizing enterocolitis (NEC) perforation: A second look. *J Pediatr Surg* 1980; 15:565-568.
97. Janik JS, Ein SH, Mancor K: Intestinal stricture after necrotizing enterocolitis. *J Pediatr Surg* 1981; 16:438-443.
98. Johnson L, Bowen F, Abbasi S, et al: Relationship of prolonged pharmacologic serum levels of vitamin E to incidence of sepsis and necrotizing en-

- terocolitis in infants with birth weight of 1500 grams or less. *Pediatrics* 1985; 75:619–638.
99. Joshi VV, Winston YE, Kay S: Neonatal necrotizing enterocolitis: Histologic evidence of healing. *Am J Dis Child* 1973; 126:113–116.
  100. Karayalcin G, Kim KY, Acs H: Necrotizing enterocolitis following exchange transfusion. *NY State J Med* 1976; 76:410–413.
  101. Keller MS, Chawla HS: Neonatal metrizamide gastrointestinal series in suspected necrotizing enterocolitis. *Am J Dis Child* 1985; 139:713–716.
  102. Keyting WS, McCarver RR, Kovarik JL, et al: Pneumatosis intestinalis: A new concept. *Radiology* 1961; 76:733–741.
  103. Kiesewetter WB, Taghizadeh F, Bower RJ: Necrotizing enterocolitis: Is there a place for resection and primary anastomosis? *J Pediatr Surg* 1979; 14:360–363.
  104. Kirschner BS, Lahr C, Lahr D, et al: Detection of increased breath hydrogen in infants with necrotizing enterocolitis. *Gastroenterology* 1977; 72(5):Part 2:A57–1080.
  105. Kleinman PK, Brill PW, Winchester P: Pneumatosis intestinalis: Its occurrence in the immunologically compromised child. *Am J Dis Child* 1980; 134:1149–1151.
  106. Kliegman RM: Neonatal necrotizing enterocolitis: Implications for an infectious disease. *Pediatr Clin North Am* 1979; 26:327–344.
  107. Kliegman RM, Fanaroff AA: Neonatal necrotizing enterocolitis: A nine-year experience. I. Epidemiology and uncommon observations. *Am J Dis Child* 1981; 135:603–607.
  108. Kliegman RM, Fanaroff AA: Neonatal necrotizing enterocolitis: A nine-year experience. II. Outcome assessment. *Am J Dis Child* 1981; 135:608–611.
  109. Kliegman RM, Fanaroff AA: Neonatal necrotizing enterocolitis in the absence of pneumatosis intestinalis. *Am J Dis Child* 1982; 136:618–620.
  110. Kliegman RM, Fanaroff AA: Necrotizing enterocolitis. *N Engl J Med* 1984; 310:1093–1103.
  111. Kliegman RM, Fanaroff AA, Izant R, et al: Clostridia as pathogens in neonatal necrotizing enterocolitis. *J Pediatr* 1979; 95:287–289.
  112. Kliegman RM, Hack M, Jones P, et al: Epidemiologic study of necrotizing enterocolitis among low-birth-weight infants. *J Pediatr* 1982; 100:440–444.
  113. Kliegman RM, Pittard WB, Fanaroff AA: Necrotizing enterocolitis in neonates fed human milk. *J Pediatr* 1979; 95:450–453.
  114. Kosloske AM, Goldthorn JF: Paracentesis as an aid to the diagnosis of intestinal gangrene: Experience in 50 infants and children. *Arch Surg* 1982; 117:571–575.
  115. Kosloske AM, Martin LW: Surgical complications of neonatal necrotizing enterocolitis. *Arch Surg* 1973; 107:223–228.
  116. Kosloske AM, Papile LA, Burstein J: Indications for operation in acute necrotizing enterocolitis of the neonate. *Surgery* 1980; 87:502–508.
  117. Kosloske AM, Ulrich JA, Hoffman H: Fulminant necrotising enterocolitis associated with clostridia. *Lancet* 1978; 2:1014–1016.
  118. Krouskop R: Influence of feeding practices in neonatal necrotizing enterocolitis, in Brown EG, Sweet A (eds): *Neonatal Necrotizing Enterocolitis*. New York, Grune & Stratton, 1980, pp 57–67.
  119. Kwong MS, Dinner M: Neonatal appendicitis masquerading as necrotizing enterocolitis. *J Pediatr* 1980; 96:917–918.
  120. Lake AM, Lauer BA, Clark JC, et al: Enterovirus infections in neonates. *J Pediatr* 1976; 89:787–791.

121. Lake AM, Walker WA: Neonatal necrotizing enterocolitis: A disease of altered host defense. *Clin Gastroenterol* 1977; 6:463-480.
122. Lake AM, Whittington PF, Hamilton SR: Dietary protein-induced colitis in breast-fed infants. *J Pediatr* 1982; 101:906-910.
123. Larsen SA Jr, Homer DR: Relation of breast versus bottle feeding to hospitalization for gastroenteritis in a middle-class U.S. population. *J Pediatr* 1978; 92:417-419.
124. Larson HE, Price AB, Honour P, et al: Clostridium difficile and the aetiology of pseudomembranous colitis. *Lancet* 1978; 1:1063-1066.
125. Lawrence G, Bates J, Gaul A: Pathogenesis of neonatal necrotising enterocolitis. *Lancet* 1982; 1:137-139.
126. Lawrence G, Shann F, Freestone D, et al: Prevention of necrotising enteritis in Papua New Guinea by active immunization. *Lancet* 1979; 1:227-230.
127. Lawrence G, Walker PD: Pathogenesis of enteritis necroticans in Papua New Guinea. *Lancet* 1976; 1:125-126.
128. Leake RD, Thanopoulos B, Nieberg R: Hyperviscosity syndrome associated with necrotizing enterocolitis. *Am J Dis Child* 1975; 192:1192-1194.
129. Lebenthal E, Lee PC: Interactions of determinants in the ontogeny of the gastrointestinal tract: A unified concept. *Pediatr Res* 1983; 17:19-24.
130. Lebenthal E, Siegel M: Understanding gastric emptying: Implications for feeding the healthy and compromised infant. *J Pediatr Gastroenterol Nutr* 1985; 4:1-3.
131. LeBlanc MH, D'Cruz C, Pate K: Necrotizing enterocolitis can be caused by polycythemic hyperviscosity in the newborn dog. *J Pediatr* 1984; 105:804-809.
132. Lehmler DJ, Kanto WP Jr: Relationships of mesenteric thromboembolism, oral feeding, and necrotizing enterocolitis. *J Pediatr* 1978; 92:96-100.
133. Leonidas JC: Necrotizing enterocolitis, in Franken EA, Smith WL (eds): *Gastrointestinal Imaging in Pediatrics*, ed 2. Philadelphia, Harper & Row, 1982, pp 324-338.
134. Leonidas JC, Hall RT: Neonatal pneumatosis coli: A mild form of neonatal necrotizing enterocolitis. *J Pediatr* 1976; 89:456-459.
135. Libby J, Sullivan N, Tassell R, et al: Relationship of two toxins of *Clostridium difficile*. Presented at the American Society of Microbiology annual meeting, Dallas, March 3, 1981.
136. Lichtenberger L: A search for the origin of neonatal hypergastrinemia. *J Pediatr Gastroenterol Nutr* 1984; 3:161-166.
137. Lloyd JR: The etiology of gastrointestinal perforations in the newborn. *J Pediatr Surg* 1969; 4:77-84.
138. Mackowiak PA: The normal microbial flora. *N Engl J Med* 1982; 307:83-93.
139. Malin SW, Bhutani VK, Ritchie WW, et al: Echogenic intravascular and hepatic microbubbles associated with necrotizing enterocolitis. *J Pediatr* 1983; 103:637-640.
140. Malt RA: The perforated appendix. *N Engl J Med* 1986; 315:1546-1547.
141. Marchildon MB, Buck BE, Abdenour G: Necrotizing enterocolitis in the unfed infant. *J Pediatr Surg* 1982; 17:620-624.
142. Mata AG, Rosengart RM: Interobserver variability in the radiographic diagnosis of necrotizing enterocolitis. *Pediatrics* 1980; 66:68-71.
143. Mata LJ, Arrutia JJ: Intestinal colonization of breast-fed children in a rural area of low socioeconomic level. *Ann NY Acad Sci* 1971; 176:93-109.
144. Mizrahi A, Barlow O, Berdon W, et al: Necrotizing enterocolitis in premature infants. *J Pediatr* 1965; 66:697-706.

145. Moomjian AS, Peckham GJ, Fox WW, et al: Necrotizing enterocolitis—endemic vs. epidemic form. *Pediatr Res* 1978; 12:530.
146. Moriarty RR, Finer NN, Cox SF, et al: Necrotizing enterocolitis and human milk. *J Pediatr* 1979; 94:295–296.
147. Morriss FH Jr, Moore M, Weisbrodt NW, et al: Ontogenic development of gastrointestinal motility: IV. Duodenal contractions in preterm infants. *Pediatrics* 1986; 78:1106–1113.
148. Moss TJ, Adler R: Necrotizing enterocolitis in older infants, children and adolescents. *J Pediatr* 1982; 100:764–766.
149. Muller G, Bernsau I, Muller W, et al: Cow milk protein antigens and antibodies in serum of premature infants during the first 10 days of life. *J Pediatr* 1986; 109:869–873.
150. Muijtens HL, Zanen HC, Sonderkamp HJ, et al: Analysis of eight cases of neonatal meningitis and sepsis due to enterobacter sakazakii. *J Clin Microbiol* 1983; 18:115–120.
151. Nagaraj HS, Sandhu AS, Cook LN, et al: Gastrointestinal perforation following indomethacin therapy in very low birth weight infants. *J Pediatr Surg* 1981; 16:1003–1007.
152. Nagington J, Walker J, Gandy G, et al: Use of normal immunoglobulin in an echovirus 11 outbreak in a special-care baby unit. *Lancet* 1983; 2:443–446.
153. Neu J, Masi M, Stevenson DK, et al: Effects of asphyxia and oral gentamicin on intestinal lactase in the suckling rat. *Pediatr Pharmacol* 1981; 1:215–220.
154. O'Neill JA Jr, Stahlman MT, Meng HC: Necrotizing enterocolitis in the newborn: Operative indications. *Ann Surg* 1975; 182:274–278.
155. Orme RLE, Eades SM: Perforation of the bowel in the newborn as a complication of exchange transfusion. *Br Med J* 1968; 4:349–350.
156. Ostertag SG, LaGamma EF, Reisen CE, et al: Early enteral feeding does not affect the incidence of necrotizing enterocolitis. *Pediatrics* 1986; 77:275–280.
157. Ostrander CR, Cohen RS, Hopper AO, et al: Breath hydrogen analysis: A review of the methodologies and clinical applications. *J Pediatr Gastroenterol Nutr* 1983; 2:525–533.
158. Pederson PV, Hansen FH, Halveg AB, et al: Necrotising enterocolitis of the newborn—is it gas-gangrene of the bowel? *Lancet* 1976; 2:715–716.
159. Pitt J, Barlow B, Heird WC: Protection against experimental necrotizing enterocolitis by maternal milk. I. Role of milk leukocytes. *Pediatr Res* 1977; 11:906–909.
160. Polin RA, Pollack PF, Barlow B, et al: Necrotizing enterocolitis in term infants. *J Pediatr* 1976; 89:460–462.
161. Powell GK: Enterocolitis in low-birth-weight infants associated with milk and soy protein intolerance. *J Pediatr* 1976; 88:840–844.
162. Powell J, Bureau M, Pare C, et al: Necrotizing enterocolitis: Epidemic following an outbreak of *Enterobacter cloacae* type 3305573 in a neonatal intensive care unit. *Am J Dis Child* 1980; 134:1152–1154.
163. Rabinowitz JG, Siegle RL: Changing clinical and roentgenographic patterns of necrotizing enterocolitis. *Am J Radiol* 1976; 126:560–566.
164. Raziuddin K, Kim MH, Yao AC: Peripheral circulatory response to feeding in newborn low-birth-weight infants. *J Pediatr Gastroenterol Nutr* 1984; 3:89–94.
165. Reid WD, Shannon MP: Necrotizing enterocolitis—a medical approach to treatment. *Can Med Assoc J* 1973; 108:573–576.
166. Reisner SH, Garty B: Necrotising enterocolitis despite breast feeding. *Lancet* 1977; 2:507.

167. Richardson CJ, Rassin DK, Mills R, et al: Hexosaminidase: Potential biochemical marker for necrotizing enterocolitis in preterm infants. *Pediatr Res* 1983; 17:332A.
168. Richmond JA, Mikity V: Benign form of necrotizing enterocolitis. *Am J Dis Child* 1975; 123:301-306.
169. Ricketts RR: The role of paracentesis in the management of infants with necrotizing enterocolitis. *Am Surg* 1986; 52:61-65.
170. Rietra PJGM, Slaterus KW, Zanen HC, et al: Clostridial toxin in feces of healthy infants. *Lancet* 1978; 2:319.
171. Roback SA, Foker J, Frantz IF, et al: Necrotizing enterocolitis: An emerging entity in the regional infant intensive care facility. *Arch Surg* 1974; 109:314-319.
172. Robertson DM, Paganelli R, Dinwiddie R, et al: Milk antigen absorption in the premature and term neonate. *Arch Dis Child* 1982; 57:369-372.
173. Rogers TR, Petrou M, Lucas C, et al: Spread of *Clostridium difficile* among patients receiving non-absorbable antibiotics for gut decontamination. *Br Med J* 1981; 283:408-409.
174. Rolfe RD, Helebian S, Feingold SM: Bacterial interference between *Clostridium difficile* and normal fecal flora. *J Infect Dis* 1981; 143:470-475.
175. Rotbart H, Levin M: How contagious is necrotizing enterocolitis? *Pediatr Infect Dis* 1983; 2:406-413.
176. Rotbart HA, Levin MJ, Yolken RH, et al: An outbreak of rotavirus-associated neonatal necrotizing enterocolitis. *Pediatr Res* 1983; 17:333A.
177. Rothstein FC, Halpin TC, Kliegman RJ, et al: Importance of early ileostomy closure to prevent chronic salt and water losses after necrotizing enterocolitis. *Pediatrics* 1982; 70:249-253.
178. Rowley M, Dahlenburg GW: Gentamicin in prophylaxis of neonatal necrotizing enterocolitis. *Lancet* 1978; 2:532.
179. Ruckebusch Y: Development of digestive motor patterns during perinatal life: Mechanism and significance. *J Pediatr Gastroenterol Nutr* 1986; 5:523-536.
180. Ryder RW, Shelton JD, Guinan ME: Committee on necrotizing enterocolitis. Necrotizing enterocolitis: A prospective multicenter investigation. *Am J Epidemiol* 1980; 112:113-123.
181. Saldanha R, Kopelman AR: Treatment of infants with distended gallbladder. *Am J Dis Child* 1986; 140:328.
182. Samm M, Curtis-Cohen M, Keller M, et al: Necrotizing enterocolitis in infants of multiple gestation. *Am J Dis Child* 1986; 140:937-939.
183. Santulli TV, Schullinger JN, Heird WC, et al: Acute necrotizing enterocolitis in infancy: A review of 64 cases. *Pediatrics* 1975; 55:376-387.
184. Sawyer RB, Sawyer KC, List JE: Infectious emphysema of the gastrointestinal tract in the adult. *Am J Surg* 1970; 120:579-583.
185. Scheifele DW, Olsen E, Fussell S, et al: Spontaneous endotoxemia in premature infants: Correlations with oral feeding and bowel dysfunction. *J Pediatr Gastroenterol Nutr* 1985; 4:67-74.
186. Schussheim A, Goldstein EJC: Antibiotic-associated pseudomembranous colitis in siblings. *Pediatrics* 1980; 66:932-935.
187. Shapiro M, Stein H, Olinsky A: Necrotizing enterocolitis and exchange transfusion. *S Afr Med J* 1973; 47:1236-1238.
188. Sheretz RJ, Sarubbi FA: The prevalence of *Clostridium difficile* and toxin in a nursery population: A comparison between patients with necrotizing enterocolitis and an asymptomatic group. *J Pediatr* 1982; 100:435-439.

189. Sherman MP, Cox KL: Neonatal eosinophilic colitis. *J Pediatr* 1982; 100:587-589.
190. Shkolnik A: Confirming the presence of necrotizing enterocolitis by means of real-time ultrasound imaging. Presented at the 27th Annual Meeting of the Society for Pediatric Radiology, Las Vegas, April 1984.
191. Silber GH, Klish WJ: Hematochezia in infants less than 6 months of age. *Am J Dis Child* 1986; 140:1097-1098.
192. Simon GL, Gorbach SL: Intestinal microflora. *Med Clin North Am* 1982; 66:557-574.
193. Speer ME, Taber LH, Yow MD, et al: Fulminant neonatal sepsis and necrotizing enterocolitis associated with a "nonenteropathogenic" strain of *Escherichia coli*. *J Pediatr* 1976; 89:91-95.
194. Stark PL, Lee A: Clostridia isolated from the feces of infants during the first year of life. *J Pediatr* 1982; 100:362-365.
195. Stein H, Beck J, Solomon A, et al: Gastroenteritis with necrotizing enterocolitis in premature babies. *Br Med J* 1972; 2:616-619.
196. Stevenson DK, Kerner JA, Malachowski N, et al: Late morbidity among survivors of necrotizing enterocolitis. *Pediatrics* 1980; 66:925-927.
197. Stiennon D: Pneumatosis intestinalis in the newborn. *Am J Dis Child* 1951; 81:651-653.
198. Stoll BJ, Kanto WP Jr, Glass RI, et al: Epidemiology of necrotizing enterocolitis: A case control study. *J Pediatr* 1980; 96:447-451.
- 198a. Stork E: Personal communication, 1986.
199. Sturm R, Staneck JL, Stauffer LR, et al: Neonatal necrotizing enterocolitis associated with penicillin-resistant toxigenic *Clostridium butyricum*. *Pediatrics* 1980; 66:928-931.
200. Swanson VL, Landing BH: Pathology, in Brown EG, Sweet AY (eds): *Neonatal Necrotizing Enterocolitis*. New York, Grune & Stratton, 1979, pp 129-141.
201. Taxman T, Dahms B, Rothstein F, et al: Evaluation of rectal bleeding in newborn infants. *Pediatr Res* 1987; in press.
202. Taylor NS, Thorne GM, Bartlett JG: Separation of an enterotoxin from the cytotoxin of *Clostridium difficile*. *Clin Res* 1980; 28:285A.
203. Touloukian RJ, Kadar A, Spencer RP: The gastrointestinal complications of neonatal umbilical venous exchange transfusion: A clinical and experimental study. *Pediatrics* 1973; 51:36-43.
204. Touloukian RJ, Posch JN, Spencer R: The pathogenesis of ischemic gastroenterocolitis of the neonate: selective gut mucosal ischemia in asphyxiated neonatal piglets. *J Pediatr Surg* 1972; 7:194-205.
205. Virnig NL, Reynolds JW: Epidemiological aspects of neonatal necrotizing enterocolitis. *Am J Dis Child* 1974; 128:186-190.
206. Vukavic T: Timing of the gut closure. *J Pediatr Gastroenterol Nutr* 1984; 3:700-703.
207. White KC, Harkavy KL: Hypertonic formula resulting from added oral medications. *Am J Dis Child* 1982; 136:931-933.
208. Willis DM, Chabot J, Radde IC, et al: Unsuspected hyperosmolality of oral solutions contributing to necrotizing enterocolitis in very-low-birth-weight infants. *Pediatrics* 1977; 60:535-538.
209. Wilson R, del Portillo M, Schmidt E, et al: Risk factors for necrotizing enterocolitis in infants weighing more than 2,000 grams at birth: A case-control study. *Pediatrics* 1983; 71:19-22.
210. Wilson R, Kanto WP Jr, McCarthy BJ, et al: Epidemiologic characteristics of

- necrotizing enterocolitis: A population-based study. *Am J Epidemiol* 1981; 114:880–887.
211. Wilson R, Kanto WP Jr, McCarthy BJ, et al: Short communication. Age at onset of necrotizing enterocolitis: An epidemiologic analysis. *Pediatr Res* 1982; 16:82–84.
  212. Wilson R, Kanto WP Jr, McCarthy BJ, et al: Age at onset of necrotizing enterocolitis. *Am J Dis Child* 1982; 136:814–816.
  213. Winberg J, Wessner G: Does breast milk protect against septicaemia in the newborn? *Lancet* 1971; 1:1091–1094.
  214. Wood RE, Herman CJ, Johnson KW, et al: Pneumatosis coli in cystic fibrosis: Clinical, radiological, and pathological features. *Am J Dis Child* 1975; 129:246–248.
  215. Yale CE, Balish E: The importance of clostridia in experimental intestinal strangulation. *Gastroenterology* 1976; 71:793–796.
  216. Yu VYH, Tudehope DI, Gill GJ: Neonatal necrotizing enterocolitis. 2. Perinatal risk factors. *Med J Aust* 1977; 1:688–693.
  217. Zeissler J, Rassfeld-Sternberg L: Enteritis necroticans due to *Clostridium welchii* type F. *Br Med J* 1949; 1:267–269.