



Since January 2020 Elsevier has created a COVID-19 resource centre with free information in English and Mandarin on the novel coronavirus COVID-19. The COVID-19 resource centre is hosted on Elsevier Connect, the company's public news and information website.

Elsevier hereby grants permission to make all its COVID-19-related research that is available on the COVID-19 resource centre - including this research content - immediately available in PubMed Central and other publicly funded repositories, such as the WHO COVID database with rights for unrestricted research re-use and analyses in any form or by any means with acknowledgement of the original source. These permissions are granted for free by Elsevier for as long as the COVID-19 resource centre remains active.

VRR 00329

Response of genetically susceptible and resistant mice to intranasal inoculation with mouse hepatitis virus JHM

Stephen W. Barthold¹ and Abigail L. Smith²

Section of Comparative Medicine^{1,2} and *Department of Epidemiology and Public Health*²,
Yale University School of Medicine, New Haven, CT 06510, U.S.A.

(Accepted for publication 7 January 1987)

Summary

Mouse hepatitis virus (MHV)-JHM infection was studied in genetically susceptible (BALB/cByJ) and resistant (SJL/J) mice following intranasal inoculation at 1, 3, 6 or 12 wk of age. Markers of infection included histology, immunohistochemistry, virus quantification and virus serology. All BALB mice developed severe disseminated disease with high mortality due to encephalitis and hepatitis. Peak MHV titers appeared in brain, liver, spleen and intestine on days 3 or 5. Age at inoculation did not influence virus titers in brain, spleen or intestine, but virus titers in liver were inversely proportional to age at inoculation. In 6-wk-old BALB mice, virus was cleared from spleen, intestine and liver by day 30 and from brain by day 60. In intestine, MHV was localized to lymphoid tissue, without fecal excretion. SJL mice of all ages developed remarkably milder disease with low mortality occurring only among mice inoculated at 1 wk of age. SJL mice inoculated at 1 wk had disseminated infection at day 3, but lesions and antigen were cleared from most organs by day 5. Mice inoculated at 3 and 6 wk of age had minimal or no involvement of peripheral organs, and mice inoculated at 12 wk of age had infections restricted to the nose. At day 5, MHV titers in brain, liver, spleen and intestine were significantly lower or undetectable in SJL mice of all ages compared to age-matched BALB mice. In 6-wk-old mice, MHV was cleared from all organs by day 10. Serum antibody titers to MHV were many-fold higher in BALB mice, compared to SJL mice, which mounted only a modest response.

Mouse hepatitis virus; Corona virus; Mouse

Address for correspondence: Stephen W. Barthold, Section of Comparative Medicine, Yale University School of Medicine, New Haven, CT 06510, U.S.A.

Introduction

Since its initial isolation from the brains of mice with posterior paresis (Cheever et al., 1949), the JHM strain of mouse hepatitis virus (MHV) has received considerable attention as a neurotropic MHV strain that experimentally induced encephalitis and demyelination in mice and rats (Bailey et al., 1949; Goto et al., 1977; Knobler et al., 1981, 1982; Sorenson et al., 1980; Stohlman et al., 1981; Wege et al., 1981, 1983; Weiner et al., 1973). Although its neurotropic properties have been emphasized, MHV-JHM is similar to several other MHV strains and isolates, with tropism for not only brain, but also many other tissues in susceptible hosts (Barthold and Smith, 1984; Barthold 1986). Strains such as MHV-S and MHV-A59 also produce brain lesions similar to MHV-JHM (Barthold et al., 1986; Barthold and Smith, 1983; Koolen et al., 1983; Taguchi et al., 1979; Woyciechowska et al., 1984). It is now becoming apparent that different MHV strains, like coronaviruses of other species (Wege et al., 1982), are either primary upper-respiratory or enteric pathogens in mice. In hosts that are more susceptible by virtue of immaturity, genotype, or impaired lymphoreticular function, respiratory MHV strains are likely to disseminate secondarily to multiple organs, but enterotropic MHV strains tend to be more restricted to enteric mucosa (Barthold, 1986; Barthold et al., 1985). Commonly studied, prototype MHV strains (1, 3, A59, JHM, S), are primary respiratory viruses in the mouse.

Since most studies with MHV-JHM have utilized artificial, usually intracerebral (i.c.), routes of inoculation with emphasis on neurotropism, this study was initiated to investigate the full spectrum of effects induced by this virus following a natural (intranasal) route of inoculation. Genotype and age are important determinants in MHV disease (Wege et al., 1982; Barthold, 1986; Bang, 1978) and were thus incorporated into this investigation. These results will provide a clearer understanding of the pathogenesis of this frequently studied MHV strain, as well as of respiratory MHV strains in general.

Materials and Methods

Experimental plan and rationale

Mouse strains were selected for known susceptibility (BALB/cByJ) or resistance (SJL/J) to i.c. inoculation with MHV-JHM (Knobler et al., 1981b,c, 1982; Stohlman and Frelinger, 1978). Pilot studies confirmed this dichotomy in susceptibility following intranasal (i.n.) inoculation. Resistance of various mouse genotypes to different MHV strains, including MHV-JHM, has been shown to evolve between 1 and 4 wk of age (Bang, 1978; Gallily et al., 1966; Pickel et al., 1981; Taguchi et al., 1977, 1979b). Resistance of SJL mice to i.c. inoculation with MHV-JHM further evolves between 6 and 12 wk of age (Stohlman et al., 1980, 1982). Thus, mice were inoculated with MHV-JHM at 1, 3, 6 and 12 wk of age. Sufficient numbers of mice were inoculated to obtain groups of 3–5 mice of each genotype and of each age group at days 3, 5, 10, 20 and 30 after inoculation. Additional groups of BALB mice

exposed at 6 wk of age were collected at days 60 and 90 after inoculation. Within age groups, mice were selected for necropsy on these days using a table of random numbers. Day 5 was chosen as a peak interval for MHV infection (Barthold and Smith, 1984), and other intervals were selected to examine the early phase (day 3) and recovery or chronic phases (days 10–90) of infection. Markers of infection included immunohistochemistry on tissues from all major organs, virus quantification in selected target tissues and serum antibody to MHV-JHM.

Mice

BALB/cByJ and SJL/J mice were purchased from The Jackson Laboratory, Bar Harbor, Maine, and shipped in filtered boxes. Upon arrival, mice were transferred into autoclaved Micro-Isolator containment cages (Lab Products, Inc., Maywood, N.J.) with autoclaved pine shavings, food (Purina Laboratory Chow, Ralston Purina Co., St. Louis, MO) and water. Late pregnant CRI:CD1BR Swiss mice were purchased from Charles River Laboratories, Inc., Portage, MI. They were shipped and maintained under similar conditions. Uninfected Swiss sentinel mice were maintained in open cages in the animal room during the course of these studies. They were tested periodically for serum MHV antibody to ensure that proper containment of experimental MHV was effected and that adventitious MHV had not been introduced to the animal room. Mice from both commercial sources were MHV-free. Mice were killed with carbon dioxide gas and exsanguinated by cardiac puncture. Tissues were frozen at -70°C until tested for MHV infectivity, or were placed in 10% neutral buffered formalin (pH 7.2) for immunohistochemistry.

Virus

MHV-JHM was obtained from the American Type Culture Collection, Bethesda, Maryland, passaged twice in NCTC 1469 cells, once in adult BALB/cByJ brain and once in 17 Cl 1 cells (Sturman and Takemoto, 1972) and frozen in aliquots at -70°C until used. All mice were inoculated twice i.n. with $10\ \mu\text{l}$ of cell-free culture fluid containing 10^3TCID_{50} of MHV-JHM. Unlike other routes of inoculation, disease severity is not affected by higher i.n. doses of MHV beyond the infectious dose (Barthold et al., 1986). Because of the relative insensitivity of cell culture for MHV detection, infant mouse infectivity assays were used for MHV quantification in target tissues. The $\log_{10}\text{LD}_{50}$ per g of tissue was determined for brain, liver, spleen and intestine at day 5 after inoculation in mice of both genotypes and all age groups and at days 0, 3, 5, 10, 20 and 30 after inoculation in mice of both genotypes inoculated at 6 wk of age. In addition, virus in brains of BALB mice exposed at 6 wk of age and collected on days 60 and 90 after inoculation was titrated. Tissues were thawed, weighed and diluted 10% (w/v) in Dulbecco's minimal essential medium containing 5% fetal bovine serum. They were homogenized and clarified in a refrigerated centrifuge at 2000 rpm for 20 min. Serial 10-fold dilutions of supernates in 0.025 ml vol were inoculated i.c. into 2-day-old suckling Swiss pups. Four pups were inoculated per dilution and endpoint mortality was established at 72 h after inoculation. The $\log_{10}\text{LD}_{50}$ per g of tissue was calculated using the method of Reed and Muench (1938). Means were calculated as geometric means.

Statistical analysis

Virus titers were compared between organs or groups using the Student's paired *t*-test (same animal) or unpaired *t*-test. Linear regression was utilized to analyze the relationship of virus titers in a target organ with age (Steel and Torrie, 1960).

Immunohistochemistry

Formalin-fixed tissues were paraffin embedded, sectioned at 5–7 μm and examined for histopathology. MHV antigen was detected using an avidin–biotin peroxidase complex method, counterstained with hematoxylin, as previously described (Barthold, 1985). Hyperimmune mouse ascitic fluid was prepared in multiparous female Swiss mice by 3 once-weekly intraperitoneal injections of MHV-JHM infected infant mouse brain emulsified in Freund's complete adjuvant. The following tissues were specifically examined for MHV antigen and lesions in mice of both genotypes, all ages and all intervals: nose, eye, brain, spinal cord, lung, liver, spleen, submaxillary and mesenteric lymph nodes, salivary glands, bone and bone marrow, small intestine, cecum, colon, kidney, urinary bladder and gonad. Immunohistochemistry was performed in batches, each of which included positive and negative antiserum and antigen controls.

Serology

Sera collected from mice inoculated at 6 wk of age were tested at two-fold dilutions beginning at 1:20 (SJL) or 1:50 (BALB) in an enzyme immunoassay (EIA) to determine antibody titers (Smith and Winograd, 1986). The antigen in the EIA was formalin fixed, MHV-JHM-infected 17 Cl 1 cells, and the detecting antibody was horseradish peroxidase-conjugated goat anti-mouse IgG (BioRad, Richmond, CA) diluted 1:3000. After addition of ABTS substrate (Kirkegaard and Perry, Gaithersburg, MD), plates were read spectrophotometrically at 410 nm. Wells were considered positive if the mean OD₄₁₀ for infected cells exceeded by three standard deviations the mean OD₄₁₀ for uninfected cells treated with the same serum dilution.

Results

Immunohistochemistry / pathology

BALB/cByJ mice. Mice of all age groups developed disseminated MHV infections on days 3 and 5, with mortality rate of approximately 50% by day 5 among mice inoculated at 3 or more wk of age and 100% among mice inoculated at 1 wk of age. Encephalitic signs became pronounced on day 4 after inoculation. Viral antigen was accompanied by necrotizing inflammation and viral syncytium formation in nose, olfactory bulb, brain, spinal cord, bone marrow, spleen, lymph nodes, liver and gut-associated lymphoid tissue (Fig. 1). The time of appearance, organ distribution and duration after inoculation of MHV antigen correlated identically with virus detection in tissues. In lung, viral antigen was sparse and associated with vascular

Tissue	BALB/cByJ				SJL/J			
	weeks				weeks			
	1	3	6	12	1	3	6	12
Nose	■	■	■	■	■	■	■	■
Brain/cord	■	■	■	■	■	□	□	□
Bone marrow	■	■	■	■	■	□	□	□
Lymph node	■	■	■	■	■	■	■	■
Spleen	■	■	■	■	■	■	■	□
Liver	■	■	■	■	■	□	□	□
Intestine*	■	■	■	■	■	□	□	□
Lung	■	■	■	■	□	□	□	□
Gonad	■	□	□	□	□	□	□	□
Kidney	□	□	□	□	□	□	□	□
Urinary bladder	□	□	□	□	□	□	□	□
Salivary glands	□	□	□	□	□	□	□	□
Skeletal muscle	□	□	□	□	□	□	□	□
Bone	□	□	□	□	□	□	□	□

* Gut associated lymphoid tissue

■ = MHV antigen detected in 1 or more mice

■ (with diagonal line) = Minimal MHV antigen detected in 1 or more mice

□ = No MHV antigen detected in any mice

Fig. 1. Summary of MHV antigen distribution in tissues on days 3 and 5 after MHV-JHM inoculation of BALB/cByJ and SJL/J mice at age 1, 3, 6, or 12 wk.

endothelium. Antigen was found sporadically in the eye, but generally not in genitourinary organs, bone, salivary glands or intestinal mucosa. In nose, lung and lymphoid tissues, MHV antigen was most pronounced on day 3, with diminution on day 5, and most pronounced on day 5 in brain, liver and bone marrow. Mortality was associated with encephalitis and hepatitis, since brain and liver were the most severely affected organs. With the exception of brain in mice inoculated at 1 wk of age, no differences in lesion severity and/or distribution of MHV antigen were apparent among age groups.

In mice inoculated at 3–12 wk of age, lesions and antigen extended from the nose to the olfactory bulb, then along the meninges and parenchyma of the anteroventral brain to the hippocampus and posterior brain stem. Olfactory bulbs were infected at day 3, and encephalitis was most severe and widespread at day 5. Neurons, glia and their cell processes contained MHV antigen (Fig. 2). In other organs, lesions and antigen were more randomly distributed, suggesting hematogenous infection. Lesions were often found adjacent to blood vessels. In liver, groups of hepatocytes, and to a lesser extent Kupffer cells, contained antigen, often with necrosis and leukocytic infiltration (Fig. 3). In spleen, antigen was most prevalent in lymphoid regions (Fig. 4). Mice inoculated at 1 wk of age had a similar pattern of disseminated infection. However, lesions and antigen in brain were diffusely distributed, rather than restricted to olfactory pathways as seen in older mice. This suggested hematogenous infection of brain in the neonate.

In surviving BALB mice, lesions and antigen had largely disappeared from nose, lymphoid tissue, bone marrow, spinal cord, olfactory bulb and lung by day 10 after inoculation. Encephalitis and hepatitis in the presence of MHV antigen were less

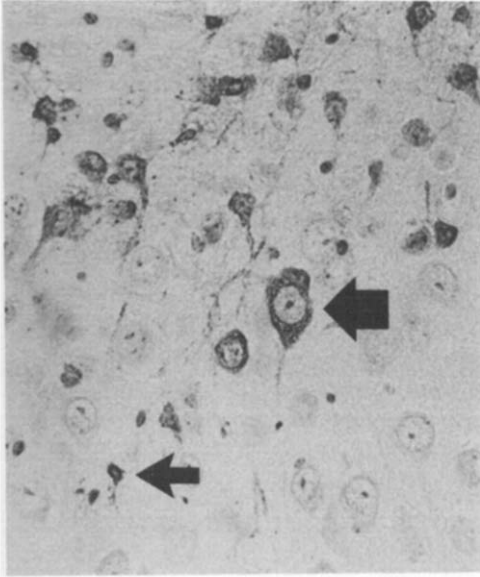


Fig. 2. MHV antigen in cell bodies and processes of neurons (large arrow) and glia (small arrow) in the hippocampus of a BALB/cByJ mouse, 5 days after MHV-JHM inoculation. Immunoperoxidase and hematoxylin, 335 \times .

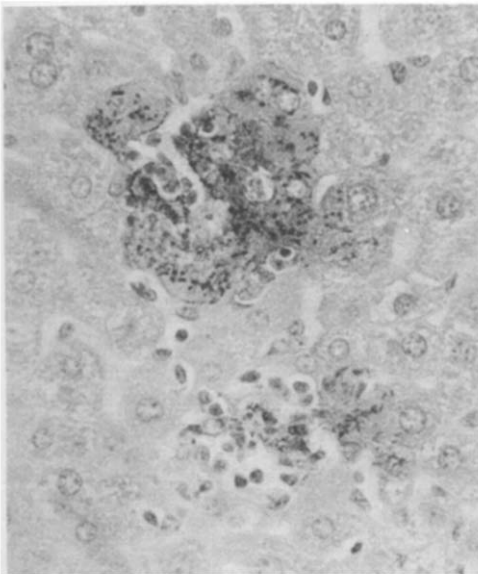


Fig. 3. Focal hepatitis associated with MHV antigen in hepatocytes of a BALB/cByJ mouse 5 days after MHV-JHM inoculation. Immunoperoxidase and hematoxylin, 335 \times .

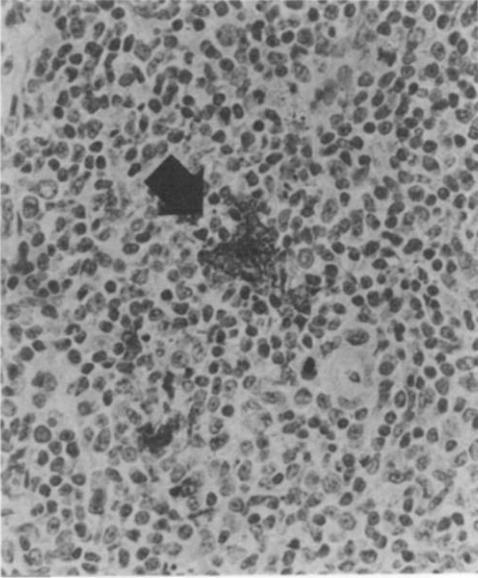


Fig. 4. MHV antigen in a cluster (probably syncytium) of lymphoid cells (arrow) within splenic white pulp of a BALB/cByJ mouse, 3 days after MHV-JHM inoculation. Immunoperoxidase and hematoxylin, 335 \times .

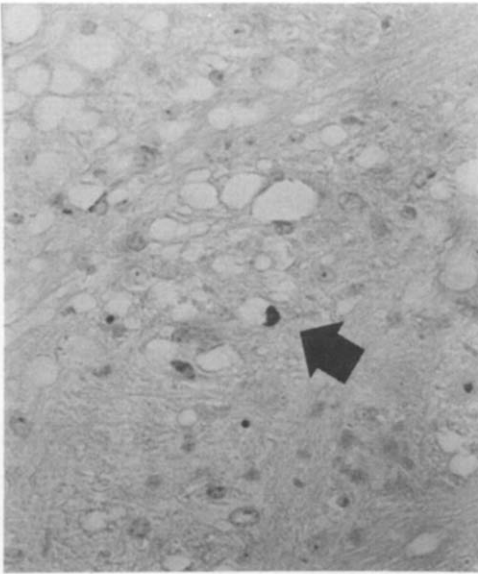


Fig. 5. MHV antigen in a single glial cell (arrow) within an area of brainstem spongiosis of a BALB/cByJ mouse, 20 days after MHV-JHM inoculation. Immunoperoxidase and hematoxylin, 335 \times .

severe and associated with lymphocytic, and in brain, glial infiltrates. Early spongiosis was present in the brain stem of some mice. By day 20, livers had residual mineralized scars without MHV antigen. Encephalitis had also largely disappeared, but there was a high prevalence of spongiosis with gliosis and demyelination localized to brain stem. In these spongiform areas, antigen was present in a few glial cells (Fig. 5). Brains of most mice exposed at 6 wk and examined 60 days later had mild resolving spongiform lesions, and brains at 90 days had no visible lesions.

SJL mice. SJL mice of all ages had remarkably milder disease than BALB mice. Mice inoculated at 1 wk of age experienced moderate mortality, which was heralded by encephalitic signs. Lesions and antigen of 1-wk-old SJL mice resembled BALB mice, and were found in nose, olfactory bulb, brain, liver, spleen, lymph nodes, bone marrow and gut associated lymphoid tissue (Fig. 1). Lesions and antigen had cleared from most organs, with the exception of nose and brain, by day 5. No mortality occurred among SJL mice inoculated at 3 or more wk of age. They had minimal visible lesions, with mild nasal involvement and sporadic, mild inflammation of olfactory bulbs, liver and lymphoid tissues on days 3 and 5. On day 5, livers contained multiple microgranulomas, consisting of small nodular accumulations of macrophages and lymphocytes. Viral antigen was restricted to a few Kupffer cells at day 3. Complete recovery was apparent by day 10 in SJL mice of all age groups, including the surviving mice inoculated at 1 wk of age.

Virus quantification

Age and genotypic differences at day 5 after inoculation

Virus titers in major target organs at day 5 after inoculation revealed age and genotype-related differences (Figs. 6, 7). Among BALB mice, virus reached equally high titers in brain and liver, and lower titers were detected in spleen and intestine. No statistically significant differences in virus titer could be detected in any organ between BALB age groups. However, there was an inverse correlation between virus titers in liver and age at inoculation ($P \leq 0.01$, $r = -0.56$). Among SJL mice, age appeared to influence involvement of different organs. SJL pups infected at 1 wk of age had highly variable virus titers in brain. SJL mice infected at 3 wk of age had no or low titers of brain virus, and older groups were negative. These data suggested that 1 wk of age represented a pivotal point in age-related resistance of brain to MHV-JHM infection. Therefore, an additional group of 3-day-old SJL pups was inoculated. Virus titers in their brains were uniformly high at 5 days (range 11.3 to 12.4, mean $11.8 \pm 0.6 \log_{10} \text{LD}_{50}/\text{g}$). Livers were uniformly negative for detectable virus at day 5 in all SJL age groups and only 1 of 3 livers from SJL pups inoculated at 3 days of age had a low level of virus activity. Virus was present in spleen and intestine in 1- and 3-wk-old mice, intestine of 6-wk-old mice, but neither spleen nor intestine contained virus in 12-wk-old mice. Since all organs were negative at day 5 in 12-wk-old mice, they were tested for virus at 3 days after inoculation and also found to be negative. Nevertheless, viral antigen was present in the nasal mucosa of SJL mice from all age groups, including all of the 12-wk-old mice examined on day 3 after inoculation.

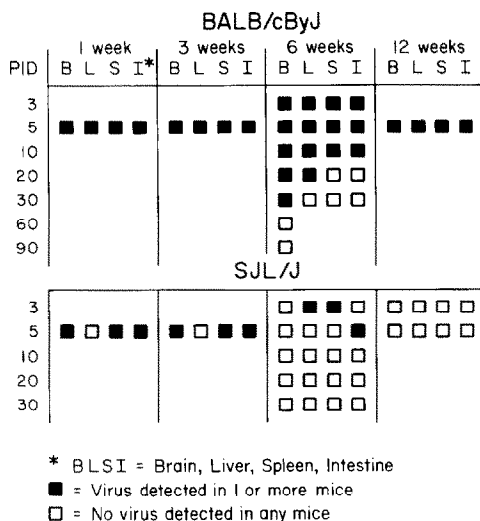


Fig. 6. Summary virus recovery from selected organs on day 5 after MHV-JHM inoculation of 1-, 3-, 6- or 12-wk-old BALB/cByJ and SJL/J mice and on different post-inoculation days (PID) after inoculation of 6-wk-old BALB/cByJ and SJL/J mice.

Comparison of virus titers between genotypes at day 5 in different organs revealed marked differences (Fig. 7). With the exception of virus titers in brain of mice infected at 1 wk of age, BALB mice had higher titers of virus in brain and liver than SJL mice of corresponding age ($P \leq 0.001$). Virus titers in spleen were consistently higher in BALB compared to SJL mice in all age groups ($P \leq 0.05$ for 1, 3 wk; $P \leq 0.001$ for 6, 12 wk). Although intestinal virus titers were higher in 1- and 3-wk BALB mice compared to SJL mice, they were not statistically different. Significant differences were found in intestinal virus titers between genotypes in the 6- and 12-wk age groups ($P \leq 0.05$, ≤ 0.001 , respectively).

Genotypic patterns at intervals after inoculation of adult (6-wk) mice

Titers of MHV-JHM were determined in brain, liver, spleen and intestine at 0, 3, 5, 10, 20 and 30 days after inoculation of 6-wk-old BALB and SJL mice (Fig. 8). No virus was detected on day 0 (within 1 h after inoculation). In BALB mice, virus was detectable in all organs by day 3. Virus activity peaks at this interval in spleen and intestine. Virus titers in brain and liver continued to rise through day 5, when mortality reached its zenith. Virus was cleared from spleen and intestine between days 10 and 20 and from liver between days 20 and 30. Brains, however, had uniform but low virus activity through day 30. Additional groups of BALB mice examined at 60 and 90 days revealed no detectable virus in brain among 9 mice at 60 days or among 5 mice at 90 days. In SJL mice, low titers of virus were transiently detectable in liver and spleen on day 3 and in intestine on day 5, but not other intervals. Brain was not infected. Virus titers on day 3 in liver and spleen were lower in SJL mice than in BALB mice ($P \leq 0.01$ liver, ≤ 0.05 spleen).

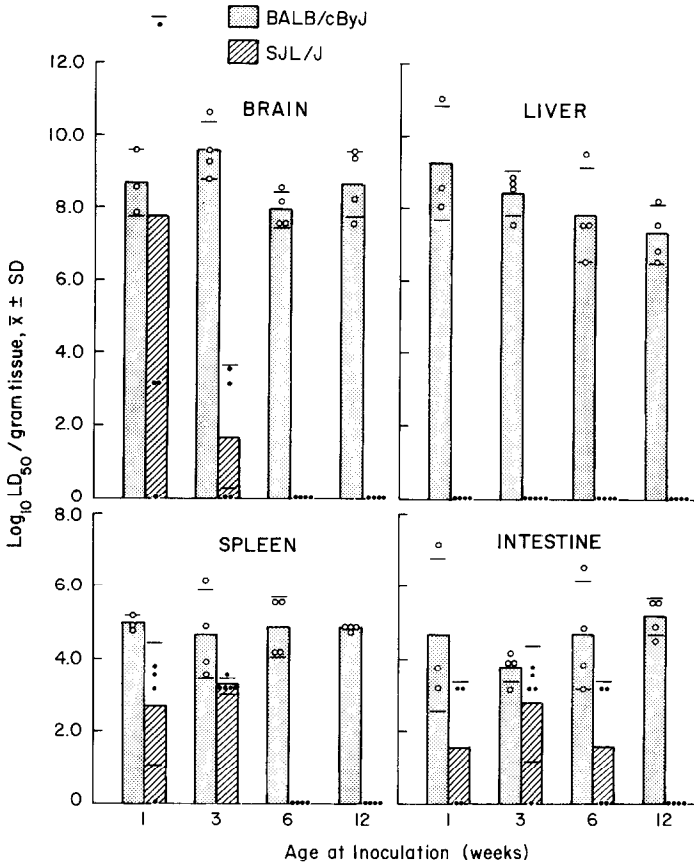


Fig. 7. Comparison of MHV titers ($\log_{10} LD_{50}/g$) in selected tissues on day 5 after MHV-JHM inoculation of 1-, 3-, 6- or 12-wk-old BALB/cByJ and SJL mice.

Supplemental Intestinal Studies

Because virus was frequently detected in intestine, but antigen was found only in gut associated lymphoid tissue, an attempt was made to confirm the location of

TABLE 1

MHV-JHM TITERS IN DIFFERENT INTESTINAL COMPONENTS OF 3-wk-old BALB/cByJ MICE AT 3 DAYS AFTER INTRANASAL INOCULATION.

Intestinal component	Virus titer $\bar{x} \pm SD$ *
Cecal feces	NVD
Intestinal wall without GALT	NVD
Intestinal wall with GALT	5.8 ± 0.7
Mesenteric lymph node	5.9 ± 1.0

* $\log_{10} LD_{50}/g$; NVD = no virus detected; GALT = gut associated lymphoid tissue.

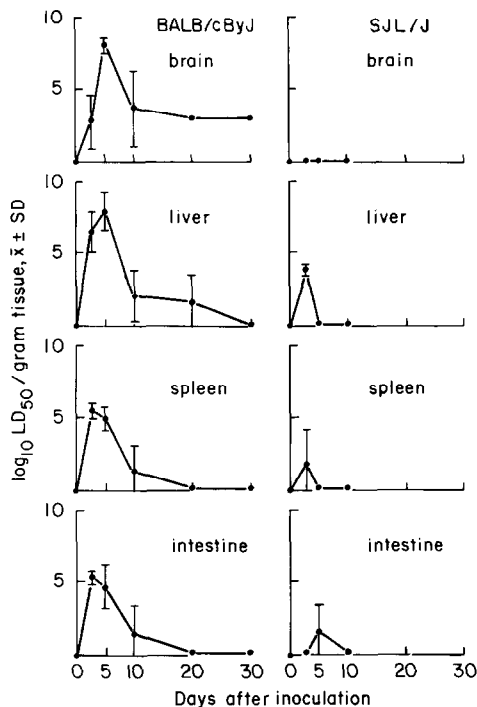


Fig. 8. Comparison of MHV titers (\log_{10} LD₅₀/g) in selected tissues at intervals after MHV-JHM inoculation of 6-wk-old BALB/cByJ and SJL mice.

virus activity in the intestine. An additional group of five 3-wk-old BALB/cByJ mice was inoculated i.n. with MHV-JHM. On day 3 after inoculation, the small intestine was dissected free of mesenteric tissue and its lumen flushed free of digesta with sterile saline. Mesenteric lymph node, ileal wall with and without Peyer's

TABLE 2

MHV ANTIBODY DETECTION BY ENZYME IMMUNOASSAY (EIA) IN SERA OF BALB/cByJ AND SJL/J MICE INOCULATED INTRANASALLY WITH MHV-JHM AT AGE 6 wk

Day after inoculation	Genotype	
	BALB	SJL
5	0/4	0/4
10	4/4 (8,000 ± 3,132)	1/4 (20)
20	4/4 (16,000 ± 2,400)	2/3 (400 ± 0)
30	6/6 (14,848 ± 2,804)	4/5 (600 ± 173)
60	9/9 (9,216 ± 2,762)	
90	5/5 (11,520 ± 4,160)	

Number positive/number tested (reciprocal of geometric mean titer ± SE).

patches, and cecal feces were collected separately and assayed for virus. Virus activity was localized to lymphoid tissue (mesenteric lymph node and Peyer's patches), but was not detected in non-lymphoid ileal wall or feces (Table 1).

Serology

There was a marked difference in antibody response between BALB and SJL mice that were inoculated at 6 wk of age (Table 2). Mice of both genotypes had detectable antibody at 10, but not 5 days after inoculation. Antibody titers were significantly higher among BALB mice and all had seroconverted by day 10 and beyond. In contrast, not all SJL mice seroconverted, despite confirmed infection in all 6 wk SJL mice at 3 days after inoculation, based on MHV antigen in nasal mucosa. Antibody titers never exceeded 1:1600 (one mouse on day 30).

Discussion

Based on mortality, resistance of several mouse genotypes to different MHV strains has been shown to evolve between 1 and 4 wk of age (Bang, 1978; Gallily et al., 1966; Taguchi et al., 1977; 1979b). Among susceptible BALB mice in the present study, mortality was highest in the youngest age group, but virus titers in most target organs did not reflect age-related differences. We did find, however, decreasing virus titers in liver with increasing age at inoculation in BALB mice. Mice of the SJL genotype are exceptionally resistant to mortality following i.c. inoculation with MHV-JHM, particularly after 6 wk of age (Knobler et al., 1981b, c, 1982; Stohlman and Frelinger, 1978; Stohlman et al., 1980, 1982). We found that resistance of SJL mice to i.n.-inoculated MHV-JHM occurs early in life and may evolve at different rates in different organs. Brain resistance to i.n. inoculation appeared to begin in mice inoculated at 1 wk of age, was relatively strong in mice inoculated at 3 wk of age, and absolute in older mice. Mice infected at 3 days of age were highly susceptible to brain infection. Liver was remarkably resistant to infection in all SJL age groups, including mice infected as young as 3 days of age. Lymphoid tissue was a target in SJL mice inoculated at 3 or less wk of age, but not older mice. It is difficult to assess if these differences were due to reduced access of virus to target tissues or tissue resistance per se, since mice were inoculated i.n. with virus. Tissue resistance is likely, since it has also been shown that direct i.c. inoculation of 4–5-wk-old SJL mice with MHV-JHM resulted in low levels of virus replication in brain, liver and spleen at 2 days, but virus had cleared by 4–7 days after inoculation (Knobler et al., 1982). Age-related differences do not appear to be due to acquired immunity to MHV, since our studies precluded natural exposure.

In BALB mice infected at 3 wk of age or older, antigen distribution patterns suggested that virus reached brain primarily by direct naso-olfactory extension. Other studies have also suggested this mechanism of brain infection, following i.n. inoculation with MHV-JHM, as well as with MHV-1, -3, -A59, and -S (Barthold et al., 1986; Barthold and Smith, 1983; Goto et al., 1977; Koolen et al., 1983; Taguchi

et al., 1979a). Mice infected at 1 wk of age developed diffuse brain infection, with a vascular distribution, as seen in suckling mice infected oronasally with several MHV strains (Barthold and Smith, 1984). Regardless of age, there was vascular dissemination of MHV-JHM to other organs, particularly liver and lymphoid tissues.

Nasal mucosa seems to be the major mucosal target for MHV-JHM excretion, since other potential excretory organs were not significantly involved. The nose has been shown to be an important target organ of MHV-JHM and MHV-S (Barthold and Smith 1983; Goto et al., 1977; Taguchi et al., 1979a). A number of MHV strains, including MHV-JHM, have been shown to infect lung following i.n. inoculation. However, viral antigen is restricted to alveolar septal cells, usually endothelium, rather than airway epithelium (Barthold and Smith, 1983, 1984; Carthew and Sparrow, 1981). Intestine was infected in mice of the present study, but virus activity was localized to gut-associated lymphoid tissue, with no appreciable virus in feces. In contrast, enterotropic MHV strains replicate nearly exclusively in enteric mucosal epithelium, regardless of age or genotype (Barthold, 1986; Barthold and Smith, 1984; Barthold et al., 1985). Our current data support other studies (Barthold and Smith, 1984) showing that urinary organs do not play a significant role in MHV replication and excretion. Reproductive tract transmission has not been fully explored. Vertical transmission in utero has been shown experimentally following intravenous MHV-JHM inoculation (Katami et al., 1978). Furthermore, MHV-like particles have been observed in endometrium of naturally infected athymic nude mice (ConSmith et al., 1976).

I.n. inoculation of adult BALB mice induced a uniform pattern of brain infection, resulting in encephalitis at 5 days after inoculation and development of localized brainstem spongiform lesions with demyelination in surviving mice, as previously described with MHV-JHM (Bailey et al., 1949; Barthold et al., 1986; Goto et al., 1977). Lesions were present through day 30, but were resolving at day 60 and had disappeared by day 90. Infectious virus was detectable through day 30, but not at day 60. Central nervous system infection is far more variable following i.c. inoculation, since outcome is determined by virus strain, virus dose, host age and host genotype (Haspel et al., 1978; Weiner, 1973). Persistent brain infection has been demonstrated in some mice that survive i.c. inoculation with MHV-JHM and MHV-A59. With MHV-JHM, active demyelination has been observed in one study for up to 16 months (Herndon et al., 1975). Foci of recurrent demyelination and infectious virus have been shown in brain at 365 days after i.c. inoculation with a temperature-sensitive mutant of MHV-JHM (Knobler et al., 1982b, c). Demyelination has also been observed for up to 6 months after i.c. inoculation of MHV-A59, and low levels of MHV-A59 RNA can be detected for up to 10 months (Lavi et al., 1984a, b). Others (Robb et al., 1979) have found that MHV-JHM, MHV-A59 and their temperature-sensitive mutants induce a high rate of demyelination, but few mice have persistent demyelination beyond 2–3 months. Most MHV studies, including our current data, have demonstrated a transient rather than persistent course of MHV infection in all tissues, including brain (reviewed in Barthold, 1986).

Acknowledgements

The technical assistance of D.S. Beck and S.D. Moore is gratefully acknowledged. This work was supported by PHS grant RR-02039 from the Division of Research Resources.

References

- Bailey, O.T., Pappenheimer, A.M., Cheever, F.S. and Daniels, J.B. (1949) A murine virus (JHM) causing disseminated encephalomyelitis with extensive destruction of myelin: II. Pathology. *J. Exp. Med.* 90, 195–221.
- Bang, F.B. (1978) Genetics of resistance of animals to viruses: I. Introduction and studies in mice. *Adv. Virus Res.* 23, 269–348.
- Barthold, S.W. (1986) Host age and genotypic effects on enterotropic mouse hepatitis virus infection. *Lab. Anim. Sci.* in press.
- Barthold, S.W. (1986) Research complications and state of knowledge of rodent coronaviruses. In: *Complications of Viral and Mycoplasmal Infections in Rodents to Toxicological Research and Testing* (Hamm, T.A., ed.), pp. 53–89. Hemisphere Publishing Corp., Washington, D.C.
- Barthold, S.W., Beck, D.S. and Smith, A.L. (1986) Mouse hepatitis virus nasoencephalopathy is dependent upon virus strain and host genotype. *Arch. Virol.* 91, 247–256.
- Barthold, S.W. and Smith, A.L. (1983) Mouse hepatitis virus S in weanling Swiss mice following intranasal inoculation. *Lab. Anim. Sci.* 33, 355–360.
- Barthold, S.W. and Smith, A.L. (1984) Mouse hepatitis virus strain-related patterns of tissue tropism in suckling mice. *Arch. Virol.* 81, 103–112.
- Barthold, S.W., Smith, A.L. and Povar, M.L. (1985) Enterotropic mouse hepatitis virus infection in nude mice. *Lab. Anim. Sci.* 35, 613–618.
- Carthew, P. and Sparrow, S. (1981) Murine coronaviruses: the histopathology of disease induced by intranasal inoculation. *Res. Vet. Sci.* 30, 270–273.
- Cheever, F.S., Daniels, J.B., Pappenheimer, A.M. and Bailey, O.T. (1949) A murine virus (JHM) causing disseminated encephalomyelitis with extensive destruction of myelin: I. Isolation and biological properties of the virus. *J. Exp. Med.* 90, 181–194.
- ConSmith, G., Kalter, S.S., Heberling, R.L. and Helmke, R.J. (1976) Particles morphologically resembling mouse hepatitis virus in nude mouse uterus. *Intervirology* 6, 90–97.
- Gallily, R., Warwick, A and Bang, F.B. (1966) Ontogeny of macrophage resistance to mouse hepatitis *in vivo* and *in vitro*. *J. Exp. Med.* 125, 537–548.
- Goto, N., Hirano, N., Aiuchi, M., Hayashi, T. and Fujiwara, K. (1977) Nasoencephalopathy of mice infected intranasally with a mouse hepatitis virus, JHM strain. *Jpn. J. Exp. Med.* 47, 59–70.
- Haspel, M.V., Lampert, P.W. and Oldstone, M.B.A. (1978) Temperature-sensitive mutants of mouse hepatitis virus produce a high incidence of demyelination. *Proc. Natl. Acad. Sci. U.S.A.* 75, 4033–4036.
- Herndon, R.M., Griffin, D.E., McCormick, U. and Weiner, L.P. (1975) Mouse hepatitis virus-induced recurrent demyelination. *Arch. Neurol.* 32, 32–35.
- Katami, K., Taguchi, F., Nakayama, M., Goto, N. and Fujiwara, K. (1978) Vertical transmission of mouse hepatitis virus infection in mice. *Jpn. J. Exp. Med.* 48, 481–490.
- Knobler, R.L., Dubois-Dalq, M., Haspel, M.V., Claysmith, A.P., Lampert, P.W. and Oldstone, M.B.A. (1981a) Selective localization of wild type and mutant mouse hepatitis virus (JHM strain) antigens in CNS tissue by fluorescence, light and electron microscopy. *J. Neuroimmunol.* 1, 81–92.
- Knobler, R.L., Haspel, M.V., Dubois-Dalq, M., Lampert, P.W. and Oldstone, M.B.A. (1981b) Host and virus factors associated with CNS cellular tropism leading to encephalomyelitis or demyelination induced by the JHM strain of mouse hepatitis virus. *Adv. Exp. Biol. Med.* 142, 341–348.
- Knobler, R.L., Haspel, M.V. and Oldstone, M.B.A. (1981c) Mouse hepatitis virus type 4 (JHM strain)-induced fatal central nervous system disease. I. Genetic control and the murine neuron as the susceptible site of disease. *J. Exp. Med.* 153, 832–843.

- Knobler, R.L., Lampert, P.W. and Oldstone, M.B.A. (1982a) Virus persistence and recurring demyelination produced by a temperature sensitive mutant of MHV-4. *Nature* 298, 279–280.
- Knobler, R.L., Tunison, L.A., Lampert, P.W. and Oldstone, M.B.A. (1982b) Selected mutants of mouse hepatitis virus type 4 (JHM strain) induce different CNS diseases. Pathobiology of disease induced by wild type and mutants ts 8 and ts 15 in BALB/c and SJL mice. *Am. J. Pathol.* 109, 157–168.
- Koolen, M.J.M., Osterhaus, A.D.M.E., van Steenis, G., Horzinek, M.C. and van der Zeijst, B.A.M. (1983) Temperature-sensitive mutants of mouse hepatitis virus strain A59: isolation, characterization and neuropathogenic properties. *Virology* 125, 393–402.
- Lavi, E., Gilden, D.H., Wroblewska, Z., Rorke, L.B. and Weiss, S.R. (1984a) Experimental demyelination produced by the A59 strain of mouse hepatitis virus. *Neurology* 34, 597–603.
- Lavi, E., Gilden, D.H., Highkin, M.K. and Weiss, S.R. (1984b) Persistence of mouse hepatitis virus A59 RNA in a slow virus demyelinating infection in mice as detected by in situ hybridization. *J. Virol.* 51, 563–566.
- Pickel, K., Muller, M.A. and ter Meulen, V. (1981) Analysis of age-dependent resistance to murine coronavirus JHM infection in mice. *Infect. Immun.* 34, 648–654.
- Reed, L.J. and Muench, H. (1938) A simple method of estimating fifty percent endpoints. *Am. J. Hyg.* 27, 493–497.
- Robb, J.A., Bond, C.W. and Leibowitz, J.L. (1979) Pathogenic murine coronaviruses. III. Biological and biochemical characterization of temperature-sensitive mutants of JHMV. *Virology* 94, 385–399.
- Smith, A.L. and Winograd, D.F. (1986) Two enzyme immunoassays for the detection of antibody to rodent coronaviruses. *J. Virol. Methods*, 14, 335–343.
- Sorenson, O., Percy, D. and Dales, S. (1980) In vivo and in vitro models of demyelinating diseases: III. JHM virus infection of rats. *Arch. Neurol.* 37, 478–484.
- Steel, R.G.D. and Torrie, J.H. (1960) Principles and Procedures of Statistics. McGraw-Hill Book Co., New York.
- Stohlman, S.A. and Frelinger, J.A. (1978) Resistance to fatal central nervous system disease by mouse hepatitis virus, strain JHM. I. Genetic analysis. *Immunogenetics* 6, 277–281.
- Stohlman, S.A., Frelinger, J.A. and Weiner, L.P. (1980) Resistance to fatal central nervous system disease by mouse hepatitis virus, strain JHM. II. Adherent cell mediated protection. *J. Immunol.* 124, 1733–1739.
- Stohlman, S.A. and Weiner, L.P. (1981) Chronic central nervous system demyelination in mice after JHM infection. *Neurology* 31, 38–44.
- Stohlman, S.A., Woodward, J.G. and Frelinger, J.A. (1982) Macrophage antiviral activity: extrinsic versus intrinsic activity. *Infect. Immun.* 36, 672–677.
- Sturman, L.S. and Takemoto, K.K. (1972) Enhanced growth of a murine coronavirus in transformed mouse cells. *Infect. Immun.* 6, 501–507.
- Taguchi, F., Aiuchi, M. and Fujiwara, K. (1977) Age-dependent response of mice to a mouse hepatitis virus, MHV-S. *Jpn. J. Exp. Med.* 47, 109–115.
- Taguchi, F., Goto, Y., Aiuchi, M., Hayashi, T. and Fujiwara, K. (1979a) Pathogenesis of mouse hepatitis virus infection. The role of nasal epithelial cells as a primary target of low-virulence virus, MHV-S. *Microbiol. Immunol* 23, 249–262.
- Taguchi, F., Yamada, A. and Fujiwara, K. (1979b) Factors involved in the age-dependent resistance of mice infected with low virulence mouse hepatitis virus. *Arch. Virol.* 62, 333–340.
- Wege, H., Koga, M., Watanabe, R., Nagashima, K. and ter Meulen, V. (1983) Neurovirulence of murine coronavirus JHM temperature-sensitive mutants in rats. *Infect. Immun.* 39, 1316–1324.
- Wege, H., Koga, M., Wege, H. and ter Meulen, V. (1981) JHM infections in rats as a model for acute and subacute demyelinating disease. *Adv. Exp. Med. Biol.* 142, 327–340.
- Weiner, L. (1973) Pathogenesis of demyelination induced by a mouse hepatitis virus (JHM virus) *Arch. Neurol.* 28, 298–303.
- Woyciechowska, J.L., Trapp, B.D., Patrick, D.H., Shekarchi, I.C., Leinikki, P.O., Sever, J.L. and Holmes, K.V. (1984) Acute and subacute demyelination induced by mouse hepatitis virus strain A59 in C3H mice. *J. Exp. Pathol.* 1, 295–306.