



Since January 2020 Elsevier has created a COVID-19 resource centre with free information in English and Mandarin on the novel coronavirus COVID-19. The COVID-19 resource centre is hosted on Elsevier Connect, the company's public news and information website.

Elsevier hereby grants permission to make all its COVID-19-related research that is available on the COVID-19 resource centre - including this research content - immediately available in PubMed Central and other publicly funded repositories, such as the WHO COVID database with rights for unrestricted research re-use and analyses in any form or by any means with acknowledgement of the original source. These permissions are granted for free by Elsevier for as long as the COVID-19 resource centre remains active.

FELINE INFECTIOUS PERITONITIS

Stacy E. Andrew, DVM

Feline infectious peritonitis (FIP) was first described in a 1963 article as chronic fibrinous peritonitis.²¹ Ocular lesions resulting from systemic infection with FIP were first reported in 1971.¹¹ Despite progress in understanding the pathogenesis of FIP disease manifestations, mortality rates associated with the FIP complex have not decreased. The FIP virus (FIPV) infects domestic and wild felines of all species. General physical examination and history taking are extremely important factors in correctly diagnosing FIP. The diagnosis and treatment of anterior and posterior uveitis are the most important factors in the care of animals with ocular manifestations of FIP.

TRANSMISSION

The FIPV can remain stable and infective outside the host for 3 to 7 weeks under dry conditions, although it is rapidly inactivated by most household detergents.²² The feline small intestine is the most likely reservoir for the virus.³² All cats are susceptible to infection with FIPV, but clinical disease is seen most commonly in younger cats between 3 months and 3 years of age.²⁷ Young kittens are protected from feline coronaviruses (FCoV) by maternal antibodies until they reach 6 weeks of age, after which time 90% of cats exposed to FCoV will seroconvert. Approximately 5% to 12% of these cats will develop classic clinical signs of FIP.^{1, 9}

The perceived increase in the prevalence of clinical cases of FIP is thought to be caused by increased fecal exposure from greater numbers of indoor cats sharing litter boxes.⁴ In a recent study, pet cats had a significantly higher coronavirus antibody titer when compared with feral cats. Fifty-nine percent of pet cats and 4% of feral cats were considered coronavirus titer-positive.²⁵ The majority of FIP cases in the United States occur in cats from catteries, in multiple-cat households, and in shelter facilities.³² Researchers are still unsure of all

From the Department of Small Animal Clinical Sciences, College of Veterinary Medicine, University of Florida, Gainesville, Florida

VETERINARY CLINICS OF NORTH AMERICA: SMALL ANIMAL PRACTICE

transmission routes of FCoV, although ingestion and possibly inhalation of virus particles in feces are believed to be the primary routes of FIPV infection.^{4,22} FIPV particles may also be transmitted via saliva, respiratory secretions, and urine in early infections.^{18,22}

Risk factors for the development of FIP in a multicat environment include the age of the cat, its coronavirus titer, the recurrence rate of feline enteric coronavirus (FECV) fecal shedding, and the proportion of chronic shedders in the household population.¹³ The mean number of cats, the mean age of cats, gender, husbandry practices, and the presence or absence of concurrent disease were shown to have no effect on the incidence of FIP.¹³ The occurrence of FIP in combination with feline leukemia virus (FeLV) is no higher than the rate of FeLV in the general cat population, and the occurrence of FIP with feline immunodeficiency virus (FIV) is even less than the occurrence of FIV in the general cat population.⁹

Elimination of FIP in a multicat household or breeding colony requires the total elimination of cats that are chronic shedders of FECV.¹³ The use of highly specific and highly sensitive reverse transcriptase–polymerase chain reactions (RT-PCR) has detected virus in naturally infected cats and reveals that healthy carriers can shed virus for up to 10 months.¹⁸ This technique cannot detect the viability of FIPV organisms.⁴ Studies have shown that 42% to 75% of cats with naturally occurring FIP shed the virus.³

If a naive cat is placed in a multicat household and encounters FIPV-infected cats, the naive cat will become infected and will most likely shed virus for several weeks to months.⁴ Transplacental transmission has been reported in one 4-day-old kitten that demonstrated typical FIP lesions and in stillborn kittens born to a queen with FIP in later stages of pregnancy.³¹ Nevertheless, transplacental transmission is considered to be rare because most kittens removed from contact with shedding adults at 5 to 6 weeks postpartum do not seroconvert.¹

PATHOGENESIS

The FIPV belongs to the group of FCoV, which also includes FECV. There are two theories concerning the relationship of the FCoVs. It has been debated that (1) FIPV is a separate and unique coronavirus,³⁰ and (2) that FIPV and FECV cannot be distinguished from each other serologically, and are in some way mutations of the same virus. Many researchers believe that there are two biotypes of FCoVs—FIPV and FECV—and that both biotypes have the potential to cause disease.⁴

Current data suggest that FIPV is a mutation of FECV, and that there are actually numerous and rapidly occurring mutations of FECV resulting in multiple FIPVs.³⁵ The FIP-induced mutations in FECV appear frequently, which indicates the mutations are relatively modest and probably occur in a unique and highly variable region of the FECV genome.³⁵ Recent evidence supports the idea that FIPVs have evolved as deletion mutations of FECVs.³⁷

Once FECV mutates into FIPV, it gains the ability to replicate in macrophages.⁴ FIPV-containing macrophages travel to regional lymph nodes where further viral replication occurs. The resultant viremia allows virus-laden macrophages to be deposited in the endothelium of small blood vessels.²⁷ The feline immune system has several mechanisms for managing this early stage of FIPV infection. Virus can be eliminated if the cat mounts a strong cell-mediated immune response. If the cat cannot exhibit a cell-mediated immune response, a profound, complement-mediated, pyogranulomatous vasculitis causing effusive

FIP develops.²⁷ Antibody-dependent enhancement of the FIPV infection occurs and results in immune complex deposition and vasculitis.¹² Complement fixation causes the release of vasoactive amines, resulting in increased blood vessel permeability and allowing plasma protein exudation.⁴ A partial cell-mediated immune response can also occur, which causes slower viral replication and the classic granuloma formation seen with noneffusive FIP.¹²

Gonon and co-workers¹⁶ demonstrated that once cats clear natural FCoV infection, they develop an antibody response against one or more of the S-glycoprotein domains, relative to the M glycoprotein, of the virus particle. The antibody response was on average 30 times higher in these cats when compared with cats that were either chronically infected or sick as a result of the infection.¹⁶ It was not clear whether the antibody response was a mechanism or an indicator of viral clearance.¹⁶ The anti-S antibody response does not seem to be a risk factor for developing FIP, and this finding should challenge the widely accepted belief that the S glycoprotein has a detrimental effect in FIP recombinant vaccines.¹⁶

CLINICAL SIGNS

Systemic

Although cats of any age can be affected by FIP, usually one half of affected cats are less than 2 years of age. Typically, these cats have lived within a multicat facility (breeder, humane society, boarding facility, cat show, veterinary clinic) within the previous year and may have history of stress in the previous few months (new home, elective surgery).⁴ The systemic effects of FIPV infection are widespread. The specific clinical and pathologic signs observed are attributable to vasculitis-induced organ damage.⁴ Classically, two forms of FIP are observed. One form is the effusive or wet type; the other is the noneffusive or dry form. With either manifestation of infection, a fatal immune-mediated vasculitis results. The time course from the onset of clinical signs to death is variable with both forms. Cats with effusive cases tend to die within 2 months of the onset of clinical signs, whereas cats with noneffusive cases have a more chronic disease course.⁴ In some noneffusive cases, effusive FIP will develop before death.³²

The first clinical signs of FCoV infection are often mild upper respiratory or intestinal signs.⁴ These signs are not usually severe enough to warrant veterinary attention, thus many cases go undetected in the early stages.⁴ Enteritis caused by coronavirus usually manifests as transient mild diarrhea. FIPV-infected kittens may have a history of diarrhea and, occasionally, stunted growth and upper respiratory signs.¹ Many FCoV-infected cats do not show any clinical signs.⁴

Clinical signs common in either the effusive or noneffusive forms of FIP include anorexia, weight loss, lethargy, and mild antibiotic-unresponsive fever (39–39.5°C).²⁷ With effusive disease, the specific clinical signs depend on the body system affected by the vasculitis. Clinical signs can include combinations of any of the following: ascites causing abdominal distention with a fluid wave; thoracic effusion resulting in dyspnea, tachypnea, and muffled heart sounds; scrotal enlargement; mucosal pallor or icterus; pericardial effusion; abdominal masses (adhesions); and mesenteric lymphadenopathy.⁴ Noneffusive disease results in clinical signs that are initially vague. In addition to the signs shared by both categories of disease, cats with noneffusive cases may have granulomatous lesions in abdominal organs (spleen, kidney, liver, omentum), the lungs, and lymph nodes.⁴ Occasionally, granulomas are localized to the gastrointestinal

tract, including the colon, ileocecolic junction, or small intestine.⁴ Cats with noneffusive FIP frequently have ocular signs, and as many as 25% develop multifocal progressive neurologic signs.⁹ The ocular and neurologic signs are caused by granuloma formation in these tissues. Because the eye is considered part of the central nervous system, any cat with neurologic symptoms should undergo a complete ocular examination to rule out causes of systemic infectious disease. Cats with neurologic manifestations of FIP may have focal or multifocal central nervous system lesions and signs.²³ Nystagmus was the most common (12 of 24 cats) caudal fossa sign in a study of FIP cases.²³

Ocular

Ocular manifestations of FIP are far more common in the noneffusive form of disease, and ocular signs may be the presenting complaint in some cats.²⁶ In one study, less than 5% (5 of 107) of cats with effusive FIP had ocular or neurologic signs, compared with 36% (34 of 94) of cats with noneffusive disease.^{31, 32} It is not unusual for cats to present with ocular signs with no sign of systemic illness. Survival after the onset of clinical signs is generally less than 1 year; however, the life span can be somewhat longer if there is only ocular involvement with the noneffusive form.¹⁵

Cats suspected of having FIP should be examined for the following ophthalmic clinical signs: aqueous flare, ocular pain, corneal edema, keratic precipitates, fibrin, hypopyon, hyphema, miosis, ocular hypotony, iridal hyperemia/neovascularization, posterior synechiae, and posterior segment changes including chorioretinitis, perivascular cuffing, optic neuritis, and retinal detachment. The most common ocular manifestation of FIP is uveitis. Anterior uveitis (inflammation of the iris and ciliary body) is usually more noticeable to the clinician, although the anterior and posterior uvea (choroid) can be affected. An aqueous flare (Fig. 1) is the hallmark of anterior uveitis and is the visualization of elevated protein levels in the anterior chamber. With a bright focal light source (such as the small aperture on the lens wheel of a direct ophthalmoscope), the clarity or turbidity of the anterior chamber can be assessed. If a continuous

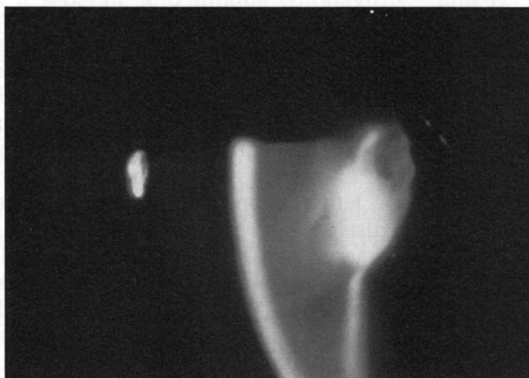


Figure 1. Aqueous flare is demonstrated in this view of a cat with feline infectious peritonitis (FIP)-induced anterior uveitis. A continuous beam of light is noted through the anterior chamber, between the slit beams on the cornea and on the iris and lens.

beam of light is seen going across the anterior chamber, aqueous flare is present. If there are no signs of anterior uveitis in a cat suspected of having FIP, a fundic examination should be performed.

Uveitis may also manifest as ocular pain, exhibited clinically in the cat as slight third-eyelid protrusion, squinting (blepharospasm), or tearing (epiphora). Corneal edema may be focal or diffuse and is also seen as a manifestation of uveitis. Keratic precipitates (Fig. 2) are clusters of inflammatory cells in the anterior chamber that settle ventrally on the posterior cornea or endothelium. It may be necessary to retract the third eyelid to visualize the precipitates or to tilt the cat's nose down to encourage the eye to roll up to examine the area of interest.

Fibrin exudation from uveal blood vessels into the anterior chamber occurs with breakdown of the blood–aqueous barrier. Hypopyon (exudation of white blood cells into the anterior chamber) or hyphema (exudation of red blood cells into the anterior chamber) indicates profound blood–aqueous barrier breakdown and uveitis. Miosis refers to constriction of the pupil, which occurs owing to prostaglandin release with uveitis and subsequent stimulation of the iris sphincter muscle. Subtle or striking iris color change may be the presenting complaint,⁴ especially in chronic cases of anterior uveitis. Ocular hypotony is lower than normal intraocular pressure owing to decreased production of aqueous humor and inflammation of the iris, with resultant increased uveoscleral (or unconventional) outflow of aqueous humor. Hyperemia of the iris refers to an increased reddening of the tissue, usually resulting from neovascularization or the ingrowth of new blood vessels. Posterior synechiae are adhesions of the iris to the lens and are caused by exudates in the anterior chamber that cause the iris to become “sticky.” Chorioretinitis is inflammation or infection of the choroid and retina and is caused by FIPV-induced vasculitis (Figs. 3 and 4). This inflamma-

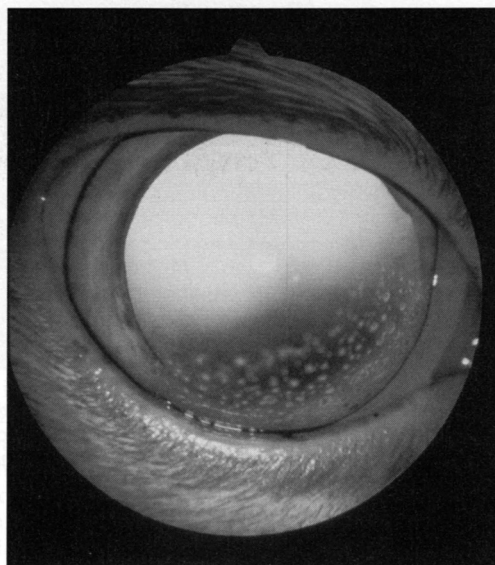


Figure 2. Keratic precipitates are evident in the anterior chamber on the ventral cornea of this young cat with FIP. (Courtesy of Kirk Gelatt, VMD, Gainesville, FL.)

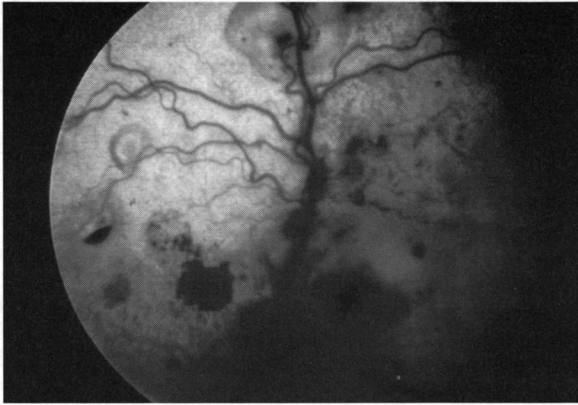


Figure 3. Retinal detachments and retinal hemorrhages caused by FIP. (Courtesy of Dennis Brooks, DVM, Gainesville, FL.)

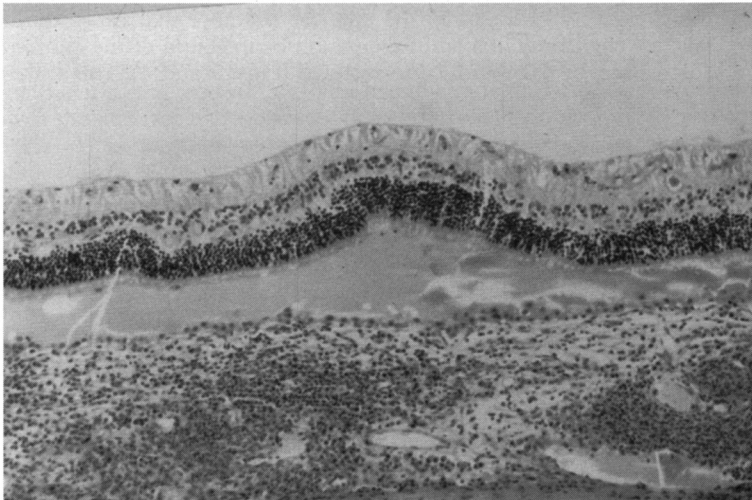


Figure 4. Histopathologic section of the eye in Figure 3. Exudative retinal detachment is seen (as fluid in the subretinal space separating the retina from the choroid), and there is a mononuclear infiltrate in the choroid (hematoxylin-eosin, original magnification $\times 20$). (Courtesy of Dennis Brooks, DVM, Gainesville, FL.)

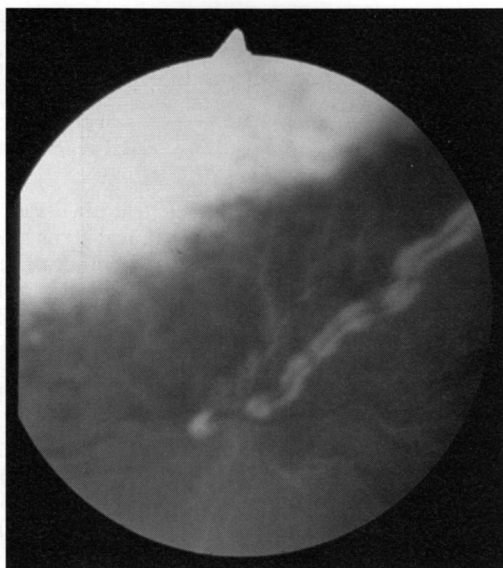


Figure 5. Perivascular cuffing is noted as white infiltrates surrounding the nontapetal blood vessels in this cat with FIP. (Courtesy of Bernhard Spiess, Dr. Med Vet, Zurich, Switzerland.)

tion can manifest as exudate from the choroidal blood vessels and in severe cases results in retinal detachment.¹¹ Perivascular cuffing, considered suggestive of FIP infection in other organ systems, can be directly visualized in the eye (Fig. 5). A cellular exudate can sometimes be seen outlining the retinal venules. With optic neuritis, the optic nerve will appear swollen with blurred margins.

The most common form of uveitis observed with FIPV infection is a bilateral granulomatous anterior uveitis often accompanied by chorioretinitis.²⁶ "Mutton fat" keratic precipitates are commonly seen with FIP and FeLV.¹⁵ This type of keratic precipitate is a large corneal endothelial deposit that is often yellow in color. The uveal tissues are extremely rich in blood vessels and easily exude cells and proteins when injured.¹¹ The blood–aqueous barrier is comprised of tight junctions between endothelial cells of iris capillaries and between nonpigmented cells of the ciliary epithelium. These junctions, as well as the blood–retinal barrier, are normally impermeable to many circulating proteins.⁵ If the blood–aqueous barrier is compromised, proteins and other cells can leak into the anterior chamber and further exacerbate inflammation. FIP granulomas affect the blood–aqueous and blood–retinal barrier vessels.¹⁵ The iris blood vessels are quite permeable in the cat when compared with other species, and the capillaries of the choriocapillaris are more permeable in kittens than in adult cats.⁸

Inflammation associated with ocular FIP can gradually progress to panuveitis, which is inflammation of all parts of the eye.¹⁵ Other sequelae or complications that can occur with ocular FIP depend on the duration of the uveitis. These complications include, but are not limited to, glaucoma owing to peripheral anterior synechiae, iridocorneal angle closure, posterior synechiae and iris bombé, or preiridal fibrovascular membrane formation; anterior or posterior lens luxation; cataract formation; blindness; and phthisis bulbi (or a fibrosed and shrunken globe).¹⁵ The reported incidence of systemic diseases causing uveitis

in cats is highly variable. A recent study¹⁰ found that 70% of cats with uveitis had no detectable cause, whereas another study²⁴ found 83% of cats with uveitis were serologically positive for exposure to an infectious agent.

DIAGNOSTICS

There is no definitive antemortem diagnostic test for FIP except histopathologic examination of tissue. Many diseases have clinical signs similar to FIP, such as lymphoma, cardiomyopathy, septic peritonitis, pyothorax, and chylothorax. Without histopathologic confirmation, the diagnosis of FIP is only presumptive.⁶ The histopathologic finding required to confirm a diagnosis of FIP is a pyogranulomatous lesion. Ocular histopathology of FIP cases reveals a leukocytic infiltrate consisting of neutrophils, plasma cells, lymphocytes, and macrophages in the ciliary body (Fig. 6) and adjacent sclera.³⁴ Perivascular lymphocytes, plasma cells, and macrophages in the sclera, retina, optic meninges, and retrobulbar connective tissue are also observed.³⁴ Enucleated eyes from cats with uveitis revealed that suspected or confirmed FIP (21.5%, 34 of 158 eyes) was the second most common cause of uveitis following idiopathic uveitis (32.3%, 51 of 158 eyes).³³ Another study reported a much lower incidence of FIP lesions (0.02%, 1 of 53 cats).¹⁰

Serology is important to diagnose and manage cases of FIP; therefore, the laboratory chosen to perform the testing must be consistent and reliable.⁴ The laboratory should have established reference ranges for low-positive and high-positive titers to determine the significant level of reactivity.⁴ Test results must be correlated with clinical findings. Random serologic testing is not useful owing to the low disease specificity. Serologic testing should be performed in conjunction with a compatible history, clinical signs, and globulin ratio⁴ that are supportive of a diagnosis of FIP. An antibody titer only indicates that a cat is infected with, or has been infected with, a coronavirus. ELISA and an immunofluorescent antibody (IFA) test are the two most common serologic tests performed for FCoV; however, serologic tests should only be interpreted with a complete understanding of the testing mechanisms and limitations.⁷ Serologic testing for FCoVs cannot distinguish virulent from avirulent strains, ascertain the time when a cat became infected with FCoV, or indicate whether an animal is susceptible or immune to clinical disease caused by FCoV.²⁷

Problems inherent in FCoV serologic testing include false-positives, false-negatives, and misinterpretations.⁷ Many laboratories perform ELISA and IFA tests. Often, an ELISA is performed first, and, if the result is negative, the testing is complete. If the ELISA is positive, an IFA is performed to determine the antibody titer.¹² A commercial ELISA test kit is awaiting US Food and Drug Administration approval (FIP Diasystems, IDEXX Co., Portland, ME). The result is read spectrophotometrically as color development. A positive result with a previously available ELISA (Snap FIP, IDEXX Co.) was considered to be roughly equivalent to an IFA titer of 1:3200.¹² The IFA test is an indirect method and is reported as the highest serum dilution conferring a positive result.¹² The test is variable owing to a lack of consistency of interpretation between experienced technicians.¹² The sensitivity of the IFA test is reported to be 95% and the specificity 98%, thus there is good predictive value for infection with coronavirus with a positive titer result.¹² The IFA is less sensitive but more specific than ELISA testing.²⁷

Cats that are seronegative do not shed FCoV, whereas one third of seropositive cats do shed FCoV.¹ Evidence of viral shedding is not a good reason to

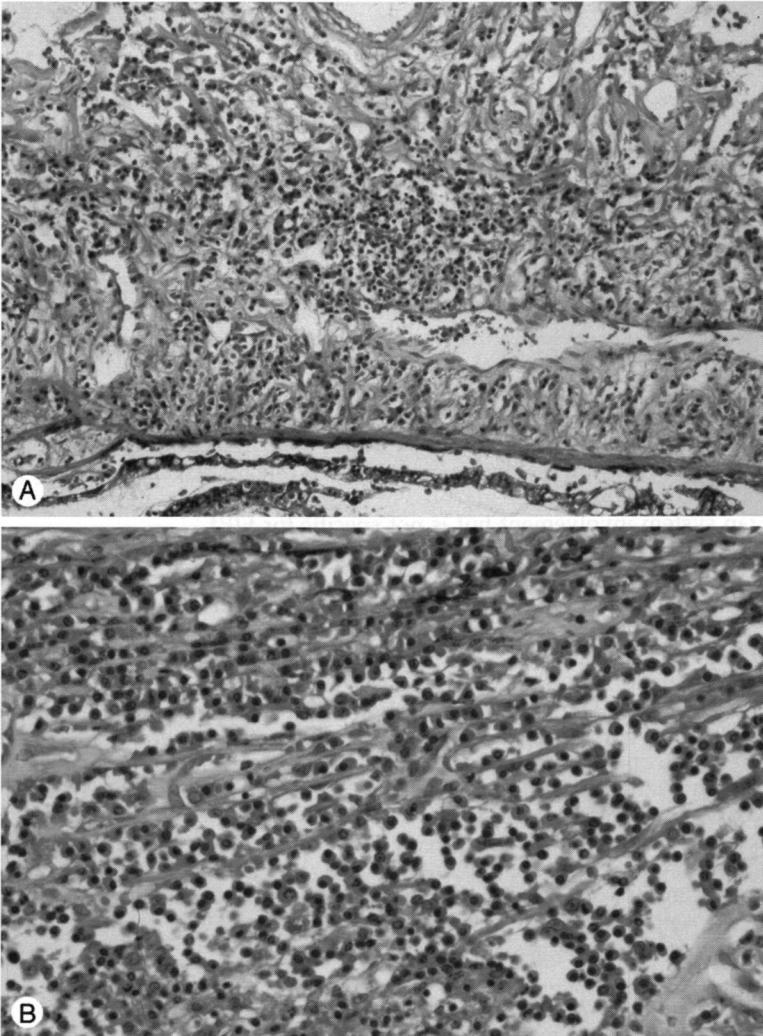


Figure 6. *A*, Histopathologic section of the iris of a 6-month-old Devon Rex with ocular and systemic FIP. Note the abundant mononuclear cell infiltrate (plasma cells and scattered macrophages), as well as diffuse expansion of the iris by edema (hematoxylin-eosin, original magnification $\times 20$). *B*, Histopathologic section of the choroid of the same animal. Mild to moderate mononuclear infiltrates are present multifocally throughout the choroid (hematoxylin-eosin, original magnification $\times 40$).

ethanize a cat because most cats stop shedding within 1 year, and less than 10% develop FIP.² A recent study demonstrated that the probability of a cat with a high FCoV antibody titer having FIP was only 38.9%,³⁶ thus a positive FCoV antibody titer does not rule in FIP. Some experts believe that cats with the

noneffusive form of FIP generally have a high FCoV antibody titer and are rarely seronegative.⁴

Reverse transcriptase-polymerase chain reaction can be performed to detect FCoV particles in tissue or fluid samples such as feces.^{4, 18} The test is highly sensitive and specific for FCoV but cannot establish a definite diagnosis of FIP. An IFA test for the FIP antigen has also been reported using smears made from nictitating membrane scrapes and was found to have 85% agreement with immunohistochemistry and serology.^{19, 20} This test detects all coronaviruses, not FIPV specifically, and further evaluation of this method of study is needed before recommending its clinical use.¹²

A complete blood count and serum chemistry profile should be obtained if there is a clinical suspicion of FIP infection. Cats with FIP will usually exhibit a neutrophilia with a left shift, nonregenerative anemia caused by chronic inflammation, high serum total protein levels, and a low albumin-to-globulin ratio owing to an increase in globulin levels. Polyclonal hyperglobulinemia is reported in approximately 75% of cats with noneffusive FIP and in 50% of cats with the effusive form of disease.⁹ Serum protein electrophoresis should be performed when elevated globulins are reported (Fig. 7). An acute phase protein, α -1-acid glycoprotein, is often elevated in plasma or effusion samples depending on organ system involvement but is not specific for FIP.⁴

Aqueous humor cytology and protein concentration are not specific enough to diagnose FIP.²⁹ A recent study using PCR performed on aqueous humor samples of cats with neurologic and ocular lesions of FIP found that all samples were negative (16 of 16 cats)¹⁴; therefore, aqueous paracentesis is of no diagnostic value in FIP-induced uveitis.

A combination of clinical signs, historical factors, and laboratory values have been used for antemortem prediction of whether a cat has FIP. Historical factors (i.e., a young cat, a multicat household, and a recent stress event), combined with clinical findings (i.e., fever, uveitis, neurologic signs, an abdominal mass, or icterus), hyperglobulinemia (>5.1 g/dL), lymphopenia ($<1.5 \times 10^3$ cells/ μ L), and serology revealing a high FCoV titer ($>1:160$) suggest a high probability of noneffusive FIP (predictive value $>85\%$).²⁷ Consistent clinical signs, lymphopenia, hyperglobulinemia, and an FCoV titer greater than 160 resulted in an 89% probability of FIP being diagnosed postmortem.³⁶ Clinical signs of FIP without the previous serum indicators had a 99% negative predictive value for a negative diagnosis.²⁷

THERAPY

Because ocular signs are more prevalent with the noneffusive form of disease, the focus of this article is on therapy for ocular manifestations of noneffusive FIP. FIP is generally considered to be a fatal disease, and the main treatment goal is to palliate clinical signs. Treatment of ocular disease is symptomatic, and the mainstay of therapy is topical or systemic corticosteroids or both.²⁶ Some cats only develop ocular FIP pyogranulomatous lesions, which manifest as uveitis in one or both eyes. These animals respond reasonably well to corticosteroids; however, if the inflammation is severe and the eye is blind and painful, enucleation is a viable treatment to increase patient comfort.²²

There are multiple therapeutic routes for uveitis. The route chosen depends on the location and severity of inflammation, as well as the characteristics of the drug chosen. The most common treatment routes for FIP-infected cats are topical and systemic. Topical medications can penetrate the cornea and reach as deep

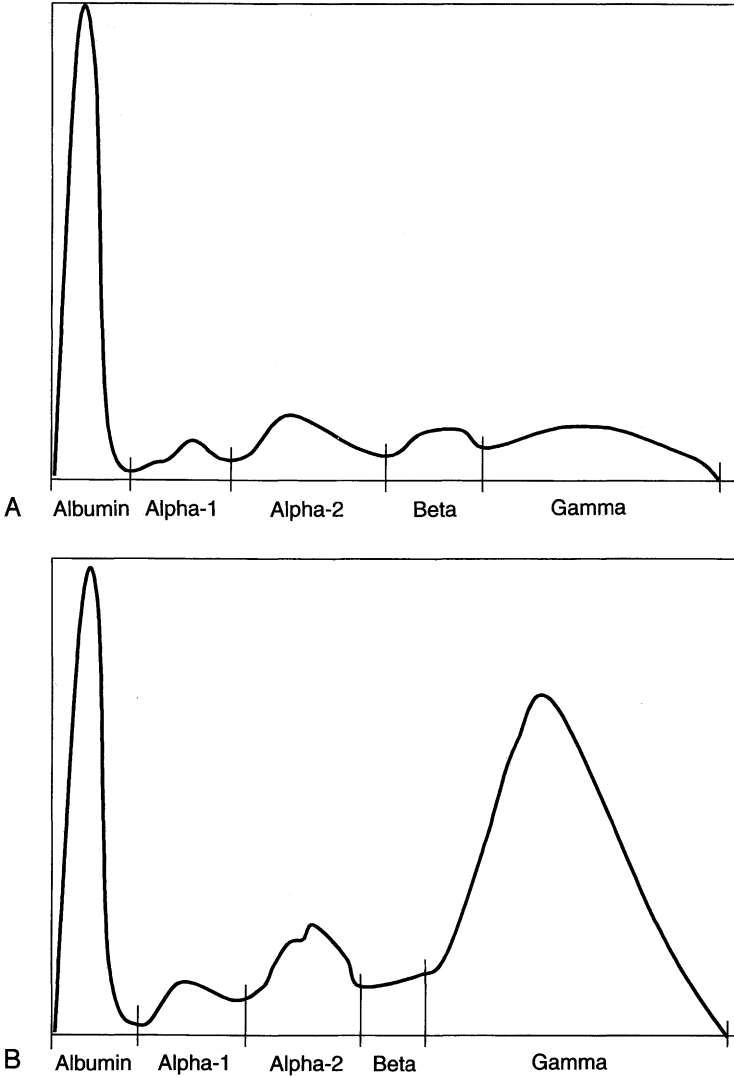


Figure 7. Serum protein electrophoresis profiles from a normal cat (A) and a clinical case of FIP (B). Note the increased gamma globulins, which is typical with FIP.

as the iris and ciliary body. Prednisolone acetate 1% and dexamethasone sodium phosphate 0.1% ophthalmic solutions penetrate the intact cornea and enter the anterior chamber, whereas medications containing hydrocortisone do not. Subconjunctival drug administration is not usually recommended because of scar tissue formation, the inability to remove therapy if clinical signs change, and the fact that most cats are amenable to topical treatment.

Immunosuppressive and anti-inflammatory agents provide palliation.¹² Glu-

corticoids inhibit plasma exudation, leukocyte accumulation, and complement pathway activation, all of which aid in the control of vasculitis.²⁸ Immunomodulatory drug therapy has been attempted to stimulate a cell-mediated immune response against FIPV.³⁸ Low doses (10–30 IU/cat/d) of oral recombinant human interferon- α (Roferon, Hoffmann-LaRoche, Nutley, NJ) may help induce remission in noneffusive FIP cases in which a partial cell-mediated immunity exists^{28, 38}; however, anecdotal reports of responses to low-dose oral interferon are empirical and unproven.¹² Treatment with *Propionibacterium acnes* (Immunoregulin, Neogen, Lexington, KY) is usually not effective.³⁸ Additional controlled prospective clinical trials are needed to evaluate the efficacy of immunomodulatory drugs on FIP.

Uveitic eyes suspected of FIP infection should be stained with fluorescein dye to rule out concurrent corneal ulceration. If no ulceration is present, treatment with topical prednisolone acetate 1% ophthalmic solution four times daily is initiated, along with 1% atropine ointment as needed, once to twice daily, to induce mydriasis. Atropine solution is not recommended for use in cats because they can have a strong negative reaction to the taste of the medication after it travels down the nasolacrimal duct into the mouth. The eye should be reevaluated 24 hours after the initiation of therapy, including fluorescein stain. If improvement indicated by dilation of the pupil and reduction in aqueous flare is observed, the topical corticosteroids can be decreased slowly over a period of several weeks to the lowest dose and frequency that keeps the uveitis controlled. If no improvement is noted, administration of anti-inflammatory doses of systemic prednisone or prednisolone should be considered.

Because FIP is considered a fatal disease, prevention is important. An intranasal vaccine (Primucell FIP, Pfizer, Exton, PA) is available. The vaccine contains a temperature-sensitive mutant that provides local protection against FCoV invasion. A local secretory antibody and systemic cell-mediated immune response to FCoV occurs, resulting in a self-limiting infection that does not become systemic.¹⁷ Routine use of the vaccine has been questioned because of the prolonged disease incubation period, seemingly low disease prevalence, and required intranasal administration; however, it may be of benefit in naive animals before entering contaminated catteries.¹⁷ The vaccine results in systemic mucosal (IgA), humoral (IgG), and cell-mediated response, and variable decreases in the incidence of disease have been reported after vaccine administration.²⁸

SUMMARY

Feline infectious peritonitis is a noncurable viral disease affecting cats worldwide. Recent evidence suggests that the FIPV has evolved as a deletion mutation of FECV. Immune complex deposition and vasculitis with pyogranulomatous lesions are the hallmark of FIP. The only definitive antemortem diagnostic test for FIP is histopathologic examination of tissue. Ocular manifestations occur commonly with noneffusive FIP. The most common clinical sign is a bilateral granulomatous anterior uveitis often accompanied by chorioretinitis. Treatment of ocular FIP is symptomatic, and the mainstay of palliative therapy is topical or systemic corticosteroids or both.

References

1. Addie DD, Jarrett O: A study of naturally occurring feline coronavirus infections in kittens. *Vet Rec* 130:133–137, 1992

2. Addie DD, Toth S, Murray GD, et al: Risk of feline infectious peritonitis in cats naturally infected with feline coronavirus. *Am J Vet Res* 56:429-434, 1995
3. Addie DD, Toth S, Herrewegh AAPM, et al: Feline coronavirus in the intestinal contents of cats with feline infectious peritonitis. *Vet Rec* 139:522-523, 1999
4. Addie DD, Jarrett O: Feline coronavirus infection. In Greene CE (ed): *Infectious Diseases of the Dog and Cat*, ed 2. Philadelphia, WB Saunders, 1998, pp 58-69
5. Alm A: Ocular circulation. In Hart WM Jr (ed): *Adler's Physiology of the Eye*, ed 9. St. Louis, Mosby Year Book, 1992, pp 198-227
6. Barlough JE: Serodiagnostic aids and management practice for feline retrovirus and coronavirus infections. *Vet Clin North Am Small Anim Pract* 14:955-969, 1984
7. Barr MC: FIV, FeLV, and FIPV: Interpretation and misinterpretation of serological test results. *Seminars in Veterinary Medicine and Surgery (Small Animal)* 11:144-153, 1996
8. Bellhorn RW: Permeability of blood-ocular barriers of neonatal and adult cats to fluorescein-labeled dextrans of selected molecular sizes. *Invest Ophthalmol Vis Sci* 21:282-290, 1981
9. BSAVA Scientific Committee: Scientific information document: Feline infectious peritonitis. *J Small Anim Pract* 39:501-504, 1998
10. Davidson MG, Nasisse MP, English RV, et al: Feline anterior uveitis: A study of 53 cases. *J Am Anim Hosp Assoc* 27:77-83, 1991
11. Doherty MJ: Ocular manifestations of feline infectious peritonitis. *J Am Vet Med Assoc* 159:417-424, 1971
12. Evermann JF, Henry CJ, Marks SL: Feline infectious peritonitis. *J Am Vet Med Assoc* 206:1130-1134, 1995
13. Foley JE, Poland A, Carlson J, et al: Risk factors for feline infectious peritonitis among cats in multiple-cat environments with endemic feline enteric coronavirus. *J Am Vet Med Assoc* 210:1313-1318, 1997
14. Foley JE, Lapointe J-M, Koblik P, et al: Diagnostic features of clinical neurologic feline infectious peritonitis. *J Vet Intern Med* 12:415-423, 1998
15. Glaze MB, Gelatt KN: Feline ophthalmology. In Gelatt KN (ed): *Veterinary Ophthalmology*, ed 3. Philadelphia, Lippincott Williams & Wilkins, 1999, pp 997-1052
16. Gonon V, Duquesne V, Klonjkowski B, et al: Clearance of infection in cats naturally infected with feline coronaviruses is associated with an anti-S glycoprotein antibody response. *J Gen Virol* 80:2315-2317, 1999
17. Greene CE: Immunoprophylaxis and immunotherapy. In Greene CE (ed): *Infectious Diseases of the Dog and Cat*, ed 2. Philadelphia, WB Saunders, 1998, pp 717-750
18. Herrewegh AAPM, De Groot RJ, Cepica A, et al: Detection of feline coronavirus RNA in feces, tissues, and body fluids of naturally infected cats by reverse transcriptase PCR. *J Clin Microbiol* 33:684-689, 1995
19. Hok K: Demonstration of feline infectious peritonitis virus in conjunctival epithelial cells from cats. *APMIS* 97:820-824, 1989
20. Hok K: A comparison between immunofluorescence staining on smears from membrana nictitans (M3 test), immunohistopathology and routing pathology in cats with suspected feline infectious peritonitis. *Acta Vet Scand* 32:171-176, 1991
21. Holzworth J: Some important disorders of cats. *Cornell Vet* 53:157-160, 1963
22. Hoskins JD: Coronavirus infection in cats. *Vet Clin North Am Small Anim Pract* 23:1-16, 1993
23. Kline KL, Joseph RJ, Averill DR Jr: Feline infectious peritonitis with neurologic involvement: Clinical and pathological findings in 24 cats. *J Am Anim Hosp Assoc* 30:111-118, 1994
24. Lappin MR, Marks A, Greene C, et al: Serologic prevalence of selected infectious diseases in cats with uveitis. *J Am Vet Med Assoc* 201:1005-1009, 1992
25. Levy JK, James KM, Cowgill LD: Infectious diseases of feral cats in central California. In *Proceedings of the 80th Annual Meeting Conference for Research Workers in Animal Disease*, Chicago, IL, November 1999
26. Martin CL, Stiles J: Ocular infections. In Greene CE (ed): *Infectious Diseases of the Dog and Cat*, ed 2. Philadelphia, WB Saunders, 1998, pp 658-717
27. McReynolds C, Macy D: Feline infectious peritonitis. Part I. Etiology and diagnosis. *Compend Contin Educ Pract Vet* 19:1007-1016, 1997

28. McReynolds C, Macy D: Feline infectious peritonitis. Part II. Treatment and prevention. *Compend Contin Educ Pract Vet* 19:1111-1116, 1997
29. Olin DD: Examination of the aqueous humor as a diagnostic aid in anterior uveitis. *J Am Vet Med Assoc* 171:557-559, 1977
30. Pedersen NC: Serologic studies of naturally occurring feline infectious peritonitis. *Am J Vet Res* 37:1449-1453, 1976
31. Pedersen NC: Feline coronavirus infections. *In* Greene CE (ed): *Clinical Microbiology and Infectious Diseases of the Dog and Cat*, ed 1. Philadelphia, WB Saunders, 1984, pp 514-526
32. Pedersen NC: An overview of feline enteric coronavirus and infectious peritonitis virus infections. *Feline Practice* 23:7-20, 1997
33. Peiffer RL, Wilcock BP: Histopathologic study of uveitis in cats: 139 Cases (1978-1988). *J Am Vet Med Assoc* 198:135-138, 1991
34. Peiffer RL, Wilcock BP, Dubielzig RR, et al: Fundamentals of veterinary ophthalmic pathology. *In* Gelatt KN (ed): *Veterinary Ophthalmology*, ed 3. Philadelphia, Lippincott Williams & Wilkins, 1999, pp 355-425
35. Poland AM, Vennema H, Foley JE, et al: Two related strains of feline infectious peritonitis virus isolated from immunocompromised cats infected with a feline enteric coronavirus. *J Clin Microbiol* 34:3180-3184, 1996
36. Sparkes AH, Gruffydd-Jones TJ, Harbour DA: An appraisal of the value of laboratory tests in the diagnosis of feline infectious peritonitis. *J Am Anim Hosp Assoc* 30:345-350, 1994
37. Vennema H, Poland A, Foley J, et al: Feline infectious peritonitis viruses arise by mutation from endemic feline enteric coronaviruses. *Virology* 243:150-157, 1998
38. Weiss R: Treatment of feline infectious peritonitis with immunomodulating agents and antiviral drugs: A review. *Feline Practice* 23:103-106, 1995

Address reprint requests to

Stacy E. Andrew, DVM
Small Animal Clinical Sciences
University of Florida
College of Veterinary Medicine
PO Box 100126
Gainesville, FL 32610-0126