



Since January 2020 Elsevier has created a COVID-19 resource centre with free information in English and Mandarin on the novel coronavirus COVID-19. The COVID-19 resource centre is hosted on Elsevier Connect, the company's public news and information website.

Elsevier hereby grants permission to make all its COVID-19-related research that is available on the COVID-19 resource centre - including this research content - immediately available in PubMed Central and other publicly funded repositories, such as the WHO COVID database with rights for unrestricted research re-use and analyses in any form or by any means with acknowledgement of the original source. These permissions are granted for free by Elsevier for as long as the COVID-19 resource centre remains active.

CORONAVIRUS INFECTION IN CATS

Johnny D. Hoskins, DVM, PhD

Coronavirus infections are significant in the world's cat population.^{1,2} As many as 80% to 90% of cats are affected within individual catteries and multicat households.² Cats are susceptible to infection with several different strains of feline coronavirus.^{2,3} Depending on the involved strain, clinical signs may range from asymptomatic infection to gastrointestinal disease of varying severity to widespread fibrinous serositis and disseminated vasculitis, commonly known as feline infectious peritonitis (FIP).²

CORONAVIRUSES

Coronaviruses are spherical, enveloped viruses that average 100 nm in diameter, possessing a single-stranded nonsegmented RNA genome of positive polarity. The virus particle is composed of structural proteins: nucleocapsid protein and spike glycoproteins.^{19,35} The nucleocapsid protein occurs in the core of the virus and is composed of only polypeptides. The spike glycoproteins are associated with the envelope of the virus.³⁵ The spike glycoproteins occur as petal-shaped projections, or peplomers, that extend outward from the envelope of the virus;¹³ these proteins are associated with attachment of the coronavirus to receptor sites on susceptible cells. Peplomers also may be major inducers of protective immunity in an infected host.

After ingestion or inhalation of a coronavirus, younger members of the host species tend to develop signs of infection, whereas the asymptomatic carrier state is more common in adult animals. Replication of coronaviruses occurs at the cytoplasmic membranes, as the virus buds into vacuoles within cell cytoplasm.³⁶ Coronavirus remains cell-associated throughout the course of infection and is released after the cell is destroyed. Replication of virus is rapid; cycle is complete in less than 24 hours.³⁶

From the Department of Veterinary Clinical Sciences, Louisiana State University School of Veterinary Medicine, Baton Rouge, Louisiana

In many species of animals, coronaviruses have a relatively restricted organ tropism. They infect the respiratory or gastrointestinal system, or both.⁴¹ FIP coronavirus, feline enteric coronavirus, canine coronavirus (CCV), transmissible gastroenteritis virus (TGEV) of swine, and human respiratory tract coronavirus comprise an antigenic cluster of closely related viruses within the family Coronaviridae.³⁴ The major structural proteins of these coronaviruses are antigenically similar to the extent that most investigators consider these coronaviruses as host-range variants rather than individual coronavirus species.⁵

Strains of feline coronavirus that infect cats have been divided into those that cause FIP and those that induce subclinical to severe enteritis (Table 1).³⁰ Strains of FIP coronavirus differ from those of feline enteric coronavirus in that FIP coronavirus is able to escape from the gastrointestinal tract and spread to replication sites in other organs. Strains of FIP coronavirus and feline enteric coronavirus probably represent pathogenic variants of a single coronavirus type.⁵ Alternatively, strains of FIP coronavirus may arise as mutants of feline enteric coronavirus strains.³³ Current knowledge of the cell culture-adapted strains of feline coronavirus is based on their morphologic, structural, and antigenic relationship to TGEV and CCV; the nature of the disease caused in the host; growth characteristics in cell culture systems; and the degree of relatedness to CCV in virus neutralization tests.³⁰

FIP Coronavirus

The most virulent strains of FIP coronavirus, such as FIPV-79-1146 and FIPV-DF2, cause fatal FIP disease in most cats inoculated oronasally, whereas strains of intermediate virulence, such as FIPV-UCD1, cause FIP disease in cats undergoing extended exposure. Strains of low virulence, such as FIPV-UCD2 and FIPV-UCD3, can become established as asymptomatic infections; fatal FIP disease occurs only if the immunologic responsiveness of the host later becomes compromised.³³

Most cases of FIP disease result from infection with strains similar to FIPV-TN406 and not with those strains of FIP coronavirus that are closely related to CCV.³³ Most asymptomatic cats with positive coronavirus-antibody titers have been previously infected by strains of feline enteric coronavirus or FIP coronavirus, which usually do not cause fatal disease by natural routes of infection. Asymptomatic cats, however, may later succumb if exposed to a more virulent strain of FIP coronavirus. Coronavirus antibody-positive cats that resist later challenge probably seroconvert as a result of a systemic infection with a virulent strain of FIP coronavirus.²⁵

Table 1. IDENTIFIED STRAINS OF FELINE CORONAVIRUS

Strains that induce FIP disease
FIPV-79-1146
FIPV-UCD1
FIPV-UCD2
FIPV-UCD3
FIPV-UCD4
FIPV-TN406 (Black)
FIPV-DF2 (Nor15)
Strains that induce enteric disease
FECV-79-1683
FECV-UCD

Various strains of FIP coronavirus evidently survive in the environment much longer than originally was believed. In recent studies,³⁶ FIP coronavirus was recovered from contaminated dry surfaces for 3 to 7 weeks. The amount of infectious virus recovered decreases with time. Because relatively large quantities of FIP coronavirus are required to establish natural infection in a susceptible cat, strains of coronavirus probably are not contagious to cats for longer than 2 or 3 weeks after an environment, bedding, food bowl, or water bowl is contaminated.³⁶ Infectivity of feline coronavirus strains is destroyed by most household disinfectants and detergents.¹¹

Feline Enteric Coronavirus

Feline enteric coronaviruses, such as strains of FECV-79-1683 and FECV-UCD, are highly infectious by the oral route to all cats of any age and have an affinity for the apical columnar epithelia of the duodenum, jejunum, and ileum.²⁷ Adult cats often endure subclinical infections; low-grade fever, vomiting, and diarrhea may be observed in newly weaned kittens.

Natural infection with strains of feline enteric coronavirus results in production of antibodies that presently are serologically indistinguishable from the antibodies produced by infection with FIP coronavirus, CCV, or TGEV. Most cats infected with a strain of feline enteric coronavirus remain persistently infected and periodically shed coronavirus in their feces.²⁵ Coronavirus antibodies do not, however, protect most cats from later exposure with virulent strains of FIP coronavirus. These antibodies may actually sensitize cats to later exposures, thereby hastening the disease process caused by a virulent strain of FIP coronavirus.³³

Transmission

Investigators remain unsure of the routes of natural transmission by which feline coronaviruses are passed between cats. Excretion of coronavirus by infected cats into the environment occurs by way of feces, oronasal secretions, and, possibly, urine.²⁵ Initial infection of susceptible cats most likely results from ingestion and/or inhalation of the coronavirus.¹¹ Close contact between cats is probably required for the most effective transmission of coronavirus, although the possibility of virus transmission by fomites (contaminated clothing, bedding, and dishware) also exists. Transmission of FIP coronavirus in utero, as suggested by several reports,^{23, 24} has not been convincingly shown to occur.

FELINE INFECTIOUS PERITONITIS

Incidence

Domestic cat and other Felidae, including lions, mountain lions, leopards, jaguars, cheetahs, lynxes, sand cats, and pallas cats, are susceptible to infection with FIP coronavirus.^{14, 28} In domestic cats, FIP disease occurs predominantly in young animals, although all ages are susceptible. A higher incidence occurs between 6 and 12 months of age, whereas a lower incidence is noted from 5 to 13 years of age, followed by an increased incidence in cats 14 years of age and

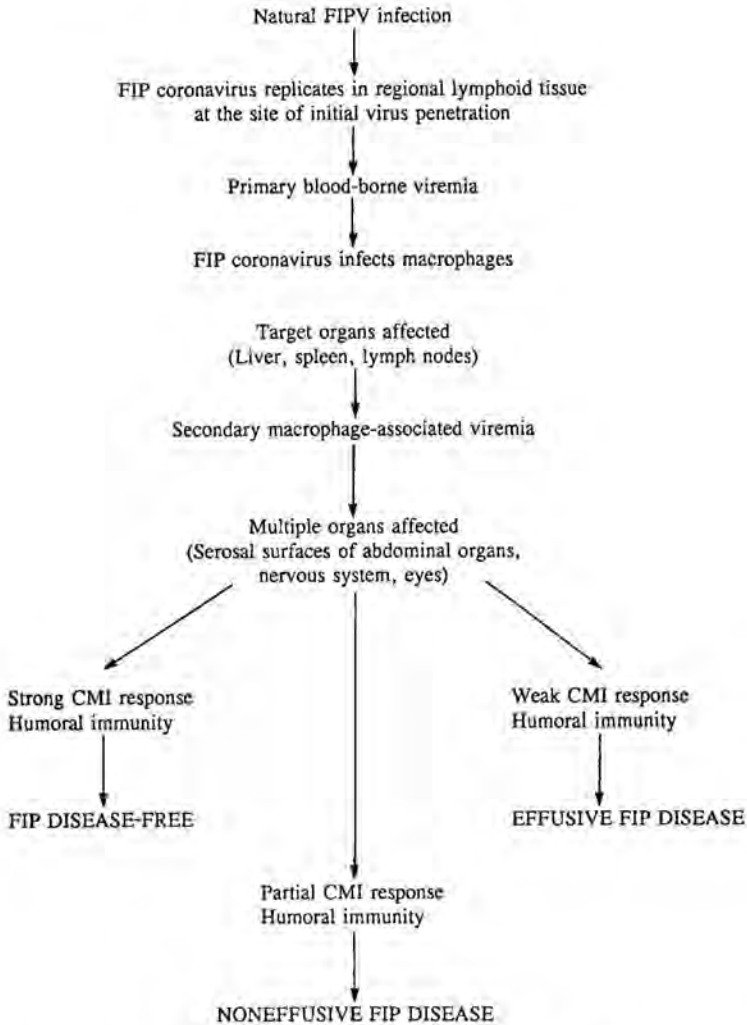


Figure 1. Pathogenesis of feline infectious peritonitis (FIP) CMI = cell-mediated immunity.

older.³⁶ Male and female cats are affected equally. FIP occurs more frequently in purebred cats than in other breeds.

Pathogenesis

After natural infection, localization and replication of FIP coronavirus occur in large mononuclear cells of regional lymphoid tissue at or near the site of initial virus penetration (Fig. 1).^{43, 44} A primary viremia results with free virus

and virus-infected mononuclear cells being transported to other body organs, especially to the liver, spleen, and lymph nodes. These organs are subsequently involved because they contain large populations of macrophages, which are the principal target cells for FIP coronavirus infection.⁴³ A secondary macrophage-associated viremia then occurs, resulting in further spread of FIP coronavirus throughout the body.⁹

The susceptibility of cats to FIP disease may involve several predisposing factors, including age at time of exposure, genetic susceptibility, physical condition, stress, presence of concurrent disease (especially feline leukemia virus and feline immunodeficiency virus infections), challenge dose and strain of feline coronavirus, route of infection, previous sensitization with nonprotective coronavirus antibodies, and cell-mediated immunocompetence.^{2,4}

If an effective cell-mediated immune response is exhibited during the primary phase of coronavirus infection, viremia will probably be terminated, thereby protecting the cat against FIP disease.²⁰ Most cats subsequently do not show clinical evidence of FIP coronavirus infection. Some cats, however, may develop a transient fever that lasts for 1 to 5 days and mild mesenteric lymphadenopathy.³⁰ If the infected cat is unable to mount an effective cell-mediated immune response and produces coronavirus antibodies that do not neutralize the virus, infection progresses rapidly into a fulminating form of FIP disease. A similar situation may occur if the cat has already acquired coronavirus antibodies through previous infection with a strain of feline enteric coronavirus or FIP coronavirus of low virulence.⁶

In the absence of an effective cell-mediated immune response, a strong nonprotective humoral response may result in effusive form of FIP disease. Cats that exhibit a partial cell-mediated immune response may develop noneffusive FIP disease.^{2,5}

An effective cell-mediated immune response does not always eliminate FIP coronavirus from the body. In some recovered cats, the infection may persist in various places in the body, such as the gastrointestinal tract or associated lymph nodes.³⁰ Factors that depress cell-mediated immune responsiveness, such as feline leukemia virus and feline immunodeficiency virus infections, concurrent disease, and advanced age, may allow recrudescence of macrophage-associated infection with periodic shedding of FIP coronavirus, thereby resulting in effusive or noneffusive disease.^{2,4}

An exaggerated and nonprotective humoral response results in excessive levels of coronavirus antibodies and the formation of large immune complexes that are rapidly phagocytized by reticuloendothelial cells.⁴⁴ Immune complexes deposited in small blood vessels fix and activate complement, thereby resulting in the release of the third component of complement. Phagocytosis of aggregates containing coronavirus, immunoglobulin, and complement is aided by the presence of receptors for immunoglobulin and complement on the macrophage surface.⁴³

Macrophages that are in perivascular locations ingest aggregates of intact FIP coronavirus, immunoglobulin, and complement and thus encourage replication of the virus and the release of new virus and complement components.²⁰ Uptake and processing of FIP coronavirus in these macrophages may be enhanced by an impaired cell-mediated immune response.⁵ Recurrent complement-mediated damage results in the release of chemotactic complement components and the attraction of neutrophils. Release of proteolytic enzymes from degenerated neutrophils exacerbates tissue damage.⁵

In cases of FIP disease, degenerative and proliferative changes occur in blood vessels, particularly in the endothelial and medial layers of small veins

and arteries in the peritoneal serosa and in the interstitial connective tissue of parenchymatous organs.¹⁸ The vascular lesion results in a pyogranulomatous lesion.⁵ In effusive disease, complement-mediated damage to the vascular endothelium results in increased vascular permeability and leakage of a non-septic exudate rich in fibrin and immunoglobulin.⁵ Severe damage to the vascular endothelium also contributes to disseminated intravascular coagulation. The development of multiple clotting abnormalities, including thrombocytopenia, increased quantity of fibrin-fibrinogen degradation products, and decreased activity of clotting factors VII, VIII, IX, XI, and XII, is evident in fatal cases of FIP disease.⁴²

Although most cats undergoing the primary phase of FIP coronavirus infection recover, many cats remain persistently infected, that is, they are persistent carriers of FIP coronavirus. A small number of these cats subsequently develop the fatal FIP disease weeks to months after the primary phase of infection.³⁶

Clinical Findings

In the early phase of FIP disease, cats with the effusive form may be presented with nonspecific signs, such as nonresponsive fever, anorexia, lethargy, weight loss, and pale mucous membranes. Icterus may be seen in patients with severe liver involvement.^{3,4} Recurring episodes of diarrhea and constipation may be observed.

Progressive abdominal distention occurs from an accumulation of ascitic fluid in the peritoneal cavity. The volume of fluid present in cases of effusive disease varies and is generally a reflection of disease chronicity.^{2,4} In chronic cases, a liter or more of fluid may accumulate within the peritoneal cavity. Abdominal palpation usually elicits no response of pain. In some cats, the omentum may be palpated as a firm, contracted mass in the anteroventral abdomen.^{2,4}

Pleural effusion with clinical signs of respiratory distress infrequently occurs in cats with effusive FIP disease. These cats are presented with decreased exercise tolerance, dyspnea, and muffled heart and lung sounds. Pericardial effusion may be present.³⁸ Ocular and central nervous system signs are seldom seen in cats with effusive disease.^{2,4} Cats that recover from effusive disease usually undergo a period of time with noneffusive disease before they show clinical evidence of complete recovery.²⁵

Clinical diagnosis of the noneffusive FIP disease usually is impeded by a lack of specific signs. Onset of noneffusive disease is more insidious than is onset of the effusive form and is frequently associated with organ-specific signs resulting from disseminated pyogranulomatous lesions in various organs. Nonspecific signs of weight loss, nonresponsive fever, and malaise may occur for several weeks before any organ-specific manifestations are present.^{2,4} Signs of renal or hepatic insufficiency and pancreatic, central nervous system, or ocular disease may be seen in cats with severe organ impairment.⁹

Abdominal palpation may reveal mesenteric lymphadenopathy and nodular irregularities that are caused by surface-oriented pyogranulomata on various viscera, especially the kidneys.^{2,4} Pneumonia with clinical signs of respiratory distress infrequently occurs. When present, pulmonary lesions consist of mixed inflammatory cell infiltrates in peribronchiolar areas that may radiographically appear as ill-defined, patchy, interstitial, and peribronchiolar densities.³⁸

Ocular involvement usually is associated with other clinical signs of noneffusive disease, but may be present as a single manifestation. Ocular lesions result from a necrotizing and pyogranulomatous uveitis that localizes around vascular structures.^{2,4} Changes in the anterior chamber include corneal edema, aqueous flare, hypotonia, iritis, hyphema, hypopyon, and keratic precipitates.

On ophthalmoscopic examination, flame-shaped or boat-shaped hemorrhages may be present. Engorgement of retinal vessels and perivascular cuffing is often noted. Choroidal inflammation may cause subretinal fluid accumulation and secondary bullous or linear retinal detachments.²¹

Neurologic signs in cats with noneffusive FIP disease are variable and may include incoordination, posterior paresis, nystagmus, convulsions, intention tremors, cranial and peripheral nerve deficits, hyperesthesia, generalized ataxia, head tilt, behavioral changes, and urinary incontinence.²² Signs reflecting central nervous system and ocular involvement frequently occur together in noneffusive disease. Lesions of central nervous system are usually multifocal or diffuse pyogranulomas and are located around the smaller blood vessels. The lesions are surface-oriented and primarily affect the choroid plexus, meninges, and ependyma.^{2,4} In cases of noneffusive disease, many patients that do not show neurologic involvement have histopathologic evidence of central nervous system involvement.²²

Laboratory Findings

Hemograms of cats with FIP disease often show a mild to moderate normocytic, normochromic anemia and leukocytosis that may be associated with absolute neutrophilia. Absolute leukopenia may develop in some cats, especially in more fulminating or fatal cases. Lymphopenia is commonly observed and is profound in cats with concurrent feline leukemia virus infection.³⁹

On serum chemistry profiles, elevations in blood urea nitrogen and serum creatinine may be present in cats with either effusive or noneffusive FIP and may reflect dehydration and inflammatory lesions in the kidneys. Elevations in serum alanine transaminase and serum alkaline phosphatase as well as hyperbilirubinemia may occur if the inflammatory process involves the liver.^{2,4} Total serum proteins exceed 7.8 g/dL in 55% of cats with effusive disease and in 75% of cats with noneffusive disease because of varied increases in alpha-2, beta-2, and gamma globulins. This polyclonal gammopathy is not pathognomonic for FIP disease but reflects its inflammatory nature.²⁵ Hyperglobulinemia also may occur in other inflammatory conditions that are associated with persistent antigenic stimulation of antibody-producing cells.

Aspirated peritoneal fluid typically is clear to slightly opaque or pale yellow to golden as well as being viscous in consistency. A stable foam often develops after shaking, presumably reflecting a protein content in excess of 5 g/dL.^{2,4} Fluid specimens may contain fibrin strands and flakes that settle with time and may clot when exposed to room air. Cellular count of fluid usually is between 1600 to 25,000 cells/ μ L. Stained smears from a concentrated fluid sample commonly show a mixture of intact neutrophils, macrophages, plasma cells, lymphocytes, mesothelial cells, and a few erythrocytes.⁹ Cultures of aspirated fluid for fungi, bacteria, and mycoplasmas usually reveal no growth.

Diagnosis

Clinical diagnosis of FIP disease is made by evaluating the presenting history, physical findings, laboratory results, coronavirus antibody titers, and exclusion of analogous diseases.²⁻⁴ These diagnostic maneuvers, however, do not provide conclusive evidence that a cat has FIP disease, especially in cases of noneffusive disease in which accumulative abdominal fluid is not available for examination.⁹

Tissue biopsy is the only diagnostic procedure that definitively confirms the presence of FIP disease in apparently healthy cats or sick cats with either effusive or noneffusive disease.²⁻⁹ Any diagnosis of FIP disease made without tissue biopsy or eventual necropsy examination must be considered, at best, to be a presumptive diagnosis.

Several serologic test procedures are available for detecting coronavirus antibodies in cats, including biologic assays, such as virus neutralization, and nonbiologic assays, such as indirect immunofluorescent antibody test, enzyme-linked immunosorbent assay, kinetics-based enzyme-linked immunosorbent assay, agar gel immunodiffusion, and passive hemagglutination techniques.⁹ The target antigen used in these assays may be either a FIP coronavirus (in liver sections of experimentally infected cats or in cell culture) or another coronavirus in the FIP coronavirus antigenic cluster, usually TGEV or CCV.³⁷

Coronavirus antibodies may be found in serum of apparently healthy cats, in cats with disorders other than effusive or noneffusive disease, and in cats with FIP disease. Excluding cats in catteries and in multiple-cat households, 10% to 40% of cats in the general feline population have coronavirus antibodies in their serum. If cats are housed together, the rate of seropositivity is completely absent or present in 80% to 90% of the cats, depending on whether feline coronavirus is enzootic in that cat population.⁵

There are several situations in which assay results for the detection of coronavirus antibody are potentially helpful to the clinician and the cat owner. Serotesting for feline coronavirus may be used as a screening procedure to determine if coronavirus is enzootic in a cat population and as an adjunct in the diagnosis of FIP disease.⁵

Most cats with histopathologically confirmed FIP disease have high coronavirus-antibody titers.⁵ Titers greater than 1:3200 usually are associated with noneffusive disease, whereas titers of 1:100 to 1:3200 may be found in cats with effusive and noneffusive disease and in cats with feline enteric coronavirus infection.²⁵ In some cats with FIP disease, negative titers or a decrease in titers may be seen terminally; this is a grave prognostic sign. In addition to correlating the positive coronavirus-antibody titer with other diagnostic information on the patient, the clinician should be aware that differences in assay results can be found between diagnostic laboratories and in the clinician's own interpretation of assay results.²

A few cats with histopathologically confirmed FIP disease may have negative coronavirus-antibody titers.⁵ Reasons for negative titers include disappearance of coronavirus antibodies in the terminal stages of FIP disease, formation of immune complexes that leave little if any free coronavirus antibodies to react in the assay procedure, use of assay systems that are not sensitive enough to detect low levels of coronavirus antibodies, and presence of small amounts of coronavirus antibodies in fulminating cases of effusive disease.³⁷

In addition, bovine serum components found in some commercial feline vaccines may induce antibody production in cats vaccinated with those prod-

ucts. These antibodies may react with antigenically similar bovine serum components in cell cultures that are used to propagate target viruses of the FIP coronavirus antigenic cluster for immunochemical assays. Resultant reactivity may be mistaken for coronavirus antibodies in serum of a recently vaccinated cat. Because of this potential interference, it is recommended that elective serotesting of healthy cats for evidence of exposure to feline coronavirus should be delayed until at least 3 to 4 months after the last parenteral vaccine was given.⁵

At the time of this writing, available serologic assays for detecting coronavirus antibodies do not identify the strain of coronavirus that is responsible for the cat's seroconversion; also, the presence of coronavirus-antibody titers merely indicates that the cat has been infected with a coronavirus in the coronavirus antigenic cluster.^{5, 36} Most healthy cats with positive coronavirus-antibody titers have probably been infected with strains of feline enteric coronavirus, with non-FIP disease-producing strains of FIP coronavirus, or with FIP disease-producing strains. Most healthy coronavirus antibody-positive cats are probably not immune carriers of highly virulent FIP coronavirus.³³ It is impossible to predict accurately the long-term prognosis of healthy coronavirus antibody-positive cat. Positive antibody titers do not indicate that a cat is protected against future development of FIP disease, will later develop FIP disease, or is definitely a hazard to other cats.^{2, 5, 36}

Treatment

Because effective treatment is unavailable for complete elimination of coronavirus infection, long-term prognosis for cats definitively diagnosed with FIP disease is extremely poor. Antiviral drugs are not available for effective treatment of affected cats, although research is ongoing to evaluate various antiviral compounds. Most treatment regimens provide, at best, only short-term remission. Palliative therapy is effective for cats with FIP disease that are in good physical condition, have a good appetite, and are free of severe anemia or neurologic deficits;⁹ however, few cats with FIP disease conform to these standards or are presented early enough in the course of disease to be given meaningful palliative therapy.

Effective drug therapy for FIP disease relies on the use of systemic corticosteroids (such as oral prednisolone, 2 to 4 mg/kg daily) to decrease the disseminated coronavirus antibody-mediated vasculitis.⁹ Although corticosteroids may provide short-term remission, long-term use is not curative in cats with disease resulting from defective cell-mediated immune response. The general well-being of cats that receive systemic corticosteroids should be monitored weekly to monthly. If the cat shows a favorable response to therapy during the first few weeks, treatment should be continued for at least 3 months.⁹ If the cat is in complete remission at the end of 3 months, the corticosteroids may be slowly withdrawn. Treatment should be reinstated, however, if signs of the disease recur. Progressive physical deterioration of the cat during treatment is a poor prognostic sign.⁹

Cats that develop pyogranulomatous lesions that only affect the eyes, especially unilateral or bilateral uveitis, respond relatively well to topical and/or systemic corticosteroid therapy³⁷ along with subconjunctival injection of methylprednisolone or triamcinolone acetonide (Figure 2). If ocular inflammation is severe and sight has been lost, enucleation may be indicated.

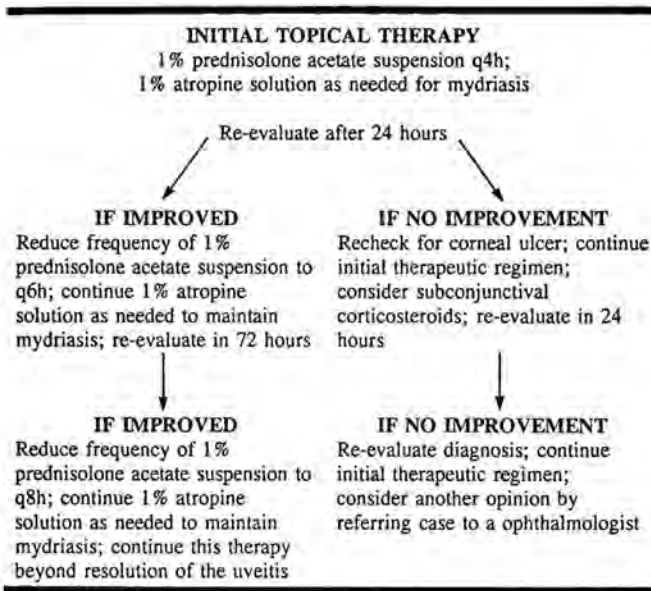


Figure 2. Recommendations for treatment of coronavirus-induced uveitis.

Control and Prevention

Incidence of new cases of FIP disease in catteries and multicat households may be reduced by promptly isolating all cats with signs associated with FIP disease, removing all cats infected with feline leukemia virus or feline immunodeficiency virus infection, and reducing overcrowding as well as by improving hygiene and nutrition, selecting queens that have good mothering instincts and are able to raise healthy litters, and only admitting cats that have negative coronavirus-antibody titers.²⁵

Using coronavirus-antibody serotesting as part of a test-and-removal program to control FIP disease (similar to successful programs used to reduce incidence of feline leukemia virus and feline immunodeficiency virus infections) cannot be recommended. Serologic assays used in detecting coronavirus antibodies in cats have poor specificity compared with the high accuracy of enzyme-linked immunosorbent assay and indirect fluorescent antibody testing procedures used to detect feline leukemia virus p27 antigen or levels of feline immunodeficiency virus antibodies. Removal of healthy coronavirus antibody-positive cats from catteries or multicat household is justified only if strong evidence that the cat is a source of FIP coronavirus infection for other cats exists.³

Vaccination

A first-generation temperature-sensitive FIP coronavirus (TS-FIPV) vaccine that protects cat against FIP coronavirus challenge is available (Primucell-FIP, SmithKline Beecham Animal Health, Exton, PA). The TS-FIPV vaccine contains

attenuated live virus and is derived by the following laboratory procedure. The original wild-type strain of FIP coronavirus, known as FIPV-DF2 isolate, is attenuated by 99 passages in Norden Laboratories feline kidney (NLFK) cell line, of which passages 61 to 99 are propagated at 31°C. The 99th passage of FIPV-DF2 is made temperature-sensitive by exposure to ultraviolet irradiation. The TS-FIPV is again propagated on NLFK cells for eight more passages and then lyophilized for subsequent vaccine use.¹⁵

The attenuated TS-FIPV strain replicates primarily in the upper respiratory tract and associated regional lymph nodes (mandibular, medial retropharyngeal, and cervical) of cats (Figs. 3 and 4). The TS-FIPV proteins stimulate local immunoglobulin A and a cell-mediated immune response, as well as a systemic cell-mediated immune response that may deter systemic dissemination of the FIP coronavirus.^{12, 16, 17}

The manufacturer (SmithKline Beecham Animal Health) recommends administering the Primucell-FIP vaccine intranasally to healthy cats 16 weeks of age or older. Initial vaccination is given with two doses 3 to 4 weeks apart. Annual revaccination with a single dose is recommended. Vaccinated pregnant cats, dexamethasone-suppressed cats, feline leukemia virus-infected cats, and feline enteric coronavirus-infected cats have not shown a febrile response or blood dyscrasias.¹⁵

FELINE ENTERIC CORONAVIRUS INFECTION

Clinical and Laboratory Findings

Various feline enteric coronavirus strains produce clinical signs that resemble those produced by TGEV in swine and by CCV in puppies.²⁵ Feline enteric

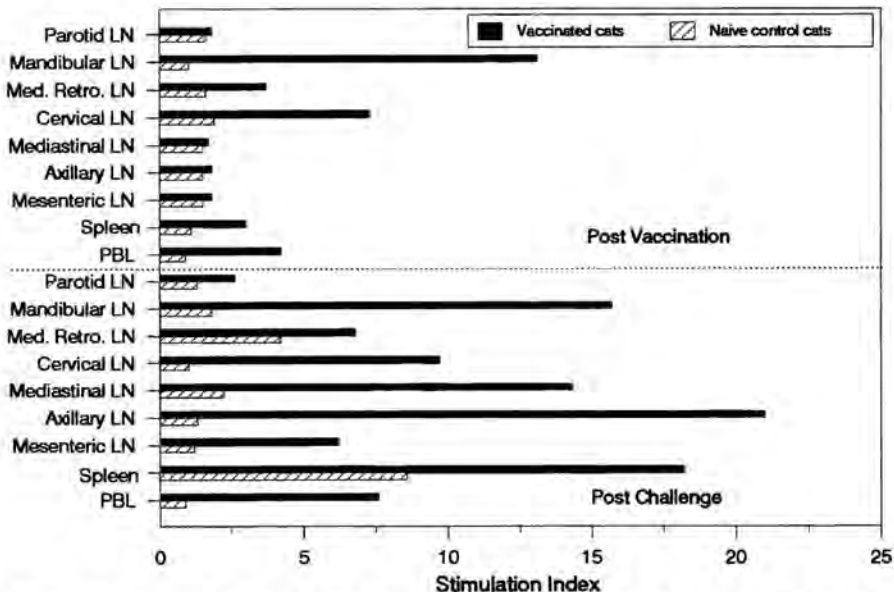


Figure 3. Lymphocyte proliferative responses to viral antigens as measured in regional lymph nodes (LN), spleen, and peripheral blood lymphocytes (PBL). Each bar represents the mean response from two cats. (Courtesy of Nancy E. Pfeiffer, SmithKline Beecham Animal Health, Exton, PA)

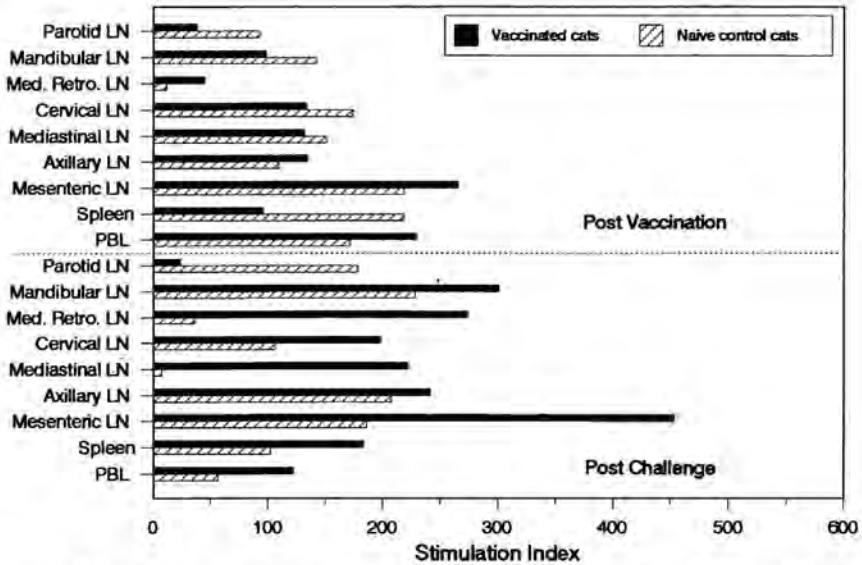


Figure 4. Lymphocyte proliferative responses to Con A as measured in regional lymph nodes (LN), spleen, and peripheral blood lymphocytes (PBL). Each bar represents the mean response from two cats. (Courtesy of Nancy E. Pfeiffer, SmithKline Beecham Animal Health, Exton, PA)

coronavirus infection is most severe in recently weaned kittens; most infected adult cats, however, remain apparently healthy.²⁷ Clinical signs in kittens include low-grade fever, intermittent vomiting, depression, and mild to moderately severe diarrhea that lasts for 2 to 5 days. Kittens with severe disease may be anorectic for 1 to 3 days.³²

In kittens with more severe infection, a transient neutropenia may accompany the onset of diarrhea.²⁵ The most severe lesions, such as villous atrophy, fusion of adjacent villi, and sloughing of the mature columnar epithelium from the upper portion of the villi, occur in the mature columnar epithelia of the duodenum, jejunum, and ileum.^{27, 32} Mortality is negligible, and nearly all affected kittens recover.²⁵

Diagnosis

A definitive diagnosis of feline enteric coronavirus infection is difficult to obtain. Clinical resemblance of feline enteric coronavirus infection to other enteritides can confound diagnosis.⁸ Electron microscopy of stool specimens to search for coronavirus particles is expensive, time-consuming, and fraught with false-negative and false-positive results. Furthermore, true-positive results provide only presumptive evidence of the cause of diarrhea.⁸

Coronavirus antibody assays do not provide the information for a definitive diagnosis of feline enteric coronavirus infection.^{25, 27} Histopathologic lesions also are not sufficiently specific for the diagnosis, and viral isolation is impractical for routine use.⁸

Treatment

Supportive care is the only treatment option for feline enteric coronavirus infection in kittens.^{25, 27} Food and water should be withheld during the more severe phases of infection, and a balanced electrolyte solution be given parenterally if there is moderate to severe dehydration. Antimicrobial therapy usually is not required.

Vaccination

In a study at Louisiana State University, Primucell-FIP vaccine was administered to 9-week-old, specific-pathogen-free kittens according to the manufacturer's instructions. A similar group of nonvaccinated animals served as controls. All of the kittens were oronasally challenged with virulent feline enteric coronavirus 2 weeks after final vaccination. The extent of clinical signs caused by feline enteric coronavirus infection in the vaccinated and nonvaccinated kittens is shown in Figure 5.

The vaccinated kittens experienced milder enteric disease after challenge exposure than did age-matched nonvaccinated kittens. The febrile response on days 1 and 3 postchallenge were significantly lower in the vaccinated kittens ($p < 0.05$). There was also a significant reduction ($p < 0.05$) in the amount of feline enteric coronavirus isolated from the jejunum, duodenum, and mesenteric lymph nodes of vaccinated kittens. Morphometric analysis of the duodenum and the jejunum indicated that villus height was less affected in the vaccinated kittens than in nonvaccinated kittens (Figure 6). There was a significant difference ($p < 0.05$) in villus height in the jejunum but not in the

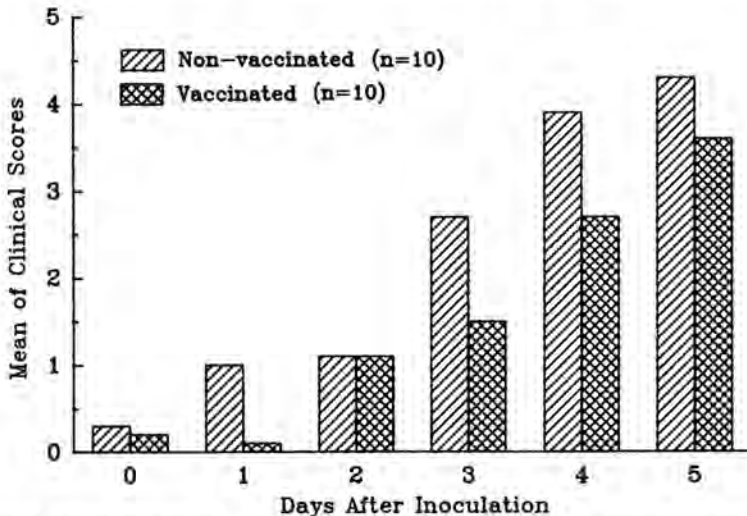


Figure 5. Mean clinical scores of nonvaccinated kittens and kittens vaccinated twice intranasally with TS-FIPV vaccine following feline enteric coronavirus challenge. The scoring system was devised to judge the extent of clinical signs; included are the following signs and point value(s): appetite (0 to 2), stools (0 to 2), vomiting (2), attitude (2), and febrile response (0 to 3).

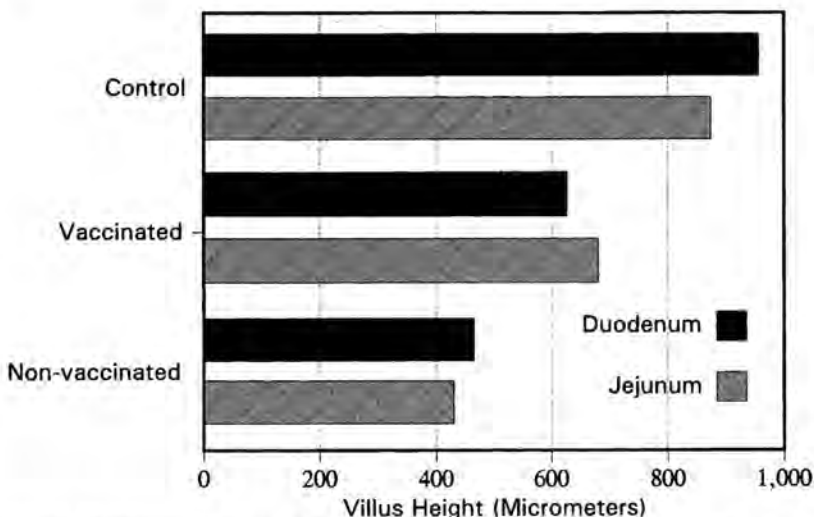


Figure 6. Morphometric results of the small intestines from ten nonvaccinated kittens and ten kittens vaccinated twice intranasally with TS-FIPV vaccine following feline enteric coronavirus challenge. Five kittens served as age-matched (nonvaccinated-nonchallenged) controls.

duodenum of the vaccinated group. In addition, the nonvaccinated kittens lost significantly more weight than the vaccinated kittens. The results of this study indicated that the TS-FIPV vaccine partially protected the kittens against disease caused by feline enteric coronavirus infection.

Prevention

Various feline enteric coronavirus strains are very common in the general cat population. The virus is found in virtually every cattery and multicat household and in approximately 25% of all outdoor cats.²⁵ Thus, it is nearly impossible to prevent kittens and adult cats from being exposed to feline enteric coronavirus. Nature limits the severity of feline enteric coronavirus infection by providing young kittens with maternal antibody protection until 6 to 12 weeks of age.²⁵

SUMMARY

Cats are susceptible to natural infection with several strains of feline coronavirus that may result in either effusive and noneffusive FIP disease or in subclinical to severe enteritis. Investigators are still unsure of the routes by which strains of coronavirus are transmitted between cats. Excretion of coronavirus by infected cats into the environment occurs by way of feces, oronasal secretions, and, possibly, urine. FIP coronavirus remains stable outside the host for as long as 3 to 7 weeks and is rapidly inactivated by most household disinfectants.

Clinical diagnosis of coronavirus infection is made by evaluating the

presenting history, physical findings, laboratory results, coronavirus antibody titers, and by excluding analogous diseases. The presence of coronavirus antibodies can be used to screen cats for the presence of coronavirus infection and as an adjunct in diagnosing clinical coronavirus infection. A intranasal TS-FIPV vaccine that protects against natural coronavirus challenge is available for healthy cats 16 weeks of age or older.

References

1. Addie DD, Jarrett O: A study of naturally occurring feline coronavirus infections in kittens. *Vet Rec* 130:133-137, 1992
2. August JR: Feline viral diseases, *In* Ettinger SJ (ed): *Textbook of Veterinary Internal Medicine*, ed 3. Philadelphia, WB Saunders, 1989, pp 312-340
3. August JR: Preventive health care and infectious disease control, *In* Sherding RG (ed): *The Cat: Diseases and Management*. New York, Churchill Livingstone, 1988, pp 391-404
4. August JR: Feline infectious peritonitis: An immune-mediated coronaviral vasculitis. *Vet Clin North Am Small Anim Pract* 14:971-984, 1984
5. Barlough JE: Cats, coronaviruses and coronavirus antibody tests. *J Small Anim Pract* 26:353-362, 1985
6. Barlough JE: Do feline coronavirus antibody tests provide a conclusive diagnosis? *Vet Med/Small Anim Clin* 79:1027-1035, 1984
7. Barlough JE: Serodiagnosis aids and management practices for feline retrovirus and coronavirus infections. *Vet Clin North Am Small Anim Pract* 14:955-969, 1984
8. Barlough JE, Stoddart CA: Feline coronaviral infections. *In* Greene CE (ed): *Infectious Diseases of the Dog and Cat*. Philadelphia, WB Saunders, 1990, pp 300-312
9. Barlough JE, Stoddart CA: Feline infectious peritonitis. *In* Scott FW (ed): *Contemporary Issues in Small Animal Practice*, vol 3. New York, Churchill Livingstone, 1986, pp 93-108
10. Barlough JE, Stoddart CA, Sorresso GP, et al: Experimental inoculation of cats with canine coronavirus and subsequent challenge with feline infectious peritonitis virus. *Lab Anim Sci* 34:592-597, 1984
11. Barlough JE, Weiss RC: Feline infectious peritonitis. *In* Kirk RW (ed): *Current Veterinary Therapy VIII*. Philadelphia, WB Saunders, 1983, pp 1186-1193
12. Christianson KK, Ingersoll JD, Landon RM, et al: Characterization of a temperature sensitive feline infectious peritonitis coronavirus. *Arch Virol* 109:185-196, 1989
13. de Groot RJ, Maduro J, Lenstra JA, et al: CDNA cloning and sequence analysis of the gene encoding the peplomer protein of feline infectious peritonitis virus. *J Gen Virol* 68:2639-2646, 1987
14. Evermann JF, Burns G, et al: Diagnostic features of an epizootic of feline infectious peritonitis in captive cheetahs. *Am Assoc Vet Lab* 26:365-382, 1984
15. Gerber JD: New approaches to feline infectious peritonitis prevention *In* *Feline Infectious Peritonitis: Current Status*. Lawrenceville, NJ, Veterinary Learning Systems, 1989, pp 20-22
16. Gerber JD, Ingersoll JD, Gast AM, et al: Protection against feline infectious peritonitis by intranasal inoculation of a temperature sensitive-FIPV vaccine. *Vaccine* 8:536-542, 1990
17. Gerber JD, Pfeiffer NE, Ingersoll JD, et al: Characterization of an attenuated temperature sensitive feline infectious peritonitis vaccine virus. *In* *Coronaviruses and Their Diseases*. New York, Plenum, 1990
18. Hayashi T, Goto N, Takahashi R, et al: Systemic vascular lesions in feline infectious peritonitis. *Jpn J Vet Sci* 39:365-377, 1977
19. Hornizek MC, Osterhaus ADME: The virology and pathogenesis of feline infectious peritonitis. Brief review. *Arch Virol* 59:1-15, 1979
20. Jacobse-Geels HEL, Daha MR, Horzinek MC: Antibody immune complexes and complement activity fluctuations in kittens with experimentally induced feline infectious peritonitis. *Am J Vet Res* 43:666-670, 1982

21. Kern TJ: Intraocular inflammation in cats as a manifestation of systemic diseases. *Cornell Health Center News*, Winter 1984, pp 4-8
22. Kornegay JN: Feline infectious peritonitis. The central nervous system form. *J Am Anim Hosp Assoc* 14:580-584, 1978
23. Pastoret PP, Henroteaux M: Epigenetic transmission of feline infectious peritonitis. *Comp Immunol Microbiol Infect Dis* 1:67-70, 1978
24. Pastoret PP, Gouffaux M, Henroteaux M, et al: Feline infectious peritonitis. *J Am Vet Med Assoc* 171:740-741, 1977
25. Pedersen NC: Coronavirus diseases (coronavirus enteritis, feline infectious peritonitis). *In* Holzworth J (ed): *Diseases of the Cat*, vol 1. Philadelphia, WB Saunders, 1987, pp 193-213
26. Pedersen NC: Virologic and immunologic aspects of feline infectious peritonitis virus infection. *Adv Exp Med Biol* 218:529-550, 1987
27. Pedersen NC: Feline infectious peritonitis and feline enteric coronavirus infections. Part I. Feline enteric coronaviruses. *Feline Pract* 13:13-19, 1983
28. Pedersen NC: Feline infectious peritonitis and feline enteric coronavirus infections. Part II. Feline infectious peritonitis. *Feline Pract* 13:5-20, 1983
29. Pedersen NC, Black JW: Attempted immunization of cats against feline infectious peritonitis. *Am J Vet Res* 44:229-234, 1983
30. Pedersen NC, Black JW, Boyle JF, et al: Pathogenic differences between various coronavirus isolates. *Adv Exp Med Biol* 173:365-380, 1984
31. Pedersen NC, Boyle JF: Immunologic phenomena in the effusive form of feline infectious peritonitis. *Am J Vet Res* 41:868-876, 1980
32. Pedersen NC, Boyle JF, Floyd K, et al: An enteric coronavirus of cats and its relationship to feline infectious peritonitis. *Am J Vet Res* 42:368-377, 1981
33. Pedersen NC, Floyd K: Experimental studies with three new strains of feline infectious peritonitis virus: FIPV-UCD2, FIPV-UCD3, and FIPV-UCD4. *Compend Contin Educ Pract Vet* 7:1001-1011, 1985
34. Pedersen NC, Ward J, Mengeling WL: Antigenic relationship of the feline infectious peritonitis virus to coronaviruses of other species. *Arch Virol* 58:45-53, 1978
35. Spaan W, Cavanagh D, Horzinek MC: Coronaviruses: Structure and genome expression. *J Gen Virol* 69:2939-2952, 1988
36. Scott FW: Update on FIP. *Proc Kal Kan Symposium* 12:43-47, 1988
37. Scott FW: The real and unreal feline coronaviruses. *In* *Feline Medicine II*. Lawrenceville, NJ, Veterinary Learning Systems, 1986, pp 27-32
38. Sherding RG: Feline infectious peritonitis. *Compend Contin Educ Pract Vet* 1:95-102, 1979
39. Stoddart M: Feline infectious peritonitis. *In* Grunsell CSG, Hill FWG, Raw RE (eds): *The Veterinary Annual*, Issue 26. Bristol, UK, Sciencetechnica, 1986, pp 324-329
40. Vennema H, de Groot RJ, Harbour DA, et al: Early death after feline infectious peritonitis virus challenge due to recombinant vaccinia virus immunization. *J Virol* 64:1407-1409, 1990
41. Wege H, Siddell ST, ter Meulen V: The biology and pathogenesis of coronaviruses. *Curr Top Microbiol Immunol* 99:165-200, 1982
42. Weiss RC, Dodds WJ, Scott FW: Disseminated intravascular coagulation in experimentally induced feline infectious peritonitis. *Am J Vet Res* 41:663-671, 1980
43. Weiss RC, Scott FW: Pathogenesis of feline infectious peritonitis. Nature and development of viremia. *Am J Vet Res* 42:382-390, 1981
44. Weiss RC, Scott FW: Pathogenesis of feline infectious peritonitis: Pathologic changes and immunofluorescence. *Am J Vet Res* 42:2036-2048, 1981
45. Woods RD, Pedersen NC: Cross protection studies between feline infectious peritonitis and porcine transmissible gastroenteritis virus. *Vet Microbiol* 4:11-16, 1979

Address reprint requests to

Johnny D. Hoskins, DVM, PhD
 Department of Veterinary Clinical Sciences
 Louisiana State University
 School of Veterinary Medicine
 South Stadium Drive
 Baton Rouge, LA 70803