



Since January 2020 Elsevier has created a COVID-19 resource centre with free information in English and Mandarin on the novel coronavirus COVID-19. The COVID-19 resource centre is hosted on Elsevier Connect, the company's public news and information website.

Elsevier hereby grants permission to make all its COVID-19-related research that is available on the COVID-19 resource centre - including this research content - immediately available in PubMed Central and other publicly funded repositories, such as the WHO COVID database with rights for unrestricted research re-use and analyses in any form or by any means with acknowledgement of the original source. These permissions are granted for free by Elsevier for as long as the COVID-19 resource centre remains active.

Late onset, symptomatic, demyelinating encephalomyelitis in mice infected with MHV-JHM in the presence of maternal antibody

S. Perlman,^{1*} R. Schelper,² E. Bolger² and D. Ries¹

Departments of ¹*Pediatrics and* ²*Pathology, University of Iowa School of Medicine, Iowa City, IA 52242, U.S.A.*

(Received June 9, 1986; accepted in revised form September 10, 1986)

Perlman, S. (Dept of Paediatrics, University of Iowa School of Medicine, IA 52242, U.S.A.), R. Schelper, E. Bolger and D. Ries. Late onset, demyelinating encephalomyelitis in mice infected with MHV-JHM in the presence of maternal antibody. *Microbial Pathogenesis* 1987; 2: 185-194.

The presence of maternal antibodies protected suckling C57BL/6 mice from the clinical manifestations of the acute encephalomyelitis caused by mouse hepatitis virus, strain JHM (MHV-JHM), a coronavirus, even though histological evidence of encephalomyelitis was found at early times after inoculation. 100% of infected suckling mice developed a fatal disease in the absence of maternal antibody. By 14 days after inoculation, the brains of all antibody-protected mice examined were nearly normal on histological examination. At 3-8 weeks post-inoculation, approximately 40% of the antibody-protected mice developed a neurological disease characterized by hindlimb paralysis and wasting. Evidence of inflammation and demyelination was apparent in the spinal cord and brainstem. The mice that remained asymptomatic at this time showed few signs of inflammation and none developed clinical disease over the following 9 months. Viral antigen could be detected in most of the mice examined at all times after inoculation, whether symptomatic or not, and was particularly evident in the animals with hindlimb paralysis. MHV-JHM could be consistently cultured from the mice with hindlimb paralysis. These results show that maternal immune factors can completely protect susceptible mice from the acute, fatal, clinical encephalomyelitis caused by MHV-JHM, but cannot prevent the establishment of a latent state and subsequent development of virus-induced, clinically evident, demyelinating disease. This model will be useful for studying the virus and host factors important for the development of MHV-JHM latency and subsequent virus-induced demyelination.

Key words: mouse hepatitis virus; demyelination; maternal antibody; immunoperoxidase.

Introduction

Several strains of mouse hepatitis virus, a member of the coronavirus family, cause persistent neurological infections in rodents and as such serve as models of chronic neurological human diseases such as multiple sclerosis and subacute sclerosing panencephalitis.^{1,2}

The JHM strain (MHV-JHM) causes either an acute encephalomyelitis or an acute or chronic demyelinating disease in mice and rats as well as a subacute demyelinating encephalomyelitis in rats.³⁻¹⁰ In all of these diseases, with the exception of the acute encephalomyelitis, oligodendrocytes are preferentially affected, with most of the virus-induced lesions located in the white matter of the brain and spinal cord. MHV-JHM

* Corresponding author.

infects other tissues, such as the liver, but this is a relatively minor part of the disease process.

The outcome of a given infection is dependent upon the age and strain of rodent infected as well as upon the biological properties and route of inoculation of the virus. The administration of monoclonal antibody directed against the glycoprotein E2 of MHV-JHM prior to infection prevents the acute encephalomyelitis, but the mice still show evidence of demyelination on histological examination.¹¹ Similarly, the presence of maternal antibody protects suckling mice from the acute infection, when administered prior to inoculation of virus.¹² Maternal antibody crosses the neonatal gut until approximately 15 days postpartum.¹³ Since MHV-JHM appears to persist in mice in the presence of maternal immune factors,¹² the immature mouse must be able to mount an immune response in order to prevent a recrudescence of the infection after the waning of passive antibody.

We have devised a model in which MHV-JHM-infected suckling mice developed a clinically asymptomatic encephalomyelitis within one week of inoculation; virus could be isolated only infrequently from these mice. Subsequently, MHV-JHM could be cultured from about 40% of mice at 3–8 weeks post-inoculation with concomitant development of a clinically evident demyelinating encephalomyelitis. In this communication, we describe the virological, histological and serological characterization of this infection.

Results

Acute encephalomyelitis

Suckling mice born to unimmunized mothers infected intranasally with MHV-JHM (5×10^4 PFU) at 10 days of age developed an acute encephalomyelitis with all mice dying by 7 days post-inoculation (Fig. 1). Clinical signs including hunching, ruffled fur, irritability and lethargy. Three of 12 mice developed these signs within 3 days of inoculation, whereas the remaining 9/12 did so within the following 4 days. Virus titers in the brains of infected animals at 3 and 5 days post-inoculation were approximately 4×10^3 and 2×10^4 PFU/g respectively (Table 1), and viral antigen could be found throughout the brain parenchyma (Table 2), in both the grey and white matter, particularly at day 5 post-inoculation. Histological examination of the brain at 3 days post-inoculation revealed a small amount of leptomeningeal infiltration whereas at 5 days post-inoculation it showed an acute encephalitis, including perivascular, parenchymal and leptomeningeal inflammatory infiltrates, and proliferating astrocytes and microglia surrounding neurons (glial stars).

Antibody protected mice: clinical studies

If female mice were immunized prior to mating, the offspring were completely protected against the acute, fatal encephalomyelitis in agreement with published results.¹² In our experiments, female mice were immunized with MHV-JHM in Freund's adjuvant five times. Resulting antibody titers ranged from 1:700 to 1:4300 (mean 1:2700) by plaque-reduction neutralization assay (Fig. 2). The offspring were infected intranasally at 10 days of age with the same dose of virus (5×10^4 PFU) that caused the acute encephalomyelitis in the offspring of unimmunized mothers. As shown in Fig. 1, 100% of the suckling mice survived the infection, and none developed any signs of clinical disease during the first few weeks following virus inoculation. In the period 3–8 weeks after inoculation (mean: 35 d, range 23–60 d), 40% (12/30) of the mice developed a neurological illness characterized by hindlimb paralysis. The clinical disease was variable in the rapidity with which hindlimb paresis progressed to complete paralysis. In some

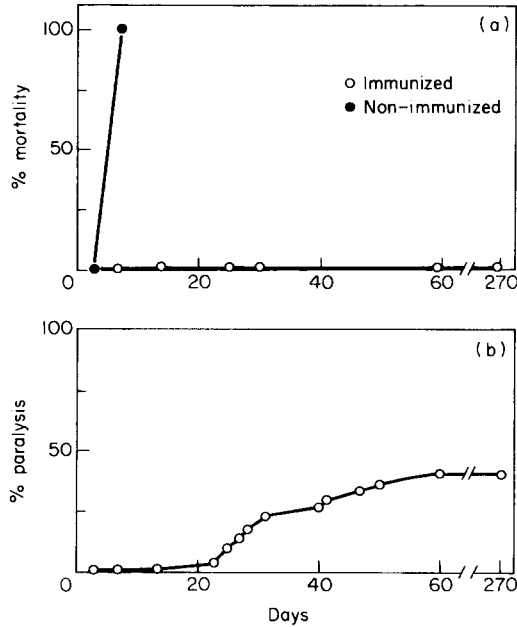


Fig. 1. Clinical disease in 10 day old suckling C57BL/6 mice inoculated with MHV-JHM (5×10^4 PFU). (a) Mortality caused by MHV-JHM in mice born to immunized and non-immunized female mice. Non-immunized mice developed acute encephalitis; the immunized mice were fully protected. (b) This panel shows the percentage of maternal antibody-protected mice which developed hindlimb paralysis. Twelve and 83 suckling mice were used in the non-immunized and immunized groups respectively.

Table 1 Viral titers in mice inoculated intranasally with MHV-JHM

	Day post-inoculation	Brain		Spinal cord	
		No. positive No. tested	Av. titer ^a (log ₁₀ PFU/g)	No. positive No. tested	Av. titer ^a (log ₁₀ PFU/g)
-maternal immunization	3	3/3	3.65	Not tested	
	5	4/4	4.08	1/2	2.30
+maternal immunization and clinically asymptomatic	3	4/7	3.22	2/3	2.78
	7	1/6	2.85	0/3	—
	14	1/6	1.83	0/1	—
	30	0/4	—	0/1	—
+maternal immunization and hindlimb paralysis	60	0/3	—	0/3	—
	23-60	6/7	3.61	4/6	3.86

^a Calculated for positive samples; median titers are shown.

mice this occurred over 2 days, whereas in others, the transition to complete paralysis was more gradual. Mice which remained asymptomatic at 60 d post-inoculation did not develop neurological disease over the following 9 months.

Viral and histological studies

Day 3: Paraffin-embedded sections of mice brains and spinal cords stained with hematoxylin-eosin showed minimal evidence of inflammatory changes or cellular

Table 2 Viral antigen in suckling C57BL/6 mice inoculated intranasally with MHV-JHM

	Days post-inoculation	Brain	Spinal cord
-maternal immunization	3	2/2	Not tested
	5	3/3	0/3
+maternal immunization and clinically asymptomatic	3	3/3	0/3
	7	8/8	1/3
	14	2/3	2/3
	30	2/4	2/3
	60	8/8	3/3
+maternal immunization +hindlimb paralysis	23-60	3/3	3/3

Data are expressed as number with positive immunoperoxidase assay/total examined.

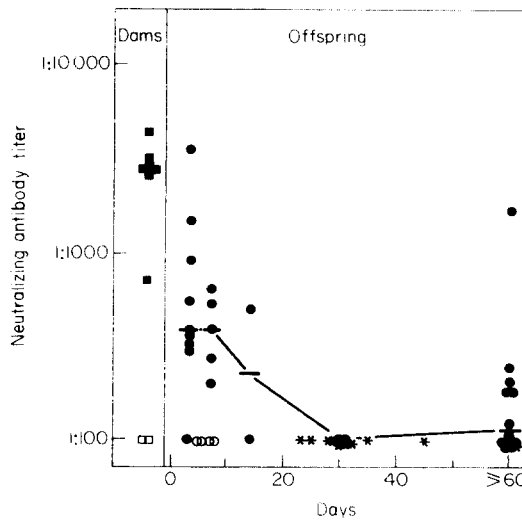


Fig. 2. Neutralizing antibody titers from immunized and non-immunized dams and their offspring at different times after inoculation. Titers for all mice 60 days and older are presented together. Each point represents sera from a different mouse. ■—immunized dam, □—unimmunized dam, ○—unimmunized offspring, ●—immunized asymptomatic offspring, *—mice with hindlimb paralysis. The line connects the median titers of the asymptomatic mice.

degeneration. Virus could be cultured from brains and spinal cords but not livers at this time (Table 1). Using an immunoperoxidase assay, viral antigen was detected throughout the brain in both the grey and white matter in the cerebrum, cerebellum and brainstem. No viral antigen could be detected in the spinal cord at this time (Table 2).

Day 7: On histological examination, the brains of mice 7 days after inoculation showed evidence of meningoencephalitis (Fig. 3), although the mice were totally asymptomatic. There were perivascular lymphocytic infiltrates and widespread, focal petechiae throughout the grey and white matter. Subependymal and meningeal infiltrates were also present. The cerebrum was heavily involved, with fewer inflammatory cells present in the hippocampus. Glial stars, similar to those seen in the acutely-infected mice, were present in the cerebral cortex adjacent to injured neurons. Lymphocytic infiltrates were also apparent in the diencephalon and pons, with minimal

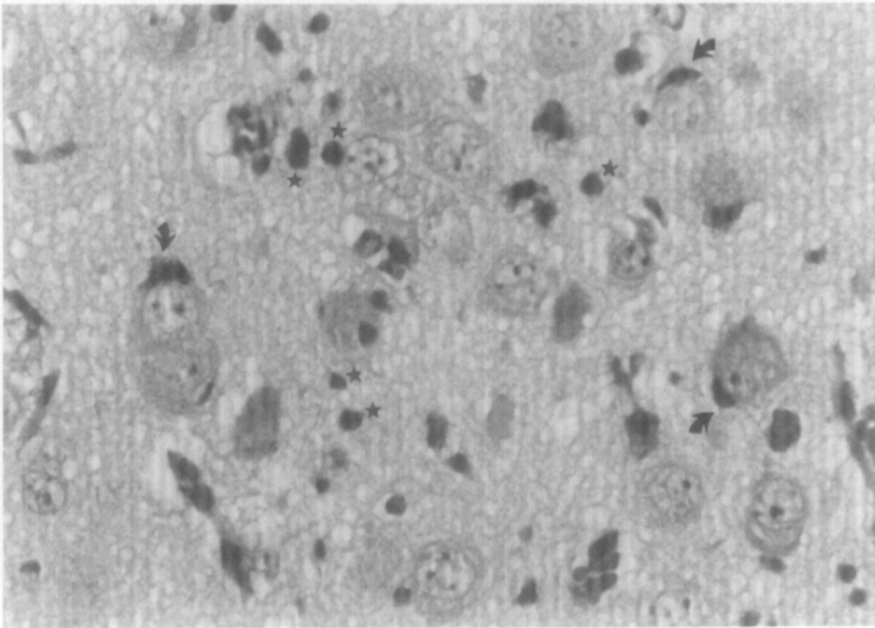


Fig. 3. Numerous neurons with their large nuclei and prominent nucleoli are seen, with reactive microglia and proliferating astrocytes present between (★) and adjacent to these neurons (arrows). This section is from the grey matter of the cerebrum of a 17 day old maternal antibody-protected suckling mouse inoculated with MHV-JHM at day 10. The mouse was asymptomatic at the time of sacrifice. Hematoxylin and eosin, $\times 540$.

involvement of the cerebellum. The liver showed evidence of viral infection also, with a few areas of lymphocytic infiltration in a nodular pattern apparent, although infectious virus was not present.

Viral antigen could be readily detected throughout the grey and white matter of the brain by immunocytochemical analysis of frozen sections and was also observed in scattered foci in a few of the spinal cords of these mice (Table 2). Virus could be cultured from the brain at seven days after inoculation in 1 of 6 mice examined (Table 1).

Day 14: By 14 days after inoculation, the brains showed much less evidence of disease on histological examination. No meningeal infiltration was present and only a small amount of lymphocytic proliferation was apparent in the grey and white matter of the parenchyma. Viral antigen could be detected by immunoperoxidase assay in scattered cells of the brains and spinal cords of two of three mice examined (Table 2). Many of the cells containing antigen were not in areas of cellular infiltration. Virus could be cultured at low titer from the brains of one of six mice assayed at this time (Table 1), but not from the liver or spinal cord.

Day 30 post-inoculation and longer in mice without neurological disease: Histological examination of the brains of mice without neurological disease at 30 d post-inoculation and longer showed no meningeal infiltration, but did show a few areas of lymphocytic infiltration of the parenchyma. Viral antigen could be detected by immunocytochemical methods in scattered cells in most of the mice examined (Table 2). Occasionally the antigen-containing cells were surrounded by a lymphocytic infiltrate, but more commonly, these cells did not invoke an inflammatory response (Fig. 4). Hematoxylin-eosin stained sections of the spinal cord showed no abnormalities except for a few lymphocytic nodules in one of the five mice examined. Examination of the livers of the older mice revealed a few focal parenchymal infiltrates with

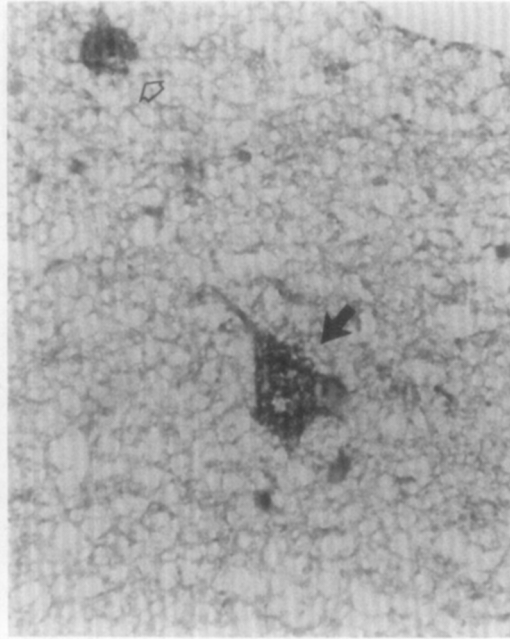


Fig. 4. This frozen section of the cerebrum of an asymptomatic maternal antibody-protected mouse inoculated 97 days prior to sacrifice shows viral antigen present in the cytoplasm of two cells (indicated by arrows) one of which is morphologically a neuron (solid arrow). No inflammatory response is apparent. This section was briefly counterstained with hematoxylin, $\times 560$.

lymphocytes and eosinophils present. Viral antigen was detected in only 1/8 of the livers examined and in marked contrast to the results obtained in the antigen studies, no virus could be cultured from the brains, spinal cords or livers of these older mice (Table 1).

Animals with hindlimb paralysis: 40% of the antibody-protected mice developed neurological disease from 23 to 60 days post-inoculation. Histological examination of the central nervous system of these mice revealed multiple abnormalities, especially in the spinal cord. Areas of destruction were apparent in the mesencephalon and pons, primarily in the white matter, although lymphocytic infiltrates were also present in the adjacent grey matter. The cerebrum showed a few areas of lymphocytic infiltration, and a basilar meningeal infiltrate was apparent. The spinal cord had many areas of focal damage with lymphocytic infiltration. After staining with Luxol Fast Blue, extensive white matter destruction was apparent with many foamy histiocytes present (Fig. 5). Many degenerating pyknotic cells were also observed in the white matter (Fig. 5). Although these cells could not be definitively identified by electron microscopy, their small size and presence in white matter suggested that they were most likely oligodendrocytes. A few coronavirus-like particles were tentatively identified by electron microscopy but they were not present in large clusters, as seen in the acute infection⁵ (data not shown).

Viral antigen could be detected throughout the brain and spinal cord, principally in the white matter (Table 2). Virus was cultured from the brains and spinal cords of mice with hindlimb paralysis at titers approaching those found in acutely infected mice (Table 1).

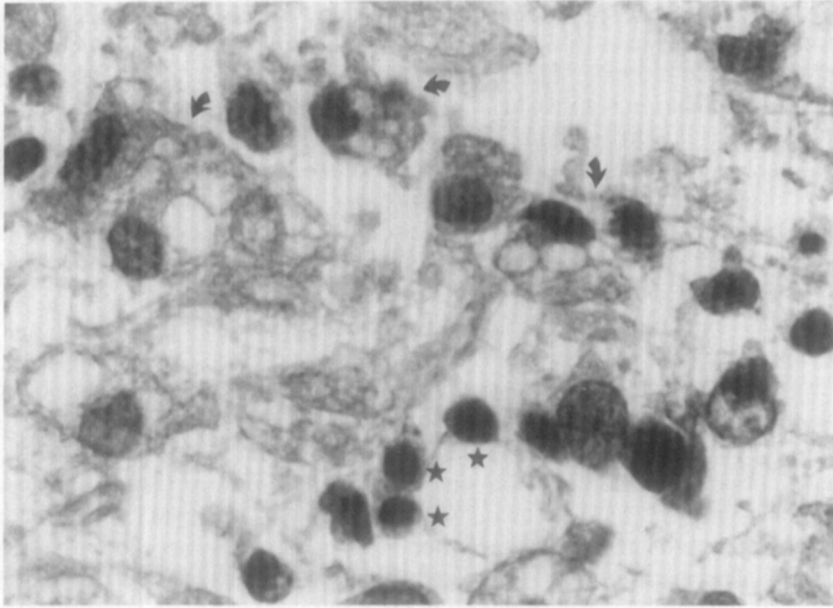


Fig. 5. This section from the pons of a 52 day old maternal antibody-protected mouse with hindlimb paralysis shows an area of intense white matter destruction, evidenced by the presence of foamy histiocytes (arrows). Numerous pyknotic cells are also present (★). Luxol Fast Blue, $\times 1330$.

Serological studies

Mean neutralization titers, as determined by a constant virus-variable serum plaque reduction assay was 1:2700 in immunized female mice (Fig. 2). Antibody titers in the offspring rapidly decreased over the first few weeks of life, and became undetectable in all mice which developed hindlimb paralysis. Many of the mice which remained asymptomatic also had undetectable titers, although low levels of neutralizing antibody were present in some. Thus, the majority of mice, whether symptomatic or not, did not develop significant levels of neutralizing antibody to MHV-JHM, suggesting that the level of antibody did not correlate with protection from the delayed onset neurological disease.

Sera from immunized females and from mice which developed hindlimb paralysis were tested for their ability to neutralize virus isolated from infected, symptomatic mice. The antibody titers in each case were approximately the same as when tested against the original strain of JHM, so that maternal sera had high neutralizing titers whereas those of the symptomatic offspring had titers $< 1:100$.

Discussion

Maternal immune factors fully protect suckling mice from the acute, fatal encephalomyelitis induced by the murine coronavirus JHM even if administered one day after inoculation.¹² In the present study, these observations were extended to a longer period of follow-up. We found that suckling mice were asymptomatic for several weeks after inoculation with the virus, although at one week after inoculation, all the mice had histological evidence of acute encephalitis which was indistinguishable from that seen in unprotected mice dying from the acute encephalomyelitis. Over the next few weeks, evidence of inflammatory response subsided in the antibody-protected

mice, although virus was still present since viral antigen, but not infectious virus, could be detected in most mice. In 60%, infectious virus could never be detected and the mice remained asymptomatic. In the other 40%, however, virus could be cultured from the brain and spinal cord, in association with neurological disease characterized by hindlimb paralysis and histological evidence of myelin destruction.

Several factors might have contributed to the appearance of clinical disease in only a fraction of the infected mice. A cell-associated variant of the virus, better able to evade the host immune system may have been selected during the period of clinical latency, as has been postulated to occur with measles virus in subacute sclerosing panencephalitis.¹⁴⁻¹⁶ In chronically infected neuroblastoma cells, MHV-JHM has been shown to evolve in such a manner in the presence of neutralizing antibody and could only be cultured after cell fusion with susceptible cells.¹⁷

The host immune system may also have contributed to the persistence of the virus by its inability to eliminate the virus. Maternal antibody is readily absorbed by the neonatal mouse until approximately 15 days postpartum.¹³ After this time, no new maternal antibody is absorbed, and the maternal antibody present in the suckling mouse decays with an approximate half-life of 5-7 days.¹⁸ The mice in our experiments developed hindlimb paralysis at a time when maternal antibody should have decreased by several half-lives. None of the clinically affected mice produced neutralizing antibody, but this deficiency was not limited to symptomatic mice, since only 50% of the asymptomatic mice developed a low, but detectable antibody response (Fig. 2).

The pathogenesis of the delayed neurological disease observed in mice protected with maternal antibody is very similar to the subacute demyelinating encephalomyelitis seen in either weanling or suckling rats inoculated intracerebrally with MHV-JHM. Dependent on the strain of rat, a fraction of animals will develop a subacute neurological disease characterized by hindlimb paralysis, after a variable latency period. Virus can be cultured from animals only during the initial stages of the infection and from animals which develop clinically evident disease.⁶⁻⁸ Histological examination of brains from clinically ill rats reveals chronic demyelination and remyelination, and a small proportion of asymptomatic animals show evidence of white matter disease as well.⁷ Intracellular viral RNA isolated both from rats with acute encephalomyelitis and from those with hindlimb paralysis has been reported to have different electrophoretic mobilities than does viral RNA isolated from infected tissue culture cells,^{19,20} suggesting that a variant of the virus has arisen during the rat infection. Whether mice with the chronic neurological disease show the same or similar changes in viral RNA remains to be determined.

Similarly, MHV-A59, a related strain of mouse hepatitis virus, also causes a subacute demyelinating disease in mice.^{21,22} Demyelination was apparent for several months after infection and viral antigen and RNA could be detected 3 and 10 months, respectively, post-inoculation. Unlike the antibody-modulated MHV-JHM infection, however, virus could only be isolated from mice during the first 25 days post-inoculation and neutralizing antibody was present in all surviving mice.

MHV-JHM was first isolated from a mouse that developed hindlimb paralysis.³ After several passages of the virus in mice, the period between inoculation of virus and onset of clinical disease became progressively shorter. In addition, an increasingly larger percentage of the mice developed acute encephalomyelitis with a decrease in the number of mice that developed hindlimb paralysis. Since then it has been difficult to obtain reproducibly a delayed, symptomatic, demyelinating encephalomyelitis in mice. The presence of maternal antibody facilitates this process and this model will allow determination of the factors important for viral latency and virus-induced demyelination in the mouse central nervous system.

Materials and methods

Cells and viruses. The JHM strain of mouse hepatitis virus (MHV-JHM), kindly supplied by Dr S. Weiss, was used in all studies. The virus was plaque-purified twice and grown in the 17CL-1 line of BALB/c 3T3 cells (also obtained from Dr S. Weiss) in Dulbecco's MEM supplemented with 10% fetal calf serum. Virus titer was $2-6 \times 10^6$ PFU/ml as determined by plaque assay on 17CL-1 or L-2 cells. L-2 cells, generously supplied by Dr J. Leibowitz, were also grown in Dulbecco's MEM with 10% fetal calf serum.

Animals. Pathogen-free C57BL/6 mice (Jackson Laboratories) were used in all studies. All mice were screened for prior MHV-JHM infection using an indirect immunofluorescence assay and all were antibody-negative prior to experimental manipulation. Female mice were immunized weekly for 5 weeks with MHV-JHM in Freund's adjuvant prior to mating. At 10 days of age, the offspring of immunized mice were inoculated intranasally with $2-6 \times 10^4$ PFU in 10 μ l. To titer virus from infected animals, each organ of interest was placed in Dulbecco's MEM and sonicated to near homogeneity. Large particles were removed by centrifugation for 10 min at 1000 *g*. Virus was titered on 17CL-1 or L-2 cells, with nearly equivalent results. The virus neutralization titer of mice sera was determined by a constant virus-variable serum plaque reduction assay.²³

Preparation of antisera. For preparation of polyclonal antisera, 17CL-1 cells were infected with MHV-JHM at a multiplicity of infection (M.O.I.) of 0.04. At 24 h post-infection cells were lysed in the original supernatant by freeze thawing, and the preparation clarified by low speed centrifugation. Virus was concentrated by centrifugation for 90 min at 100 000*g* in the Beckman SW27 rotor, and resuspended at a concentration of about 10^8 PFU/ml. Rabbits were inoculated subcutaneously five times with 0.1 ml of this preparation mixed with an equal volume of Freund's adjuvant. Sera was prepared and complement inactivated by treatment at 56°C for 30 min. The virus neutralization titer of the sera was greater than 1:2000 by plaque reduction assay. Monoclonal antibody to the nucleocapsid protein of MHV-JHM was the generous gift of Dr J. Leibowitz.

Immunoperoxidase studies. Animals were perfused with phosphate-buffered saline (PBS) via intracardiac puncture. Isolated organs were embedded in Tissue-Tek II O.C.T. medium (Miles Laboratory) and frozen in liquid nitrogen. Sections were prepared and fixed with methanol containing 0.3% hydrogen peroxide. The sections were treated sequentially with normal horse serum, with rabbit polyclonal antiviral antibody at a dilution of 1:50 or 1:100, then with biotinylated goat antirabbit antibody at a dilution of 1:100 or 1:200 and finally with Vectastain ABC (Vector Laboratories). The slides were developed by exposure to diaminobenzidine (0.8 mg/ml) in hydrogen peroxide (0.01%). The slides were air-dried, mounted and examined under the light microscope. Slides were briefly counterstained with hematoxylin prior to examination. No staining was observed if normal rabbit serum was substituted for the antiviral antibody or if brains from uninfected mice were used instead of infected brains.

Immunofluorescence assay. 17CL-1 cells were infected on coverslips with MHV-JHM at a m.o.i. of 1. After 12 hours, the cells were fixed with methanol and reacted with antisera from unimmunized or immunized mice at various dilutions. After washing, the coverslips were treated with fluorescein conjugated goat anti-mouse IgG diluted 1:200 and examined using a fluorescent microscope.

Light and electron microscopy. For light or electron microscopy, animals were perfused with 10% formalin or 3% glutaraldehyde via intracardiac injection. For light microscopy, the isolated organs were embedded in paraffin, cut into 4-10 μ m sections and stained with either hematoxylin and eosin or Luxol Fast Blue. For transmission electron microscopy, the organs were fixed with 3% glutaraldehyde, post fixed with osmium tetroxide, dehydrated and embedded in Epon. Thin sections for electron microscopy were stained with uranyl acetate and lead citrate and examined using a Hitachi H-600 electron microscope.

We thank Drs James Bale, Jr, C. Martin Stoltzfus, Richard Andersen and William Bell for

helpful discussion. S.P. was supported by the Medical Foundation in the initial phases of this work. The investigation was supported in part by N.I.H. Biomedical Research Grant RR 05372.

References

1. Lampert PW. Autoimmune and virus-induced demyelinating diseases. A review. *Am J Pathol* 1978; 91: 176–97.
2. Siddell S, Wege H, ter Meulen V. The biology of coronaviruses. *J Gen Virol* 1983; 64: 761–76.
3. Cheever FS, Daniels JB, Pappenheimer AM, Bailey OT. A murine virus (JHM) causing disseminated encephalomyelitis with extensive destruction of myelin. *J Exp Med* 1949; 90: 181–94.
4. Herndon RM, Griffin DE, McCormick V, Weiner LP. Mouse hepatitis virus-induced recurrent demyelination. *Arch Neurol* 1975; 32: 32–5.
5. Lampert PW, Sims JK, Kniazeff AJ. Mechanism of demyelination in JHM virus encephalomyelitis. *Acta Neuropathol* 1973; 24: 76–85.
6. Nagashima K, Wege H, Meyeremann R, ter Meulen V. Coronavirus induced subacute demyelinating encephalomyelitis in rats. A morphological analysis. *Acta Neuropathol (Berl)* 1978; 44: 63–70.
7. Nagashima K, Wege R, Meyeremann R, ter Meulen V. Demyelinating encephalomyelitis induced by long term coronavirus infection in rats. *Acta Neuropathol (Berl)* 1979; 45: 205–13.
8. Sorensen O, Perry D, Dales S. *In vivo* and *in vitro* models of demyelinating diseases. III. JHM virus infection of rats. *Arch Neurol* 1980; 37: 478–84.
9. Stohlman SA, Weiner LP. Chronic central nervous system demyelination in mice after JHM virus infection. *Neurology* 1981; 31: 38–44.
10. Weiner LP. Pathogenesis of demyelination induced by a mouse hepatitis virus. *Arch Neurol* 1973; 28: 298–303.
11. Buchmeier MJ, Lewicki HA, Talbot PJ, Knobler RL. Murine hepatitis virus-4 (strain JHM)-induced neurological disease is modulated *in vivo* by monoclonal antibody. *Virology* 1984; 132: 261–70.
12. Pickel K, Muller MA, ter Meulen V. Influence of maternal immunity on the outcome of murine coronavirus JHM infection in suckling mice. *Med Microbiol Immunol* 1985; 174: 15–24.
13. Halliday R. The effect of steroid hormones on the absorption of antibody by the young rat. *J Endocrinol* 1959; 18: 56–66.
14. Hall WW, Choppin PW. Measles-virus proteins in the brain tissue of patients with subacute sclerosing panencephalitis. Absence of the M protein. *N Engl J Med* 1971; 304: 1152–5.
15. Johnson KP, Norrby E, Swoveland P, Carrigan DR. Experimental subacute sclerosing panencephalitis: Selective disappearance of measles virus matrix protein from the central nervous system. *J Infect Dis* 1981; 144: 161–9.
16. Rammohan KW, McFarland HF, McFarlin DE. Subacute sclerosing panencephalitis after passive immunization and natural measles infection: role of antibody in persistence of measles virus. *Neurology* 1982; 32: 390–4.
17. Stohlman SA, Sakaguchi AY, Weiner LP. Characterization of the cold-sensitive murine hepatitis virus mutants rescued from latently infected cells by cell fusion. *Virology* 1979; 98: 448–55.
18. Pace MG, Dresser DW. The elimination of mouse and bovine globulins from the circulation of newborn and adult mice. *Quart J Exp Physiol* 1961; 46: 369–75.
19. Jackson DP, Percy DH, Morris VL. Characterization of murine hepatitis virus (JHM) RNA from rats with experimental encephalomyelitis. *Virology* 1984; 137: 297–304.
20. Taguchi F, Siddell SG, Wege H, ter Meulen V. Characterization of a variant virus selected in rat brains after infection by coronavirus mouse hepatitis virus JHM. *J Virol* 1985; 54: 429–35.
21. Lavi E, Gilden D, Wroblewska Z, Rorke L, Weiss SR. Experimental demyelination produced by the A59 strain of mouse hepatitis virus. *Neurology* 1984; 34: 597–603.
22. Lavi E, Gilden DH, Highkin MK, Weiss SR. Persistence of mouse hepatitis virus A59 RNA in a slow virus demyelinating infection in mice as detected by *in situ* hybridization. *J Virol* 1984; 51: 563–6.
23. Lennette EH, Schmidt NJ. Diagnostic procedures for viral and rickettsial infections. New York: American Public Health Association, 1969: 446.